

Primary Repair of the Medial Collateral Ligament With Internal Bracing



Jelle P. van der List, M.D., and Gregory S. DiFelice, M.D.

Abstract: The medial collateral ligament (MCL) is commonly injured in the setting of anterior cruciate ligament (ACL) injuries. Because the MCL has better healing capacity than the ACL, the general perception is that MCL injuries can be treated conservatively. Treating these injuries conservatively, however, can lead to residual valgus laxity. Furthermore, it delays time to surgery, which prevents acute treatment of concomitant ACL injuries using primary repair or acute reconstruction. Several treatment methods for MCL injuries have been proposed, including primary repair, augmented repair with autograft tissue, or primary reconstruction. In this surgical technique article, we present the technique of acute primary MCL repair with internal bracing with 2 limited incisions. With this technique, early surgical intervention is possible, and early rehabilitation is safe because of the internal bracing. Advantages include fast recovery, avoidance of muscle atrophy because of early mobilization, prevention of residual valgus instability, and maintenance of proprioception.

The medial collateral ligament (MCL) is commonly injured in the setting of anterior cruciate ligament (ACL) injuries (20% to 38%).¹ It is widely accepted that the MCL has better healing capacity than the ACL, which has led to the general perception that MCL tears can be treated conservatively whereas ACL tears require operative treatment.^{1,2}

It is common practice that grade I MCL tears (ligament sprain) can be treated conservatively and that operative ACL treatment can be commenced without delay. Regarding grade II MCL tears (partial tears), opinions vary among orthopaedic surgeons. Although most surgeons recommend conservative treatment of these injuries,³ some have shown there is residual laxity after treating grade II tears conservatively⁴ and therefore suggested operative treatment.¹ With regard to grade III MCL tears (complete tears), most surgeons prefer operative treatment because conservative treatment can

lead to significant residual laxity and potentially endanger the repaired ligament after primary repair or the graft after reconstruction. Furthermore, delaying surgery is not only suboptimal for patients but also can limit the opportunities for acute ACL treatment with primary repair.^{5,6} Several authors have shown excellent outcomes after MCL repair with graft augmentation or MCL reconstruction,⁷ and a recent systematic review showed that there is a role for primary repair in patients with MCL injuries.⁸ In this article we describe the surgical technique of primary MCL repair with internal bracing that can be used in the setting of isolated MCL injuries, combined ACL-MCL injuries, or multi-ligamentous knee injuries.

Surgical Technique

In this article and in [Video 1](#), we describe the repair of a complete proximal (femoral) MCL tear because this is the most common tear location of the MCL (approximately 90%).^{9,10} However, it should be noted that the same technique can be performed in mirrored fashion for distal (tibial) tears. A second note should be made that not only MCL tears can be treated with this technique, but other concomitant medial-sided injuries can be repaired by use of the same proximal suture anchor, such as medial patellofemoral ligament, posterior oblique ligament, or deep MCL injuries,¹¹ as described earlier by Lubowitz et al.¹⁰ Magnetic resonance imaging ([Fig 1A](#)) can be used preoperatively to identify which medial-sided structures are damaged,

From the Orthopaedic Trauma Service, Department of Orthopaedic Surgery, Hospital for Special Surgery, Weill Medical College of Cornell University, New York, New York, U.S.A.

The authors report the following potential conflict of interest or source of funding: J.P.v.d.L. receives support from Arthrex. Money not received yet, but request is approved. G.S.D. receives support from Arthrex.

Received December 5, 2016; accepted March 2, 2017.

Address correspondence to Jelle P. van der List, M.D., Hospital for Special Surgery, 535 E 70th St, New York, NY 10021, U.S.A. E-mail: vanderlistj@hss.edu

© 2017 by the Arthroscopy Association of North America

2212-6287/161219/\$36.00

<http://dx.doi.org/10.1016/j.eats.2017.03.003>

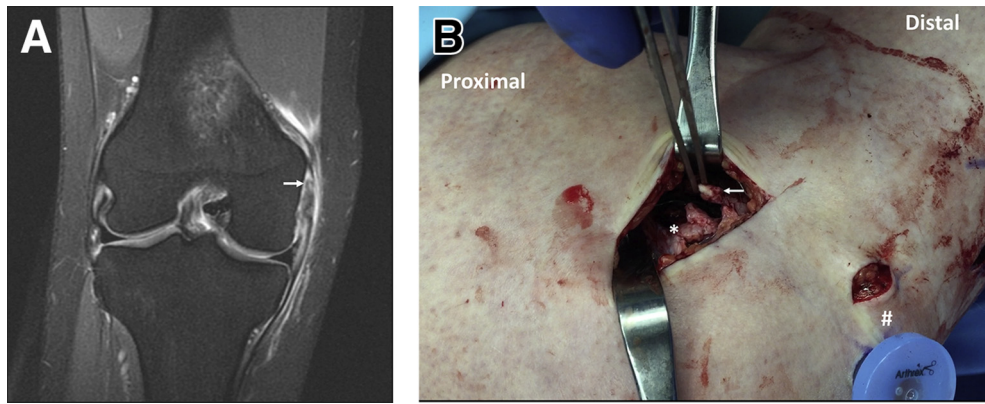


Fig 1. (A) Coronal T2-weighted image of the right knee showing a femoral tear of the medial collateral ligament (arrow). (B) View on the medial side of a right knee in 90° of flexion. The proximal stump of the medial collateral ligament (asterisk) and the distal avulsed ligament (arrow) can be seen. At the bottom right corner, the PassPort cannula (Arthrex) (hash sign) can be seen from the arthroscopic primary anterior cruciate ligament repair.

as well as what the location of the MCL tear is, to define the operative strategy.

Patient Positioning

The patient is placed in the supine position, and the operative leg is prepared and draped as for standard knee arthroscopy. The knee is placed in 20° of flexion, and the hip should be placed in external rotation, such that the medial side of the knee can be fully visualized.

Primary MCL Repair

A first minimal skin incision of approximately 3 to 4 cm is made over the medial epicondyle at the location of the femoral origin of the MCL. Dissection is then carried down through layer 1, as necessary. The proximal stump and the avulsed superficial MCL, which can sometimes be retracted, should then be

identified (**Fig 1B**). Starting as distally as possible, the MCL is sutured toward the proximal avulsed end in an alternating, interlocking Bunnell-type pattern. After the first stitch is passed, each suture limb is then passed through the ligament in the opposite direction. Generally, 4 to 5 passes can be made before the last suture exits the avulsed ligament proximally. It is important to assess the resistance with each pass because increased resistance can indicate a previously placed stitch. A punch tap is then used to create a threaded hole for suture anchor placement just posterior to the medial epicondyle.¹² The repair sutures of the MCL are passed through the eyelet of a 4.75-mm Vented BioComposite SwiveLock suture anchor (Arthrex, Naples, FL) that is loaded with FiberTape (Arthrex) that will function as the internal brace.¹³ The suture anchor is then deployed, while the repair sutures

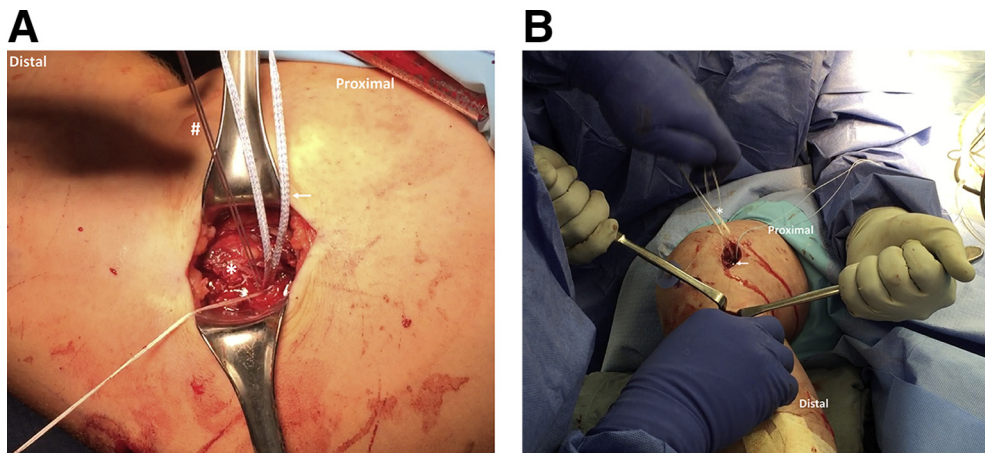


Fig 2. (A) View on the medial side of a left knee in 90° of flexion. The medial collateral ligament is now repaired (asterisk) with a suture anchor and repair stitches (remaining repair stitches [hash sign] need to be cut short), and the FiberTape internal brace (arrow) can be used to reinforce the repair. (B) View on the medial side of a right knee in 70° of flexion. The clamp is channeled from the distal wound to the proximal wound, and the tip of the clamp (arrow) is visible. The FiberTape (asterisk) is grabbed with the clamp and channeled distally.

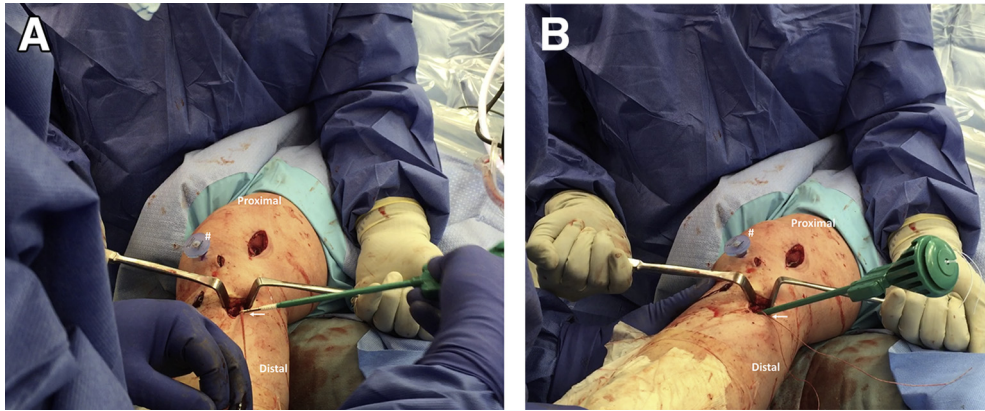


Fig 3. (A) View on the medial side of a right knee in 20° to 30° of flexion. The FiberTape internal brace is now channeled under the skin bridge, and a suture anchor (arrow) is used to fix the FiberTape on the anteromedial side of the tibia. The PassPort cannula (hash sign) of the primary anterior cruciate ligament repair can be seen. (B) View on the medial side of a right knee in full extension. The suture anchor is partially deployed in the tibia after the FiberTape has been tensioned (arrow), and the knee is now ranged through its range of motion to assess any overconstraint of the knee. The PassPort cannula (hash sign) of the primary anterior cruciate ligament repair can be seen.

of the MCL are tensioned to reapproximate the ligament toward the femoral MCL origin (Fig 2A). The knee should be held flexed to 30° to avoid capturing the joint. After the primary repair of the MCL is completed, the core stitches and repair stitches can be reused to approximate more superficial tissues as necessary. Once they are used to their fullest, the core stitches are removed, the repair stitches are cut short, and the primary repair of the ligament is complete. Depending on the injury pattern, in some cases, the senior author (G.S.D.) prefers to first deploy the suture anchor and then to suture the MCL from proximal to distal and suture the ligament toward the suture anchor.

Internal Brace

Now, a second minimal skin incision is made over the distal insertion of the superficial MCL, which is located approximately 6 cm distal to the joint line.¹² Dissection is made through layer 1 to expose the distal fibers of the superficial MCL. Care is taken to avoid the hamstring tendons that traverse the exposure. A clamp is placed under layer 1, and the MCL is followed proximally under the skin bridge until the proximal insertion is reached. The clamp is then visualized through the proximal incision wound. The FiberTape is grabbed with the clamp, is channeled under the skin bridge distally along the repaired MCL, and exits out of the distal wound at the distal insertion of the superficial MCL (Fig 2B).

The FiberTape now needs to be fixed distally with a second suture anchor (Fig 3A). By use of a punch tap, a hole is created at the center of the distal MCL insertion, just proximal to the hamstring tendons. The FiberTape is then passed through the loop of a second 4.75-mm Vented BioComposite suture anchor. The suture

anchor is placed at the hole, the FiberTape is tensioned with the knee at 30° of flexion, and the suture anchor is partially deployed in the hole. The knee is then tested for range of motion (ROM) and valgus stability to ensure the knee both is stable to valgus and has not been overconstrained (Fig 3B). Once satisfactory tension on the FiberTape is achieved, the suture anchor is fully deployed in the tibia. The core stitch is removed, the FiberTape is cut short, and the internal bracing procedure is complete. Finally, the knee is tested for ROM and valgus stability at 0° and 30° of flexion, and the wounds are closed in standard layered fashion. The advantage of the internal brace is that the repair is essentially protected, and the patient is able to both bear weight and begin ROM exercises immediately. Pearls and pitfalls of this technique are shown in Table 1.

Rehabilitation Protocol

Primary goals of rehabilitation are to obtain early ROM, prevent stiffness, and normalize gait. Other significant injuries, such as an ACL tear, often influence the exact rehabilitation protocol. In general, patients wear a brace for 4 weeks along with weight bearing as tolerated, and the brace is locked in extension until quadriceps control is regained. In the first few days, ROM exercises are initiated in controlled fashion. After 4 to 6 weeks, gentle strengthening is commenced and a standard ACL-MCL rehabilitation program is followed.

Discussion

Injury of the MCL in the setting of ACL injury is frequently reported, and the optimal treatment of grade II and III injuries is unclear.^{1,3-5,7,8} Most surgeons prefer conservative treatment for 4 to 6 weeks to let the MCL heal, after which ACL reconstruction is performed.

Table 1. Surgical Pearls and Pitfalls of Primary MCL Repair With Internal Bracing

Pearls
Use MRI to identify the MCL tear location and other concomitant medial-sided injuries.
Identify the avulsed MCL and other injured ligaments (POL, MPFL, deep MCL).
Repair the avulsed MCL from distal to proximal (or vice versa in the case of a tibial avulsion tear).
Sufficiently tension the repair stitches before deploying the suture anchor.
Load the suture anchor with additional sutures if other ligaments are injured.
Use a large Kelly clamp to follow the MCL proximally from the distal insertion (or vice versa in the case of a tibial avulsion tear).
Sufficiently tension the FiberTape with the knee at 30°, before deploying the anchor.
Deploy the suture anchor partially first so that tension can be adjusted in the case of overconstraint.
Cycle the knee and fix the FiberTape distally at 30° of flexion.
Pitfalls
Prevent tensioning the FiberTape at full extension because this can cause overconstraint.
Bear in mind that not fully deploying the suture anchors can cause hardware irritation.

MCL, medial collateral ligament; MPFL, medial patellofemoral ligament; MRI, magnetic resonance imaging; POL, posterior oblique ligament.

However, this has several disadvantages: Quadriceps muscle atrophy occurs, treatment is prolonged, and there is often residual laxity with valgus stress,^{4,9} which not only causes discomfort for the patient but also increases the risk of ACL (graft) reinjury.

The procedure of primary MCL repair with internal bracing is a minimally invasive, technically straightforward procedure that allows patients to immediately start mobilizing because the repair is protected by the internal brace. This is especially relevant given that a resurgence of interest in acute primary repair of ACL injuries has recently been noted.^{5,14} In patients with proximal ACL and proximal MCL tears, primary ACL and MCL repair with internal bracing can be performed in the acute setting with the advantage of avoiding quadriceps atrophy, maintaining proprioception, and preserving the patients' ligaments. The patient in [Video 1](#) underwent primary ACL and MCL repair with internal bracing within a week of injury. She immediately had a stable knee without the prolonged need for an external brace, and this enabled early physical therapy. At 7 weeks postoperatively—roughly the same time at which the patient would be undergoing a delayed ACL reconstruction after bracing of the MCL if she was treated by traditional means—the patient had normal ROM, had a stable knee, and was running in the clinic ([Video 1](#)). Primary MCL repair can also be performed in conjunction with ACL reconstruction, but it should be emphasized that a balance should be found between early surgery (good MCL tissue quality but risk of

arthrofibrosis) and late surgery (low risk of arthrofibrosis but potential scarring of the MCL).

Grade III MCL injuries are generally treated either conservatively, with repair augmented with grafts, or with primary reconstruction.^{1,9,11} Recently, however, Lubowitz et al.¹⁰ presented open primary MCL repair with internal bracing with suture anchors using 1 large incision on the medial side of the knee. More recently, Ateschrang et al.¹ described the technique and outcomes of ACL reconstruction and internal bracing of the MCL in 16 patients with acute ACL and grade II or III MCL injuries. At follow-up, they found excellent ROM and no patients with arthrofibrosis, and they attributed these findings to the use of 2 small incisions, as opposed to historical studies that used open primary repair and reported problems with ROM and arthrofibrosis. However, they did not repair the MCL but percutaneously internally braced the torn ligament with 2 large screws without ligament repair. They noted that 6 patients (38%) had femoral screw irritation, 4 of whom (25%) ultimately required screw removal. With our technique, we implemented the benefits of both studies: Two incisions were used instead of one; the MCL was repaired to preserve the proprioception and biomechanical properties of the native MCL; and minimally invasive suture anchors were used, as opposed to percutaneous screws.

Other authors have advocated using MCL reconstruction to restore valgus instability. A recent systematic review showed that postoperative medial stability was achieved in 49% to 100% of cases, depending on the technique of MCL reconstruction.¹⁵ Dong et al.¹⁶ compared MCL triangular reconstruction with MCL repair without an internal brace in the setting of ACL-MCL injuries and found equivalent outcomes regarding ROM, medial stability, and subjective outcomes but a higher rate of anteromedial instability in the repair group. The benefits of our presented MCL repair technique with internal bracing compared with MCL reconstruction are that MCL injuries can be treated in the acute setting; this procedure has a relatively quick

Table 2. Advantages and Disadvantages of Arthroscopic Primary MCL Repair With Internal Bracing

Advantages
The procedure is performed relatively quickly.
The native MCL is preserved.
The MCL repair is protected with internal bracing.
Early range of motion is possible (compared with conservative MCL treatment with an external brace).
Concomitant acute ACL surgery can be performed.
There is a lower risk of residual laxity compared with conservative treatment.
The technique can be performed in nearly all acute MCL cases. ^{9,10}
Disadvantages
The technique cannot be used in the chronic setting.

ACL, anterior cruciate ligament; MCL, medial collateral ligament.

recovery, as well as an early return to activity; quadriceps muscle atrophy is prevented; and the native MCL tissue is preserved (Table 2). More studies with longer-term follow-up are, however, necessary to assess if these benefits outweigh the potential for less optimal restoration of anteromedial stability, as Dong et al. noted.

In conclusion, we have presented the surgical technique of primary MCL repair with internal bracing using 2 relatively small skin incisions. With this technique, MCL injuries and other medial-sided ligamentous injuries can be repaired, and the internal bracing provides valgus stability and enables early ROM and weight bearing during rehabilitation. Furthermore, this treatment avoids delaying surgery in the setting of combined ACL-MCL injuries while enabling acute surgery to address injured tissues.

References

1. Ateschrang A, Dobele S, Freude T, Stockle U, Schroter S, Kraus TM. Acute MCL and ACL injuries: First results of minimal-invasive MCL ligament bracing with combined ACL single-bundle reconstruction. *Arch Orthop Trauma Surg* 2016;136:1265-1272.
2. Woo SL-Y, Vogrin TM, Abramowitch SD. Healing and repair of ligament injuries in the knee. *J Am Acad Orthop Surg* 2000;8:364-372.
3. Millett PJ, Pennock AT, Sterett WI, Steadman JR. Early ACL reconstruction in combined ACL-MCL injuries. *J Knee Surg* 2004;17:94-98.
4. Zaffagnini S, Bignozzi S, Martelli S, Lopomo N, Marcacci M. Does ACL reconstruction restore knee stability in combined lesions?: An in vivo study. *Clin Orthop Relat Res* 2007;454:95-99.
5. van der List JP, DiFelice GS. Preservation of the anterior cruciate ligament: A treatment algorithm based on tear location and tissue quality. *Am J Orthop (Belle Mead NJ)* 2016;45:E393-E405.
6. DiFelice GS, van der List JP. Arthroscopic primary repair of proximal anterior cruciate ligament tears. *Arthrosc Tech* 2016;5:e1057-e1061.
7. Koga H, Muneta T, Yagishita K, Ju YJ, Sekiya I. Surgical management of grade 3 medial knee injuries combined with cruciate ligament injuries. *Knee Surg Sports Traumatol Arthrosc* 2012;20:88-94.
8. DeLong JM, Waterman BR. Surgical repair of medial collateral ligament and posteromedial corner injuries of the knee: A systematic review. *Arthroscopy* 2015;31:2249-2255.e5.
9. Halinen J, Lindahl J, Hirvensalo E, Santavirta S. Operative and nonoperative treatments of medial collateral ligament rupture with early anterior cruciate ligament reconstruction: A prospective randomized study. *Am J Sports Med* 2006;34:1134-1140.
10. Lubowitz JH, MacKay G, Gilmer B. Knee medial collateral ligament and posteromedial corner anatomic repair with internal bracing. *Arthrosc Tech* 2014;3:e505-e508.
11. LaPrade RF, Wijdicks CA. The management of injuries to the medial side of the knee. *J Orthop Sports Phys Ther* 2012;42:221-233.
12. LaPrade MD, Kennedy MI, Wijdicks CA, LaPrade RF. Anatomy and biomechanics of the medial side of the knee and their surgical implications. *Sports Med Arthrosc Rev* 2015;23:63-70.
13. Mackay GM, Blyth MJ, Anthony I, Hopper GP, Ribbans WJ. A review of ligament augmentation with the InternalBrace: The surgical principle is described for the lateral ankle ligament and ACL repair in particular, and a comprehensive review of other surgical applications and techniques is presented. *Surg Technol Int* 2015;26:239-255.
14. van der List JP, DiFelice GS. Primary repair of the anterior cruciate ligament: A paradigm shift. *The Surgeon* 2017;15:161-168.
15. DeLong JM, Waterman BR. Surgical techniques for the reconstruction of medial collateral ligament and posteromedial corner injuries of the knee: A systematic review. *Arthroscopy* 2015;31:2258-2272.e1.
16. Dong J, Wang XF, Men X, et al. Surgical treatment of acute grade III medial collateral ligament injury combined with anterior cruciate ligament injury: Anatomic ligament repair versus triangular ligament reconstruction. *Arthroscopy* 2015;31:1108-1116.