

Case Report

Appropriateness of Mini-Invasive Approaches for Nausea and Vomiting Refractory to Medical Therapy in Palliative Care Setting: A Case Report

Chiara Casadio^a Elisa Tassinari^a Riccardo Carloni^a Romina Rossi^b
Maria Valentina Tenti^c Laura Fabbri^c Marco Maltoni^{c,d}

^aMedical Oncology, IRCCS Azienda Ospedaliero-Universitaria di Bologna, Bologna, Italy;

^bIRCCS Istituto Romagnolo per lo Studio dei Tumori (IRST) "Dino Amadori", Meldola, Italy;

^cPalliative Care Unit, Azienda Unità Sanitaria Locale (AUSL) Romagna, Forlì, Italy; ^dDepartment of Medical and Surgical Sciences, University of Bologna, Bologna, Italy

Keywords

Palliative care · Nausea · Vomiting · Endoscopic approaches · Gastrointestinal cancers

Abstract

Introduction: Nausea and vomiting are frequent multifactorial symptoms in oncological patients. These manifestations, mainly affecting the advanced disease stages, may lead to existential, psychological, and physical suffering, with a negative impact on the quality of life (QoL) of the individual and his family. The medical approach makes use of a wide range of drugs, with different antiemetic potency and various mechanisms of action, taking into account the etiology and the patient's response to the different therapeutic strategies. In recent years, in addition to pharmacological treatments, some endoscopic procedures have been integrated into clinical practice as promising palliative approaches. **Case Presentation:** Herein, we describe and discuss a case of a 64-year-old female affected by advanced stage pancreatic adenocarcinoma, in which different techniques – both medical and endoscopic – have been used to approach a refractory symptomatology with a negative impact on the patient's QoL. In the context of a multidisciplinary approach in primary palliative care, a tailored intervention encompassing invasive methods for palliative purposes, may be considered adequate and appropriate when the prognostic expectation and the physical functionality indices allow it. **Conclusion:** Minimally invasive palliative interventions should be offered to patients with advanced cancer when

symptoms become refractory to standard medical therapies, as part of the holistic approach in modern treatments. Therefore, the integration of an early palliative approach into the patient's therapeutic path becomes essential for the management of all the individual's needs.

© 2024 The Author(s).

Published by S. Karger AG, Basel

Introduction

In advanced cancer patients, common symptoms like nausea and vomiting may have a significant impact on quality of life (QoL), resulting in a relevant physical and psychological distress. Nausea, a persistent sensation of being about to vomit, can occur alone or together with other gastrointestinal manifestations such as bloating, upper abdominal pain and a sense of gastric replenishment. Furthermore, it often results in food avoidance and potentially weight loss. On the other hand, vomiting may occur with or without the sensation of nausea.

In patients with advanced cancer, nausea and vomiting's etiology is often multifactorial. In fact, both symptoms may result from anticancer treatments (both radiotherapy and chemotherapy), acute complication due to the presence of the malignancy (such as hypercalcemia, malignant gastrointestinal obstruction, peritoneal carcinomatosis and ascites), gastroparesis or central nervous system tumors [1]. Although it may be challenging, it would be important for clinicians to identify their underlying causes to assess the most appropriate therapeutic options. For patients at the end of life, an empiric medical treatment for nausea and vomiting seems widely reasonable even when a specific reason has not been identified [2].

Dopamine, histamine, serotonin (both type 3 [5-HT₃] and type 4 [5-HT₄]), and muscarinic acetylcholine receptor antagonists are all well-established classes of antiemetic agents. Often, a combination of several antiemetics with various mechanisms of action has proved useful in symptom control [2]. Metoclopramide (a dopamine D₁ and D₂ receptor antagonist, 5-HT₃ receptor antagonist and 5-HT₄ receptor agonist) is usually the drug of first choice in palliative care, especially when a cause has not been correctly identified [2]. In patients who do not benefit from metoclopramide, several other centrally acting antiemetic agents such as haloperidol, chlorpromazine or olanzapine may be used. Haloperidol, a typical antipsychotic antagonist of D₂ dopamine receptor and alpha-adrenergic antagonist, is often used as a second-line option. Several randomized clinical trials have shown its prompt effectiveness at improving symptoms [3]. There are few clinical trials evaluating the use of the neuroleptic chlorpromazine (an antagonist of D₂-D₃-D₅ dopamine receptors); nevertheless, the Multi-national Association of Supportive Care in Cancer (MASCC) guidelines recommend it as a possible drug of choice [2]. In addition, the atypical antipsychotic olanzapine (an antagonist/inverse agonist on D₁-D₂-D₄ dopamine receptors and on 5-HT_{2A}, 5-HT_{2C} and 5-HT₃ serotonin receptors) appears to be a well-tolerated option and a reasonable alternative to metoclopramide in patients with advanced cancer and no clear etiology for the chronic nausea and vomiting. In fact, in a small double-blinded randomized clinical trial, comparing the role of olanzapine versus placebo in 30 individuals with advanced cancer and persistent nausea and vomiting, patients reported less emesis, improved appetite and QoL [4].

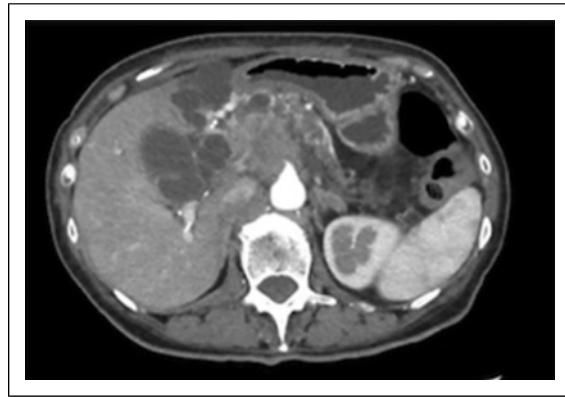
Furthermore, endoscopic approaches – such as enteral stentings – are starting to assume an increasing role to palliate invalidating symptoms related to gastrointestinal tumors [5]. The 2022 European Society of Gastrointestinal Endoscopy (ESGE) guidelines suggest creating an endoscopic ultrasound (EUS)-guided gastroenterostomy (GE) in patients with gastric outlet obstruction (mostly caused by pancreatic, gastric, ampullary or biliary tumors) [6].

EUS-GE can combine the benefits of surgery and metal stent placement, creating a relatively large gastrointestinal anastomosis using a minimally invasive technique. Furthermore, for patients presenting with abdominal pain not adequately controlled with analgesic drug use or when significant opioid-induced side effects are present, EUS-guided celiac plexus neurolysis has been shown to be as safe and effective as traditional non-endoscopic methods in several meta-analyses. In particular, this technique allows patients both to decrease their analgesic drug use and improve pain control [7]. Herein, we reported a multimodal therapeutic approach in a patient with pancreatic adenocarcinoma, suffering from difficult managing nausea, vomiting and abdominal pain.

Case Presentation

In May 2022, a 64-year-old female referred to the emergency department complaining of epigastric pain, radiated to the back, present for about a month. The patient's past medical history was characterized by arterial hypertension, supraventricular tachycardia treated with transcatheter radiofrequency ablation, benign thyroid nodules and renal colic. To investigate the intense abdominal pain, she underwent several in-depth investigations, such as full laboratory examinations, contrast-enhanced thorax-abdomen computed tomography (CT) and EUS-guided fine-needle aspiration biopsy. The whole instrumental assessments revealed the presence of a borderline-resectable pancreatic ductal adenocarcinoma of the head-uncinate process, about the size of 30 mm. According to the oncologist's recommendation, the patient has been enrolled in the phase II randomized clinical trial CASSANDRA (NCT04793932), comparing the efficacy of short-course versus long-course preoperative chemotherapy with cisplatin, nab-paclitaxel, capecitabine, and gemcitabine or oxaliplatin, folinic acid, irinotecan, and 5-fluorouracil (mFOLFIRINOX). From June 8 to July 27, 2022, the women received four cycles of mFOLFIRINOX, with discrete subjective tolerance. The restaging CT showed a locoregional disease progression, with perilesional fat-tissue involvement. Consequently, from August 17, the patient started a first-line chemotherapy strategy based on gemcitabine and nab-paclitaxel (last cycle: October 12, 2022). Nevertheless, the combination therapy has been impaired by severe nausea, vomiting, abdominal pain, and anorexia. To set the correct symptoms management, after several attempts with the most used outpatient antiemetic strategies (such as metoclopramide and octreotide), the patient needed hospitalization. Upon admission, the woman had an ECOG Performance Status (ECOG PS) of 2 and a Palliative Prognostic Score (PaP Score) of 8.5 points; during the stay she received: specific antiemetic treatment with 5-HT₃ antagonist (ondansetron 8 milligrams (mg) intravenous two times per day), corticosteroids (desametasone 8 mg intravenous per day), analgesic therapies (oxycodone 10 mg 3 tablets per day, fentanyl transdermal 100 micrograms (µg) every 72 h, paracetamol 1,000 mg 3 tablets per day, pregabalin 75 mg 2 tablets per day) and fluid rehydration, combined with fasting [8]. A total body CT scan (Fig. 1), performed on October 31, revealed further disease progression, with massive vascular involvement, cystic, pancreatic and common hepatic duct enlargement and duodenal C-loop compression. Laboratory examinations showed an important serum bilirubin (total level 10.83 mg per deciliter (mg/dL) – normal values 0.3–1 mg/dL – of which conjugated 10.12 mg/dL – normal values 0.2–0.8 mg/dL), transaminases (aspartate aminotransferase 263 units per liter (U/L) – normal values: less than 30 U/L, alanine aminotransferase 351 U/L – normal values: less than 40 U/L), gamma-glutamyl transferase (1,042 U/L – normal values 5–36 U/L) and alkaline phosphatase (1,065 U/L – normal values 50–220 U/L) elevation. On November 7, given the malignant principle of biliary duct obstruction leading to the important jaundice, the patient underwent ultrasound-guided transduodenal endoscopic biliary

Fig. 1. Abdominal CT scan before endoscopic procedures (performed on October 31, 2022). The radiological examination showed a volumetric enlargement of the primary lesion (62 × 38 × 54 millimeters [mm]), with a massive arteriovenous involvement (superior mesenteric artery, celiac trunk, portomesenteric confluence, inferior vena cava). The newly formed tissue compressed the duodenal C-loop, dislocated due to gallbladder overdistension. The cystic, pancreatic and common hepatic ducts were enlarged, with intrahepatic biliary tree ectasia.

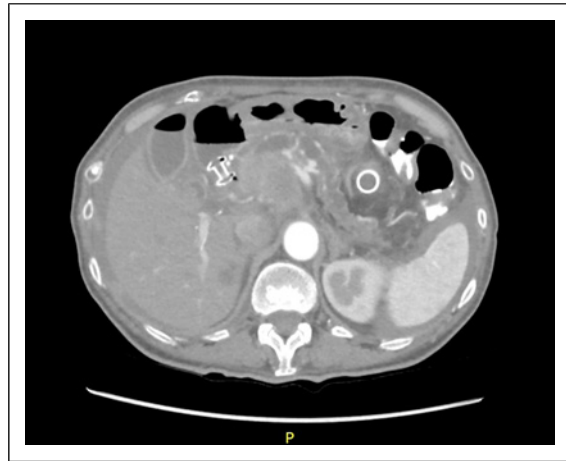


drainage, with Hot-Axios metal stenting, after a first unsuccessful attempt of endoscopic retrograde cholangiopancreatography. The next few days, the woman was able to feed with a creamy diet and complained no more abdominal pain. Unfortunately, several days later, the patient showed a recurrence of the whole symptomatology (refractory abdominal pain, vomiting and nausea), notwithstanding the medical therapy strengthening. After an adequate interview with the patient and her family, reassessing ECOG PS and PaP Score (consistent with the previous one), on November 11, the woman underwent EUS-guided gastroenteric anastomosis using lumen-apposing metal stent, combined with celiac plexus neurolysis. After this procedure, the woman experienced an important clinical improvement, with the resumption of enteral feeding. Furthermore, the clinicians reduced the massive daily antiemetic drug therapy (stop ondansetron and dexamethasone, started metoclopramide 10 mg 2 tablets per day), with a considerable sparing of side effects. An abdominal CT scan has been performed on November 15 to monitor the clinical course (Fig. 2). The radiological assessment confirmed the clinical suspicion of further disease progression, with a significant ascites accumulation. According to the woman's expectations and given the several persistent symptoms, the patient was moved to a hospice structure. Thanks to this therapeutic adjustment, the patient was gradually able to come back home into well-being for several weeks, before last hospice admission, during while she required for a terminal sedation to relieve emotional and physical distress. The patient died without apparent signs of suffering on February 23, 2023.

Discussion

As widely known, nausea and vomiting are symptoms often reported by cancer patients. Pharmacological treatments with a combination of antiemetics medications may not always be effective; hence, some individuals experience drug-refractory symptoms. Bearing in mind their detrimental impact on QoL, non-pharmacological interventions are taking hold in therapeutic management to provide an integrated response to cancer patient's needs. In this case report, we shed light on the promising results of a multidisciplinary approach, based both on pharmacological and endoscopic interventions, to refractory symptoms affecting the advanced stages of the disease. In fact, recent technical advancements led to wider clinical applications of EUS-guided procedures, such as drainage of obstructed biliary systems and celiac plexus neurolysis [7]. Traditionally, surgical gastrojejunostomy or endoscopic placement of an enteral metal stent has been the therapies of choice for gastric outlet obstruction;

Fig. 2. Abdominal CT scan after endoscopic procedures (performed on November 15, 2022). The radiological investigation, besides confirming the correct placement of the metal stent, showed an important increase in the peritoneal fluids, with a greater stickiness in the pelvic cavity (65 mm).



several studies compared these two techniques [9, 10]. Since 2022, ESGE guidelines recommend EUS-GE as an alternative to enteral stenting or surgery for malignant gastric outlet obstruction [6]. More in detail, the EUS-GE is a technique based on the placing of a metal stent (lumen-apposing metal stent) between the stomach and a duodenal or jejunal loop to circumvent a gastric outlet obstruction. This method manages to combine the theoretical advantages of enteral stenting and surgery, using a minimally invasive technique to create a large gastrointestinal anastomosis at a distance from the primary tumor [11, 12]. As widely proven, EUS-GE is a minimally invasive and cost-effective intervention, beneficial for patient's QoL [13]. Some papers focused on the effective role of endoscopic approaches on patients with advanced gastrointestinal tumors [14]. In their work, Gohil and colleagues described the various endoscopic techniques used in pancreatic cancer to palliate biliary or gastric outlet obstruction and pain, highlighting the potential role of a multidisciplinary management of these patients [5]. Nevertheless, none of these latter has embedded any palliative prognostic evaluation to assess the intervention's suitability on a specific patient. To our knowledge, this is the first report describing a challenging clinical case in which the use of a validated and accessible prognostic score (i.e., PaP Score) has influenced medical decisions in a context of early palliative care [8]. In our opinion, techniques actually considered "invasive," such as endoscopic or surgical ones, may find a justification in a multidisciplinary context for selected patients with adequate prognostic life expectations and performance status in the field of early palliative care. Certainly, this pioneering approach may lead to a lack of understanding among patients and relatives, which may find out of proportion an invasive approach in an advanced disease setting. We believe that proper reporting and shared care planning, with the help of experienced psychologists if needed, may result in a successful doctor-patient communication.

Once again, everyday clinical practice needs the integration of a systematic use of palliative prognostic score evaluation in a cross-disciplinary approach to oncological patients to ensure a holistic take care of the individual. The CARE checklist has been completed by the authors for this case report, online supplementary material (for all online suppl. material, see <https://doi.org/10.1159/000536218>).

Conclusions

Particularly delicate is the accompaniment of patients in their end-of-life period. In this challenging moment, specialists should be able to recognize the needs of both patients and family members, defining a treatment plan consistent with the current clinical presentation,

giving consideration to all the possible future developments. All this may only take place in a multidisciplinary approach to the specific clinical need, in which different health care practitioners can cooperate to guarantee the best possible symptoms' management. In conclusion, in our opinion, it is crucial to include the use of endoscopic procedures – as a part of a holistic approach – to relieve nausea and vomiting in patients with gastric outlet obstruction in the context of an early palliative approach.

Statement of Ethics

Written informed consent was obtained from the patient's next of kin for publication of the details of their medical case and any accompanying images. Ethical approval is not required for this study in accordance with local or national guidelines.

Conflict of Interest Statement

The authors have no conflicts of interest to declare.

Funding Sources

This study was not supported by any sponsor or funder.

Author Contributions

Chiara Casadio and Elisa Tassinari: writing – original draft; Riccardo Carloni, Romina Rossi, Maria Valentina Tenti, and Laura Fabbri: writing – review and editing; and Marco Maltoni: writing – review and editing and supervision.

Data Availability Statement

All data generated or analyzed during this study are included in this article and its supplementary material files. Further inquiries can be directed to the corresponding author.

References

- 1 Gordon P, LeGrand SB, Walsh D. Nausea and vomiting in advanced cancer. *Eur J Pharmacol*. 2014;722:187–91.
- 2 Davis M, Hui D, Davies A, Ripamonti C, Capela A, DeFeo G, et al. MASCC antiemetics in advanced cancer updated guideline. *Support Care Cancer*. 2021;29(12):8097–107.
- 3 Hardy JR, Skerman H, Philip J, Good, P, Currow, DC, Mitchell, G, et al. Methotrimeprazine versus haloperidol in palliative care patients with cancer-related nausea: a randomised, double-blind controlled trial. *BMJ Open*. 2019;9(9):e029942.
- 4 Navari RM, Pywell CM, Le-Rademacher JG, White P, Dodge AB, Albany C, et al. Olanzapine for the treatment of advanced cancer-related chronic nausea and/or vomiting: a randomized pilot trial. *JAMA Oncol*. 2020;6(6):895–9.
- 5 Gohil VB, Klapman JB. Endoscopic palliation of pancreatic cancer. *Curr Treat Options Gastroenterol*. 2017;15(3):333–48.
- 6 van der Merwe SW, van Wanrooij RLJ, Bronswijk M, Everett S, Lakhtakia S, Rimbas M, et al. Therapeutic endoscopic ultrasound: European Society of Gastrointestinal Endoscopy (ESGE) guideline. *Endoscopy*. 2022;54(2):185–205.

- 7 Puli SR, Reddy JB, Bechtold ML, Antillon MR, Brugge WR. EUS-guided celiac plexus neurolysis for pain due to chronic pancreatitis or pancreatic cancer pain: a meta-analysis and systematic review. *Dig Dis Sci*. 2009; 54(11):2330–7.
- 8 Maltoni M, Nanni O, Pirovano M, Scarpi E, Indelli M, Martini C, et al. Successful validation of the palliative prognostic score in terminally ill cancer patients. Italian Multicenter Study Group on Palliative Care. *J Pain Symptom Manage*. 1999;17(4):240–7.
- 9 Jeurnink SM, Steyerberg EW, van Hooft JE, van Eijck CHJ, Schwartz MP, Vleggaar FP, et al. Surgical gastrojejunostomy or endoscopic stent placement for the palliation of malignant gastric outlet obstruction (SUSTENT study): a multicenter randomized trial. *Gastrointest Endosc*. 2010;71(3):490–9.
- 10 Minata MK, Bernardo WM, Rocha RS, Morita FHA, Aquino JCM, Cheng S, et al. Stents and surgical interventions in the palliation of gastric outlet obstruction: a systematic review. *Endosc Int Open*. 2016;4(11):E1158–70.
- 11 Bronswijk M, Vanella G, van Malenstein H, Laleman W, Jaekers J, Topal B, et al. Laparoscopic versus EUS-guided gastroenterostomy for gastric outlet obstruction: an international multicenter propensity score-matched comparison (with video). *Gastrointest Endosc*. 2021;94(3):526–36.e2.
- 12 Khashab MA, Bukhari M, Baron TH, Nieto J, El Zein M, Chen YI, et al. International multicenter comparative trial of endoscopic ultrasonography-guided gastroenterostomy versus surgical gastrojejunostomy for the treatment of malignant gastric outlet obstruction. *Endosc Int Open*. 2017;5(4):E275–81.
- 13 Aadam AA, Liu K. Endoscopic palliation of biliary obstruction. *J Surg Oncol*. 2019;120(1):57–64.
- 14 Yamao K, Sawaki A, Takahashi K, Imaoka H, Ashida R, Mizuno N. EUS-guided choledochoduodenostomy for palliative biliary drainage in case of papillary obstruction: report of 2 cases. *Gastrointest Endosc*. 2006;64(4): 663–7.