

## Case Report

## Multidisciplinary management of concomitant pulpal and periodontal lesion: A case report



Mustafa A. Al Attas, DDS<sup>a</sup>, Hadeel Y. Edrees, PhD<sup>a</sup>, Aya M.N. Sammani, MSc<sup>b</sup> and Ahmad A. Madarati, PhD<sup>b,\*</sup>

<sup>a</sup> College of Dentistry, King AbdulAziz University, KSA

<sup>b</sup> Restorative Dental Science Department, College of Dentistry, Taibah University, Almadinah Almunawwarah, KSA

Received 11 November 2016; revised 8 May 2017; accepted 14 May 2017; Available online 27 June 2017

### المخلص

في تقرير الحالة هذه؛ نصف معالجة حالة شاملة لمنطقتي اللب واللثة معا. تقدم مريض في سن ٣١ بأعراض التهاب دواعم السن الذروي للسن رقم ٣٦ نتج عن علاج فاشل للثة والتهاب عدواني عام لدواعم السن. وبعد تقليح كامل الفم والتخطيط للجذر، بدأنا بعلاج عصب السن رقم ٣٦. وفي حين تم بنجاح علاج القناتين البعيدة والشدقية الوسطى، حدث اختراق للقناة اللسانية الوسطى، وتمت معالجتها باستخدام المركب المعدني ثلاثي الأكسدة. قمنا بجراحة دقيقة ذروية للجذر الوسطى بالإضافة إلى تنظيف جراحي لدواعم اللثة للربع الأيسر السفلي. وبعد ذلك بثلاثة أسابيع قمنا بجراحات استئصالية وتجديدية لثوية للأرباع الثلاثة الباقية. وبسبب فترة الستة أشهر اللازمة للعلاج، قمنا بالجراحة التجديدية للربع الأيسر السفلي. وعند الكشف على المريض بعد ستة أشهر من العلاج تبين أن الجذر الوسطى قد تم شفاؤه بالكامل إضافة إلى تعافي الجذر الأبعد إلى حد كبير. وقد ساهم نهج متعدد التخصصات واستخدام الأدوات الحديثة في تحقيق نتائج جيدة.

**الكلمات المفتاحية:** نهج متعدد التخصصات؛ اللبي واللثوي؛ تقليح كامل الفم؛ تخطيط الجذر؛ جراحة اللثة

### Abstract

In this case report, the management of a concomitant endodontic-periodontal lesion case is described. A 31-year-old patient presented with symptomatic apical periodontitis of tooth #36 due to failed endodontic treatment and a generalized aggressive periodontitis. Following full-mouth scaling and root-planing, a root-

canal retreatment (tooth #36) was initiated. While the distal and mesio-buccal canals were successfully treated, a transportation perforation of the mesio-lingual canal occurred and was repaired by the MTA. An apical microsurgery of the mesial root combined with surgical periodontal debridement for the lower left quadrant was performed. Three weeks later, resective and regenerative periodontal surgeries of the other 3 quadrants were accomplished. Because of the 6-month post-operative healing, the regenerative periodontal surgery for the lower-left quadrant was performed. The 6-month post-operative recall showed complete healing of the mesial root lesion and reduction of the distal root lesion. The multidisciplinary approach and advanced armamentarium contributed to favourable outcome.

**Keywords:** Concomitant; Endodontics; Endo-perio lesions; Multidisciplinary approach

© 2017 The Authors.

Production and hosting by Elsevier Ltd on behalf of Taibah University. This is an open access article under the CC BY-NC-ND license (<http://creativecommons.org/licenses/by-nc-nd/4.0/>).

### Introduction

The dental pulp and the surrounding periodontium communicate through dentinal tubules, lateral canals, developmental grooves and apical foramina, which are potential portals for transmission of disease between both tissues. Diagnosis and therefore differentiation of endodontic and periodontal diseases is challenging because they may

\* Corresponding address: Restorative Dental Science Department, College of Dentistry, Taibah University, PO Box: 2898, Almadinah Almunawwarah, 43353, KSA.

E-mail: [ahmad.madarati@hotmail.co.uk](mailto:ahmad.madarati@hotmail.co.uk) (A.A. Madarati)

Peer review under responsibility of Taibah University.



have similar clinical characteristics and may impact each other.<sup>1</sup>

Several classifications have been suggested for periodontal-endodontic lesions. Torabinejad & Trope classified them as endodontic origin, periodontal origin, combined endodontic-periodontal lesions, separate endodontic and periodontal lesions, lesions with communication or lesions without communication.<sup>2</sup> A recent classification categorized lesions based on the primary disease with its secondary effect into retrograde periodontal disease (either as primary endodontic lesion with drainage through the periodontal ligament or primary endodontic lesion with secondary periodontal involvement), primary periodontal lesion, primary periodontal lesion with secondary endodontic involvement, combined endodontic-periodontal lesion, or iatrogenic periodontal lesions.<sup>3</sup>

However, a commonly used classification categorizes endodontic-periodontal lesions as Primary Endodontic lesions, Primary Periodontal lesions and Combined lesions.<sup>4</sup> Another category, Concomitant Pulpal and Periodontal lesions, was added later and includes the two separate lesion types simultaneously in which both disease states exist but with different causative factors and with no evidence that either disease has influenced the other.<sup>5</sup>

The combined endodontic-periodontal lesions were investigated; thus, different treatment strategies were described.<sup>6–8</sup> Oh et al. proposed the following 4-phase treatment algorithm: (i) pre-surgical (determining periodontal/regenerative prognosis), (ii) endodontics, (iii) periodontal surgical, and (iv) post-guided-tissue regeneration reevaluation protocol.<sup>6</sup> Tseng et al. reported treatment of a true combined endodontic-periodontal lesion<sup>9</sup> by a nonsurgical root-canal-retreatment followed immediately by a periodontal treatment including guided tissue regeneration. Karabucak and Setzer treated two cases; confirming the effectiveness of an apical surgery supported by periodontal guided tissue regeneration.<sup>10</sup>

The aim of this work is to describe the multidisciplinary clinical management of a concomitant endodontic-periodontal lesion.

### Case report

A 31-year-old female patient presented to the endodontic specialty clinic at the dental hospital, King AbdulAziz University, KSA, with a chief complaint, "I have pain when chewing on lower left molars, and a bad mouth smell." Dental history revealed a five-year old root-canal-treatment (tooth #36) and multiple permanent restorations. Clinical examination (Figure 1A) showed a defective composite restoration on tooth #36, a missing tooth #46, normal response to cold test for #37 and *Halitosis*, despite fair oral hygiene. Teeth #36 and #37 had 5–6 mm buccal and lingual periodontal pockets. Tooth #36 showed buccal grade-1 furcation involvement with grade-1 mobility. Teeth #37 and #47 showed buccal grade-2 furcation involvement with grade-2 mobility. The three teeth were tender on percussion and palpation. Radiographic examination revealed a previous substandard root-canal-treatment of tooth #36 with apical radiolucency (Figure 1B) and severe vertical bone loss at the proximal area between teeth #36 & #37 and the mesial area of #47 (Figure 1C). A generalized aggressive periodontitis and a

previously treated tooth (#36) with symptomatic apical periodontitis were the final diagnosis. The treatment plan involved saving tooth #36 and included the following stages:

#### 1. Initial Periodontal Treatment

Full-mouth scaling and root planing were combined with adjunctive antibiotic coverage as described by Lindhe et al. (Augmentin 1 gm twice/day and Metronidazole 500 mg 3 times/day for 2 weeks).<sup>8</sup>

#### 2. Endodontic Treatment (tooth #36)

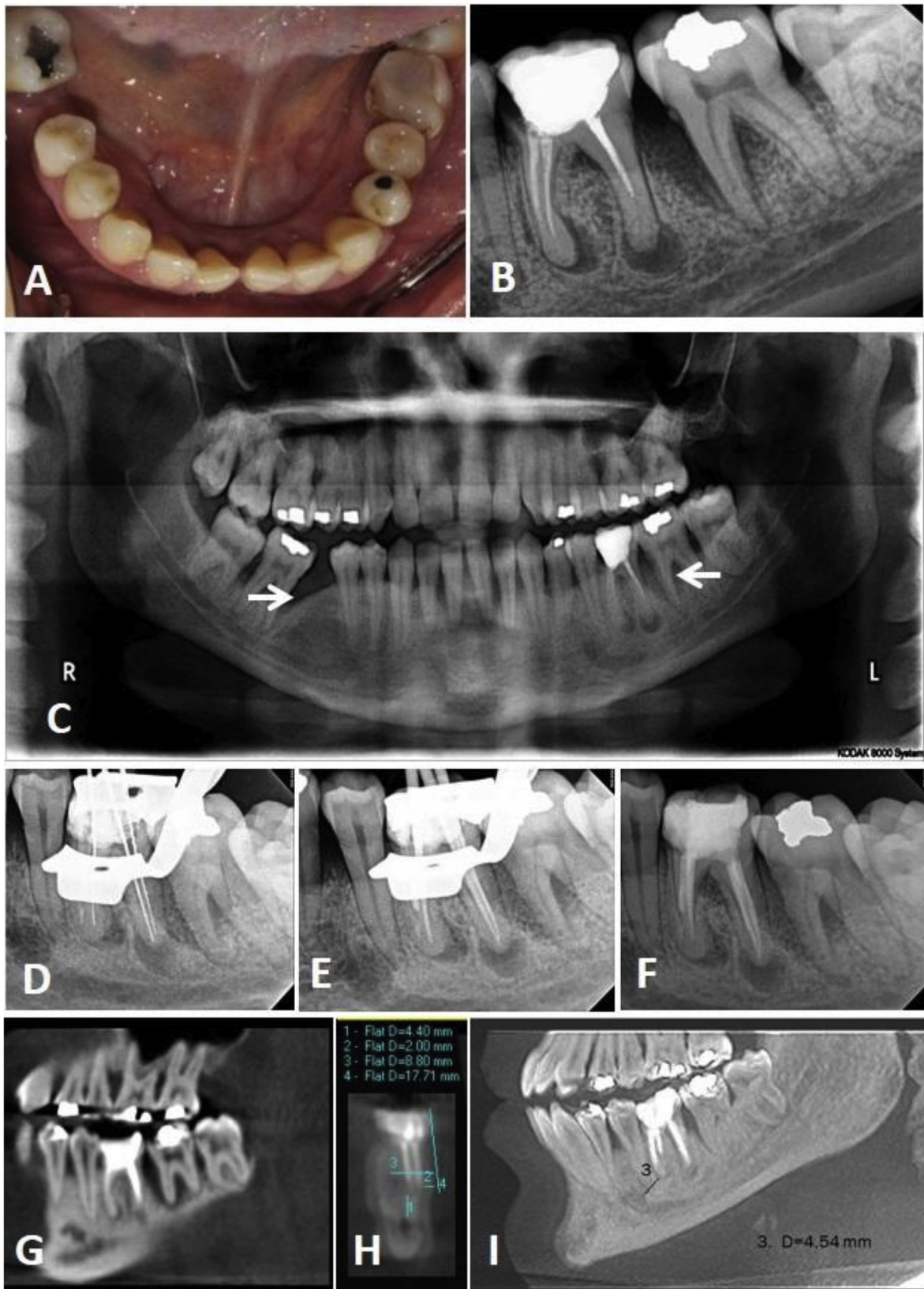
The defective composite restoration was removed, and the tooth (#36) was rebuilt with glass-ionomer cement (GIC) (Fuji IX GP<sup>®</sup>, GC, Chicago, IL). The old gutta-percha filling was removed using ProTaper Universal Retreatment<sup>®</sup> files (Dentsply Tulsa Dental, Tulsa, OK) (Figure 1D–F). The distal and mesio-buccal canals were successfully cleaned and shaped up to X3 ProTaper-Next, files (Dentsply Tulsa Dental, Tulsa, OK). However, a transportation perforation occurred while negotiating the mesio-lingual canal. The distal and mesio-buccal canals were obturated with gutta-percha and sealer using the continuous wave technique. The perforated mesio-lingual canal was repaired with Pro-Root MTA cement (Dentsply Tulsa Dental, Tulsa, OK). The tooth was restored with GIC for one week and later replaced with composite (GC America, Chicago, IL) (Figure 1F).

#### 3. Surgical Endodontic and Periodontal Treatment

A decision on apical microsurgery of the mesial root combined with a surgical periodontal debridement was agreed. A preoperative Cone-Beam-Computerized-Tomography (CBCT) showed 4.5 mm between the mesial root apex (tooth #36) and the mental foramen and 4.4 mm between the root apices and the mandibular canal. The CBCT also showed 8.8 mm bucco-lingual thickness of the mesial root. Following local anaesthesia, a vertical incision mesial to tooth #34 and a sulcular incision extending from tooth #34 to #37 distal surface, a triangular full-thickness flap was reflected to perform periodontal debridement (Figure 2). Under microscope magnification and following an osteotomy, the apical 4 mm of the mesial root (tooth #36) was resected, the canals were identified and two 3 mm retrograde cavities were prepared using surgical ultrasonic tips (Satelec/Acteon, Merignac, France) and were filled with MTA (Figure 3). The flap was replaced, sutured and a post-surgery radiograph was taken. Three weeks later, resective and regenerative periodontal surgeries of the other three quadrants were performed. (Figure 4A–C). Six months post-apical surgery, good healing of periapical and periodontal tissues of tooth #36 was observed clinically and radiographically (Figure 4D and E). Therefore, the regenerative periodontal surgery for the lower left quadrant using a bone graft and a collagen membrane were performed (Figure 4D–I).

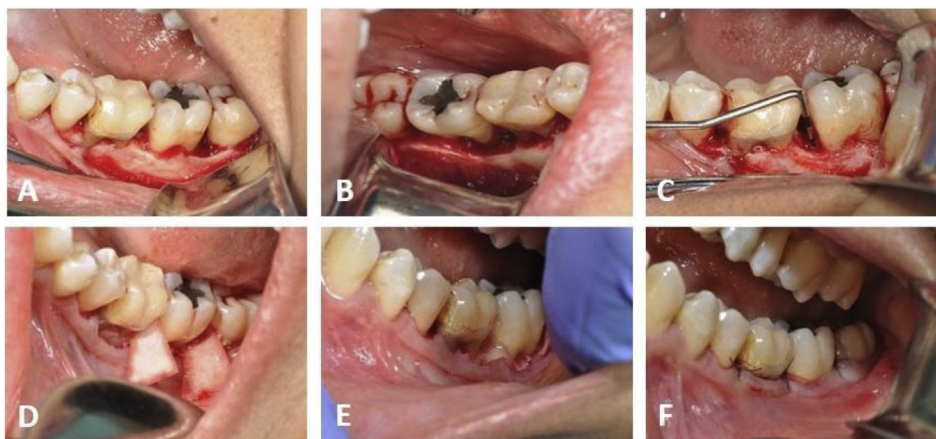#### 4. Follow-up

The 6-month post-periodontal surgery clinical and radiographic follow-up revealed normal response of teeth

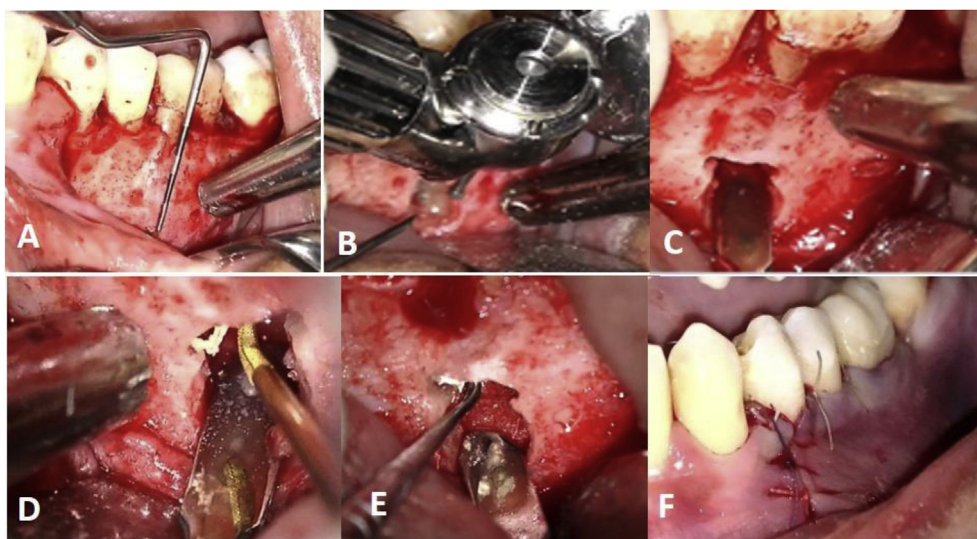


**Figure 1:** (A) Pre-operative clinical view. (B) Pre-operative periapical radiograph. (C) Panoramic radiograph showing bilateral vertical bone loss (arrows). (D–F) Retreatment procedures radiographs. (G–I) Cone Beam Computerized Tomography (CBCT) assessment of lower left quadrant.





**Figure 2:** Regenerative periodontal surgery of lower left quadrant.



**Figure 3:** Some steps of apical microsurgery of mesial root of tooth #36; (A) Working length determination (B) Osteotomy. (C) Root after resection. (D) Retro-cavity preparation. (E) MTA retro-filling. (F) Suturing.

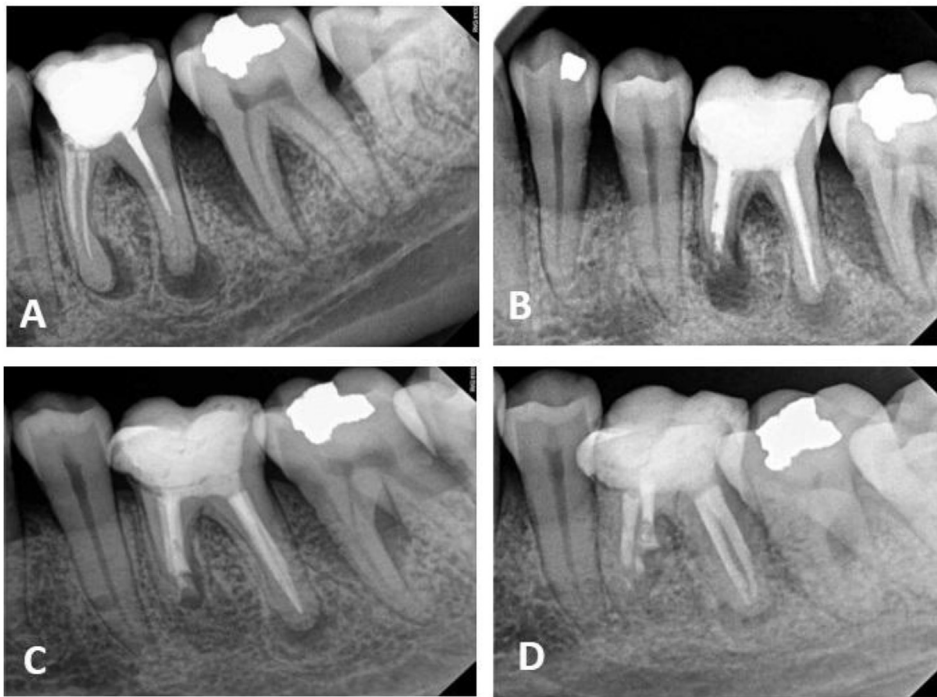#36 and 37 to palpation and percussion, normal mobility, improved periodontal and almost complete healing of the mesial root lesion and a significant reduction of the distal root lesion (Figure 3A–D). However, taking radiographic images with the same angle in a standardized method would have better confirmed the healing of periapical tissues. Nevertheless, efforts were made to take the follow-up radiograph from a similar angle to that taken at the time of the procedure.

### Discussion

Proper management of endodontic-periodontal lesions requires precise diagnosis and identification of aetiological factors. This case presented a treatment of a concomitant pulpal-periodontal lesion. This disease may progress undiagnosed, and the treatment is rendered to only one of the diseased tissues; thus, the other may respond favourably. Management of such lesions necessitates dealing with both diseases concomitantly.<sup>11</sup>

For this case, the chief complaint was pain on biting on the left area, which suggests the presence of an apical or periodontal disease. Clinical investigation revealed tenderness of tooth #36 on percussion, periodontal pockets and halitosis. The radiographic examination showed apical radiolucency of both roots of tooth #36 and vertical bone loss in that area. Considering the dental history (previous root canal treatment), the case was diagnosed as previously treated tooth (#36) with symptomatic apical periodontitis associated with generalized aggressive periodontitis.

Periapical radiographs provide limited information because the three-dimensional anatomy is represented in a two-dimensional image. In contrast, the CBCT eliminates superimposition of the surrounding structures, detects undiagnosed lesions and can differentiate between apical cysts and granuloma.<sup>12–14</sup> However, for the latter, it should be noted that recent studies showed that CBCT is not a reliable method for differentiating radicular cysts from granuloma lesions.<sup>13</sup> Nevertheless, it is well-accepted that histopathological examination of the lesion biopsy remain



**Figure 4:** Radiographic assessment of treatment outcome. (A) Pre-Operative Radiographs. (B) Post-Apical Surgery radiograph. (C) 6 months follow up radiographs. (D) 1 year follow up radiographs.

the standard procedure for differential diagnosis. Unfortunately, biopsy has not been considered for this case, which can be counted as one limitation. Additionally, CBCT enables accurate 3-D measurements.<sup>12</sup> Therefore, CBCT is an important tool in diagnosis and treatment planning.<sup>14</sup> The treatment of generalized aggressive periodontitis included several surgical and non-surgical procedures supplemented by antibiotics.<sup>8</sup>

Failed endodontic treatments can be managed by surgical or non-surgical retreatment. The most common aetiology of such cases is persistent intra-radicular infection.<sup>15</sup> This infection is usually subsequent to sub-standard root-canal-treatment without rubber-dam augmented by defective coronal restorations. Therefore, the non-surgical root canal retreatment was preferred because it enabled cleaning and disinfecting of infected root-canals. However, the transportation perforation rendered the cleaning procedures of the apical part of the mesio-lingual canal. Consequently, an apical microsurgery was performed to resect the un-negotiated part of the root-canal, which might be highly colonized by bacteria.<sup>15,16</sup> Performing the endodontic retreatment and the apical microsurgery under the high magnification of a dental operating microscope showed no signs of cracks or fractures of the offending tooth. In addition, CBCT investigation ruled out other possible aetiological factors, such as vertical root fracture.

Kim & Kratchman divided endodontic-periodontal lesions undergoing apical microsurgery into 6 categories to assess treatment modalities.<sup>17</sup> Accordingly, the severe classes (the endodontic lesion communicates with the periodontal defect) require a concurrent bone graft and membrane-barrier techniques in addition to endodontic microsurgery for a more predictable outcome. However, for lesions

without such communication, neither operating problems nor adverse effects on the treatment outcome are observed.<sup>18,19</sup> Since the mesial-root lesion was large but did not communicate with a periodontal defect, the apical microsurgery was performed without guided-tissue-regeneration procedures. The distal root was not resected because the distal canals were cleaned and shaped, then filled to the full working length, and it was adjacent to anatomical challenges (the mandibular canal). Additionally, we tried not to sacrifice additional root structure, which may enhance tooth retention. Moreover, osteotomy and resection in such cases may result in complicated communication with the periodontal defect.<sup>18,19</sup>

Observing good healing of the endodontic lesion prior to the regenerative periodontal surgery was promising; creating a favourable environment for periodontal repair by bone-grafting and membrane.<sup>20</sup> One year post-endodontic intervention (6 months after the final periodontal surgery), a healed apical lesion of the mesial-root was noticed with significant reduction of the distal-root lesion and bone formation at the periodontal bone defect. Advanced innovations, such as magnification, ultrasonics and biocompatible retrograde-filling materials (i.e., MTA), have contributed to better outcomes of endodontic microsurgery (up to 94%) compared to conventional surgery (54%).<sup>21,22</sup> The good healing in the current case may be attributed also to the combined management of endodontic retreatment and apical microsurgery.<sup>23</sup> Healing of the mesial root lesion after its apical resection was faster than that of the distal root (treated without apical surgery). This finding could be attributed to the creation of a clean wound without irritation to the alveolar bone.<sup>20</sup> Non-surgical retreatment does not include curettage of the inflamed tissues.

Subsequently, the body has to remove the tissues as part of the healing response.<sup>24</sup> This removal necessitated a longer follow up for the distal-root lesion compared to the resected mesial-root to assure a better outcome.<sup>25</sup>

### Conclusions

Eliminating possible aetiological factors and a multidisciplinary approach are essential factors for successful management of endodontic-periodontal lesions. Recent advances in endodontic armamentarium and materials offer better control and precise management of the disease.

### Authors' contribution

MAA and HYE performed the treatment and wrote the first draft of the manuscript. AS and AM finalised writing the manuscript. AS retrieved references from the literature and revised the manuscript. AM acted as a corresponding author.

### Conflict of interest

The authors have no conflict of interest to declare.

### References

- Bender IB, Seltzer S. The effect of periodontal disease on the pulp. *Oral Surg Oral Med Oral Pathol Oral Radiol Endod* 1972; 33: 458–474.
- Torabinejad M, Trope M. Endodontic and periodontal interrelationships. In: Walton RE, Torabinejad M, editors. *Principles and practice of endodontics*; 1996.
- Al-Fouzan KS. A new classification of endodontic-periodontal lesions. *Int J Dent* 2014; 919173.
- Simon JHS, Glick DH, Frank AL. The relationship of endodontic-periodontic lesions. *J Periodontol* 1972; 43: 202–208.
- Belk CE, Gutmann JL. Perspectives, controversies, and directives on pulpal-periodontal relationship. *J Can Dent Assoc* 1990; 56: 1013–1017.
- Oh SL, Fouad AF, Park SH. Treatment strategy for guided tissue regeneration in combined endodontic-periodontal lesions: case report and review. *J Endod* 2009; 35: 1331–1336.
- Sharma R, Hegde V, Siddharth M, Hegde R, Manchanda G, Agarwal P. Endodontic-periodontal microsurgery for combined endodontic-periodontal lesions: an overview. *J Conserv Dent* 2014; 17: 510–516.
- Lindhe S, Socransky S, Nyman S, Haffajee A, Westfelt E. Critical probing depths in periodontal therapy. *J Clin Periodontol* 1982; 3: 421–430.
- Tseng CC, Harn WM, Chen YH, Huang CC, Yuan K, Huang PH. A new approach to the treatment of true combined endodontic periodontic lesions by the guided tissue regeneration technique. *J Endod* 1996; 22: 693–696.
- Karabucak B, Setzer FC. Retreatment of complex periradicular lesions with periodontal involvement. *J Endod* 2009; 35: 1310–1315.
- David G, Kerns, Gerald N. Glickman: endodontic and periodontal interrelationships. In: Cohen S, Hargreaves KM, editors. *Pathways of the pulp*. 10th ed. 2009.
- Estrela C, Bueno MR, Leles CR, Azevedo B, Azevedo JR. Accuracy of cone beam computed tomography and panoramic and periapical radiography for detection of apical periodontitis. *J Endod* 2008; 34: 273–279.
- Rosenberg PA, Frisbie J, Lee J, Lee K, Frommer H, Kottal S, Phelan J, Lin L, Fisch G. Evaluation of pathologists (histopathology) and radiologists (cone beam computed tomography) differentiating radicular cysts from granulomas. *J Endod* 2010; 36: 423–428.
- Cotton TP, Geisler TM, Holden DT, Schwartz SA, Schindler WG. Endodontic applications of cone-beam volumetric tomography. *J Endod* 2007; 33: 1121–1132.
- Nair PN, Henry S, Cano V, Vera J. Microbial status of apical root canal system of human mandibular first molars with primary apical periodontitis after “one-visit” endodontic treatment. *Oral Surg Oral Med Oral Pathol Oral Radiol Endod* 2005; 99: 231–252.
- Kim S, Pecora G, Rubinstein R. Comparison of traditional and microsurgery in endodontics. In: Kim S, Pecora G, Rubinstein R, editors. *Color atlas of microsurgery in endodontics*. Philadelphia: W.B. Saunders; 2001.
- Kim S, Kratchman S. Modern endodontic surgery concepts and practice: a review. *J Endod* 2006; 32: 601–623.
- Kim E, Song J, Jung I, Lee S, Kim S. Prospective clinical study evaluating endodontic microsurgery outcomes for cases with lesions of endodontic origin compared with cases with lesions of combined periodontal-endodontic origin. *J Endod* 2008; 34: 546–551.
- Song M, Shin SJ, Kim E. Outcome of endodontic microsurgery: a prospective clinical study. *J Endod* 2011; 37: 316–320.
- Abbott PV, Salgado JC. Strategies for the endodontic management of concurrent endodontic and periodontal diseases. *Aust Dent J* 2009; 54(Suppl. 1): S70–S85.
- Setzer FC, Shah SB, Kohli MR, Karabucak B, Kim S. Outcome of endodontic surgery: a meta-analysis of the literature part I: comparison of traditional root-end surgery and endodontic microsurgery. *J Endod* 2010; 36: 1757–1765.
- Tsesis I, Rosen E, Taschieri S, Telishevsky Strauss Y, Ceresoli V, Del Fabbro M. Outcomes of surgical endodontic treatment performed by a modern technique: an updated meta-analysis of the literature. *J Endod* 2013; 39: 332–339.
- Grung B, Molven O, Halse A. Periapical surgery in a Norwegian county hospital: follow-up findings of 477 teeth. *J Endod* 1990; 16: 411–417.
- Kvist T, Reit C. Results of endodontic retreatment: a randomized clinical study comparing surgical and nonsurgical procedures. *J Endod* 1999; 25: 814–817.
- Torabinejad M, Corr R, Handysides R, Shabahang S. Outcomes of nonsurgical retreatment and endodontic surgery: a systematic review. *J Endod* 2000; 35: 930–937.

**How to cite this article:** Al Attas MA, Edrees HY, Sammani AMN, Madarati AA. Multidisciplinary management of concomitant pulpal and periodontal lesion: A case report. *J Taibah Univ Med Sc* 2017;12(5):455–460.