

RESEARCH

Missed clinical clues in patients with pheochromocytoma/paraganglioma discovered by imaging

Natalie Rogowski-Lehmann¹, Aikaterini Geroula², Aleksander Prejbisz³, Henri J L M Timmers⁴, Felix Megerle⁵, Mercedes Robledo⁶, Martin Fassnacht⁵, Stephanie M J Fliedner⁷, Martin Reincke¹, Anthony Stell⁸, Andrzej Januszewicz³, Jacques W M Lenders^{4,9}, Graeme Eisenhofer^{2,9} and Felix Beuschlein^{1,10}

¹Medizinische Klinik und Poliklinik IV, Klinikum der Universität München, Munich, Germany

²Institut für Klinische Chemie und Laboratoriumsmedizin, Universitätsklinikum Carl Gustav Carus an der TU Dresden, Dresden, Germany

³Department of Hypertension, Institute of Cardiology, Warsaw, Poland

⁴Section of Endocrinology, Department of Internal Medicine, Radboud University Medical Centre, Nijmegen, The Netherlands

⁵Medizinische Klinik und Poliklinik I des Universitätsklinikums Würzburg, Würzburg, Germany

⁶Hereditary Endocrine Cancer Group, Human Cancer Genetics Programme, Spanish National Cancer Research Centre, Centro de Investigacion Biomedica en Red de Enfermedades Raras (CIBERER), Madrid, Spain

⁷First Department of Medicine, University Medical Center Schleswig-Holstein, Lübeck, Germany

⁸Department of Computing and Information, University of Melbourne, Melbourne Australia

⁹Medizinische Klinik III, Universitätsklinikum Carl Gustav Carus an der Technische Universität Dresden, Dresden, Germany

¹⁰Klinik für Endokrinologie, Diabetologie und Klinische Ernährung, Universitätsspital Zürich, Zürich, Switzerland

Correspondence should be addressed to F Beuschlein: felix.beuschlein@usz.ch

Abstract

Background: Pheochromocytomas and paragangliomas (PPGLs) are rare but potentially harmful tumors that can vary in their clinical presentation. Tumors may be found due to signs and symptoms, as part of a hereditary syndrome or following an imaging procedure.

Objective: To investigate potential differences in clinical presentation between PPGLs discovered by imaging (iPPGLs), symptomatic cases (sPPGLs) and those diagnosed during follow-up because of earlier disease/known hereditary mutations (fPPGL).

Design: Prospective study protocol, which has enrolled patients from six European centers with confirmed PPGLs. Data were analyzed from 235 patients (37 iPPGLs, 36 sPPGLs, 27% fPPGLs) and compared for tumor volume, biochemical profile, mutation status, presence of metastases and self-reported symptoms. iPPGL patients were diagnosed at a significantly higher age than fPPGLs ($P < 0.001$), found to have larger tumors ($P = 0.003$) and higher metanephrine and normetanephrine levels at diagnosis ($P = 0.021$). Significantly lower than in sPPGL, there was a relevant number of self-reported symptoms in iPPGL (2.9 vs 4.3 symptoms, $P < 0.001$). In 16.2% of iPPGL, mutations in susceptibility genes were detected, although this proportion was lower than that in fPPGL (60.9%) and sPPGL (21.5%). Patients with PPGLs detected by imaging were older, have higher tumor volume and more excessive hormonal secretion in comparison to those found as part of a surveillance program. Presence of typical symptoms indicates that in a relevant proportion of those patients, the PPGL diagnosis had been delayed.

Précis: Pheochromocytoma/paraganglioma discovered by imaging are often symptomatic and carry a significant proportion of germline mutations in susceptibility genes.

Key Words

- ▶ pheochromocytoma
- ▶ paraganglioma
- ▶ imaging
- ▶ signs and symptoms
- ▶ prospective

Endocrine Connections
(2018) 7, 1168–1177

Introduction

Pheochromocytomas and paragangliomas (PPGLs) are neuroendocrine tumors that derive from adrenomedullary tissue (pheochromocytomas) in about 85% of cases and from extra-adrenal chromaffin tissue (paragangliomas) in the remainder (1). PPGLs are overall rare and occur with a frequency of up to 1:500 in patients with arterial hypertension and up to 1:1000 in unselected post mortem studies (2). PPGLs have the capacity to secrete catecholamines, which results in elevation of blood pressure. Thereby, the disease represents a surgically correctable form of hypertension. As a consequence of the unpredictable hormone secretion, the tumors are potentially very harmful if not quickly diagnosed and treated. In fact, retrospective analyses indicate that life-threatening events with cardiovascular complications including hypertensive crisis and catecholamine-induced cardiomyopathy are not uncommon even as first presentation of disease (3, 4). The symptoms that occur in patients with PPGLs are caused by the excessive production of catecholamines and include headache, palpitations and sweating together with intermittently or persistently elevated blood pressure (5).

While the presence of typical signs and symptoms has some predictive value for the diagnosis of catecholamine excess, clinical presentation can vary widely with silent courses over a long period of time; at least 10–15% of cases can be completely asymptomatic and among patients screened due to germline mutations or because of imaging up to 50% or more can be normotensive and asymptomatic (6). With the increasing number of high-resolution imaging procedures, a considerable proportion of PPGLs are now being discovered incidentally (7). As around 3–7% of incidentally discovered adrenal masses are finally diagnosed as pheochromocytoma (8, 9), current guidelines recommend exclusion of catecholamine excess in all patients with adrenal incidentalomas (2).

Over one-third of all patients with PPGLs are affected by germline mutations of tumor-susceptibility genes that considerably increase the risk to develop additional PPGLs at new sites and other syndrome-related neoplasms (2, 10). To date, at least 16 genes have been identified to be responsible for hereditary PPGLs (11) and exome sequencing approaches have defined the occurrence of somatic mutations in candidate genes that partly overlap with those found as germline variants. These advances in genetic and molecular diagnostics can assist in identifying at-risk patients and family members who might benefit from routine surveillance for associated syndromic

features. Nevertheless, even for patients without these mutations, there is risk of recurrent disease that can result in cardiovascular complications or can evolve into metastatic progression (12).

Fortunately, once suspected, appropriate biochemical testing now makes it unlikely that the presence of a catecholamine-producing tumor will be missed. In particular, recognition that the O-methylated metabolites of catecholamines – the metanephrines – are produced continuously within chromaffin tumor cells with outward diffusion independently of variations in exocytosis, has led to promulgation of these analytes as superior for diagnosis of PPGLs compared to other analytes (13, 14). Consequently, Endocrine Society clinical practice guidelines now mandate with a strong level of evidence measurements of plasma free or urine fractionated metanephrines as first-line tests for diagnosis of the tumors (2). Based on these recommendations and the pathophysiological background of the disease, the indication to screen for PPGLs includes presence of typical signs and symptoms of catecholamine excess, incidental findings of suspicious adrenal or extra-adrenal lesions based on imaging, follow-up of an earlier history of PPGL or of carriers of a susceptibility gene.

Follow-up with routine periodic biochemical screening for PPGLs in patients at risk for the tumors has been consistently advocated by experts in the field (2, 15). The advances in imaging techniques, the much-improved insights into the pathophysiology and genetics of the disease and the high sensitivity of modern hormone screening approaches have considerably changed the composition of PPGL patients in clinical practice. Indeed, over the years, the proportion of patients has shifted from symptomatic cases to those that are incidentally detected or undergo routine surveillance. Despite these well-appreciated changes, there were no prospective studies to compare PPGLs diagnosed by imaging or by the presence of typical symptoms. To fill these gaps, we have used the Prospective Monoamine-producing Tumor study (PMT study) that has included a large number of patients with suspected PPGL for clinical and biochemical evaluation (16, 17, 18, 19, 20).

Materials and methods

Patients

Patients were recruited from a total of 2056 subjects screened for PPGLs in a prospective multicenter study

(Prospective Monoamine-producing Tumor study) since 2010 according to a protocol and standard-operating procedures available online (<https://pmt-study.pressor.org>). Out of the 2056 screened subjects, a total of 236 patients (11.5%) were diagnosed with an abdominal and/or thoracic PPGL. One patient was excluded from the current analysis because of insufficient data. Patients were enrolled at six tertiary medical centers (University Hospital Carl Gustav Carus Dresden; University Medical Centre Schleswig-Holstein Lübeck; University Hospital of Munich; and University Hospital of Würzburg, all in Germany; Radboud University Medical Centre, Nijmegen, the Netherlands and the Institute of Cardiology, Warsaw, Poland) usually upon referral from primary and secondary care centers and according to several criteria establishing suspicion or risk for PPGLs: (1) signs and symptoms of catecholamine excess; (2) incidental finding by imaging; (3) known hereditary risk and (4) previous history of PPGL. The study protocol was approved by the local ethic committees of all participating centers (e.g. 'Ethikkommission an der Technischen Universität Dresden', 'Ethikkommission bei der Medizinischen Fakultät der LMU München', 'Ethikkommission bei der Medizinischen Fakultät der Universität Würzburg', 'Ethikkommission der Universität zu Lübeck') and all subjects provided written informed consent prior study inclusion. Enrolled subjects underwent biochemical and imaging testing as defined in the study protocol (21) and in accordance to more recently published international guidelines (2).

While biochemical testing was done in a centralized lab in Dresden, Germany (21), imaging was performed at the discretion of the individual centers, which was reported to involve CTs ($n=75$), MRI ($n=27$) and functional imaging ($n=65$) based on the indication and availability of the technique.

Patients with PPGLs confined to the head and neck were excluded. Patients with confirmed abdominal and/or thoracic PPGL were categorized according to the documented reason for screening: PPGLs discovered by imaging (iPPGLs) and symptomatic cases (sPPGLs) and those diagnosed as part of regularly scheduled follow-up because of earlier history of PPGL or known hereditary mutation (fPPGLs). Detection by imaging was defined when imaging had been performed for unrelated conditions without the intention to diagnose a PPGL. Basic clinical data were collected and spherical tumor volumes were calculated. All three diameters in tumor volumes were recorded in 167/235 (=71.1%), two diameters in 22/235 (=9.4%) and only one diameter in

28/235 (=11.9%) patients. Eighteen patients (7.7%) with extensive metastatic disease were excluded from the analysis of tumor volume. Spherical tumor volume was calculated as a volume of an ellipsoid ($V=4/3\pi abc$ with a , b , and c as the provided diameters in three dimensions). If only two or one diameter were reported, the volume was calculated as a spheroid ($V=4/3\pi a^2b$) or a sphere ($V=4/3\pi a^3$), respectively. In case of metastatic disease, tumor volumes based on CT/MRI were summed, with the exception of cases with extensive metastatic spread. Only at the time of study enrollment, patients underwent a questionnaire as part of the study protocol that documented the history of a total of 12 symptoms over the last 30 days prior to enrollment with potential association to catecholamine excess. Documentation of these symptoms (headache, sweateness, palpitations, pallor, flush, panic, constipation, nausea, chest pain, abdominal pain, tremor and weakness) were available from 217 out of 235 PPGL patients (92.3%). The number of symptoms present were added up to categorize patients into oligo symptomatic ((0–3)/12 symptoms), symptomatic ((4–6)/12 symptoms) and highly symptomatic ((7–12)/12 symptoms) groups.

Statistical analysis

The three groups of iPPGLs, sPPGLs and the fPPGLs were compared for clinical and biochemical characteristics including age of onset, gender, tumor size and plasma metanephrine levels. To compare the different groups, the Mann–Whitney U test and ANOVA were used and chi quadrat test for correlation between size and biochemical profile. Statistical significance was determined as a P value below 0.05 using the SPSS Software, version 24 (SPSS, Inc.). If not stated otherwise, $P<0.05$ were denoted with one star (*) and $P<0.001$ with two stars (**), respectively.

Results

Description and distribution of PPGL patient cohort

Out of the 2056 enrolled patients a total of 236 patients (11.5%) were diagnosed with an abdominal and/or thoracic PPGL. One patient was excluded because of insufficient data. The remaining 235 patients with confirmed disease had a median age of 49 years (range: 11–82) at diagnosis, with 57% being females and 43% males. The distribution for the reason to enroll the patients into the study protocol were 86 due to tumors discovered by imaging

(iPPGLs, 36.6%), 85 due to signs and symptoms indicative of catecholamine excess (sPPGLs, 36.2%) and 64 screened as part of a regular surveillance because of previous disease or known susceptibility gene carrier status (fPPGLs, 27.2%, Table 1). From the total PMT study population ($n=2056$), inclusion criteria were available in 2055 patients. From those, 468 (22.8%) were included on the basis of a finding by imaging, and 86 (18.4%) of these patients were found to have a PPGL.

Clinical and genetic characteristics of PPGL patients detected by imaging

Age at diagnosis was significantly higher in the patients detected by imaging (range 17.3–82.3, median 54.7 years) in comparison to fPPGL patients (range 11.1–70.2, median 39.0 years, $P<0.001$) and also in sPPGL patients (range

11–79, median 49.6 years, $P=0.015$) (Fig. 1A). Overall, sex distribution was not different among the groups.

Tumor volume (median, range) in iPPGL patients was 35.9 mL (0.9–904.3 mL), which was significantly larger in comparison to the fPPGL group (12.1 mL, 0.3–296.7 mL; $P=0.003$, Fig. 1B) but not in comparison to those enrolled for symptoms (sPPGL, 34.2 mL, 2.2–2242 mL; $P=0.78$). In 91.9% of iPPGL patients, the tumor was localized in one adrenal gland, while 8.1% were detected as an extra-adrenal tumor. From the seven extra-adrenal tumors in the iPPGL group, six were abdominal PPGLs and one was a patient with hepatic metastases. In contrast, 26.6% of the fPPGL group was diagnosed with an extra-adrenal localization at first presentation.

Within the iPPGL group, five patients (5.8%) were diagnosed with metastatic disease at study entry (clinical context is provided in Table 2) and a similar proportion

Table 1 General clinical and genetic characteristics of PPGL patients from the different screening groups.

	iPPGL	sPPGL	fPPGL	P value
Number of patients	86	85	64	
Age at diagnosis (median, years)	54.7 (17.3–82.3)	49.6 (11.0–79.0)	39.0 (11.1–70.2)	iPPGL vs fPPGL <0.001 sPPGL vs fPPGL <0.001 iPPGL vs sPPGL 0.015
Females, n (%)	51 (59.3)	50 (58.8)	34 (53.1)	iPPGL vs fPPGL 0.45 sPPGL vs fPPGL 0.49 iPPGL vs sPPGL 0.95
Hypertension present, n (%)	54/81 (66.7)	74/80 (92.5)	35/58 (61.4)	iPPGL vs fPPGL 0.45
Persistent, n (%)	37/81 (45.7)	30/80 (37.5)	25/58 (43.9)	sPPGL vs fPPGL <0.001
Paroxysmal, n (%)	5/81 (6.2)	5/80 (6.3)	0/58 (0)	iPPGL vs sPPGL <0.001
Both, n (%)	12/81 (14.8)	39/80 (48.2)	10/58 (17.5)	
BMI (kg/m ²)	23.9 (17.2–41.1)	24.8 (17.4–34.3)	23.4 (16.2–37.8)	iPPGL vs fPPGL 0.74 sPPGL vs fPPGL 0.19 iPPGL vs sPPGL 0.28
Mutations in susceptibility genes, n (%)	12/74 (16.2)	17/79 (21.5)	39/64 (60.9)	iPPGL vs fPPGL <0.001 sPPGL vs fPPGL <0.001 iPPGL vs sPPGL 0.41
SDHA, n (%)	0/74 (0)	0/79 (0)	0/63 (0)	
SDHB, n (%)	2/74 (2.7)	5/79 (6.3)	10/63 (15.9)	
SDHC, n (%)	1/74 (1.4)	0/79 (0)	0/63 (0)	
SDHD, n (%)	1/74 (1.4)	1/79 (1.3)	11/63 (17.5)	
VHL, n (%)	2/74 (2.7)	3/79 (3.8)	6/63 (9.5)	
RET, n (%)	1/74 (1.4)	5/79 (6.3)	8/64 (12.75)	
NF1, n (%)	5/74 (6.8)	3/79 (3.8)	3/64 (4.7)	
MAX, n (%)	0/74 (0)	0/79 (0)	1/64 (1.6)	
HRAS, n (%)	0/74 (0)	0/79 (0)	0/64 (0)	
EPAS 1, n (%)	0/74 (0)	0/79 (0)	1/64 (1.6)	
Malignancy at presentation, n (%)	5/84 (6.0)	5/85 (5.9)	26/65 (40.0)	iPPGL vs fPPGL <0.001 sPPGL vs fPPGL <0.001 iPPGL vs sPPGL 1.0
PPGL location	77/84 (91.7)	76/85 (89.4)	38/64 (59.4)	iPPGL vs fPPGL <0.001
Adrenal, n (%)	7/84 (8.3)	7/85 (8.2)	17/64 (26.6)	sPPGL vs fPPGL <0.001
Extra-adrenal, n (%)	0/84 (0)	2/85 (2.4)	9/64 (14.1)	iPPGL vs sPPGL 0.57
Multifocal, n (%)				

Data are expressed as mean if not stated otherwise with range in parenthesis or frequencies.
 BMI, body mass index.

was found in symptomatic patients (5.9%), while 25 out of the 64 (39.1%) fPPGL patients were found to have metastatic disease.

Germline mutations in susceptibility genes were present in the majority of the patients of the fPPGL group (60.9%). In comparison to the fPPGL group, although at an overall lower proportion, a relevant number of patients also in the iPPGL group (16.2%; $P < 0.001$, clinical details are provided in Table 2) and in the symptomatic group (21.5%, $P < 0.001$) were found to have mutations in susceptibility genes.

The prospective evaluation of family history in the imaging group revealed no family history in 77/86 (89.5%) while in the remaining 9 (10.5%) some evidence of genetic disease was apparent (six patients with syndromic clinical features and three patients with first

or second-degree relatives with PPGLs). In none of these cases, imaging was performed for those specific reasons (for details see Table 2). All five of the *NF1* patients had syndromic clinical features and one of the patients with *SDHB* mutation had a history of clear cell renal carcinoma so first suspicion had been a *VHL* mutation. In the majority of cases, genetic testing was done only after enrollment in the study protocol.

Catecholamine biochemical profile in imaging-based PPGL patients

For plasma metanephrine levels (median, range), no significant difference was detectable between iPPGL (150, 7.0–3089 pg/mL) and sPPGL patients (259, 7–3000 pg/mL, $P = 0.12$), while they were significantly lower in the fPPGL group (38, 5–6888 pg/mL, $P < 0.001$, Fig. 2A). Plasma normetanephrine levels were also found to be significantly different between iPPGL (636, 45–25,444 pg/mL) and fPPGL patients (393, 48–23,333 pg/mL, $P = 0.022$). No difference in plasma normetanephrine levels was detected between the iPPGL and the sPPGL patients (1045.5, 55–6340 pg/mL, $P = 0.27$, Fig. 2B). Regarding plasma methoxytyramine levels, no significant difference was evident between the three groups (median 13.75 pg/mL in iPPGL, 17.0 pg/mL in sPPGL ($P = 0.26$) and 12.5 pg/mL in fPPGL ($P = 0.97$), Fig. 2C).

Signs and symptoms in patients with PPGLs detected by imaging

The proportion of patients with hypertension was higher in the symptomatic group (92.5%) in comparison to the iPPGL (66.7% $P < 0.001$) and fPPGL (61.4%, $P < 0.001$), while the rate of persistent and paroxysmal hypertension was similar among the groups.

Overall, the number of self-reported symptoms was significantly lower in iPPGL patients (2.90, 0–11) in comparison to sPPGL patients (4.34, 0–10, $P < 0.001$), while it was similar in comparison to fPPGL patients (2.32, 0–10, $P = 0.366$). Accordingly, in the sPPGL group, the proportion of patients was shifted toward the more symptomatic categories (oligosymptomatic 36.8%, symptomatic 39.5% and highly symptomatic 23.7%) in comparison to the iPPGL group (oligosymptomatic 65.4%, symptomatic 23.5% and highly symptomatic 11.1%, Fig. 3A).

Among these symptom-based categories, lowest plasma normetanephrine levels were observed in

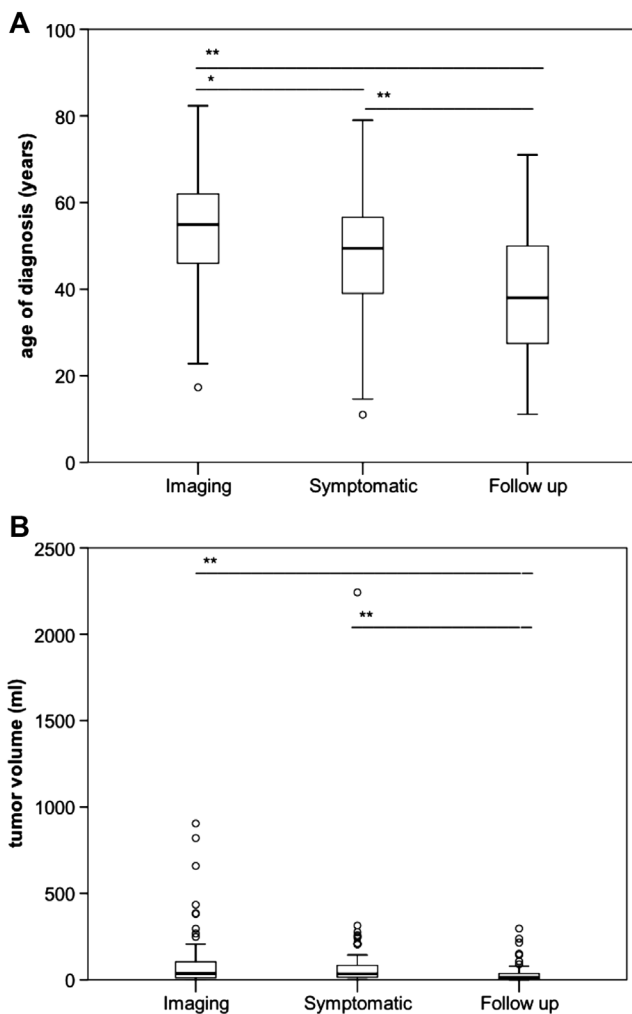


Figure 1 Age of diagnosis (A) and tumor volume (B) in the different PPGL patient groups.

Table 2 Overview on patients with PPGL diagnosed by imaging and concomitant syndromic presentation, positive family history or metastatic disease.

#	Clinical context	Reason for inclusion as putatively incidental
1	Family history or syndromic presentation	First-degree relative with PPGL, hospitalization for uncontrolled diabetes mellitus type 2 (HbA1c 10%); routine abdominal ultrasound followed by CT scan revealed pheochromocytoma
2	Family history or syndromic presentation	Hospitalization for insufficiently controlled diabetes mellitus type 2. Indication for abdominal sonography because of weight loss of 7 kg. Thereby, incidental finding of an adrenal mass of 6 cm. Following study entry, family history reveals one daughter and one granddaughter 'with a benign adrenal tumor'
3	Family history or syndromic presentation	Positive family history was only revealed after surgery and genetic diagnosis (of a <i>SDHD</i> mutation) as the patient had no contact to other family members
4	Family history or syndromic presentation	Neurofibromatosis was first diagnosed in 1998; arterial hypertension was first described in 2004. Right sided adrenal PPGL was detected incidentally in 2012 through imaging for abdominal pain
5	Family history or syndromic presentation	Patient was referred to a nephrologist due to elevated creatinine levels in 10/2013, which led to sonographic detection of a clear cell carcinoma of the right kidney. During a follow-up in 08/2015, an adrenal mass on the right side was detected by ultrasound. Patient came to the outpatient clinic with suspicion of an adrenocortical adenoma
6	Family history or syndromic presentation	Discovery of an adrenal tumor after abdominal imaging for unrelated reason; <i>VHL</i> was diagnosed clinically and genetically only after patient had undergone surgery
7	Family history or syndromic presentation	Patient had known <i>NF1</i> first diagnosed in 1964. Arterial hypertension had been first diagnosed in 1996. In 2015, the patient was seen by her general practitioner for 'kidney pain', which revealed a mass in the right retroperitoneal space. The patient was free of typical symptoms other than arterial hypertension, which had been known for many years
8	Family history or syndromic presentation	Abdominal ultrasound, which revealed bilateral adrenal tumors was performed due to abdominal pain. Only further clinical evaluation (with detection of neurofibroma) in the study center made the connection with the presence of neurofibromatosis
9	Family history or syndromic presentation	Diagnostic imaging performed for unexplained weight loss and increasingly difficult to maintain blood glucose levels with known diabetes type 1 revealed a tumor in left adrenal. Genetic testing was performed following surgery of the pheochromocytoma, which found a mutation for <i>SDHC</i>
10	Metastatic disease	Prolonged respiratory infection with weight loss of 7 kg, abdominal CT scan revealed mediastinal lymph nodes, CT guided fine needle biopsy resulted in the diagnosis of paraganglioma which was found to be metastasized in the liver and the bone
11	Metastatic disease	Patient was referred as an inpatient in sepsis which led to the diagnosis of endocarditis and further imaging revealed metastasized PGL
12	Metastatic disease	Urinary retention led to the diagnosis of an adrenal tumor (with the initial suspicion of adrenocortical carcinoma) with the final diagnosis of metastatic PGL
13	Metastatic disease	Abdominal CT scan was performed due to unspecific abdominal pain, which revealed a pheochromocytoma. Metastases were detected only 6 months after primary surgery
14	Metastatic disease	Patient was referred because his primary care physician had made an abdominal ultrasound because of a suspected kidney stone. Unexpectedly, a large adrenal mass on the right side was found. Retrospectively, the patient for many years had signs of excessive sweating and hypertension but these issues became apparent only when referred to the study center, where metastatic disease was diagnosed

oligosymptomatic patients (median 520, 48–25,444 pg/mL), but significantly higher levels were found in symptomatic (832, 70–7175 pg/mL, $P=0.009$), and highly symptomatic patients (1410, 45–23,333 pg/mL, $P=0.018$, Fig. 3C). A significant difference was also evident in plasma metanephrine levels between the oligosymptomatic (82, 7–3089 pg/mL), symptomatic (172.5, $P<0.001$) and highly symptomatic groups (268, 10–6888 pg/mL, $P<0.001$). No such difference was present for methoxytyramine levels.

Discussion

Herein, we have made use of a multicenter prospective clinical protocol that was set up to include patients at-risk for PPGLs. Based on these data, we demonstrate that patients with PPGLs detected by imaging have significant larger tumor volumes, are older and have higher metanephrine and normetanephrine levels in comparison to those of the regular surveillance group. Both improved sensitivity and overall increasing use

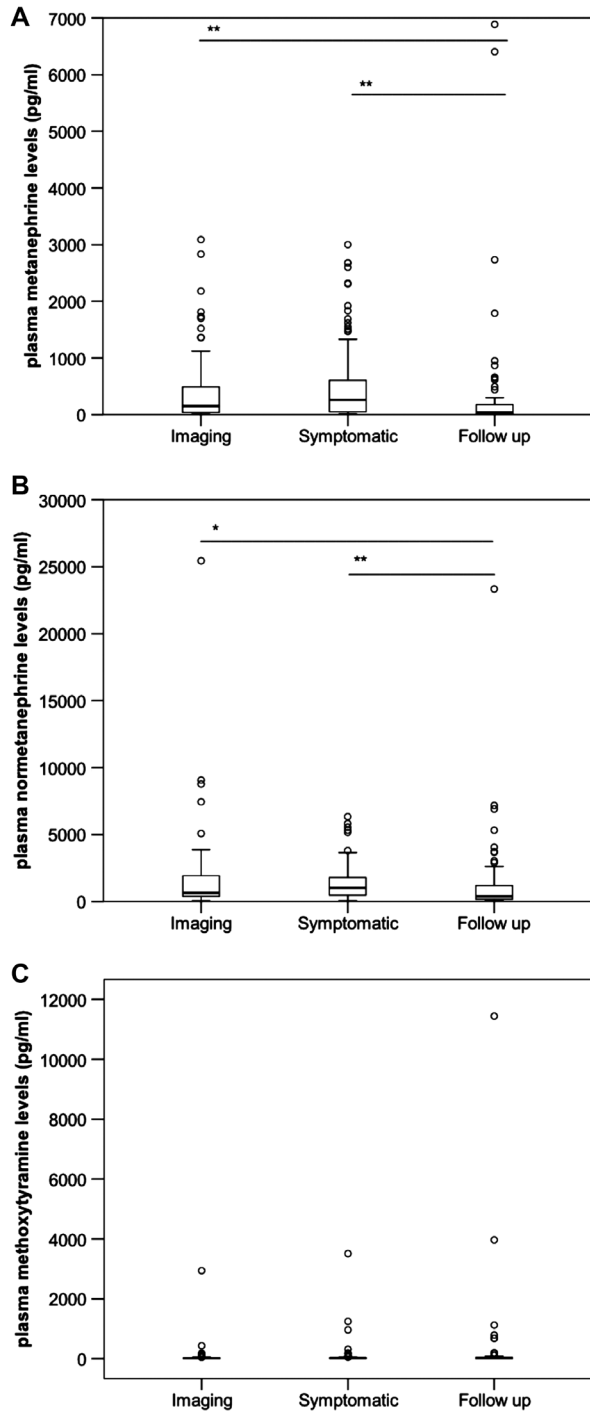


Figure 2 Plasma metanephrine (A), normetanephrine (B) and methoxytyramine levels (C) at time of study inclusion in the different PPGL groups.

of imaging procedures has contributed to the rise of incidentally detected lesions within the adrenal gland and elsewhere. The surprising and unexpected finding of this study is that a substantial proportion of patients in whom a PPGL was discovered by imaging for any other

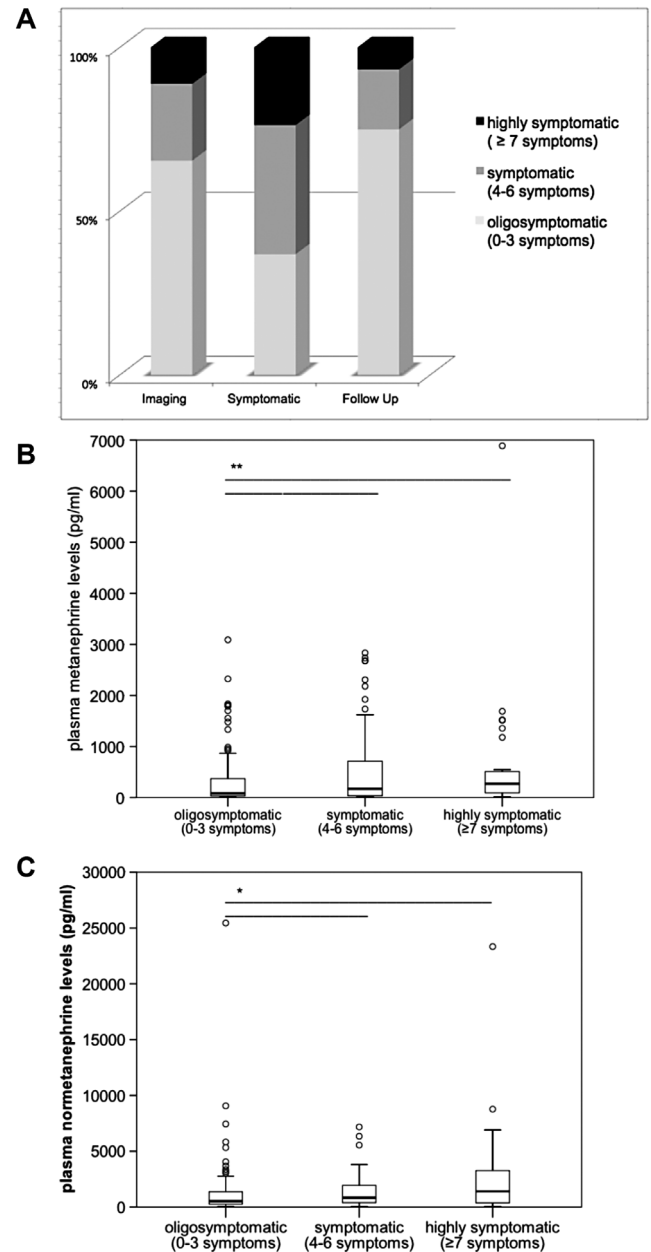


Figure 3 Distribution of symptomatic patients (highly symptomatic, symptomatic, oligo symptomatic) among the different PPGL groups (A) and median plasma metanephrine (B) and normetanephrine levels (C) in relation to the symptom score.

reason appeared to have clear clues of a PPGL (signs and symptoms or genetic cause) that should have prompted the search for a PPGL at an earlier stage. Furthermore, patients of the imaging group carried a relevant burden of comorbidities with a potential connection to their PPGL diagnosis – seven patients of the iPPGL group (8.1%) had major cardiovascular events.

The finding of higher age at presentation in patients with PPGLs detected by imaging is in line with retrospective data from the literature (7). As patients at higher age have a higher probability to be subjected to imaging techniques at older ages, the risk of detecting an incidental adrenal lesion also increases with age. This might have induced a selection bias toward a higher age in the PPGLs detected by imaging in the presented cohort. Of note, in direct comparison to symptomatic patients, the differences compared to those discovered by imaging were not striking. Similarly, there was no relevant difference between symptomatic and imaging-based patients in the localization of the tumors or proportion of apparent malignant disease at the time of first diagnosis. On the basis of these parameters, it appears that detection of a PPGL by imaging or based on typical clinical symptoms does not result in patient populations with clearly distinct characteristics that relate to age distribution or imaging results.

In the current study, overall around 12% of PPGLs detected by imaging were associated with highly suggestive symptoms; in addition, some patients had syndromic clinical features and some a positive family history (examples are provided in Table 2). Therefore, careful clinical examination and acquisition of medical histories might well have led to earlier diagnosis in a subset of patients in whom diagnosis was based on imaging findings. While the increase in imaging procedures and the high proportion of PPGLs based on imaging might be coincidental, it is intriguing to speculate that our findings might reflect a shift from symptom- and clinical oriented to imaging-based diagnostic procedures. The considerable rate of familial cases among those PPGLs discovered by imaging further suggests that in some instances regular follow-up and/or genetic counseling had not been appropriately followed.

As to be expected from the inclusion criteria, patients from the symptomatic group had an increased likelihood of a high symptom score, which was paralleled by higher levels of plasma metanephrines and normetanephrines. Of note, within the imaging group, 21.5% of patients presented with paroxysmal hypertension either isolated or in combination with persistent hypertension. Similarly, within the last month prior study enrollment, a relevant number of these patients reported on at least four of the pre-defined symptoms that had been associated with catecholamine excess (headache, sweatiness, palpitations, pallor, flush, panic, constipation, nausea, chest pain, abdominal pain, tremor and weakness). In a recent meta-analysis on the – often retrospective – literature of

PPGL-related signs and symptoms, no single clinical feature could be identified with a particular value in diagnosing or excluding PPGLs (22). However, while prospective studies involving comparisons to patients in whom PPGL had been excluded will be required, it seems prudent that a high symptomatic burden should raise clinical suspicion for the presence of catecholamine excess. Obviously, this information has to be gathered by clinical examination and by taking a detailed patient history.

Given the strong genetic contributions for the development of PPGLs and the lack of a reliable marker for the distinction between benign and malignant disease, follow-up with routine periodic biochemical screening for PPGLs in patients at risk has been consistently advocated by experts (2, 15). However, there remains a wide gap between what is recommended and what is followed in routine clinical practice. Specifically, patients with *NF1* mutations were recommended until very recently, to undergo screening for PPGLs only when additional symptoms raised the suspicion of catecholamine excess. A recent study by Moramarco and colleagues reported on a relevant proportion of PPGL cases detected incidentally in patients with *NF1* (23). These findings, which are inline with our own and other recent findings support need for change to recommendations for *NF1* patients such that all should receive some form of periodic surveillance for PPGLs irrespective of other clinical clues.

As indicated in two recent reports (12, 15), this gap reflects the inconsistent and relative lack of data concerning risk of recurrent or new disease and the associated paucity of evidence for any improved clinical outcome that might be achieved by routine follow-up. The data presented herein provide indirect evidence for the effectiveness of screening procedures in the context of a known hereditary risk for the development of PPGLs: patients who underwent diagnosis in the follow-up group had significantly lower levels of plasma catecholamine metabolites with lower burden of clinical symptoms.

Within the surveillance group, the prevalence of malignancy was the highest, which likely reflects the large proportion of patients with *SDHB* mutations. However, also in the imaging group a considerably high rate of susceptibility gene mutations were evident. While no past or family history in the majority of these patients had been indicative for a hereditary cause, almost one quarter were found to be gene carriers. As these findings clearly impact on the follow-up of the index patient and on genetic risk of first-grade family members, also PPGL patients detected on the basis of imaging should be offered genetic counseling on a regular basis.

The strength of the current study is the substantial sample size of PPGL patients that have prospectively undergone follow-up. We acknowledge the imperfect data coverage, differences in imaging protocols among centers and yet limited duration of the observation period. Despite these limitations, we demonstrate that also patients with PPGLs discovered by imaging carry a considerable morbidity risk that should be matched by appropriate and specialized medical care. Notably, in a subgroup of patients despite their apparently incidental diagnosis medical and family history and careful clinical examination would already have provided good reasons for biochemical screening independent of imaging studies.

While we can only speculate on the individual reasons for missed or delayed diagnosis, we believe that the most important measures to improve current shortcomings in early detection of PPGL patients comprises continuous medical education of general physicians and medical disciplines (e.g. general internal medicine, cardiology, nephrology) who have a likelihood to encounter a PPGL patient. Secondly, active invitation of patients with a PPGL history or hereditary background into specific surveillance programs could likely increase adherence to follow-up studies. Finally, privacy law regulations in place in some European countries have to be balanced against the risk to lose access to information that is relevant for clinical decision making.

Declaration of interest

The authors declare that Felix Beuschlein is member of the editorial board of Endocrine Connections, and all other authors have nothing to disclose.

Funding

The research leading to these results has received funding from the following sources: The Seventh Framework Programme (FP7/2007–2013) under grant agreement n° 259735 awarded to F B, H T and G E. The study has further been supported by the Deutsche Forschungsgemeinschaft (DFG) within the CRC/Transregio 205/1 'The Adrenal: Central Relay in Health and Disease' to M F, M R, J L, G E, and F B.

Acknowledgements

The authors are grateful to all patients who participated in this research and to Christina Brugger, Katharina Langton and Denise Kaden for excellent technical assistance.

References

- Lenders JW, Eisenhofer G, Mannelli M & Pacak K. Pheochromocytoma. *Lancet* 2005 **366** 665–675. ([https://doi.org/10.1016/S0140-6736\(05\)67139-5](https://doi.org/10.1016/S0140-6736(05)67139-5))
- Lenders JW, Duh QY, Eisenhofer G, Gimenez-Roqueplo AP, Grebe SK, Murad MH, Naruse M, Pacak K, Young WF Jr & Endocrine Study. Pheochromocytoma and paraganglioma: an endocrine society clinical practice guideline. *Journal of Clinical Endocrinology and Metabolism* 2014 **99** 1915–1942. (<https://doi.org/10.1210/jc.2014-1498>)
- Riester A, Weismann D, Quinkler M, Lichtenauer UD, Sommerey S, Halbritter R, Penning R, Spitzweg C, Schopohl J, Beuschlein F, *et al.* Life-threatening events in patients with pheochromocytoma. *European Journal of Endocrinology/European Federation of Endocrine Societies* 2015 **173** 757–764. (<https://doi.org/10.1530/EJE-15-0483>)
- Giavarini A, Chedid A, Bobrie G, Plouin PF, Hagege A & Amar L. Acute catecholamine cardiomyopathy in patients with pheochromocytoma or functional paraganglioma. *Heart* 2013 **99** 1438–1444. (<https://doi.org/10.1136/heartjnl-2013-304073>)
- Gunawardane PT & Grossman A. Pheochromocytoma and paraganglioma. *Advances in Experimental Medicine and Biology* 2016 **956** 239–259.
- Mannelli M, Lenders JW, Pacak K, Parenti G & Eisenhofer G. Subclinical pheochromocytoma. *Best Practice and Research: Clinical Endocrinology and Metabolism* 2012 **26** 507–515. (<https://doi.org/10.1016/j.beem.2011.10.008>)
- Kopetschke R, Sliisko M, Kilisli A, Tuschy U, Wallaschofski H, Fassnacht M, Ventz M, Beuschlein F, Reincke M, Reisch N, *et al.* Frequent incidental discovery of pheochromocytoma: data from a German cohort of 201 pheochromocytoma. *European Journal of Endocrinology/European Federation of Endocrine Societies* 2009 **161** 355–361. (<https://doi.org/10.1530/EJE-09-0384>)
- Mansmann G, Lau J, Balk E, Rothberg M, Miyachi Y & Bornstein SR. The clinically inapparent adrenal mass: update in diagnosis and management. *Endocrine Reviews* 2004 **25** 309–340. (<https://doi.org/10.1210/er.2002-0031>)
- Cawood TJ, Hunt PJ, O'Shea D, Cole D & Soule S. Recommended evaluation of adrenal incidentalomas is costly, has high false-positive rates and confers a risk of fatal cancer that is similar to the risk of the adrenal lesion becoming malignant; time for a rethink? *European Journal of Endocrinology/European Federation of Endocrine Societies* 2009 **161** 513–527. (<https://doi.org/10.1530/EJE-09-0234>)
- Burnichon N, Buffet A & Gimenez-Roqueplo AP. Pheochromocytoma and paraganglioma: molecular testing and personalized medicine. *Current Opinion in Oncology* 2016 **28** 5–10. (<https://doi.org/10.1097/CCO.000000000000249>)
- Favier J, Amar L & Gimenez-Roqueplo AP. Paraganglioma and pheochromocytoma: from genetics to personalized medicine. *Nature Reviews Endocrinology* 2015 **11** 101–111. (<https://doi.org/10.1038/nrendo.2014.188>)
- Plouin PF, Amar L, Dekkers OM, Fassnacht M, Gimenez-Roqueplo AP, Lenders JW, Lussey-Lepoutre C, Steichen O & Guideline Working Group. European Society of Endocrinology Clinical Practice Guideline for long-term follow-up of patients operated on for a pheochromocytoma or a paraganglioma. *European Journal of Endocrinology/European Federation of Endocrine Societies* 2016 **174** G1–G10. (<https://doi.org/10.1530/EJE-16-0033>)
- Lenders JW, Pacak K, Walther MM, Linehan WM, Mannelli M, Friberg P, Keiser HR, Goldstein DS & Eisenhofer G. Biochemical diagnosis of pheochromocytoma: which test is best? *JAMA* 2002 **287** 1427–1434.
- Pacak K, Eisenhofer G, Ahlman H, Bornstein SR, Gimenez-Roqueplo AP, Grossman AB, Kimura N, Mannelli M, McNicol AM & Tischler AS. Pheochromocytoma: recommendations for clinical practice from the First International Symposium. *Nature Clinical Practice Endocrinology and Metabolism* 2007 **3** 92–102. (<https://doi.org/10.1038/ncpendmet0396>)
- Amar L, Lussey-Lepoutre C, Lenders JW, Djadi-Prat J, Plouin PF & Steichen O. MANAGEMENT OF ENDOCRINE DISEASE: Recurrence or new tumors after complete resection of pheochromocytomas and paragangliomas: a systematic review and meta-analysis. *European Journal of Endocrinology/European Federation of Endocrine Societies* 2016 **175** R135–R145. (<https://doi.org/10.1530/EJE-16-0189>)

- 16 Peitzsch M, Pelzel D, Glockner S, Prejbisz A, Fassnacht M, Beuschlein F, Januszewicz A, Siegert G & Eisenhofer G. Simultaneous liquid chromatography tandem mass spectrometric determination of urinary free metanephrines and catecholamines, with comparisons of free and deconjugated metabolites. *Clinica Chimica Acta* 2013 **418** 50–58. (<https://doi.org/10.1016/j.cca.2012.12.031>)
- 17 Peitzsch M, Prejbisz A, Kroiss M, Beuschlein F, Arlt W, Januszewicz A, Siegert G & Eisenhofer G. Analysis of plasma 3-methoxytyramine, normetanephrine and metanephrine by ultraperformance liquid chromatography-tandem mass spectrometry: utility for diagnosis of dopamine-producing metastatic pheochromocytoma. *Annals of Clinical Biochemistry* 2013 **50** 147–155. (<https://doi.org/10.1258/acb.2012.012112>)
- 18 Darr R, Pamporaki C, Peitzsch M, Miehle K, Prejbisz A, Peczkowska M, Weismann D, Beuschlein F, Sinnott R, Bornstein SR, *et al.* Biochemical diagnosis of pheochromocytoma using plasma-free normetanephrine, metanephrine and methoxytyramine: importance of supine sampling under fasting conditions. *Clinical Endocrinology* 2014 **80** 478–486. (<https://doi.org/10.1111/cen.12327>)
- 19 Eisenhofer G, Brown S, Peitzsch M, Pelzel D, Lattke P, Glockner S, Stell A, Prejbisz A, Fassnacht M, Beuschlein F, *et al.* Levodopa therapy in Parkinson's disease: influence on liquid chromatographic tandem mass spectrometric-based measurements of plasma and urinary normetanephrine, metanephrine and methoxytyramine. *Annals of Clinical Biochemistry* 2014 **51** 38–46. (<https://doi.org/10.1177/0004563213487894>)
- 20 Rao D, Peitzsch M, Prejbisz A, Hanus K, Fassnacht M, Beuschlein F, Brugger C, Fliedner S, Langton K, Pamporaki C, *et al.* Plasma methoxytyramine: clinical utility with metanephrines for diagnosis of pheochromocytoma and paraganglioma. *European Journal of Endocrinology/European Federation of Endocrine Societies* 2017 **177** 103–113. (<https://doi.org/10.1530/EJE-17-0077>)
- 21 Eisenhofer G, Prejbisz A, Peitzsch M, Pamporaki C, Masjkur J, Rogowski-Lehmann N, Langton K, Tsourdi E, Peczkowska M, Fliedner S, *et al.* Biochemical diagnosis of chromaffin cell tumors in patients at high and low risk of disease: plasma versus urinary free or deconjugated O-methylated catecholamine metabolites. *Clinical Chemistry* 2018 [epub]. (<https://doi.org/10.1373/clinchem.2018.291369>)
- 22 Soltani A, Pourian M & Davani BM. Does this patient have pheochromocytoma? A systematic review of clinical signs and symptoms. *Journal of Diabetes and Metabolic Disorders* 2015 **15** 6. (<https://doi.org/10.1186/s40200-016-0226-x>)
- 23 Moramarco J, El Ghorayeb N, Dumas N, Nolet S, Boulanger L, Burnichon N, Lacroix A, Elhaffaf Z, Gimenez Roqueplo AP, Hamet P, *et al.* Pheochromocytomas are diagnosed incidentally and at older age in neurofibromatosis type 1. *Clinical Endocrinology* 2017 **86** 332–339. (<https://doi.org/10.1111/cen.13265>)

Received in final form 4 September 2018

Accepted 10 September 2018

Accepted Preprint published online 11 September 2018