



Contents lists available at ScienceDirect

International Journal of Surgery Case Reports

journal homepage: www.casereports.com

Jejunal perforation as an unusual presentation of total colonic aganglionosis in a neonate: A case report

Sang Beom Han^a, Jiha Kim^b, Suk-Bae Moon^{c,*}^a Department of Ophthalmology, Kangwon Natinoal University Hospital, Kangwon National University School of Medicine, Chuncheon, Republic of Korea^b Department of Neurosurgery, Kangwon National University Hospital, Kangwon National University School of Medicine, Chuncheon, Republic of Korea^c Department of Surgery, Kangwon Natinoal University Hospital, Kangwon National University School of Medicine, Chuncheon, 24289, Republic of Korea

ARTICLE INFO

Article history:

Received 6 September 2017

Received in revised form 3 October 2017

Accepted 11 October 2017

Available online 18 October 2017

Keywords:

Total colonic aganglionosis

Jejunum

Appendix

Biopsy

ABSTRACT

INTRODUCTION: Neonatal intestinal perforation usually occurs at distal small bowel secondary to distal bowel obstruction. The aim of this report is to describe an unusual case of total colonic aganglionosis with an initial presentation of proximal jejunal perforation.

PRESENTATION OF CASE: A male newborn presented with jejunal perforation on the fifth day of life and was treated by laparoscopic primary repair. Abdominal distention persisted postoperatively, and radiological examination revealed an obstruction near the terminal ileum. Laparotomy showed a transition zone 30-cm proximal to the ileocecal valve, and diverting ileostomy and appendiceal biopsy was performed. Permanent section demonstrated the complete absence of ganglion cells in the appendix and total colonic aganglionosis was strongly suspected.

DISCUSSION: Contrary to the classic teaching, proximal bowel perforation can occur in case of far distal obstruction, and careful distal evaluation would direct more appropriate surgical treatment option.

CONCLUSIONS: Total colonic aganglionosis can present as a proximal bowel perforation. Careful distal evaluation can provide diagnostic clues in cases of proximal intestinal perforation. Appendiceal biopsy is a reliable tool for evaluating suspected total colonic aganglionosis, but multiple colonic and rectal biopsies should be obtained to confirm the diagnosis.

© 2017 The Authors. Published by Elsevier Ltd on behalf of IJS Publishing Group Ltd. This is an open access article under the CC BY-NC-ND license (<http://creativecommons.org/licenses/by-nc-nd/4.0/>).

1. Introduction

One of the most common and fatal abdominal complications occurring in the neonatal period is intestinal perforation, which is usually secondary to intestinal obstruction or necrotizing enterocolitis (NEC). The classic teaching is that distal intestinal obstruction often leads to abdominal distension and perforation, while proximal intestinal obstruction leads to excessive vomiting rather than distension [1]. We herein describe a case of total colonic aganglionosis (TCA), a common form of distal intestinal obstruction, presenting as proximal jejunal perforation. We discuss the utility of appendiceal biopsy as a tool for diagnosing TCA.

The work in this case has been reported in line with the SCARE criteria [2].

2. Presentation of the case

A male newborn with persistent feeding intolerance and abdominal distension was referred for surgical evaluation on the 40th day of life. He was born at 37⁺⁶ weeks gestational age with a birth weight of 3000 g. He failed to pass meconium until 2 days after birth and soon thereafter developed abdominal distension and dyspnea, for which he was admitted to the neonatal intensive care unit of the regional hospital. Despite conservative care, pneumoperitoneum developed on the fifth day of life and jejunal perforation was identified 45-cm distal to the ligament of Treitz. The lesion was repaired primarily under laparoscopic guidance by a general surgeon. There was no evidence of NEC and no other intestinal pathology was identified near the site of perforation on gross examination. Feeding intolerance and abdominal distention persisted in the postoperative period and the patient was eventually referred for a pediatric surgery consultation on the 40th day of life. Contrast enema showed a normal caliber colon without a transition zone in the colon or the rectum and a small bowel series demonstrated a partial mechanical obstruction near the terminal ileum (Fig. 1A, B). On laparotomy, there were no obstructing lesions identified at the terminal ileum but a transition zone was identified 30 cm proximal to the ileocecal valve (Fig. 2), thus suggesting TCA with involvement of the terminal ileum. Severe intraabdominal adhesions precluded

Abbreviations: NEC, necrotizing enterocolitis; TCA, total colonic aganglionosis; SIP, spontaneous intestinal perforation; HD, Hirschsprung's disease.

* Corresponding author.

E-mail addresses: msbhan@nate.com (S.B. Han), dopaa@naver.com (J. Kim), sukbae75.moon@gmail.com (S.-B. Moon).

<https://doi.org/10.1016/j.ijscr.2017.10.018>

2210-2612/© 2017 The Authors. Published by Elsevier Ltd on behalf of IJS Publishing Group Ltd. This is an open access article under the CC BY-NC-ND license (<http://creativecommons.org/licenses/by-nc-nd/4.0/>).

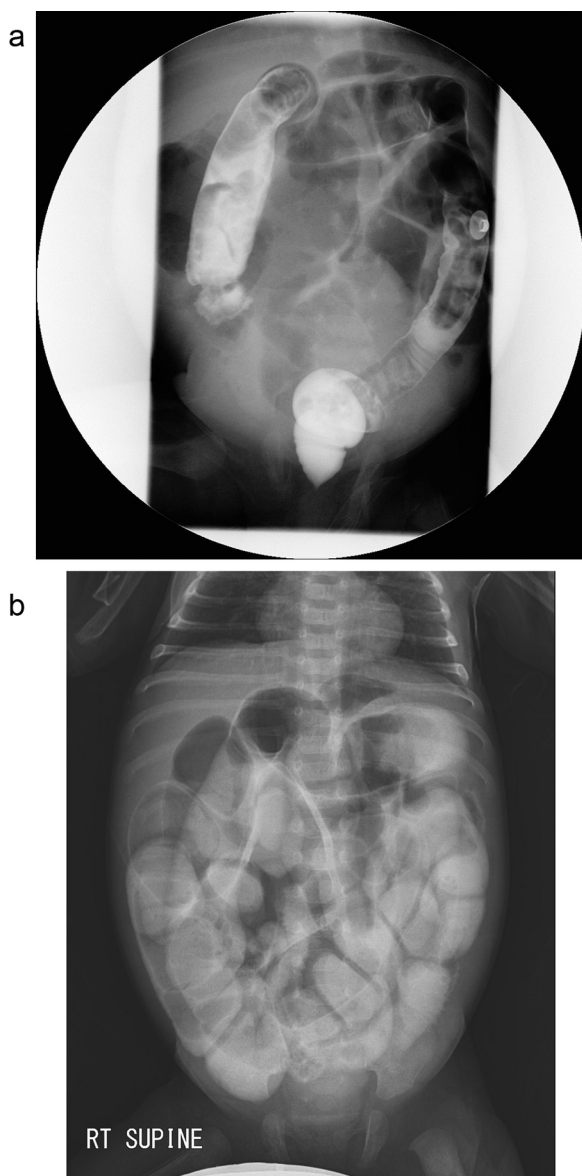


Fig. 1. (A) Barium enema showed relatively normal caliber colon and rectum. (B) Small bowel series showed faint lining of rectum and descending colon wall on delayed images, suggesting partial obstruction at distal small bowel.

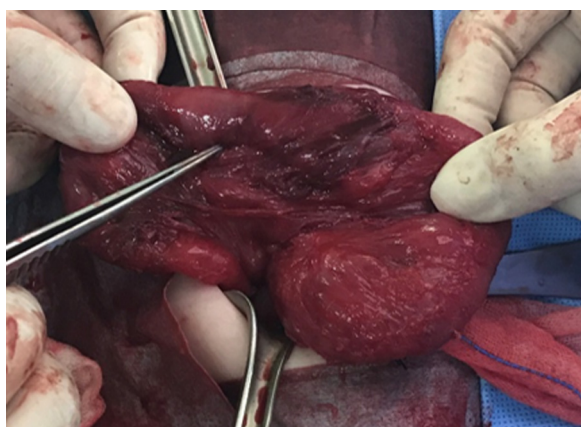


Fig. 2. Transition zone is noted at 30 cm proximal to the ileocecal valve.

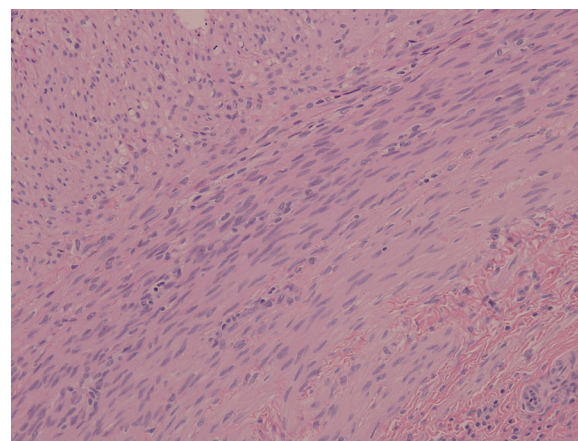


Fig. 3. There were no identifiable ganglion cells on permanent section of the appendix (H&E, $\times 200$).

performing the dissection necessary to obtain multiple colonic and rectal biopsies, so appendectomy was performed for pathological examination and an ileostomy was created. On pathological examination, there were no identifiable ganglion cells in the appendix and thus TCA was suspected (Fig. 3). The postoperative course was uneventful and the patient is currently awaiting a definitive pull-through operation.

3. Discussion

We herein described a rare case of jejunal perforation as the initial presentation of total colonic aganglionosis in a full-term neonate. Traditional teachings have suggested that intestinal perforation occurs more frequently in the distal bowel following mechanical obstruction, while proximal obstruction usually leads to excessive vomiting rather than abdominal distension and perforation [1]. This case contradicts those conventional observations. Additionally, one of the most common causes of intestinal perforation in the neonatal period is a NEC [3], which was not apparent in this patient. One consideration as a cause of perforation in this case is spontaneous intestinal perforation (SIP), but considering that SIP almost always occurs in premature extremely low birth weight or very low birth weight infants [4], SIP alone does not adequately explain the perforation in this patient. Other possible causes of bowel obstruction leading to perforation include atresia of the small or large bowel and anorectal malformations, all of which were grossly excluded intraoperatively. A literature review examining the relationship between bowel perforations and TCA revealed that the most common sites of perforation were the proximal colon (68%) and appendix (17%). In 84% of infants with TCA who experienced bowel perforation, the point of perforation was located in the aganglionic bowel segment [5]. Although no definite cause of perforation could be identified, distal obstruction by TCA with subsequent backpressure reaching the jejunum explains the mechanism of perforation most reasonably and appropriately in this case.

Surgical treatment of neonatal intestinal perforation should be tailored to the individual cause of perforation. Many surgeons perform primary anastomoses in perforations associated with a mechanical obstruction such as atresia if the cause of the obstruction can be removed surgically. We suggest that the two most important contraindications to primary repair include: (1) the presence of intrinsic bowel pathology such as NEC and (2) a functional obstruction of the distal bowel such as Hirschsprung's disease (HD) or other motility disorder. Bowel wall inflammation in NEC can lead to post-repair complications such as stricture, stenosis, or anasto-

motric leakage, and uncontrolled distal functional obstruction may eventually lead to re-perforation. Therefore, in the presence of either of these two conditions, we recommend consideration of diverting enterostomy until the cause of the perforation is eliminated.

A general surgeon performed the initial operation, a laparoscopic primary repair, in this patient. Many reports demonstrate that the outcomes of pediatric surgeries, especially among neonates, are improved when performed by pediatric surgeons as opposed to general surgeons [6,7]. When confronted with patients similar to this case, experienced pediatric surgeons would have evaluated the possibility of distal obstruction and the findings suggestive of TCA might have led the surgeon to create an ileostomy after the initial procedure, rather than performing primary repair alone. This case suggests that when treating neonates presenting with proximal intestinal perforation without a definitive cause such as NEC, the distal bowel should also be evaluated for the possibility of mechanical or functional obstruction. Importantly, this patient did not pass meconium for 2 days after birth, which is a hallmark of HD. A pediatric surgical specialist may have considered performing a contrast enema or rectal biopsy to rule out HD at this point, and a subsequent rectal washout to cleanse the colon may have prevented the perforation.

The diagnosis of TCA is generally achieved by identifying a microcolon on initial contrast enema with subsequent diagnostic appendectomy to demonstrate aganglionosis of the appendix [8]. However, a normal caliber colon can be present in TCA and the diagnosis of TCA is difficult to establish by contrast enema study alone in such cases. Traditionally, many surgeons have assumed that the absence of ganglion cells in the appendix is pathognomonic of TCA, and a recent study demonstrated the utility of appendiceal biopsy as a reliable tool in diagnosing TCA [9]. In contrast, other studies have questioned such beliefs by documenting cases of children who were presumed to have TCA when the appendix was aganglionic at the time of initial laparotomy but who were ultimately found to have normal rectal ganglion cells at the time of the pull-through procedure [10]. In the case described here, pathology demonstrated the complete absence of ganglion cells in the appendix and thus TCA was strongly suspected despite a normal-appearing colon on the contrast enema study. However, we recommend obtaining multiple colonic and rectal biopsies to confirm TCA after appendiceal biopsy.

Aganglionosis of the appendix does not necessarily indicate that all of the small intestine has ganglia, and we had not performed small bowel biopsies to ascertain the presence of small intestinal ganglia. However, preoperative radiological evaluation performed to confirm the extent of small bowel passage and to examine the gross appearance of the transition zone at the distal ileum was sufficient to correctly identify the appropriate site for the ileostomy, and we speculated that a standard length Duhamel pull-through using the ileum proximal to the present stoma would be adequate to treat this patient.

Total intestinal aganglionosis (TIA) occurs in less than 1% of patients with HD. TIA, the most severe form of HD, can eventually lead to intestinal failure and death [11]. Intestinal transplantation represents the only alternative treatment to achieve intestinal autonomy in this patient population, and promising results have been reported after intestinal transplantation in conjunction with parenteral nutrition. Intestinal transplantation should thus be considered as a feasible treatment option for patients with TIA [12].

4. Conclusion

We report a rare case of TCA that initially presented with jejunal perforation. Although the initial surgical approach was misdirected,

the subsequent operation performed by a pediatric surgeon was successful and TCA was suspected based on the results of an appendiceal biopsy demonstrating a complete absence of ganglion cells in the appendix. In cases of proximal intestinal perforation without a clear cause, the distal bowel should also be evaluated for any possible mechanical or functional obstruction. Appendiceal biopsy is a useful tool for suggesting TCA, but multiple colonic and rectal biopsies should be obtained to make the definite diagnosis of TCA.

Conflicts of interests

The authors declare that they have no conflicts of interests.

Funding

The authors declare that they have no funding sources.

Ethical approval

Ethics approval is not required because this is a single case report involving only retrospective review of medical records and does not include data that can identify the patient.

Consent

Written informed consent was obtained from the patient's parents for participation in this case report.

Authors contributions

SBH performed the literature review and composed the main body of the manuscript. SBM was the primary physician caring for the patient and conceptualized this article. Both authors read and approved the final manuscript.

Registration of research studies

This is the first case-report, and which doesn't require registration in "Study Registry". Therefore, we don't have UIN of this study.

Guarantor

Suk-Bae Moon.

References

- [1] W. Stehr, C.A. Gingalewski, Other causes of intestinal obstruction, in: A.G. Coran, T.M. Krummel, L.M. Laberge, R.C. Shamberger, A.A. Caldamone (Eds.), *Pediatric Surgery*, Elsevier, Philadelphia, 2012, pp. 1127–1134.
- [2] R.A. Agha, A.J. Fowler, A. Saetta, I. Barai, S. Rajmohan, D.P. Orgill, The SCARE group, The SCARE statement: consensus-based surgical case report guidelines, *Int. J. Surg.* 34 (2016) 180–186.
- [3] K.G. Sylvester, G.Y. Liu, C.T. Albanese, Necrotizing enterocolitis, in: A.G. Coran, T.M. Krummel, L.M. Laberge, R.C. Shamberger, A.A. Caldamone (Eds.), *Pediatric Surgery*, Elsevier, Philadelphia, 2012, pp. 1187–1207.
- [4] M. Rayyan, I. Myatchin, G. Naulaers, Y. Ali Said, K. Allegaert, M. Miserez, Risk factors for spontaneous localized intestinal perforation in the preterm infant, *J. Matern. Fetal Neonatal Med.* (2017), <http://dx.doi.org/10.1080/14767058.2017.1350161> [Epub ahead of print].
- [5] B. Newman, A. Nussbaum, J.A. Kirkpatrick Jr., Bowel perforation in Hirschsprung's disease, *AJR Am. J. Roentgenol.* 148 (1987) 1195–1197.
- [6] Y. Kim, K. Jung, Y.J. Ryu, S.B. Moon, Pediatric appendectomy: the outcome differences between pediatric surgeons and general surgeons, *Surg. Today* 46 (2016) 1181–1186.
- [7] P.S. da Silva, V.E. de Aguiar, J. Waisberg, Pediatric Surgeon vs general surgeon: does subspecialty training affect the outcome of appendicitis? *Pediatr. Int.* 56 (2014) 248–253.
- [8] E. Stranzinger, M.A. DiPietro, D.H. Teitelbaum, P.J. Strouse, Imaging of total colonic Hirschsprung disease, *Pediatr. Radiol.* 38 (2008) 1162–1170.

- [9] T. O'Hare, M. McDermott, M. O'Sullivan, P. Dicker, B. Antao, A retrospective cohort study of total colonic aganglionosis: is the appendix a reliable diagnostic tool? *J. Neonatal Surg.* 5 (2016) 44.
- [10] V.A. Lane, M.A. Levitt, P. Baker, P. Minnici, K. Deans, The appendix and aganglionosis. A note of caution-How the histology can mislead the surgeon in total colonic Hirschsprung's disease, *Eur. J. Pediatr. Surg. Rep.* 3 (2015) 3–6.
- [11] F. Sauvat, C. Grimaldi, F. Lacaille, F. Ruemmele, L. Dupic, N. Bourdaud, et al., Intestinal transplantation for total intestinal aganglionosis: a series of 12 consecutive children, *J. Pediatr. Surg.* 43 (2008) 1833–1838.
- [12] H. Nakamura, D. Henderson, P. Puri, A meta-analysis of clinical outcome of intestinal transplantation in patients with total intestinal aganglionosis, *Pediatr. Surg. Int.* 33 (2017) 837–841.

Open Access

This article is published Open Access at scimedirect.com. It is distributed under the [IJSCR Supplemental terms and conditions](#), which permits unrestricted non commercial use, distribution, and reproduction in any medium, provided the original authors and source are credited.