

# Multiple Spontaneous Ectopic Pregnancies Following Bilateral Salpingectomy

Yusor Al-Nuaimy<sup>1</sup>, Jacqueline John<sup>2</sup>, Sousan Mohamad Alhomsy<sup>2</sup>, Omaema Omar Al-Baghdadi<sup>2</sup>

<sup>1</sup>College of Medicine, Ajman University, Ajman, United Arab Emirates; <sup>2</sup>Department of Obstetrics and Gynaecology, Tawam Hospital, Al-Ain City, Abu Dhabi, United Arab Emirates

Correspondence: Omaema Omar Al-Baghdadi, Consultant Physician Obstetrics and Gynaecology and Program Director of OBGYN Residency Program, Tawam Hospital, Al Ain City, Abu Dhabi, United Arab Emirates, Tel +971585809767, Fax +971-3-767-1228, Email oalbaghdadi@yahoo.co.uk

**Introduction:** Ectopic pregnancy (EP) is a significant cause of gynaecological morbidity and mortality. Salpingectomy is the preferred management modality in recurrent ectopic pregnancies; although they do not eliminate the risk of recurrence. The aetiology of recurrent ectopic pregnancies remains unknown but there are identifiable risk factors associated with increased likelihood of occurrence.

**Case Presentation:** We present the case of a 30-year-old woman who attended the emergency unit with her second spontaneous ectopic pregnancy following a previous bilateral salpingectomy. She had prior multiple spontaneous ectopic pregnancies: laparoscopic salpingectomy for a left cornual EP in 2017 followed by laparotomic salpingectomy for a ruptured right EP after failed medical management in 2018. Lastly, she had laparoscopic removal of an EP sac in the scar of a previous left cornual EP in 2019. She presented with a history of missed periods, pelvic pain, and vaginal spotting. Her examination revealed left lower abdominal pain, soft, non-tender abdomen, and no cervical excitation. Pelvic ultrasound revealed a thin endometrium and no intrauterine pregnancy visualised. A suspicious complex mass near the left ovary with a ring-like structure was noted. Her  $\beta$ -HCG was (251 IU/L) which plateaued after 48 hrs (220 IU/L). She responded well to methotrexate with no need for surgical intervention this time.

**Conclusion:** This case is unique as it highlights the importance of keeping an open mind when managing recurrent ectopic pregnancies, especially when preventative surgical measures have been performed previously.

**Keywords:** ectopic pregnancy, recurrent, salpingectomy, PID, laparoscopy

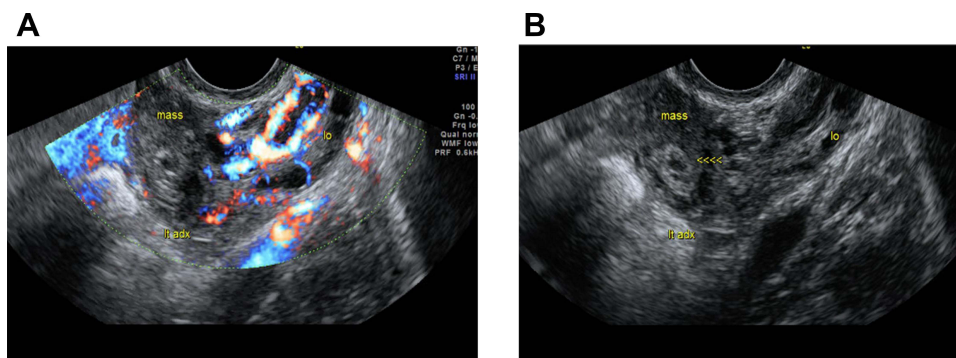
## Introduction

An ectopic pregnancy (EP) is defined as the implantation and development of an embryo outside of the endometrial cavity. The rate of ectopic pregnancy occurrence varies depending on the implantation site: interstitial (2.4%), isthmic (12.0%), ampullary (70.0%), fimbrial (11.1%), ovarian (3.2%) and abdominal (1.3%).<sup>1</sup> However, the occurrence of an ectopic pregnancy after surgical measures have been performed (eg, salpingectomy) is exceedingly rare, with only a handful cases recorded in literature. Current management of recurrent ectopic pregnancy consists of a medical intervention (methotrexate) or surgical interventions (salpingostomy, fimbrial evacuation or salpingectomy).<sup>2</sup> To the best of our knowledge, there is no report of spontaneous recurrent cornual ectopic pregnancies post bilateral salpingectomy. Till date, the reported cases concerning multiple EPs post bilateral salpingectomy were following IVF management. This case report demonstrates that an ectopic pregnancy can still occur naturally after surgical preventative measures have been taken.

## Case Presentation

A 30-year-old Emirati female G8P3A2Ep3, with a history of primary infertility for 3 years, had multiple IVF trials. Currently, she is a mother of three children with two previous early miscarriages and three ectopic pregnancies for which she had a bilateral salpingectomy.

She presented with left lower abdominal pain, vaginal spotting, and 6 weeks of amenorrhea. Upon examination, the patient was found to have a soft, non-tender abdomen and no cervical excitation by vaginal assessment. Pelvic ultrasound (Figure 1A and B) revealed a thin endometrium (0.6 cm), normal ovaries, and a suspicious complex mass ( $2.1 \times 1.5 \times 1.5$  cm) in the left

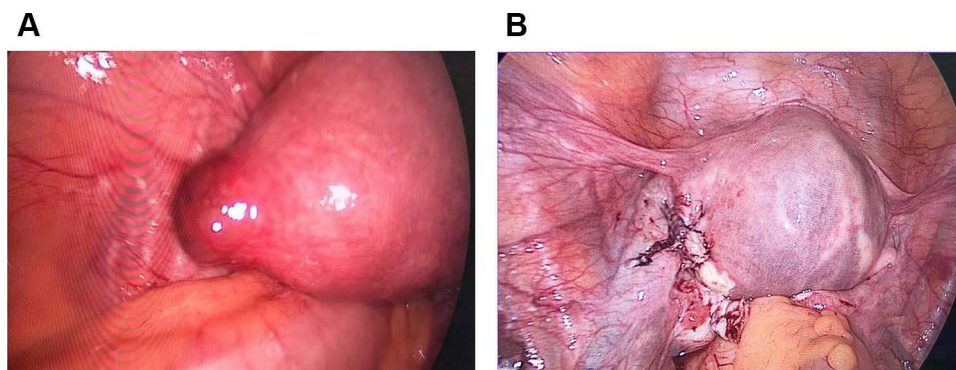


**Figure 1** (A) Pelvic ultrasound of latest interstitial ectopic pregnancy (2022). (B) Pelvic ultrasound of latest interstitial ectopic pregnancy (2022).

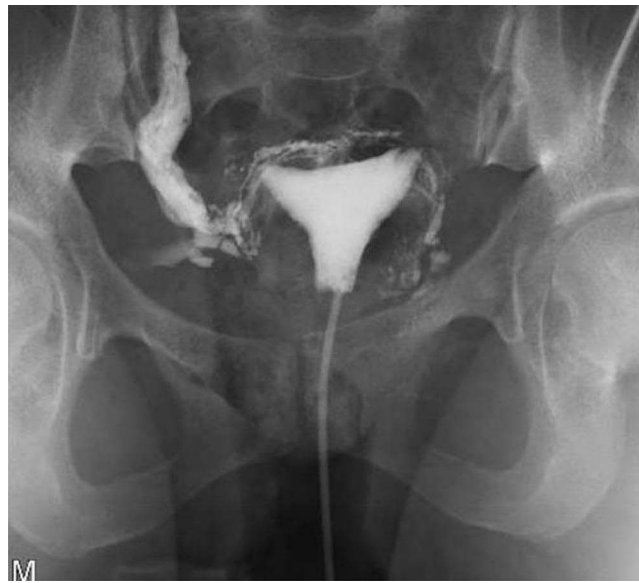adnexa near the left ovary with a ring-like structure; no intrauterine pregnancy was visualised. Laboratory investigations revealed elevated  $\beta$ -HCG (251 IU/L) which plateaued after 48 hrs (220 IU/L). A diagnosis of EP was reached. Surgical and medical treatment modalities were offered to the patient; the patient opted for medical treatment. As such, methotrexate was administered, within two weeks,  $\beta$ -HCG levels plummeted to insignificant levels.

Her previous history showed that she had had a diagnostic hysteroscopy and laparoscopy in 2014, due to primary infertility, revealing an arcuate uterus, membranous adhesions between the fallopian tubes and ovary, and a left hydrosalpinx, a blue-dye test confirmed right fallopian tube patency only. In 2016, the patient conceived spontaneously following a failed in vitro fertilisation (IVF) trial, which resulted in a full-term spontaneous vaginal delivery. In 2017, the patient had an ectopic pregnancy in the left uterine cornua, which was surgically treated via laparoscopic salpingectomy. In 2018, an ectopic pregnancy in the right fallopian tube was surgically treated by laparotomic salpingectomy for a ruptured EP after failed methotrexate treatment. In 2019, the patient yet again presented with a left scar ectopic pregnancy; laparoscopic removal of the sac with suturing of the cornua part was performed (Figure 2A and B). The clinical diagnoses of all ectopic pregnancies were confirmed histologically. In 2020, the patient had a set of twins conceived via IVF and delivered by c-section.

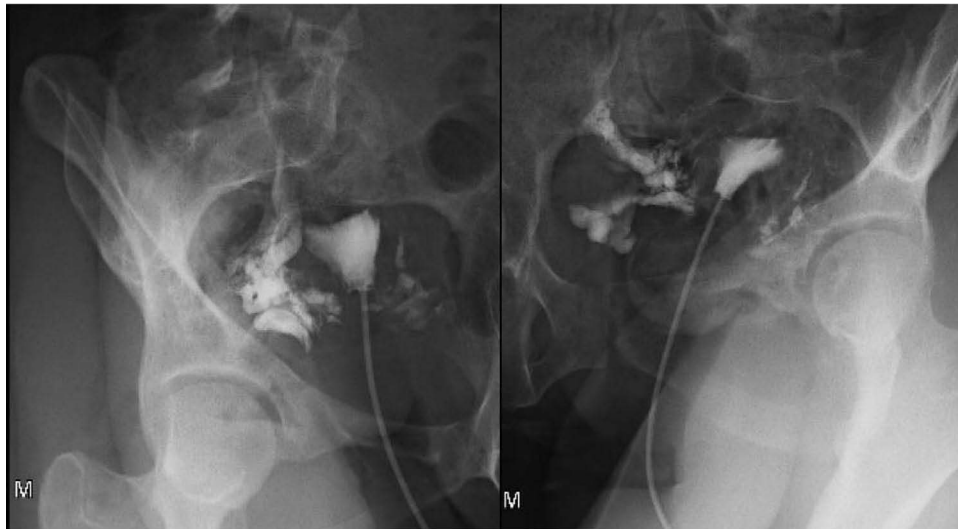
Considering the patient's background of multiple EPs and being liable for more in the future, an x-ray hysterosalpingography was performed to determine the patency of the tubes and prepare a plan to prevent another reoccurrence of EP (Figures 3 and 4). The hysterosalpingogram reported the appearance of both tubes with the left tube noticeably shorter than the right, faint spillage on both sides, intravasation into the veins, and possible partial recanalization of both tubes had taken place. The agreed management after counselling the patient about the above findings was to have combined oral contraception and to opt for IVF should she plan to have another pregnancy.



**Figure 2** (A) Left cornua before laparoscopy (2019). (B) Laparoscopic removal of ectopic pregnancy sac and diathermy (2019).



**Figure 3** XR Hysterosalpingography (March 2023).



**Figure 4** XR Right and Left Hysterosalpingography (March 2023).

## Discussion

Ectopic pregnancies account for nearly 1.5–2% of all pregnancies;<sup>3</sup> recurrent ectopic pregnancies following salpingectomies are even rarer, although the exact incidence rate is unclear. Theoretically, performing a salpingectomy eliminates the risk of a future potential ectopic pregnancy; however, that is not always the case.<sup>4,5</sup> Given the clinical context of a prior salpingectomy, diagnosis of a recurrent ectopic pregnancy becomes challenging; nevertheless, there are identifiable risk factors (similar to those of an initial EP) that place patients in the high index of suspicion for a recurrent EP. A systematic review performed in 2020 suggested that tubal damage, evidence of infectious pelvic pathology, prior pelvic surgery, salpingostomy, salpingitis, infertility, lower annual income, and a lack of contraceptive use are common risk factors amongst patients with recurrent EP.<sup>2</sup> The same risk factors were also reported in several other large-scale studies.<sup>6–9</sup> Considering the aforementioned and adding to that the high-risk nature of ectopic pregnancies, the diagnosis of a recurrent ectopic pregnancy must always be considered a possibility despite its rarity.

The exact mechanism of ectopic pregnancy occurrence is not illustrated in literature. As of now, there are three possible hypotheses that explain its aetiology: migration of a fertilized egg across the endometrium to the contralateral remnant stump, migration of a fertilized egg across a transperitoneal passage (POD) to the contralateral patent fallopian tube, or recanalization of the remnant stump which allows for communication between the endometrial and peritoneal cavities to a certain degree.<sup>10-12</sup> As of yet, there are no further postulations seeking to explain the mechanism by which a recurrent ectopic pregnancy occurs.

Our literature search results showed few similar published cases which describe ectopic pregnancy post IVF treatment in patients. Most recently in July 2022, Liu et al reported a heterotopic pregnancy at the left ovarian ligament post IVF and embryo transfer (IVF-ET) after bilateral salpingectomy.<sup>13</sup>

A literature review in 2020 by Zhenbo OuTang et al reviewed 19 cases of ectopic pregnancies post bilateral salpingectomy at various sites including tubal stump, abdominal cavity, ovary, retroperitoneum and uterine cornua, however all the cases described were post IVF-ET, making IVF a considerable risk factor for ectopics post bilateral salpingectomy.<sup>14</sup> A systematic review done up to 2020, revealed only 4 out of 39 cases of spontaneous intrauterine pregnancies post total bilateral salpingo-oophorectomies performed for indications other than permanent contraception.<sup>5</sup> In 2022, Zhang et al attributed the presence of a fallopian tube stump alongside a uterine cornual fistula to be the main cause of an ectopic pregnancy post IVF-ET treatment.<sup>15</sup> Another rare case of spontaneous intrauterine pregnancy post bilateral salpingectomy was reported in 2004 by Bollapragada et al which suggested a patent cornual end or a suspected fistulous tract to be the possible cause for the same.<sup>4</sup>

Our case is unique in that a 2nd 'spontaneous' ectopic pregnancy has developed at the left uterine cornua despite a bilateral salpingectomy done for previous ectopic pregnancies. Unlike the above mentioned cases, our patient did not undergo any IVF treatment that resulted in an ectopic pregnancy. Similarly, the hysterosalpingogram findings of our case could suggest the presence of a left patent uterine cornua and/or possible fistula formation as the cause for the recurrent spontaneous EP.

What this case reveals is that total prevention of recurrence of an ectopic pregnancy is difficult to attain due to the uncertain aetiology of its occurrence. Nonetheless, there are several ways in which its incidence can be reduced. During a salpingectomy, it is often advisable to leave out a long tubal stump to reduce the risk of bleeding but due to the given risk of a recurrent ectopic pregnancy, the length of the tubal segment should be minimised.<sup>10</sup> Furthermore, sufficient diathermy of the proximal portion of the fallopian tube or its ligation might be used to decrease the risk of another implantation.<sup>16</sup> Another measure is to conduct a hysterosalpingography to measure the patency of the fallopian tubes/stumps after a salpingectomy procedure.

## Conclusion

The rate of occurrence of ectopic pregnancies following salpingectomies is unknown; yet they remain of clinical significance owing to high mortality rates.<sup>17</sup> Clinicians should be aware of the risk factors and should also bear in mind that a salpingectomy does not fully exclude the diagnosis of an ectopic pregnancy.

## Data Sharing Statement

All data underlying the results are available as part of the article and no additional source data are required.

## Ethical Approval

Written consent was obtained from the patient for publishing this article and all accompanying images. Institutional ethical approval was not required to publish the case.

## Disclosure

The authors declare no conflict of interests.

## References

1. Bouyer J, Coste J, Fernandez H, Pouly JL, Job-Spira N. Sites of ectopic pregnancy: a 10 year population-based study of 1800 cases. *Hum Reprod.* 2002;17(12):3224–3230. doi:10.1093/humrep/17.12.3224
2. Petrini A, Spandorfer S. Recurrent ectopic pregnancy: current perspectives. *Int J Womens Health.* 2020;12:597–600. doi:10.2147/ijwh.S223909
3. De Los Rios JF, Castañeda JD, Miryam A. Bilateral ectopic pregnancy. *J Minim Invasive Gynecol.* 2007;14(4):419–427. doi:10.1016/j.jmig.2007.01.011
4. Bollapragada SS, Bandyopadhyay S, Serle E, Baird C. Spontaneous pregnancy after bilateral salpingectomy. *Fertil Steril.* 2005;83(3):767–768. doi:10.1016/j.fertnstert.2004.07.970
5. Baltus T, Brown J, Molakatalla S, Kapurubandara S. Spontaneous pregnancy after total bilateral salpingectomy: a systematic review of literature. *J Minim Invasive Gynecol.* 2022;29(2):213–218. doi:10.1016/j.jmig.2021.09.713
6. Butts S, Sammel M, Hummel A, Chittams J, Barnhart K. Risk factors and clinical features of recurrent ectopic pregnancy: a case control study. *Fertil Steril.* 2003;80(6):1340–1344. doi:10.1016/s0015-0282(03)02206-4
7. Hurrell A, Reebe O, Funlayo O. Recurrent ectopic pregnancy as a unique clinical sub group: a case control study. *Springerplus.* 2016;5(1):265. doi:10.1186/s40064-016-1798-0
8. Levin G, Dior UP, Shushan A, Gilad R, Benshushan A, Rottenstreich A. Risk factors for recurrent ectopic pregnancy following single-dose methotrexate treatment. *Eur J Contracept Reprod Health Care.* 2019;24(4):294–298. doi:10.1080/13625187.2019.1625324
9. Tan Y, Bu ZQ, Shi H, Song H, Zhang YL. Risk factors of recurrent ectopic pregnancy in patients treated with in vitro fertilization cycles: a matched case-control study. *Front Endocrinol.* 2020;11:552117. doi:10.3389/fendo.2020.552117
10. Zuzarte R, Khong CC. Recurrent ectopic pregnancy following ipsilateral partial salpingectomy. *Singapore Med J.* 2005;46(9):476–478.
11. Takeda A, Manabe S, Mitsui T, Nakamura H. Spontaneous ectopic pregnancy occurring in the isthmic portion of the remnant tube after ipsilateral adnexectomy: report of two cases. *J Obstet Gynaecol Res.* 2006;32(2):190–194. doi:10.1111/j.1447-0756.2006.00385.x
12. Yano T, Ishida H, Kinoshita T. Spontaneous ectopic pregnancy occurring in the remnant tube after ipsilateral salpingectomy: a report of 2 cases. *Reprod Med Biol.* 2009;8(4):177–179. doi:10.1007/s12522-009-0028-7
13. Liu Y, Li Y, Li K, Li S. Abdominal heterotopic pregnancy after in vitro fertilization and embryo transfer following bilateral salpingectomy: a case report and literature review. *Front Reprod Health.* 2022;4:921141. doi:10.3389/frph.2022.921141
14. OuYang Z, Yin Q, Wu J, Zhong B, Zhang M, Li F. Ectopic pregnancy following in vitro fertilization after bilateral salpingectomy: a review of the literature. *Eur J Obstet Gynecol Reprod Biol.* 2020;254:11–14. doi:10.1016/j.ejogrb.2020.08.046
15. Zhang M, Zhao C, Zheng J, et al. Ovarian pregnancy after bilateral salpingectomy in a patient with in vitro fertilization: a case report. *J Int Med Res.* 2022;50(9):3000605221123683. doi:10.1177/03000605221123683
16. Samiei-Sarir B, Diehm C. Recurrent ectopic pregnancy in the tubal remnant after salpingectomy. *Case Rep Obstet Gynecol.* 2013;2013:753269. doi:10.1155/2013/753269
17. Cantwell R, Clutton-Brock T, Cooper G, et al. Saving in the United Kingdom. *Bjog.* 2011;118(Suppl 1):1–203. doi:10.1111/j.1471-0528.2010.02847.x

International Medical Case Reports Journal

Dovepress

### Publish your work in this journal

The International Medical Case Reports Journal is an international, peer-reviewed open-access journal publishing original case reports from all medical specialties. Previously unpublished medical posters are also accepted relating to any area of clinical or preclinical science. Submissions should not normally exceed 2,000 words or 4 published pages including figures, diagrams and references. The manuscript management system is completely online and includes a very quick and fair peer-review system, which is all easy to use. Visit <http://www.dovepress.com/testimonials.php> to read real quotes from published authors.

Submit your manuscript here: <https://www.dovepress.com/international-medical-case-reports-journal-journal>