

# One-stop hybrid surgery for treatment of complex Stanford type B aortic dissection

Yongzhong Guo<sup>1</sup>, Jinjie Shao<sup>1</sup>, Wenjian Shi<sup>2</sup>,  
Mei Tian<sup>3</sup>, Ling Li<sup>1</sup>, Tangsakar Ermek<sup>1</sup> and  
Zonggang Zhang<sup>1</sup>

## Abstract

**Objectives:** To compare the efficacy and prognosis of one-stop hybrid surgery using the elephant trunk procedure for treatment of complex Stanford type B aortic dissection.

**Methods:** We retrospectively analyzed patients who underwent surgical treatment from January 2014 to July 2019. The patients were divided into those who underwent the elephant trunk procedure (n = 10) and those who underwent one-stop hybrid surgery (n = 10). The cardiopulmonary bypass time, mechanical ventilation time, length of hospital stay, and red blood cell usage were compared between the two groups. All patients' 3-month postoperative aortic computed tomography angiography (CTA) findings were also reviewed.

**Results:** The cardiopulmonary bypass time, mechanical ventilation time, and length of hospital stay were significantly shorter and red blood cell usage was significantly lower in the one-stop hybridization group. The aortic cross-clamp time was not significantly different between the two groups. Aortic CTA review after hybrid surgery showed that the true lumen of the descending aorta was almost completely restored at 3 months.

**Conclusion:** One-stop hybrid surgery effectively alleviated the occlusion of the aortic dissection, prevented the need for additional surgery, and expanded the indications for covered-stent endovascular repair.

<sup>1</sup>Heart Surgery, Xinjiang Uygur Autonomous Region People's Hospital, Xinjiang, Urumqi, China

<sup>2</sup>Department of Anesthesiology, Xinjiang Uygur Autonomous Region People's Hospital, Urumqi, China

<sup>3</sup>Infection Management Division, Xinjiang Uygur Autonomous Region People's Hospital, Xinjiang, Urumqi, China

## Corresponding author:

Zonggang Zhang, Heart Surgery, Xinjiang Uygur Autonomous Region People's Hospital, No. 91 Tianchi Road, Tianshan District, Urumqi, Xinjiang Province 830001, China.

Email: zhangzg6219@sohu.com



## Keywords

Stanford type B aortic dissection, hybrid surgery, elephant trunk procedure, covered stent, occlusion, computed tomography angiography

Date received: 8 February 2020; accepted: 26 June 2020

## Introduction

Aortic dissection is a cardiovascular disease with high fatality. The primary rupture is generally located in the descending aorta; however, when the dissection affects the distal end of the aortic arch, it is known as complex Stanford type B aortic dissection. Because of the involvement of the aortic arch, surgery is required for complex Stanford type B aortic dissection to prevent acute pericardial tamponade caused by nervous system injury or vessel rupture due to eversion-stripping dissection affecting the brachiocephalic vessels. Because complex Stanford type B aortic dissection involves the aortic arch, left hemiplegia or total aortic arch replacement under deep hypothermia is necessary. These procedures are associated with high risks of morbidity and mortality. Moreover, the deep hypothermic circulatory arrest time is limited because the mortality rate increases as the deep hypothermic circulatory arrest time increases. With the development of interventional surgery, studies have shown that substation-type hybrid surgery combining aortic bypass and endovascular repair results in less trauma than does the elephant trunk procedure.<sup>1</sup> However, only a few reports have addressed the effects of one-stop hybrid surgery.<sup>2-4</sup> In this study, we retrospectively analyzed patients with complex Stanford type B aortic dissection who underwent either one-stop hybrid surgery or the elephant trunk procedure. The advantages and

disadvantages of the two surgical methods were compared. The study results will provide surgeons with insight on the best surgical procedure for complex Stanford B aortic dissection.

## Materials and methods

### Patients

We retrospectively analyzed the medical records of patients with complex Stanford type B aortic dissection who were admitted to the Department of Cardiac Surgery of the People's Hospital of Xinjiang Uygur Autonomous Region (Xinjiang, China) from January 2014 to July 2019. The inclusion criteria were (1) an age of 25 to 70 years, (2) a history of sudden severe tear-like chest pain but without acute coronary syndrome as confirmed by electrocardiography in a local hospital or our hospital, (3) confirmation of Stanford type B aortic dissection by preoperative aortic computed tomography angiography (CTA) with location of the rupture <15 mm from the left subclavian artery, and (4) treatment with medical symptomatic support before surgery. Surgical treatment was performed within 24 to 120 hours. The patients were divided into two groups according to the surgical procedure: the elephant trunk procedure group or the one-stop hybrid surgery group. No statistically significant differences were observed between the two groups before surgery.

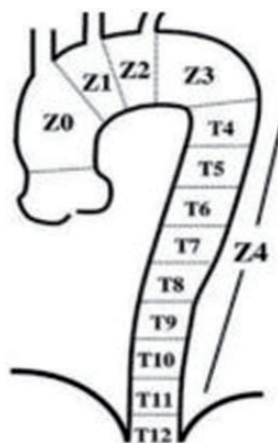
### Ethics statement

This study was conducted in accordance with the Declaration of Helsinki. The study was approved by the Ethics Committee of Xinjiang Uygur Autonomous Region People's Hospital. Written informed consent was obtained from all participants.

### Surgical procedures

**Elephant trunk stenting.** The patients underwent general anesthesia and thoracotomy through a median chest incision. The surgeons established cardiopulmonary bypass to block the ascending aorta. A clamp was placed between the left common carotid artery and the left subclavian artery. A clamp was placed at the level of the fourth and fifth intercostals at the distal end to block the beginning of each branch of the aorta. The aorta was transected 1 cm from the distal end of the left subclavian opening. The aorta was transected at the level of the fourth and fifth intercostals at the distal end. A covered stent was slowly inserted into the real lumen of the descending aorta. Finally, the proximal end of the stent was fixed to the wall of the aorta with a continuous suture.

**Aortic bypass grafting.** The patients underwent general anesthesia and endotracheal intubation. The surgeon cut the platysma muscle through the patient's neck, exposed the bilateral sternocleidomastoid muscles, separated the common carotid artery by a length of about 3 cm, and blocked one common carotid artery. The left common carotid artery was anastomosed to the left subclavian artery in an end-to-side fashion. Next, a stent graft was retrogradely implanted through a small incision in the femoral artery. No significant change in cerebral blood oxygen monitoring occurred during the whole operation. Before the operation, according to the method of



**Figure 1.** Diagram of the Mitchell's Area method. Aortic arch zones: Z0 includes the area from the ascending aorta to the distal end of the innominate artery opening. Z1 includes the area from the distal end of the innominate artery opening to the distal end of the left common carotid artery opening. Z2 includes the area from the left common carotid artery opening distal to the far end of the left subclavian artery opening. Z3 includes the area of the descending aorta 2 cm distal to the left subclavian artery opening. Z4 includes the descending aorta 2 cm below the distal opening of the left subclavian artery.

aortic arch break division proposed by Mitchell et al.<sup>5</sup> (Figure 1), the left common carotid–left subclavian artery bypass was mainly performed in zone 3. In zone 2, the left subclavian artery was close to the left common carotid artery, making it difficult to obtain an adequate anchorage area by simply reconstructing the left subclavian artery; therefore, right carotid–left carotid–left subclavian artery bypass was needed.

**Covered stent graft in aortic cavity.** After the patient was sent to the catheter room, the surgeon conducted a groin incision under the guidance of digital subtraction angiography to separate the femoral artery, inserted a 5-Fr vessel sheath, and sent the wire and catheter for abdominal

aortography. The results of abdominal aortography confirmed that the catheter was located in the real cavity of the aortic dissection. The surgeon continued to send the guide wire and catheter for ascending aortography. The real cavity of the aortic dissection and the rupture of the intima were confirmed again, and the covered stent was sent to cover the left common carotid artery and/or the left subclavian artery by a covered stent conveyor (Medtronic, Inc., Minneapolis, MN, USA). The location of the stent was confirmed again by ascending aortography. The femoral artery was sutured postoperatively.

### Statistical analysis

The statistical software SPSS for Windows, version 11.5 (SPSS Inc., Chicago, IL, USA) was used to perform an independent-samples t-test for comparison of the intraoperative and postoperative monitoring and treatment data between the two groups. A  $P$  value of  $<0.05$  was considered statistically significant.

## Results

### Patients' general information

Twenty patients were enrolled in this study. They comprised 12 men and 8 women aged 47 to 70 years (mean age,  $58 \pm 4.5$  years). All patients were diagnosed with Stanford type B dissection with an affected aortic arch. Ten patients underwent the elephant trunk procedure, and 10 patients underwent one-stop hybrid surgery. The patients' general information is presented in Table 1.

### Intraoperative and postoperative monitoring and treatment comparison

The cardiopulmonary bypass time, mechanical ventilation time, and hospital stay were significantly shorter ( $P = 0.02$ ,  $0.03$ , and

**Table 1.** Patients' general information.

Parameter	Patients (n = 20)
Male	12 (60%)
Female	8 (40%)
History of smoking (10 cigarettes/day)	8 (40%)
Hypertension	18 (90%)
Diabetes mellitus	4 (20%)
Kidney ischemia	2 (10%)
Visceral artery involvement	4 (20%)

$0.04$ , respectively) and red blood cell usage was significantly lower ( $P = 0.04$ ) in the one-stop hybrid surgery group than in the elephant trunk procedure group. The aortic cross-clamp time was not significantly different between the two groups (Table 2).

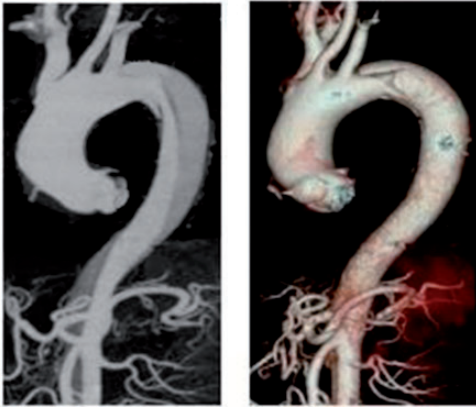
### Postoperative follow-up

Aortic CTA in patients with complex Stanford type B aortic dissection showed that the thoracic descending aorta proximal to the dissection involved the aortic arch and that the intimal rupture was  $<2$  cm from the left subclavian artery (Figure 2). Prior to surgery, aortic CTA in both groups showed that the true lumen of the thoracic descending aorta was compressed and that the official lumen was narrow (Figures 3(a) and 4(a)). Aortic CTA review 3 months after hybrid surgery showed that the true lumen of the descending aorta had been reconstructed with an enlarged true lumen, while the false lumen was reduced. The true lumen of the descending aorta was almost completely restored, and neither stent displacement nor endoleakage was observed. A reticular metal shadow was visible in the descending aorta (Figure 3(b)). Aortic CTA review 3 months after the elephant trunk procedure indicated that the true lumen of the descending aorta was enlarged, while the false lumen was reduced. A high-density stent was visible

**Table 2.** Comparison of intraoperative and postoperative monitoring and treatment.

Evaluation index	Elephant trunk procedure group	One-stop hybrid surgery group	t	P
Cardiopulmonary bypass time, minutes	91.45 ± 12.80	74.09 ± 15.85*	1.36	0.02
Aortic cross-clamp time, minutes	42.26 ± 8.60	40.50 ± 7.08	4.25	1.35
Red blood cell usage, U	8.36 ± 3.14	3.53 ± 3.06*	3.21	0.04
Mechanical ventilation time, hours	12.67 ± 5.25	5.90 ± 2.96*	2.36	0.03
Length of stay, days	14.83 ± 2.33	8.30 ± 2.34*	3.07	0.04

\* $P < 0.05$  compared with the elephant trunk procedure group.



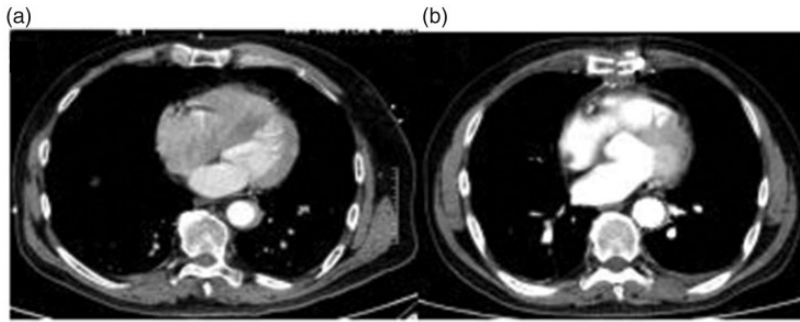
**Figure 2.** Aortic computed tomography angiography of complex Stanford type B aortic dissection.

in the descending aorta. The outer edge of the stent was surrounded by low-density shadows, and the true cavity was not fully recovered (Figure 4(b)). All patients survived the surgical procedure and returned to normal life.

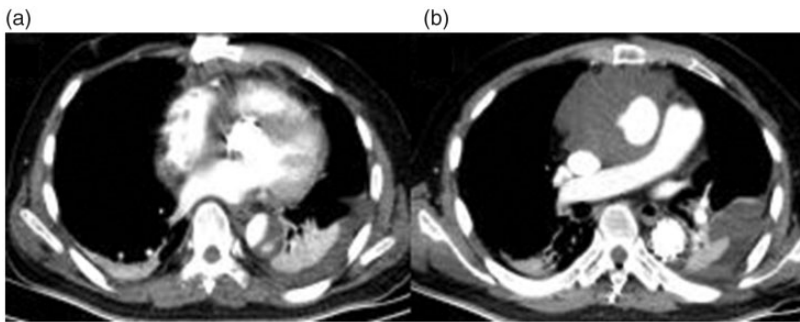
## Discussion

The traditional surgical strategy for type B aortic dissection involving the aortic arch is to replace the distal aortic arch and descending aorta, which often requires deep hypothermic circulatory arrest or femoral arteriovenous bypass. Generally, this surgery is quite complicated and may be associated with certain complications.<sup>6,7</sup> In

recent years, an aortic exclusive technique has been widely used in the separation of type B aortic dissection.<sup>8,9</sup> The surgical mortality rate and occurrence of complications are significantly lower than those of traditional surgery. During the past 10 years, the success rate of the endoluminal procedure for type B aortic dissection in China reached 99%.<sup>10</sup> However, if the dissection involves the distal end of the aortic arch, simple endoluminal covered-stent placement is not suitable.<sup>11</sup> The hybridization technique, which combines superior aortic arch branch bypass surgery and aortic endoluminal treatment, has been shown to improve the surgical options for type B dissection involving the aortic arch.<sup>12,13</sup> Studies performed in both China and abroad have shown that it is difficult to cure complex aortic dissection in one stage with a median sternal incision or left chest incision. One-stage surgery with a median sternal and anterior lateral incision or with transverse sternal bilateral thoracotomy have shortcomings including significant trauma and a high mortality rate. Additionally, the mortality and complication rates are even higher in two-stage surgery, which is not an option for some patients. In the present study, one-stop hybrid surgery was performed to reduce the risks of severe trauma and high mortality associated with two-stage surgery. The indications for endoluminal covered-stent placement were thus expanded.



**Figure 3.** Aortic computed tomography angiography (a) before surgery and (b) 3 months after one-stop hybrid surgery.



**Figure 4.** Aortic computed tomography angiography (a) before surgery and (b) 3 months after the elephant trunk procedure

Covered-stent endoluminal repair for complex Stanford B aortic dissection may block the left subclavian artery and cause a series of serious complications, including spinal cord ischemia and left limb ischemia. Therefore, the elephant trunk procedure may be a more reasonable approach.<sup>14,15</sup> However, this procedure involves thoracotomy and may lead to nervous system complications, lung infection, and acute renal failure. Chino et al.<sup>16</sup> demonstrated that based on the severity of proximal and distal lesions of the aortic arch, more severe lesions should be treated first, followed by distal lesions. However, this method was not suitable for the radical cure of proximal and distal lesions of the

aortic arch. Because complex Stanford type B aortic dissection involves the left hemi-arch, covered-stent endoluminal repair is also difficult to perform at the distal end of the aortic arch. Various bypass surgeries are currently available for the aortic arch, and all have the same purpose: to expand the proximal anchoring area and reduce the complications caused by the elephant trunk procedure. The present study showed that compared with the elephant trunk procedure, one-stop hybrid surgery was more effective for complex Stanford B-type aortic dissection, prevented thoracotomy, lowered the incidence of thoracic complications, reduced bleeding and red blood cell usage, and shortened the



mechanical ventilation time and recovery time.

Postoperative aortic CTA showed that the blood flow within the stent in both groups was smooth, and no endoleakage or displacement was observed within the stent. The true lumen of the aorta at the distal end of the stent was enlarged, and the false lumen was significantly reduced. During the elephant trunk procedure, the intimal rupture of the thoracic descending aorta was closed by the elephant stent. The tension of the aortic false lumen after exclusion by the elephant stent was reduced, thereby promoting the formation of false lumen thrombosis. As the elephant trunk gradually expanded, the true lumen gradually enlarged, and the thrombus in the false lumen was gradually absorbed. The elephant trunk exhibited the self-expanding property of an artificial blood vessel with a stent, which not only closed the endoluminal rupture of the blood vessel but also maximized the expansion of the compressed true lumen. At the same time, the false lumen was squeezed and eliminated, which promoted reattachment of the torn vessel wall, thereby completing the reconstruction of the vessel wall. However, the recovery time of the true lumen was longer than that of patients undergoing hybrid surgery. An et al.<sup>17</sup> demonstrated that the elephant trunk procedure does not close the descending aortic rupture, resulting in continuous opening of the false lumen and expansion of the thoracoabdominal aorta. One-stop hybrid surgery for the treatment of Stanford type B aortic dissection involving the distal aortic arch effectively promotes occlusion of the false lumen and prevents two-stage surgery, thereby improving the long-term effects of surgery.

### *Limitations*

In addition to the need for a “one-stop” hybrid surgical room, hybrid surgery

requires the surgical team to master specific surgical and interventional techniques. The hybridization technique for the treatment of complex Stanford type B aortic dissection requires partial or complete blockage of the brachiocephalic trunk, and the variation rate of the circle of Willis is 50%. Therefore, preoperative cerebrovascular CTA examination is required to ensure that the left and right cerebral vascular collateral circulation are sufficient and thus avoid cerebrovascular accidents and hemiplegia caused by intraoperative cerebral hypoxia. The femoral artery of patients with complex Stanford type B aortic dissection may be affected; therefore, femoral arterial cannulation is not appropriate during surgery. Replacement of the entire aortic arch plus placement of a distal descending aortic stent can prevent all of these risks. At present, there is no uniform standard for the treatment of or indications for complex aortic arch dissection in China. Therefore, additional studies on this technique are required to refine the anatomical classification of dissection lesions.

### **Conclusion**

In patients with complex Stanford type B aortic dissection, one-stop hybrid surgery effectively alleviated the occlusion of the aortic dissection, prevented the need for additional surgery, and expanded the indications for covered-stent endovascular repair.

### **Declaration of conflicting interest**

The authors declare that there is no conflict of interest.

### **Funding**

This research received no specific grant from any funding agency in the public, commercial, or not-for-profit sectors.

## References

1. Ochoa Char CI, Zafar MA, Velasquez C, et al. Complex two-stage open surgical repair of an aorto-esophageal fistula after thoracic endovascular aortic repair. *J Vasc Surg Cases Innov Tech* 2019; 5: 261–263.
2. Burke CR and Bavaria JE. The role of thoracic endovascular repair in chronic type B aortic dissection. *Semin Thorac Cardiovasc Surg*; Epub ahead of print 4 Sep 2019. DOI: 10.1053/j.semtcvs. 2019.08.010.
3. Miura S, Kurimoto Y, Maruyama R, et al. Thoracic endovascular aortic repair on zone 2 landing for type B aortic dissection. *Ann Vasc Surg* 2019; 60: 120–127.
4. Nauta FJ, Trimarchi S, Kamman AV, et al. Update in the management of type B aortic dissection. *Vasc Med* 2016; 21: 251–263.
5. Mitchell RS, Ishimaru S, Ehrlich MP, et al. First International Summit on Thoracic Aortic Endografting: roundtable on thoracic aortic dissection as an indication for endografting. *J Endovasc Ther* 2002; 2: 98–105.
6. Piffaretti G, Grassi V, Lomazzi C, et al. Thoracic endovascular stent graft repair for ascending aortic diseases. *J Vasc Surg* 2019; 70: 1384–1389.
7. Chait J, Kibrik P, Alsheekh A, et al. Descending thoracic endovascular aortic repair does not require cardiothoracic surgery support. *Vascular* 2019; 27: 448–450.
8. Uchida T and Sadahiro M. Thoracic endovascular aortic repair for acute aortic dissection. *Ann Vasc Dis* 2018; 11: 464–472.
9. Canaud L, Gandet T, Sfeir J, et al. Risk factors for distal stent graft-induced new entry tear after endovascular repair of thoracic aortic dissection. *J Vasc Surg* 2019; 69: 1610–1614.
10. Han X and Xu K. Endovascular stent-graft therapy for type B aortic dissection: a meta-analysis. *J Interv Radiol* 2011; 7: 530–533. <http://cjir.papernonce.org/oa/DArticle.aspx?type=view&id=110707>
11. Yu J, Huang L, Jiang S, et al. Analysis of thoracic aortic stent-graft placement in 108 cases with insufficient proximal anchor area. *Chinese Journal of Interventional Cardiology* 2010; 3: 121–124. [http://caod.oriprobe.com/articles/24230329/Analysis\\_of\\_thoracic\\_aortic\\_stent\\_graft\\_placement\\_in\\_108\\_cases\\_with\\_in.htm](http://caod.oriprobe.com/articles/24230329/Analysis_of_thoracic_aortic_stent_graft_placement_in_108_cases_with_in.htm)
12. Sepehripour AH, Ahmed K, Vecht JA, et al. Management of the left subclavian artery during endovascular stent grafting for traumatic aortic injury—a systematic review. *Eur J Vasc Endovasc Surg* 2011; 41: 758–769.
13. Wei Y, Chang Q, Yu C, et al. One-stage hybrid operation for treating descending aortic diseases involving distal aortic arch. *Chinese Journal of Clinical Thoracic and Cardiovascular Surgery* 2011; 2: 99–103. [http://caod.oriprobe.com/articles/26713880/One\\_Stage\\_Hybrid\\_Operation\\_for\\_Treating\\_Descending\\_Aortic\\_Diseases\\_Inv.htm](http://caod.oriprobe.com/articles/26713880/One_Stage_Hybrid_Operation_for_Treating_Descending_Aortic_Diseases_Inv.htm)
14. Amabile P, Grisoli D, Giorgi R, et al. Incidence and determinants of spinal cord ischaemia in stent-graft repair of the thoracic aorta. *Eur J Vasc Endovasc Surg* 2008; 35: 455–461.
15. Zhao HP, Zhu JM, Ma WG, et al. Total arch replacement with stented elephant trunk technique for acute type B aortic dissection involving the aortic arch. *Ann Thorac Surg* 2012; 93: 1517–1522.
16. Chino S, Kato N, Nakajima K, et al. Thoracic endovascular aortic repair for the treatment of ruptured acute type B aortic dissection. *Jpn J Radiol* 2019; 37: 321–327.
17. An Z, Tan MW, Song ZG, et al. Retrograde type A dissection after ascending aorta involved endovascular repair and its surgical repair with stented elephant trunk. *Ann Vasc Surg* 2019; 58: 198–204.