



# Primary ovarian rhabdomyosarcoma coexisting with Pseudo-Meigs' syndrome in a young patient: a case report and brief literature review

Genç bir hastada Pseudo-Meigs' sendromu ile birlikte olan primer over rabdomiyosarkomu: olgu sunumu ve kısa dizin taraması

Şule Gökçe<sup>1</sup>, Zafer Kurugöl<sup>2</sup>, Elvin Orujov<sup>2</sup>, Gürdeniz Serin<sup>3</sup>

<sup>1</sup>Department of Pediatrics, General Pediatrics Unit, Ege University Faculty of Medicine, İzmir, Turkey

<sup>2</sup>Department of Pediatrics, Ege University Faculty of Medicine, İzmir, Turkey

<sup>3</sup>Department of Pathology, Ege University Faculty of Medicine, İzmir, Turkey

## The known about this topic

Primary rhabdomyosarcoma is one of the malign soft tissue sarcomas of childhood originating from embryonic mesenchyme. Primary ovarian rhabdomyosarcoma is an extremely rare malignancy in pediatric. Primary ovarian rhabdomyosarcoma might be present with different manifestations.

## Contribution of the study

It is the first patient of the literature with primary ovarian rhabdomyosarcoma presenting with pseudo-Meigs' syndrome. Isolated ascites might be associated with intra abdominal malignancies. Pseudo-Meigs' syndrome secondary to primary ovarian rhabdomyosarcomas should be considered in the differential diagnosis of massive ascites accompanied by pleural effusion.

## Abstract

Primary rhabdomyosarcoma is one of the malignant soft tissue sarcomas of childhood originating from embryonic mesenchyme. The tumor can occur in the head, neck region, and limbs, and genitourinary system. Primary ovarian rhabdomyosarcoma is an extremely rare malignancy with a few documented pediatric patients in the literature. Pseudo-Meigs' syndrome is a type of Meigs' syndrome that is usually associated with other benign ovarian tumors or any other type of malignant tumors. It is a rare condition characterized by ascites, pleural effusion, benign ovarian tumors or fibroma-like tumors, and resolution of ascites and pleural effusion after the removal of the tumor. A patient of Asian origin came to our clinic with symptoms of mild dyspnea, and gradually increasing abdominal swelling. Magnetic resonance imaging scans indicated masses with solid cystic components on both ovaries with a suspicion of malignancy, showing bilateral pleural effusion and massive ascites. This is the first reported case of a pure primary ovarian rhabdomyosarcoma associated with a Pseudo-Meigs syndrome in a young girl.

**Keywords:** First case, Meigs' syndrome, primary ovarian rhabdomyosarcoma, pseudo-Meigs' syndrome

## Öz

Rabdomiyosarkom, embriyonik mezenşimden köken alan çocukluk çağı malin yumuşak doku sarkomlarından biridir. Tümör baş, boyun bölgesinde ve ekstremitelerde ve genitouriner sistemde yer alabilir. Primer ovaryan rabdomiyosarkom, oldukça ender görülen ve dizinde çok az bildirilmiş çocuk hastası olan bir malinedir. Pseudo-Meigs' sendromu, genellikle diğer benin yumurtalık tümörleri ya da başka herhangi bir malin tümör türü ile ilişkili olan bir Meigs' sendromu tipidir. Asit, pleval efüzyon, benign over tümörleri ya da fibroma benzeri tümörler ve tümör çıkarıldıktan sonra gerileyen asit ve pleval efüzyon ile belirgin ender bir durumdur. Kliniğimize Asya kökenli bir hasta hafif nefes darlığı ve giderek belirginleşen karın şişliği yakınmaları ile başvurdu. Manyetik rezonans görüntüleme ile malinite ile uyumlu olan her iki overde de solid kistik komponentli kitle, bilateral pleval efüzyon ve masif asit saptandı. Bu olgu, Pseudo-Meigs sendromunun eşlik ettiği saf primer over rabdomiyosarkomu saptanmış ilk olgudur.

**Anahtar sözcükler:** İlk olgu, Meigs' sendromu, primer ovaryan rabdomiyosarkom, Psödo-meigs' sendromu

**Cite this article as:** Gökçe Ş, Kurugöl Z, Orujov E, Serin G. Primary ovarian rhabdomyosarcoma coexisting with Pseudo-Meigs' syndrome in a young patient: a case report and brief literature review. *Turk Pediatri Ars* 2020; 55(2): 203-6.

**Corresponding Author/Sorumlu Yazar:** Şule Gökçe E-mail/E-posta: sule.gokce@ege.edu.tr

**Received/Geliş Tarihi:** 06.06.2018 **Accepted/Kabul Tarihi:** 17.12.2018

©Copyright 2020 by Turkish Pediatric Association - Available online at [www.turkpediatriarsivi.com](http://www.turkpediatriarsivi.com)

©Telif Hakkı 2020 Türk Pediatri Kurumu Derneği - Makale metnine [www.turkpediatriarsivi.com](http://www.turkpediatriarsivi.com) web adresinden ulaşılabilir.

DOI: 10.14744/TurkPediatriArs.2019.82474

**OPEN ACCESS** This work is licensed under a Creative Commons Attribution-NonCommercial 4.0 International License.

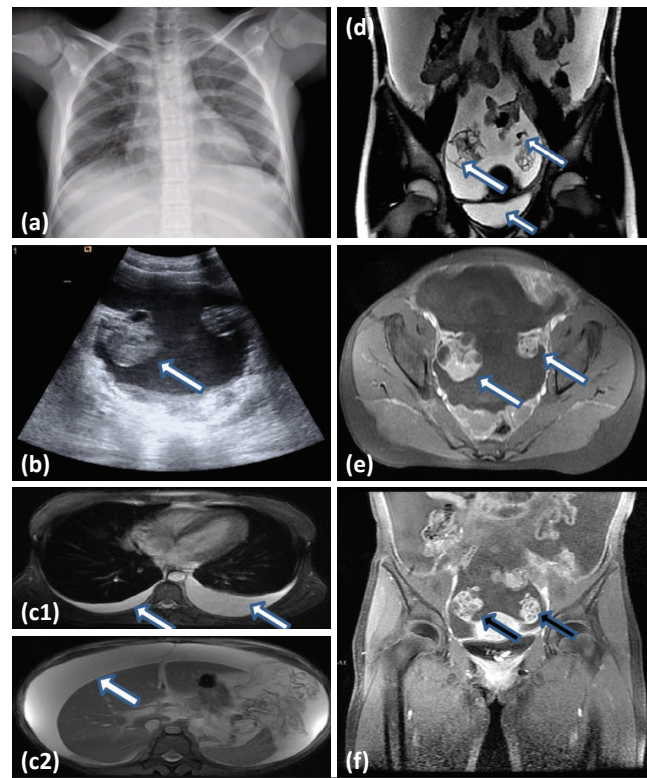


## Introduction

Meigs' syndrome is a clinical condition defined as a tetrad of ascites, pleural effusion, benign ovarian tumors or fibroma-like tumors, and spontaneous disappearance of fluids after surgery of the tumor. It was first published in a report by Meigs and Cass of seven cases presenting with these signs, and was then was termed as Meigs' syndrome by Rhodas and Terrell in 1937 (1, 2). Pseudo-Meigs' syndrome is a subform of Meigs' syndrome that usually has a relation with other benign tumors of the ovary, namely struma ovarii, hemangioma, para-ovarian fibroma or any other type of malignant tumors including ovarian carcinoma, papillary ovary and the fallopian tube carcinoma, which can display similar characteristic signs (3–5). Primary rhabdomyosarcoma is one of the pediatric malignant soft tissue sarcomas of childhood originating from embryonic mesenchyme, and has the tendency to settle on the head, neck region, and limbs, and also the genitourinary system. Primary ovarian rhabdomyosarcoma is an extremely rare malignancy in children. To the best of our knowledge, pseudo-Meigs' syndrome has never been described in a pediatric case of primary ovarian rhabdomyosarcoma. In this report, a young girl with pseudo-Meigs' syndrome diagnosed with primary ovarian rhabdomyosarcoma is presented.

## Case

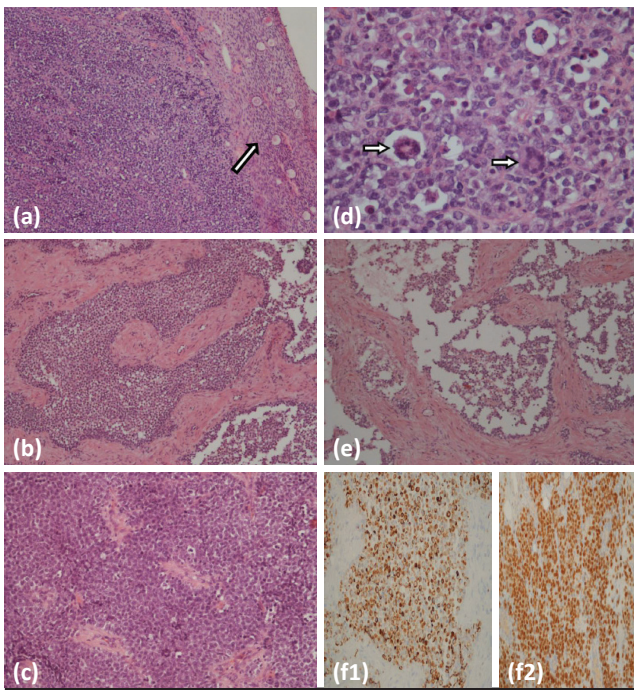
A 12-year-old girl was admitted to our department with mild dyspnea and 5-day history of abdominal swelling. There was no family history nor any disease or past history of drug use, toxin exposure, and immunization. On admission, her physical examination parameters were as follows: weight 39 kg (50 percentile), height 143 cm (25 percentile), temperature 37.2°C, heart rate 110/min, and blood pressure 96/54 mm Hg. An abdominal examination revealed severe distension caused by ascites without abdominal masses. There was no edema in the extremities. In a bilateral lung examination, decreased breath sound was heard in the lower lobes and there was dullness on percussion bilaterally in basal segments. Her routine laboratory values, serum carcinoembryonic antigen (CEA-19), alpha-fetoprotein, and quantitative  $\beta$  human chorionic gonadotropin, were within the normal range. However, elevated serum levels of CA-125 of 308 U/mL (normal: <35.0 U/mL) and lactic dehydrogenase [770 U/L (normal: 122-234 U/L)] were detected. Direct posteroanterior lung radiography revealed a mild bilateral pleural effusion. Abdominal and pelvic ultrasound demonstrated massive ascites of 9 cm at the deepest point, and there was a 2.5x2-cm mass on the posterior of the right ovary. Magnetic resonance imaging (MRI) performed on day 8 post onset of her symptoms showed bilateral pleural effusion, mas-



**Figure 1.** (a) Chest X-ray showed bilateral mild pleural effusion on admission. (b) Pelvic ultrasonography revealed a mass of 2.5x2 cm size on the posterior of right ovary (white arrow). (c1, c2) Preoperative magnetic resonance imaging showing bilateral hydrothorax (c1) and massive ascites in axial images (c2) (white arrows). (d) Coronal fat-suppressed T1-weighted image showing the hyperintense right and left ovarian mass contained solid and cystic components (arrows) and ascites in the pelvis (arrow) (right ovary 32x45 mm, left ovary 14x12 mm). (e) Axial view revealed masses on the both ovaries contained solid and cystic components (white arrows); F: T2-weighted sequence of coronal image showing masses on the both ovaries contained solid and cystic components (black arrows)

sive ascites, and masses with solid cystic components on both ovaries, 32x45 cm on the right, and 14x12 cm on the left, which were primarily thought to be malignant (Fig. 1), and also paraaortic-paracaval lymphadenopathies and implantation masses compatible with peritonitis carcinomatosa were observed.

An explorative laparotomy was arranged for diagnostic and therapeutic purposes. During the laparotomy, a 3x1x3-cm solid mass originating from the right ovary, and a 0.9x1x1-cm solid mass on the left ovary, both containing cystic and solid areas, were observed with approximately 6700 mL of serous ascites. The uterus and both adnexa appeared not to have pathologic appearance. The right



**Figure 2.** (a) Tumor infiltration in Ovary (Normal ovary is seen on the right side, white arrow). This ovary shows the alveolar pattern of spindle cells on the left (H&E 100x). (b) Tumor cells that have lost cellular cohesion between fibrovascular septations and septations surrounded by single row cells (H&E 100x) (Omentum). (c) Solid areas (H&E 200x) produced by round narrow cytoplasmic tumor cells (Omentum). (d) Multinuclear tumor giant cells (marked with arrow) (H & E 400x) (Omentum). (e) Characteristic alveolar growth pattern. Discohepatic neoplastic cells in alveolar like spaces (H&E 100x) (Omentum). (f1) Cytoplasmic desmin positivity (200x) in tumor cells in the immunohistochemical examination (Omentum). (f2) Nuclear myogenin positivity (200x) in tumor cells in the immunohistochemical examination (Omentum)

ovary tumor was distinguished, and a bilateral ovarian mass were removed for biopsy. Omentectomy was performed and sent for frozen section examination. A metastasis-like involvement was observed on the left lobe of the liver as well as an involvement in the retroperitoneal lymph nodes. From the frozen section of the ovary and omentum, the mass was diagnosed as pure ovarian rhabdomyosarcoma. A retroperitoneal lymph node was also enucleated and together with the right ovary, cyst aspiration fluid was sent to the cytology laboratory. Pathologic evaluation of the ovarian tumor revealed an alveolar pattern (>50 percent alveolar component, predominantly) (Fig. 2). Postoperatively, the pleural effusion spontaneously resolved in a week. Finally, the diagnosis was pure ovarian alveolar rhabdomyosarcoma, which had metastases of liver, omentum, presenting with pseudo-Meigs' syndrome

(Stage 4, group IV alveolar rhabdomyosarcoma). The patient was referred to the oncology department and was started on chemotherapy. Informed consent was obtained from patients' parents who participated in this case.

### Discussion

We described a case of a previously healthy young girl who developed pseudo-Meigs' syndrome secondary to rhabdomyosarcoma of the ovary. Pseudo-Meigs' syndrome is a rare condition including fluids in the peritoneal and pleural cavity, which is improved after the removal of the mass described in both benign and malignant ovarian tumors. Meigs' syndrome is a condition characterized by a postoperative resolution of ascites and pleural effusions during ovarian fibromas, fibroma-thecomas, and fibroma-like tumors (thecoma, granulosa cell tumor, or Brenner tumor) (6). The prevalent togetherness of pseudo-Meigs' syndrome and ovarian tumors, namely, endometrioid adenocarcinoma and germ cell tumor is commonly known. As seen in the literature, pseudo-Meigs syndrome is observed in both malignant and benign pathologies of the ovary, and rarely in metastases of the ovary. However, pseudo-Meigs' syndrome associated with primary rhabdomyosarcoma of the ovary has never been described to date.

Primary ovarian rhabdomyosarcoma is an extremely rare malignancy with a few documented pediatric patients in the literature. The review of Guérard et al. (7) reported 14 cases including three pediatric patients. Nielsen et al. (8) reported 13 patients with primary ovarian rhabdomyosarcoma who were admitted to hospital with abdominal pain and abdominal swelling. Two patients were reported by Randolph (9), one of them, a 13-year-old girl who presented with difficulty in breathing and emesis, was diagnosed as having alveolar rhabdomyosarcoma of the right ovary with metastases to the colon. The other was a female pediatric patient with a 1-month history of gradually increasing abdominal girth and abdominal pain that rapidly progressed, causing anorexia, nausea, weight loss, and non-bilious emesis.

In the literature, case presentations and studies of Meigs' and pseudo-Meigs' syndromes are more prevalent in female adults. Despite the fact that several cases of Meigs' syndrome have been reported in children, there are very few reports of pseudo-Meigs' syndrome in childhood, and such a case was submitted by Wolff et al. (10). Similar to the present case, the pleural and peritoneal fluids of our case spontaneously disappeared after surgery.

When we examined the literature in terms of pure ovarian rhabdomyosarcoma and pseudo-Meigs' syndrome,

no data were found. However, Randolph et al. (9) published case reports on two patients who were diagnosed as having primary ovarian rhabdomyosarcoma. One of the patients, a 6-year-old girl, presented with abdominal pain, pleural effusion, and increased girth around the abdomen. She was then diagnosed as having primary ovarian rhabdomyosarcoma. We think that this case may be incomplete malignant pseudo-Meigs' syndrome. The other case of Randolph et al. might be thought as pseudo-pseudo Meigs' syndrome due to the fact that the patient had systemic lupus erythematosus accompanied by ascitic fluid, but we do not know whether the ascites disappeared as a post-operative outcome or if pleural effusion was present. We did not think that our patient had SLE because she did not have classic SLE features.

We presented a case of an association between pseudo-Meigs' syndrome and rhabdomyosarcoma of the ovary. Pseudo-Meigs' syndrome is extremely rare in childhood. Primary ovarian rhabdomyosarcoma is also a rare condition during childhood. The coexistence of the two entities has never been published before. It is very important to consider pseudo-Meigs' syndrome secondary to primary ovarian rhabdomyosarcomas in the differential diagnosis of massive ascites accompanied by pleural effusion.

**Informed Consent:** Informed consent was obtained from patients' parents who participated in this case.

**Peer-review:** Externally peer-reviewed.

**Author Contributions:** Concept - Ş.G., Z.K., E.O., G.S.; Design - Ş.G.; Supervision - Ş.G., Z.K.; Materials - Ş.G., E.O.; Data Collection and/or Processing - Ş.G., E.O.; Analysis and/or Interpretation - Z.K., S.G.; Literature Review - Ş.G., Z.K.; Writing - Ş.G.; Critical Review - Z.K.

**Conflict of Interest:** No conflict of interest was declared by the authors.

**Financial Disclosure:** The authors declared that this study has received no financial support.

**Hasta Onamı:** Bilgilendirilmiş onam, bu olguya katılan hastaların ebeveynlerinden alınmıştır.

**Hakem Değerlendirmesi:** Dış bağımsız.

**Yazar Katkıları:** Fikir - Ş.G., Z.K., E.O., G.S.; Tasarım - Ş.G.; Denetleme - Ş.G., Z.K.; Malzemeler - Ş.G., E.O.; Veri Toplanması ve/veya İşlemesi - Ş.G., E.O.; Analiz ve/veya Yorum - Z.K., S.G.; Literatür Taraması - Ş.G., Z.K.; Yazıyı Yazan - Ş.G.; Eleştirel İnceleme - Z.K.

**Çıkar Çatışması:** Yazarlar çıkar çatışması bildirmemişlerdir.

**Mali Destek:** Yazarlar bu çalışma için mali destek almadıklarını beyan etmişlerdir.

## References

1. Meigs JV, Cass JW. Fibroma of the ovary with ascites and hydrothorax, with a report of seven cases. *Am J Obstet Gynecol* 1937; 33: 249–67.
2. Rhoads JE, Terrell AW. Ovarian fibroma with ascites and hydrothorax (Meigs' syndrome): report of a case. *JAMA* 1937; 109: 1684–7.
3. Kaneta Y, Nishino R, Asaoka K, Toyoshima K, Ito K, Kitai H. Ovarian hemangioma presenting as pseudo-Meigs' syndrome with elevated CA125. *J Obstet Gynaecol Res* 2003; 29: 132–5.
4. Chen FC, Fink RL, Jolly H. Meigs' syndrome in association with a locally invasive adenocarcinoma of the fallopian tube. *Aust N Z J Surg* 1995; 65: 761–2.
5. Krenke R, Maskey-Warzechowska M, Korczynski P, et al. Pleural effusion in Meigs' Syndrome-transudate or exudate?: Systematic review of the literature. *Medicine* 2015; 94: e2114.
6. Zannoni GF, Gallotta V, Legge F, Tarquini E, Scambia G, Ferrandina G. Pseudo-Meigs' syndrome associated with malignant struma ovarii: a case report. *Gynecol Oncol* 2004; 94: 226–8.
7. Guérard MJ, Arguelles MA, Ferenczy A. Rhabdomyosarcoma of the ovary: ultrastructural study of a case and review of literature. *Gynecol Oncol* 1983; 15: 325–39.
8. Nielsen GP, Oliva E, Young RH, Rosenberg AE, Prat J, Scully RE. Primary ovarian rhabdomyosarcoma: a report of 13 cases. *Int J Gynecol Pathol* 1998; 17: 113–9.
9. Cribbs RK, Shehata BM, Ricketts RR. Primary ovarian rhabdomyosarcoma in children. *Pediatr Surg Int* 2008; 24: 593–5.
10. Wolff AL, Ladd AP, Kumar M, Gunderman RB, Stevens J. Pseudo-Meigs syndrome secondary to ovarian germ cell tumor. *J Pediatr Surg* 2005; 40: 737–9.