



# Salvage of Exposed Groin Vascular Grafts with Early Intervention Using Local Muscle Flaps

Brian L. May, BS\*

Nicole A. Zelenski, MD\*

Sanjay V. Daluvoy, MD\*

Matthew W. Blanton, MD†

Cynthia K. Shortell, MD†

Detlev Erdmann, MD, PhD,  
MHSc\*

**Background:** Peripheral vascular surgery may be complicated by wound infection and potential graft exposure in the groin area. Muscle flap coverage of the graft has been promoted to address these wound complications. The authors present their findings regarding graft salvage rates and patient outcomes using local muscle flaps to address vascular graft complications of the groin.

**Methods:** Data were obtained by retrospective cohort study of patients who underwent a local muscle flap procedure by a single surgeon following vascular graft complication in the groin.

**Results:** Seventeen patients undergoing local muscle flap coverage of a vascular graft were reviewed. Six men and 9 women, 51–80 years old, were included in the study. Wound complications in the groin occurred anywhere from 3 days to 3.5 years following graft placement. Graft exposure was the most common presenting complication (14 of 17 patients). Muscle flap coverage occurred within 15 days of complication presentation in all patients (average, 6.4 days). Seven of the 15 patients experienced postoperative complications within 6 months of the procedure, most commonly wound dehiscence. However, analysis demonstrated that vascular grafts were successfully salvaged in 10 of the 17 patients (59%) over the course of follow-up (range, 104–1748 days). Average time to muscle flap coverage was 4.2 days in patients who retained the graft and 9.6 days in patients who ultimately lost their vascular graft.

**Conclusion:** The authors demonstrate improved vascular graft salvage rate when local muscle flap procedure is performed early after initial wound complication presentation. (*Plast Reconstr Surg Glob Open* 2015;3:e514; doi: 10.1097/GOX.0000000000000480; Published online 22 September 2015.)

From the \*Division of Plastic, Reconstructive, Maxillofacial and Oral Surgery, Department of Surgery, Duke University Medical Center, Durham, N.C.; and †Division of Vascular Surgery, Department of Surgery, Duke University Medical Center, Durham, N.C.

Received for publication December 11, 2014; accepted July 13, 2015.

Presented at the North Carolina Society of Plastic Surgeons Annual Meeting, October 4–7, 2012, White Sulphur Springs, W.Va., and the Southeastern Society of Plastic and Reconstructive Surgery Annual Scientific Conference of 2013, June 1–5, 2013, Bonita Springs, Fla.

Copyright © 2015 The Authors. Published by Wolters Kluwer Health, Inc. on behalf of The American Society of Plastic Surgeons. All rights reserved. This is an open-access article distributed under the terms of the Creative Commons Attribution-Non Commercial-No Derivatives License 4.0 (CCBY-NC-ND), where it is permissible to download and share the work provided it is properly cited. The work cannot be changed in any way or used commercially.

DOI: 10.1097/GOX.0000000000000480

Vascular graft infections and graft exposure after peripheral bypass surgery remain significant causes of morbidity after peripheral vascular surgery.<sup>1</sup> Vascular graft infections result either directly from bacterial seeding during the surgical procedure or indirectly from local and/or hematogenous spread.<sup>2</sup> The incidence of infection has been reported to range from 0.7% to 10% and is especially high following postoperative exposure of the femoral vessels in the groin.<sup>3–5</sup> The femoral or groin region is commonly involved, as it is a frequent site of peripheral bypass grafting for lower limb revascularization.<sup>6</sup> The underlying mechanism of groin-specific wound infections in proximity to vascular grafts has been attributed to one or a combination of the

**Disclosure:** The authors have no financial interest to declare in relation to the content of this article. The Article Processing Charge was paid for by the authors.

following factors: poor local blood supply, lymphatic disruption, seroma formation, devitalized fat and/or skin maceration, and/or difficulty in maintaining wound care in the area.<sup>7</sup>

Graft exposure, one possible sequela of wound infection, raises the risk of graft failure/removal with subsequent limb loss at rates up to 70% and increases the risk of mortality.<sup>6,8</sup> Although proximal graft infections lead to increased mortality, distal graft infections are more likely to lead to amputation.<sup>6</sup> The critical elements to graft and limb survival are the depth of the affected wound and whether the graft itself is involved.<sup>9</sup>

Traditionally, treatment for exposed or infected grafts was radical, with vascular surgeons performing complete excision and wide debridement followed by extra anatomical bypass whenever possible. However, these procedures carried high limb loss rates of 8–52% and mortality rates of 4–36%.<sup>6</sup> In 1963, Carter et al<sup>10</sup> proposed aggressive wound debridement and coverage of the infected graft with clean dressings along with topical and systemic antibiotics. However, Calligaro et al<sup>11</sup> later demonstrated that this method of graft salvage using healing by secondary intention resulted in protracted wound healing and increased morbidity including thrombosis, superinfection, and exsanguination due to disrupted anastomosis in comparison to coverage with muscle flaps. The use of a muscle flap for secondary reconstruction, introduced in the 1980s and recently popularized, addressed many of these associated problems. This technique uses vascularized tissue, such as the sartorius, rectus femoris, rectus abdominis, or gracilis muscle, to cover the wound bed. Vascularized tissue increases local tissue oxygenation, augments immune cell and antibiotic delivery, and obliterates dead space in which seroma or hematoma can form.<sup>6</sup> The use of a muscle flap in the management of an infected vascular graft has shown improved outcomes by reducing amputation rates to below 30% and mortality to below 14%.<sup>11,12</sup>

Despite these improvements, there are still no clear or consistent guidelines for the management of vascular graft infections and exposure. The purpose of this study was to review a single surgeon's experience with muscle flap coverage for management of peripheral vascular graft infections of the groin to identify factors associated with improved outcomes.

## METHODS

Approval for this study was obtained through the Duke Institutional Review Board. Waiver of patient consent was also obtained as the study posed limited risk to patient confidentiality, and patient care would

be unaffected by the results of the study. Retrospective data collection and analysis from a medical center over a 4-year period (2009–2012) was performed. Inclusion criteria encompassed all patients who underwent muscle flap coverage performed by a single surgeon (D.E.) for exposed or infected vascular grafts. The data were extracted from operative notes, daily progress notes, history and physical examination at the time of admission, and discharge summaries.

Preoperative data including patient demographics, comorbidities, risk factors for poor healing (smoking, nutrition status, and diabetes), type of initial bypass procedure, interval between bypass and exposure/infection, presenting symptoms, associated laboratory results, and any initial mitigating treatments (such as vacuum-assisted closure or wound care) were obtained. The operative data obtained included time from recognized exposure/infection to flap procedure, type of reconstructive procedure including muscle flap choice, and organism cultured from the wound. The primary outcome evaluated was the fate of vascular graft. Other secondary postoperative outcomes evaluated were postflap complications, length of hospital stay, and fate of the affected limb. Statistical analysis was performed using Microsoft Excel 2011 (Microsoft Corp.) and JMP Pro 11 (SAS Institute Inc.).

Graft infections were defined as outlined by Szilagyi et al<sup>9</sup> in 1972, in which infected wounds were grade I (infection involves the dermis only), grade II (infection extends into subcutis but does not invade vascular graft), or grade III (vascular graft involved in the infection). The interval between initial vascular surgery and infection was categorized into 3 groups: (1) acute, defined as less than 1 month; (2) subacute, defined as between 1 and 3 months; and (3) delayed, defined as infection lasting 3 months.

## RESULTS

For this retrospective review, a total of 17 patients ( $n = 17$ ) with exposed and/or infected femoral vascular grafts were identified for review. Patients' age ranged from 51 to 80 years, with an overall mean of 64.5 years (Table 1). The patients in this series had on average 3.3 significant comorbidities (range, 1–5). Hypertension ( $n = 15$  patients), diabetes ( $n = 7$ ), coronary artery disease ( $n = 7$ ), and hyperlipidemia ( $n = 5$ ) were the most frequent associated comorbidities. Ten of the 17 patients were active smokers at the time of the initial procedure.

The 17 original vascular procedures performed included femoral-tibial bypass, femoral-femoral bypass, femoral-popliteal bypass, femoral arteriovenous fistula, aortobifemoral bypass, and femoral endarterectomy. Twelve of these procedures used

**Table 1. Patient Demographics**

Patient	Age	Sex	Vascular Graft	Graft Material	Flap Type	Time from Graft to Dehiscence (d)	Time from Dehiscence to Flap (d)	Odds Ratio	Culture Results	Infection*	Graft Fate	Limb Fate
1	74	Male	Femorotibial	Dacron and PTFE	Gracilis	3	15	VRE		Acute	Excised	AKA
2	75	Female	Femorofemoral	PTFE	Sartorius	101	13	—		—	Salvaged	
3	63	Female	Femoropopliteal	Dacron	Gracilis	7	3	<i>Proteus mirabilis</i>		Acute	Salvaged	
4	68	Female	Femoral AV fistula	Gortex	Rectus femoris	963	2	MRSA		Chronic	Salvaged	
5	51	Female	Aortobifemoral	Dacron and saphenous	Sartorius	22	7	<i>Escherichia coli</i>		Acute	Excised	AKA
6	66	Male	Femoral endarterectomy	Dacron	Rectus femoris	5	12	—		—	Excised	AKA
7	62	Male	Aortobifemoral	Dacron	Sartorius	9	6	Coagulase-negative <i>Staphylococcus</i>		Acute	Excised	
8	72	Female	Aortobifemoral	Dacron	Sartorius	7	1	Coagulase-negative <i>Staphylococcus</i>		Acute	Salvaged	
9	54	Male	Femorofemoral with profunda to popliteal	PTFE and saphenous	Sartorius	4	3	—		—	Salvaged	
10	80	Female	Femoral endarterectomy	Bovine pericardium	Sartorius	7	5	—		—	Salvaged	
11	52	Female	Aortobifemoral	Dacron	Sartorius	12	5	<i>E. coli</i> , Diphtheroid, <i>Streptococcus viridans</i>		Acute	Excised	AKA
12	67	Female	Femorofemoral	PTFE	Rectus femoris	1251	15	<i>Candida tropicalis</i>		Chronic	Excised	
13	73	Male	Aortobifemoral	Dacron	Sartorius	43	7	Acinetobacter, MRSA		Subacute	Excised	
14	72	Male	Emergent aortobifemoral	Dacron	Sartorius	24	2	<i>Enterobacter cloacae</i> , mixed Gram +/-		Acute	Salvaged	
15	65	Female	Femorotibial	Saphenous	Rectus femoris	11	2	<i>P. mirabilis</i> , <i>Enterococcus</i>		Acute	Salvaged	
16	57	Male	Femorofemoral with femoropopliteal	PTFE and saphenous	Gracilis	18	7	<i>Pseudomonas aeruginosa</i>		Acute	Salvaged	BKA
17	62	Male	Femoral endarterectomy	Bovine pericardium	Sartorius	11	4	<i>Klebsiella pneumoniae</i>		Acute	Salvaged	

\*Acute, <1 month; subacute: 1–3 months; delayed, >3 months.

AKA, Above Knee Amputation; AV, Arteriovenous; BKA, Below Knee Amputation; MRSA, Methicillin Resistant *Staphylococcus aureus*; PTFE, Polytetrafluoroethylene; VRE, Vancomycin Resistant *Enterococcus*.



**Table 2. Clinical Findings at Presentation**

Signs/Symptoms	n (%)
Exposed graft	14 (82.4)
Leukocytosis	8 (47.1)
Fevers	0 (0.00)
Draining wound	3 (17.6)
Groin hematoma	2 (11.8)
Wound dehiscence	1 (5.9)
Perigraft fluid collections	1 (5.9)

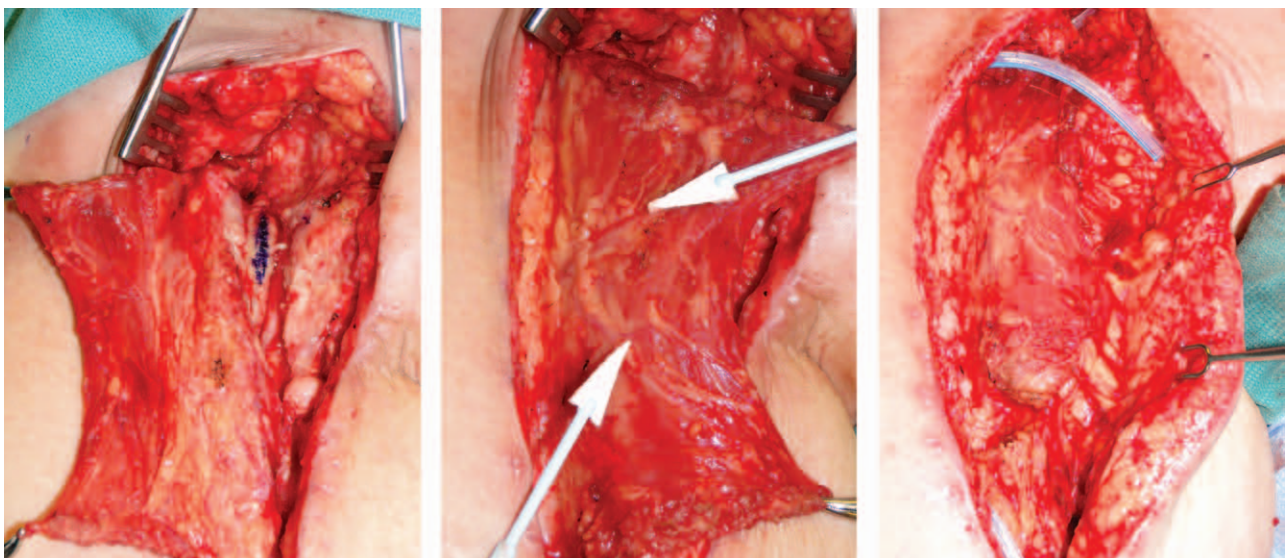
prosthetic grafts, whereas 2 used an autogenous graft and 3 relied on combinations of prosthetic and autogenous grafts (Table 2). There were 8 male and 9 female patients requiring muscle flap coverage, and the mean follow-up period was 804 days (range, 104–1748; median, 910).

The timing of wound complication and/or graft exposure occurred from 3 days to 3.5 years after initial vascular surgery procedure. An exposed graft ( $n = 14$ ) was the most common presenting sign (Table 2). Graft exposure was defined by either visible graft at the wound base or wound dehiscence with tunneling tract to the graft. Five patients were found to have decreased prealbumin levels at the time of graft complication presentation. Decreased prealbumin levels were interpreted as subadequate nutrition status in these patients and efforts were made to improve the nutritional deficits. Thirteen patients had positive intraoperative wound cultures, and a majority of these infections ( $n = 10$ ) presented acutely within 1 month from the original procedure. There was a broad spectrum of pathogens among the culture-positive patients, which included *Proteus mirabilis* ( $n = 2$ ), *Escherichia coli* ( $n = 2$ ), coagulase-

negative *Staphylococcus* ( $n = 2$ ), *Enterococcus* ( $n = 2$ ), *Klebsiella pneumoniae* ( $n = 1$ ), and *Pseudomonas aeruginosa* ( $n = 1$ ) (Table 1). In all cases, the vascular graft was initially retained and muscle flap coverage was performed.

Wound and graft coverage with muscle flap was performed in all 17 cases within 15 days of wound breakdown (mean = 6.4 days). These muscle flaps included the use of sartorius ( $n = 10$ ), rectus femoris ( $n = 4$ ), and gracilis flaps ( $n = 3$ ). Muscle flap selection was performed by the primary surgeon and was based on anatomic considerations regarding wound location, size of exposure, and available blood supply (evaluated by prior vascular studies). Example of graft coverage using a sartorius flap can be seen in Figure 1. With the sample size available, the type of flap had no significant impact on long-term outcome (Table 3). Ten of 17 patients had initial treatment before definitive muscle flap coverage. The remaining 7 patients underwent muscle flap coverage as the primary treatment upon presentation of graft complication. These treatments included irrigation and debridement (I&D), incisional negative pressure wound therapy (NPWT), I&D with NPWT, or simple wound packing. The average time to muscle flap coverage was 4.2 days in patients who retained their graft and 9.6 days in patients in whom the graft was later removed ( $P = 0.009$ , single-tailed Wilcoxon rank-sum test) (Fig. 2).

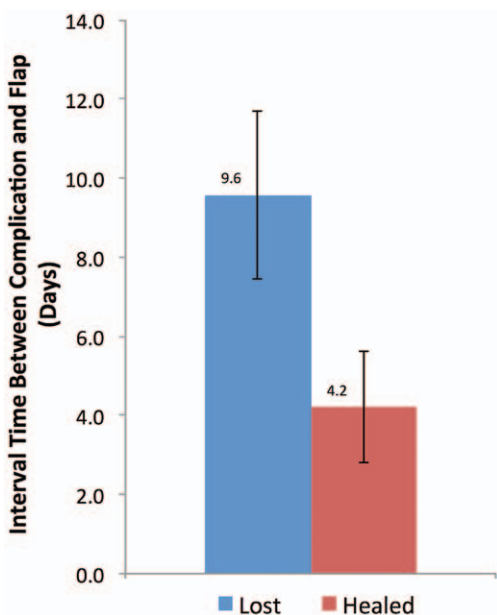
The average length of hospital stay after muscle flap procedure was 10.7 days (range, 5–29). There were no mortalities within the 30-day postoperative period; however, there were 2 patient deaths in the long-term follow-up period from unrelated causes.



**Fig. 1.** Example of sartorius flap coverage of an exposed groin graft. A, Exposed graft visible at the base of incision. B, Sartorius muscle flap exposed with vascular pedicles visible. C, Completed flap in place covering vascular graft.

**Table 3. Flap Type and Graft Salvage Rate**

Flap Type (n)	Salvage Rate (%)
Sartorius (10)	60
Gracilis (3)	67
Rectus femoris (4)	50
Overall (17)	59



**Fig. 2.** Time from vascular graft complication to muscle flap surgery in days. Grafts ultimately resulting in excision trended toward longer delay to muscle flap coverage than those ultimately salvaged ( $P = 0.009$ ).

At the 6-month follow-up, there were 9 postoperative complications in 7 patients receiving muscle flap surgery. There were 3 instances of postoperative wound dehiscence ( $n = 3$ ), 3 instances of infection ( $n = 3$ ), and 3 instances of hematoma/fluid accumulation ( $n = 3$ ). One case of dehiscence was treated successfully with negative pressure therapy, one required multiple surgical debridement procedures, and one resulted in acute infection, graft loss, and amputation in the acute setting. In the 6-month follow-up, this was the only instance of graft loss.

Overall, the vascular graft was successfully retained in 10 of the 17 patients (59%) and limb preserved in 12 (71%) for the duration of this study (follow-up from 3.4 to 57 months). Two of the 5 patients experiencing limb amputation experienced complications following further vascular interventions greater than 1 year following muscle flap coverage for the initial graft infection and were unrelated to initial flap failure. Only one patient of the 5 underwent below knee amputation due to ischemia of the foot before muscle flap coverage of the vascular graft. This patient experienced no further complications, and the

graft was successfully salvaged. After 1-year follow-up, the vascular graft was successfully retained in 15 of the 17 patients (88%), and limb preservation was present in 14 of the 17 patients (82%).

Seven of the vascular grafts were excised due to infection, wound dehiscence, an instance of graft blow-out, and an instance of spontaneous occlusion leading to the overall salvage rate of 59%. Five of the 7 patients who lost their graft were actively smoking at the time of the muscle flap surgery. The remaining 2 patients had 60 and 80 pack-year histories respectively, but had reported quitting before initial vascular graft procedure.

One of these 7 patients suffered graft loss acutely when the muscle flap reconstruction was complicated 2 weeks postoperatively with a lymphatic fistula. This progressed to an infection, and despite multiple attempts to salvage the graft, it was eventually removed and subsequent amputation was required. The other 6 grafts were lost 9 months to 2 years post muscle flap procedure.

## DISCUSSION

A retrospective review of a single surgeon's experience at this institution reveals successful management of exposed/infected vascular grafts with a local muscle flap. Muscle flaps with healthy vascularized tissue provide bulk to obliterate dead space, increase oxygenated blood and antibiotic flow to infected areas, and have been shown to improve healing time and lower bacterial counts.<sup>13</sup> The timing between graft infection presentation and muscle flap coverage seems to be an important predictor of outcome.

The data from this study demonstrate that performing early muscle flap coverage for exposed, infected vascular grafts improves the rate of vascular graft salvage. Conversely, it was found that delay in treatment is associated with higher graft loss rates. The 7 patients who experienced graft loss had a mean 9.6-day interval between presentation of groin wound complication and definitive muscle flap intervention. Six of these 7 patients underwent multiple I&D, NPWT, or combination therapies before muscle flap surgery. The seventh patient had primary treatment by muscle flap coverage, but flap coverage was delayed 7 days. Patients who retained their vascular graft had a significantly shorter mean interval of 4.2 days ( $P = 0.009$ ) from presentation to muscle flap surgery. Progressive wound contamination occurring during delayed flap coverage could be a contributing factor in this observation. It is possible that the graft wounds treated initially with definitive muscle flap coverage were more clean, thus leading to improved outcomes, whereas those undergoing interim treatments such as I&D were

significantly more contaminated and thus would have had poor outcomes even with early definitive muscle flap placement.

In the study by Fischer et al,<sup>14</sup> the use of prophylactic muscle flap coverage of vascular grafts was examined. It was demonstrated that patients undergoing prophylactic flap coverage at the time of vascular grafting have overall lower rates of wound complications compared with patients undergoing muscle flap coverage for salvage. Additionally, Fischer et al<sup>15</sup> have developed the Penn Groin Assessment Scale (PGAS) as a means of identifying patients in whom prophylactic muscle flap coverage is beneficial or necessary. The PGAS was developed reviewing 68 prophylactic flap procedures in comparison to 178 vascular graft procedures without muscle flap coverage. The authors of the aforementioned study have found that incidence of complication and patient care costs can be reduced when performing prophylactic muscle flaps in patient populations categorized as high risk according to the PGAS. This evidence suggesting the benefits of prophylactic muscle flap coverage further support the authors' conclusion in this study that early muscle flap coverage in patients with infected vascular grafts is exceedingly important if grafts are to be effectively salvaged.

In addition to early or prophylactic flap coverage, higher salvage rates have been reported in the setting of acute infection; however, 3 of the 4 vascular graft losses seen in this study were in patients presenting for muscle flap procedure with positive cultures within 1 month of original vascular surgery.<sup>16</sup> Williams et al<sup>17</sup> cautioned against the use of muscle flap in the case of Methicillin Resistant *Staphylococcus Aureus* due to high reinfection rates and mortality. However, a patient of this study with chronic Methicillin Resistant *Staphylococcus Aureus* infection was treated in this manner and the graft was successfully salvaged.<sup>17,18</sup> Similarly, Ali et al<sup>19</sup> suggest that perioperative mortality rates are increased in grafts infected with fungal organisms. A patient in this study suffered chronic *Candida tropicalis*, yet still maintained a patent, viable vascular graft and muscle flap.

A recent literature review examined numerous studies with an overall population of 223 patients with prosthetic vascular graft infections. In the review, 74% of these patients were primarily managed by graft conservation and muscle flap coverage. Of those who underwent graft conservation and muscle flap coverage, 12.2% of these patients ultimately lost their vascular graft and 13% required amputation.<sup>6</sup> The results presented here show a higher graft loss rate of 41%. The difference in graft loss rates can potentially be attributed to the highly variable follow-up periods in the review (from 5 months to 56

months; mean, 29 months). A study from this review that more closely mirrors the data presented here was a small institutional series that had a 50% graft loss with a mean follow-up of 23 months.<sup>6</sup>

NPWT has also been suggested as an alternative to flap coverage of infected vascular grafts.<sup>2</sup> In a large study of 44 patients with Szilagyi grade III infections, Mayer et al<sup>20</sup> reported vascular graft salvage rate of 84% at 4-year follow-up after surgical debridement and NPWT in conjunction with targeted antibiotics. Initially, for these patients, the NPWT systems were changed intraoperatively until granulation tissue was present covering the graft. Similarly, Dosluoglu et al<sup>21</sup> reported an 83% success rate in a similar patient population, although the follow-up in this study was of variable duration (2–72 months).

Despite the low apparent graft loss rate using NPWT, the length of hospital stay in these studies was much longer, with a mean of 32 days (range, 20–82 days), whereas this study demonstrated a mean hospital stay of 10.7 days (range, 5–29 days). In addition, these patients were exposed to multiple operations for NPWT device changes, which further increases the risk of reinfection or hemorrhage. There have been reports of significant bleeding with the use of NPWT to treat infected vascular grafts. Svensson et al<sup>22</sup> in 2008 reported 2 early bleeding and 3 late infected pseudoaneurysms in 33 patients with vascular groin infections being treated by NPWT. They concluded that vascular graft infections of the groin treated with NPWT were at greater risk of developing infection-related complications, which were associated with higher rates of amputation and death.

The type of muscle flap has also been shown to affect the overall salvage rate of infected vascular grafts. A 2013 study of 244 patients undergoing either prophylactic or salvage muscle flap coverage concludes that sartorius muscle flaps are better suited in prophylactic settings and salvage procedures in which the wound bed is small, whereas rectus femoris flaps are more appropriate for larger salvage operations.<sup>23</sup> The results of this study, however, demonstrate no significant difference in outcome or graft salvage rate between sartorius, gracilis, and rectus femoris flaps (Table 2).

Recently, studies have emerged that examine factors predictive of the need for muscle flap coverage for salvage of vascular grafts. Another study by Fischer et al<sup>24</sup> retrospectively examined 925 patients undergoing vascular grafting of the groin. In this study, they identified that patients experiencing graft complications necessitating salvage muscle flap were more likely to have had prior groin surgery, prosthetic grafts, coronary and peripheral artery disease, and obesity.



Although the single-surgeon study presented here demonstrates the importance of early muscle flap coverage in the setting of infected vascular grafts of the groin, the limitations of this study include retrospective nature of the review and relatively small sample size. The variable presentation and lack of treatment standardization of infected vascular grafts makes prospective randomized studies difficult; however, continued investigation should be done to determine positive predictors of outcomes and to determine compounding factors affecting the success of early versus delayed muscle flap coverage.

### CONCLUSIONS

The findings of this study suggest that early intervention with local muscle flap placement after femoral vascular graft infection is important to ensure successful patient outcome defined as graft salvage. Although there are clinical series advocating the use of negative pressure therapy for treatment of infected vascular grafts, the experience of the authors is that such therapy may lead to the delay of definitive muscle flap surgery. Such a delay may result in negative patient outcomes, including graft loss, continued infection, or even limb loss. As such, the authors continue to advocate for early muscle flap coverage whenever possible in infected vascular grafts of the groin.

**Detlev Erdmann, MD, PhD, MHSc**

Division of Plastic, Reconstructive  
Maxillofacial and Oral Surgery  
Department of Surgery  
Duke University Medical Center  
Durham, NC 27710

E-mail: detlev.erdmann@dm.duke.edu

### REFERENCES

- Illig KA, Alkon JE, Smith A, et al. Rotational muscle flap closure for acute groin wound infections following vascular surgery. *Ann Vasc Surg.* 2004;18:661–668.
- Hasse B, Husmann L, Zinkernagel A, et al. Vascular graft infections. *Swiss Med Wkly.* 2013;143:w13754.
- Wengrovitz M, Atnip RG, Gifford RR, et al. Wound complications of autogenous subcutaneous infrainguinal arterial bypass surgery: predisposing factors and management. *J Vasc Surg.* 1990;11:156–161; discussion 161–163.
- Kent KC, Bartek S, Kuntz KM, et al. Prospective study of wound complications in continuous infrainguinal incisions after lower limb arterial reconstruction: incidence, risk factors, and cost. *Surgery* 1996;119:378–383.
- Perler BA. The case for conservative management of infected prosthetic grafts. *Adv Surg.* 1996;29:17–32.
- Seify H, Moyer HR, Jones GE, et al. The role of muscle flaps in wound salvage after vascular graft infections: the Emory experience. *Plast Reconstr Surg.* 2006;117:1325–1333.
- Perler BA, Vander Kolk CA, Dufresne CR, et al. Can infected prosthetic grafts be salvaged with rotational muscle flaps? *Surgery* 1991;110:30–34.
- Calligaro KD, DeLaurentis DA, Veith FJ. An overview of the treatment of infected prosthetic vascular grafts. *Adv Surg.* 1996;29:3–16.
- Szilagyi DE, Smith RF, Elliott JP, et al. Infection in arterial reconstruction with synthetic grafts. *Ann Surg.* 1972;176:321–333.
- Carter SC, Cohen A, Whelan TJ. Clinical experience with management of the infected dacron graft. *Ann Surg.* 1963;158:249–255.
- Calligaro KD, Veith FJ, Sales CM, et al. Comparison of muscle flaps and delayed secondary intention wound healing for infected lower extremity arterial grafts. *Ann Vasc Surg.* 1994;8:31–37.
- Graham RG, Omotoso PO, Hudson DA. The effectiveness of muscle flaps for the treatment of prosthetic graft sepsis. *Plast Reconstr Surg.* 2002;109:108–113; discussion 114–115.
- Morasch MD, Sam AD II, Kibbe MR, et al. Early results with use of gracilis muscle flap coverage of infected groin wounds after vascular surgery. *J Vasc Surg.* 2004;39:1277–1283.
- Fischer JP, Nelson JA, Mirzabeigi MN, et al. Prophylactic muscle flaps in vascular surgery. *J Vasc Surg.* 2012;55:1081–1086.
- Fischer JP, Nelson JA, Rohrbach JJ, et al. Prophylactic muscle flaps in vascular surgery: the Penn Groin Assessment Scale. *Plast Reconstr Surg.* 2012;129:940e–949e.
- Perler BA, Kolk CA, Manson PM, et al. Rotational muscle flaps to treat localized prosthetic graft infection: long-term follow-up. *J Vasc Surg.* 1993;18:358–364; discussion 364–365.
- Williams IM, Milling MA, Shandall AA. Vascularised muscular flaps and arterial graft infection in the groin. *Eur J Vasc Endovasc Surg.* 2003;25:390–395.
- Chalmers RT, Wolfe JH, Cheshire NJ, et al. Improved management of infrainguinal bypass graft infection with methicillin-resistant *Staphylococcus aureus*. *Br J Surg.* 1999;86:1433–1436.
- Ali AT, Modrall JG, Hocking J, et al. Long-term results of the treatment of aortic graft infection by in situ replacement with femoral popliteal vein grafts. *J Vasc Surg.* 2009;50:30–39.
- Mayer D, Hasse B, Koelliker J, et al. Long-term results of vascular graft and artery preserving treatment with negative pressure wound therapy in Szilagyi grade III infections justify a paradigm shift. *Ann Surg.* 2011;254:754–759; discussion 760.
- Dosluoglu HH, Loghmanee C, Lall P, et al. Management of early (<30 day) vascular groin infections using vacuum-assisted closure alone without muscle flap coverage in a consecutive patient series. *J Vasc Surg.* 2010;51:1160–1166.
- Svensson S, Monsen C, Kölbel T, et al. Predictors for outcome after vacuum assisted closure therapy of peri-vascular surgical site infections in the groin. *Eur J Vasc Endovasc Surg.* 2008;36:84–89.
- Fischer JP, Mirzabeigi MN, Sieber BA, et al. Outcome analysis of 244 consecutive flaps for managing complex groin wounds. *J Plast Reconstr Aesthet Surg.* 2013;66:1396–1404.
- Fischer JP, Nelson JA, Shang EK, et al. Predicting the need for muscle flap salvage after open groin vascular procedures: a clinical assessment tool. *J Plast Surg Hand Surg.* 2014;48:389–395.