



## Case Report

# Superficial acral fibromyxoma of the thumb: a case report

Bruno Gonçalves Schroder e Souza,<sup>1,\*</sup> Tales Pereira Lisboa,<sup>2</sup> Victor Atsushi Kosuja Barbosa,<sup>2</sup> José Paulo Sabino de Almeida,<sup>3</sup> Carlos Eduardo Bacchi,<sup>4</sup> Valter Gonçalves Souza<sup>5</sup>

<sup>1</sup>MSc in Medicine; Orthopedist and Traumatologist at Hospital de Misericórdia de Santos Dumont, Santos Dumont, MG, Brazil.

<sup>2</sup>Undergraduate Medical Student at Universidade Federal de Juiz de Fora, Juiz de Fora, MG, Brazil.

<sup>3</sup>Orthopedist and Traumatologist at Clínica ORTRA, Juiz de Fora, MG, Brazil.

<sup>4</sup>PhD in Medicine; Full Professor at Universidade Estadual Paulista (Unesp) de Botucatu; Pathologist at Laboratório Bacchi, Pathology Consultancy, Botucatu, SP, Brazil

<sup>5</sup>Orthopedist and Traumatologist and Head of the Orthopedics and Traumatology Service, Hospital de Misericórdia de Santos Dumont, Santos Dumont, MG, Brazil.

Work performed at Hospital de Misericórdia de Santos Dumont, Santos Dumont, MG, Brazil.

### ARTICLE INFO

#### Article history:

Received on February 27, 2012

Approved on July 17, 2012

#### Keywords:

Thumb/surgery

Fibroma/diagnosis

Hands/surgery

Pathology, clinical

Antigens, surface

### A B S T R A C T

The authors report a case of superficial acral fibromyxoma (SAF) in a 74-year-old male who presented with a painless mass in a periungual dorsoradial region of the right thumb. It is a rare benign neoplasm, which was recently described, that arose on the skin and subcutaneous tissue of the hands and feet, especially in the proximity to the ungual region of male adults. Surgical treatment was performed with the excision in blocks of the margins of the lesion and fragmentation of the nail and nail matrix, according to the literature recommendation. Although there may be local recurrence in 22% of the cases, the patient presents no symptoms, deformities or functional limitations. In addition, there was no sign of tumor recurrence 18 months after the surgery. We are not aware of a similar case report in the Brazilian literature.

© 2013 Sociedade Brasileira de Ortopedia e Traumatologia. Published by Elsevier Editora Ltda. Este é um artigo Open Access sob a licença de [CC BY-NC-ND](#)

\*Corresponding author at: Av. Getúlio Vargas, 316, 3º andar, Centro, CEP: 36 240-000, Santos Dumont, MG, Brazil.

E-mail: brunogss01@yahoo.com.br

## Introduction

Superficial acral fibromyxoma (SAF) is a myxoid tumor that was recently described by Fetsch et al.,<sup>1</sup> which preferentially affects the subungual or periungual region. It is generally manifested in the form of a slow-growing painless mass that mainly affects male adults. With regard to histological analysis, it presents as a poorly delineated neoplasm composed of fusiform or stellate neoplastic cells with a varying degree of pleomorphism, located in myxoid and collagenous stroma. The fusiform cells present immunoreactivity to CD34, CD99, vimentin and, focally, to the epithelial membrane antigen (EMA). Blood vessels are predominantly found in the myxoid area and mast cells tend to be distributed throughout the lesion. In most cases, the prognosis is benign, although there have been reports of cases with local recurrence.<sup>2</sup>

Dissemination of cases of this tumor serves the purpose of informing surgeons and pathologists about the correct diagnosis for these lesions, since this is a rare tumor that is liable to recur. Its differential diagnoses include malignant tumors such as dermatofibrosarcoma protuberans and dermatofibrosarcoma myxoid.<sup>3-5</sup>

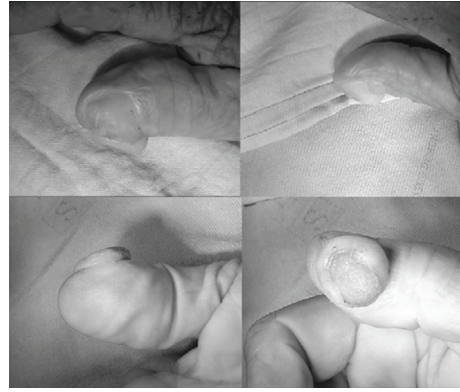
## Case report

The patient was a 74-year-old man with slightly painful tumor growth in the dorsoradial periungual region of the right thumb that had progressively been increasing in size over approximately the last 10 years. The patient was retired and had previously been a farm laborer. He reported that he had had two previous episodes of trauma at the site where the tumor growth had formed, resulting in ulceration followed by rapid healing. The data relating to the patient's previous pathological, social and family histories did not contain any elements of relevance to the diagnosis.


The physical examination revealed a periungual tumor in the dorsoradial region of the right thumb, of oval shape, which medially pushed back the nail, unguinal matrix and cuticle. At the center of the lesion, an epithelized depression was evident, suggesting previous ulceration (Fig. 1). The tumor had firm consistency and was adhering to the deep layers; it was slightly painful on palpation. The thumb presented complete perfusion without signs of increased local vascularization or any other phlogistic sign. Transillumination confirmed the solid nature of the lesion. There were no abnormalities of thumb mobility. The patient complained of local hyperesthesia on palpation and was Tinel negative.

Simple radiography showed tumor growth, with density similar to the adjacent soft tissues, without calcifications and without bone erosion, deformity or periosteal reaction.


The lesion was resected en-bloc, with nail and matrix fragments, under trunk anesthetic block. The excision was intended to be marginal, since it was suspected that this was a benign lesion. Even so, it was necessary to deepen the incision down to the bone phalange, and a local cutaneous flap had to be rotated into position, in order to achieve primary closure of the lesion.



**Fig. 1 - Preoperative images of the right thumb showing voluminous tumor growth on the dorsoradial edge of the thumb. From the upper left corner, clockwise: dorsal view, ulnar view, palmar view and radial view.**



**Fig. 2 - Superficial acral fibromyxoma. Macroscopic appearance: specimen removed en-bloc, showing superficial face with fragment of nail adhering to it.**



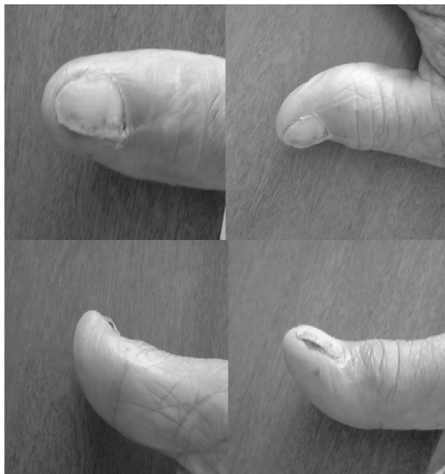
**Fig. 3 - Superficial acral fibromyxoma. Macroscopic appearance: specimen removed en-bloc, showing underside with subcutaneous tissue adhering to it.**



**Fig. 4 - Superficial acral fibromyxoma. Histopathological analysis showing well delimited fibromyxoid neoplasm, partially covered with hyperplastic epidermis, with hyperkeratosis. HE, 100x.**



**Fig. 5 - Superficial acral fibromyxoma. Histopathological analysis showing elongated neoplastic cells without atypias, with myxoid stroma and rich vascularization. HE, 200x.**



**Fig. 6 - Postoperative images of the right thumb showing adequate healing, with good cosmetic result and without signs of recurrence. From the upper left corner, clockwise: dorsal view, ulnar view, palmar view and radial view.**

The macroscopic examination showed that the specimen was a discoid tissue fragment of 1.6 cm in diameter and 1.0 cm in depth, with a face consisting of tumor surface with a nail fragment adhering to it (Fig. 2) and an underside covered with subcutaneous tissue (Fig. 3). Examination under a microscope showed ulceration with stromal invasion by the neoplasm. The tissue proliferation also involved the dermis and the subcutaneous tissue, and comprised stellate and fusiform cells distributed in a collagenized matrix, with myxoid areas (Fig. 4). A rich vascular network, discrete nuclear atypia and rate mitosis figures were seen (Fig. 5). Immunohistochemical analysis showed CD34 expression, but the specimen was negative for smooth muscle actin, EMA, desmin, protein S-100 and CD63. The clinical and anatomopathological findings confirmed the diagnosis of SAF.

After 18 months of follow-up, the patient continues to be asymptomatic, without deformities or functional limitations, and without signs of tumor recurrence (Fig. 6).

## Discussion

SAF was originally described by Fetsch et al.<sup>1</sup> in 2001, and is a benign neoplasm of the skin and subcutaneous tissue that is considered to be rare. It usually affects the extremities of the fingers and toes. On rare occasions, SAF affects other locations: it has been reported on the palm of the hand and the calcaneus.<sup>6</sup> Although it is considered to be benign, it may recur locally in up to 22% of the cases.<sup>6</sup> No cases of distant metastasis have been reported in the literature. Although it was initially reported as a very rare tumor,<sup>1</sup> some more recent reports have suggested that this tumor is less rare but very likely to be underdiagnosed.<sup>5-8</sup> In fact, in a survey that we conducted in PubMed, we only found 18 reports of tumors of this type, and none of these reports form part of the Brazilian literature.

Several authors have emphasized that the diagnosis of unspecified myxoma should no longer be used,<sup>6,7</sup> considering that differentiation of the specific tumor types is now possible and makes it possible to identify cases with the potential for recurrence, as is the case of SAF.<sup>1,2</sup> Moreover, precise histopathological diagnosis may avoid cases of unnecessarily aggressive treatment. In the original report by Fetsch et al.,<sup>1</sup> four of the 37 specimens studied originated from partial amputation of the fingers. Today, limb preservation is recommended in treating SAF, such that the primary objective should be en-bloc resection with disease-free margins.<sup>7,9,10</sup>

The present case required rotation of a local cutaneous flap in order to cover the bone. Other differential diagnoses for SAF include epidermal inclusion cyst, glomus tumor, fibrous histiocytoma, acquired digital fibrokeratoma, sclerosing perineuroma, superficial angiomyxoma, acral myxoinflammatory fibroblastic sarcoma and several other low-grade myxoid sarcomas.<sup>1-7,9,10</sup> The difficulty in coming to a diagnostic conclusion generally lies in the relative lack of knowledge of this lesion among many pathologists, dermatologists and hand surgeons.<sup>7</sup> Prescott et al. discussed this matter in a paper that reported 41 new cases of SAF that were diagnosed retrospectively.<sup>7</sup> These tumors had previously been labeled as myxoma, fibroma or dermatofibroma. These authors questioned the validity of this type of generic diagnosis in the present century, given that immunohistochemical markers are now available and are capable of differentiating between specific tumor types, often with important clinical implications for treatment and prognosis.<sup>6,7</sup> In our case, the initial diagnosis was inconclusive and a consultation office with a specialist pathologist and immunohistochemical tests furnished the definitive diagnosis.

The clinical data on our patient illustrate the typical presentation of these tumors. In the literature, the region most affected is the distal extremity of the fingers and toes.<sup>1,2,5-10</sup> In one series, involvement of the unguis was observed in 75% of the cases.<sup>7</sup> In the majority of the series, there was greater occurrence among male adults. The length of evolution of these tumors has been reported as ranging from three months to 30 years.<sup>2</sup> The mean size of the lesions ranges from 1.5 to 2 cm,<sup>1,7</sup> although cases of between 0.6 and 5 cm in diameter have been reported.<sup>1</sup> The radiographic findings from these

tumors are generally nonspecific, with increased soft-tissue volume and absence of calcifications. It can be noted that all of the abovementioned characteristics were corroborated in our patient. However, bone erosion may also be present and has been reported by several authors.<sup>11,12</sup> In the majority of the cases, the mass is painless, although painfulness may be noted in up to 10% of the cases.<sup>7,9</sup>

Histologically, SAF consists of moderate proliferation of fusiform fibroblasts and stellate cells inside a myxoid, myxocollagenous or collagenous matrix. A rich microvascular network and local mast cell infiltration are often seen in the tumor. The cells present a pattern of storiform, irregular and fascicular growth, with rare findings of mitosis figures and nuclear atypia.<sup>1-3</sup> Immunohistochemistry is important for the diagnosis and shows positive findings for CD34, CD99 and EMA (epithelial membrane antigen) and negative findings for S-100, cytokeratin, smooth muscle, skeletal muscle and melanocytic markers.<sup>1,3,4,6,8</sup>

The natural history of this neoplasm indicates that its evolution is benign, although the histology of the tumor may vary from mild cellular atypia to marked nuclear atypia, with many mitosis figures in rare cases.<sup>1</sup> In this situation, there is some concern regarding the possible risk of low-grade malignant transformation.<sup>5,9</sup> For this reason, the preferred treatment is complete surgical resection with free margins. Thus, through this, disastrous events with an impact on such patients can be minimized with the perception of a correct diagnosis and consequent appropriate management. The present case continues under observation, since recurrences have been reported in such cases up to one year and eight months after the surgery.<sup>2</sup>

### Conflicts of interest

The authors declare that there was no conflict of interests in conducting this study.

### REFERENCES

1. Fetsch JF, Laskin WB, Miettinen M. Superficial acral fibromyxoma: a clinicopathologic and immunohistochemical analysis of 37 cases of a distinctive soft tissue tumor with a predilection for the fingers and toes. *Hum Pathol.* 2001;32(7):704-14.
2. Goo J, Jung YJ, Kim JH, Lee SY, Ahn SK. A case of recurrent superficial acral fibromyxoma. *Ann Dermatol.* 2010;22(1):110-3.
3. Lisovsky M, Hoang MP, Dresser KA, Kapur P, Bhawan J, Mahalingam M. Apolipoprotein D in CD34-positive and CD34-negative cutaneous neoplasms: a useful marker in differentiating superficial acral fibromyxoma from dermatofibrosarcoma protuberans. *Mod Pathol.* 2008;21(1):31-8.
4. McNiff JM, Subtil A, Cowper SE, Lazova R, Glusac EJ. Cellular digital fibromas: distinctive CD34-positive lesions that may mimic dermatofibrosarcoma protuberans. *J Cutan Pathol.* 2005;32(6):413-8.
5. Cogrel O, Stanislas S, Coindre JM, Guillot P, Beylot-Barry M, Doutre MS, et al. Superficial acral fibromyxoma: three cases. *Ann Dermatol Venerol.* 2010;137(12):789-93.
6. Al-Daraji WI, Miettinen M. Superficial acral fibromyxoma: a clinicopathological analysis of 32 tumors including 4 in the heel. *J Cutan Pathol.* 2008;35(11):1020-6.
7. Prescott RJ, Husain EA, Abdellaoui A, Al-Mahmoud RM, Khan M, Salman WD, et al. Superficial acral fibromyxoma: a clinicopathological study of new 41 cases from the U.K.: should myxoma (NOS) and fibroma (NOS) continue as part of 21st-century reporting? *Br J Dermatol.* 2008;159(6):1315-21.
8. Abou-Nukta F, Fiedler P, Parkash V, Arons J. Superficial acral fibromyxoma of the distal phalanx of the thumb. *J Hand Surg Br.* 2006;31(6):619-20.
9. Wang QF, Pu Y, Wu YY, Wang J. Superficial acral fibromyxoma of finger: report of a case with review of literature. *Zhonghua Bing Li Xue Za Zhi.* 2009;38(10):682-5.
10. André J, Theunis A, Richert B, De Saint-Aubain N. Superficial acral fibromyxoma: clinical and pathological features. *Am J Dermatopathol.* 2004;26(6):472-4.
11. Varikatt W, Soper J, Simmons G, Dave C, Munk J, Bonar F. Superficial acral fibromyxoma: a report of two cases with radiological findings. *Skeletal Radiol.* 2008;37(6):499-503.
12. Oteo-Alvaro A, Meizoso T, Scarpellini A, Ballestín C, Pérez-Espejo G. Superficial acral fibromyxoma of the toe, with erosion of the distal phalanx. A clinical report. *Arch Orthop Trauma Surg.* 2008;128(3):271-4.