



Catastrophic ceramic failure in total hip arthroplasty: the role of microseparation

Konstantinos Tsitskaris¹ • Reza Mansouri² • Patrick LS Li²

¹Chase Farm Hospital, Enfield, UK

²King's College Hospital, London, UK

Correspondence to: Konstantinos Tsitskaris. Email: tsitskaris@yahoo.com

DECLARATIONS

Competing interests

None declared

Funding

None

Ethical approval

This case report receive the approval of our institution's ethical review board following the submission of the relevant application; written informed consent to publication was obtained from the patient or next of kin

Guarantor

KT

Contributorship

KT assisted during the revision operation and wrote the paper; RM helped organize the article; PLSL performed the operations and edited the article

Acknowledgements

None

We present a case report of a ceramic liner fracture after total hip arthroplasty; we believe that the fracture occurred because the microseparation between the ceramic bearings was accentuated by an avulsion of the greater trochanter.

Case report

In May 2008, a left total hip arthroplasty was undertaken for the treatment of end-stage osteoarthritis in a 77-year-old man with a body mass index of 25 kg/m². A cementless total hip arthroplasty prosthesis was implanted through a transgluteal approach. A combination of a ceramic acetabular liner with a 36 mm ceramic femoral head was chosen. During the procedure, a low femoral neck cut resulted in a fracture of the greater trochanter, which was subsequently fixed with two partially threaded screws. Immediate postoperative radiographs revealed satisfactory orientation of the components and a fixed greater trochanter. The patient made an uneventful recovery and was discharged on the seventh postoperative day with instructions to walk with the use of crutches, partially weight-bearing for six weeks. At six weeks the previously fixed greater trochanter was found to be avulsed (Figure 1).

The patient had no symptoms and was therefore allowed to mobilize fully weight-bearing. At the six-month follow-up the prosthesis was considered to be functioning well on the basis of satisfactory pain relief as reported by the patient. He was able to walk unaided, with a normal gait. The hip had an excellent range of movement with no tenderness over the greater trochanter and there was no limb length discrepancy. At 15 months postoperatively the patient reported the

sudden onset of pain-free squeaking with no history of trauma. Radiographs revealed a fracture of the ceramic acetabular liner (Figure 2) and seven days later revision surgery was undertaken. The fractured liner and the partially threaded screws were removed and thorough debridement of multiple small fragments of ceramic was undertaken. The femoral head exhibited macroscopic signs of wear and was removed as well (Figure 3). Having checked the stability of both prosthetic components, revision consisted of the exchange of the acetabular liner and the femoral head with ceramic implants of the same size as the originals. During the procedure, the greater trochanter was found enveloped in fibrous tissue, partially comminuted. The abductors were found to be atrophic and were reattached with transosseous sutures to the proximal femur. The patient made an uncomplicated recovery and was discharged on the fifth postoperative day. At 24 months following the revision procedure (Figure 4), the patient was pain-free and able to mobilize unaided.

Discussion

The use of third generation ceramic-on-ceramic bearings in total hip arthroplasty is thought to be a safe and reliable option particularly in young and more active patients.^{1,2} The prevalence of ceramic fracture has decreased with the use of superior materials.^{3,4} Nevertheless, ceramic fracture and the risk of squeaking continue to cause anxiety.

Fracture of a ceramic bearing usually presents with the sudden onset of pain accompanied by a variably described sound (squeaking, pop, click, etc.).^{4,5} Factors implicated both in the risk for

Reviewer fracture of a ceramic bearing and the potential for squeaking are obesity⁶ and acetabular cup malpositioning.^{7,8} Our patient was not obese and the acetabular component was in a satisfactory position (inclination of 40°, anteversion of 10°).

Visual inspection of the retrieved components revealed evidence of stripe wear on the ceramic

femoral head. The stripe wear was most certainly a result of the direct contact of the femoral head with the acetabular shell; this contact was also the probable cause for the sudden onset of squeaking in the previously 'silent' hip articulation. In terms of the ceramic liner, several medium-sized pieces and multiple smaller fragments were retrieved; further biomechanical assessment of the liner was deemed futile due to the severe damage to its structure.

Microscopic ceramic particles have been identified after histological examination of the periprosthetic soft tissues following ceramic fractures. These particles have been associated with higher wear rates especially affecting the use of polyethylene liner with stainless steel femoral head articulations for revisions following fractured ceramic components.⁹ During our revision procedure and in order to avoid excessive postoperative wear rates we opted for the use of ceramic components both for the liner and the femoral head.

With regards to the aetiology behind the ceramic liner breakage, we believe that the greater trochanteric avulsion during the primary procedure may have been the initiating factor that eventually led to ceramic failure. Professor Fisher's team¹⁰ studied the phenomenon of microseparation between ceramic bearings *in vitro* and they were able to reproduce clinically relevant wear rates in ceramic-on-ceramic hip prostheses. During their investigation, scanning electron micrographs revealed transgranular fractures of the ceramic. They also suggested that soft tissue tension and muscle forces could influence the degree of microseparation. In our case we believe that the trochanteric avulsion resulted in an accentuation of the physiological microseparation which exists between the bearing surfaces. The formation and subsequent propagation of cracks across the surface of the ceramic liner led to the fracture of the material.

Microseparation may play an important part in the aetiology of ceramic fractures.¹⁰ We suggest that formation of cracks in the ceramic is more likely to occur when there is accentuation of the microseparation that exists between the bearing surfaces. Achieving the correct soft tissue tension is an essential skill in any total hip arthroplasty, but it may be even more critical when a ceramic bearing is used. In the event of trochanteric

Figure 1
At six weeks the previously fixed greater trochanter was found to be avulsed

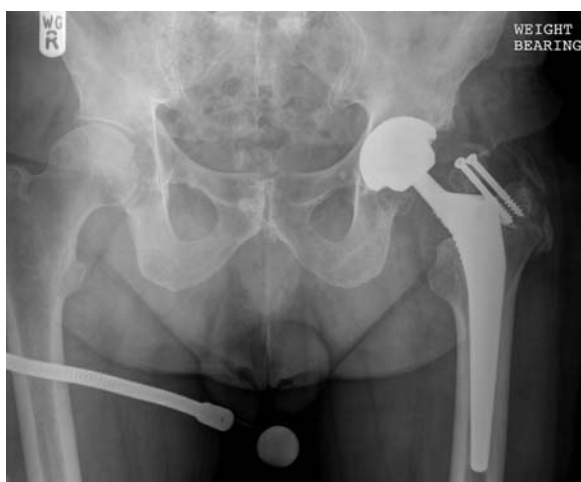

Figure 2
Anteroposterior radiograph of the pelvis showing the acetabular liner fracture, 15 months postoperatively

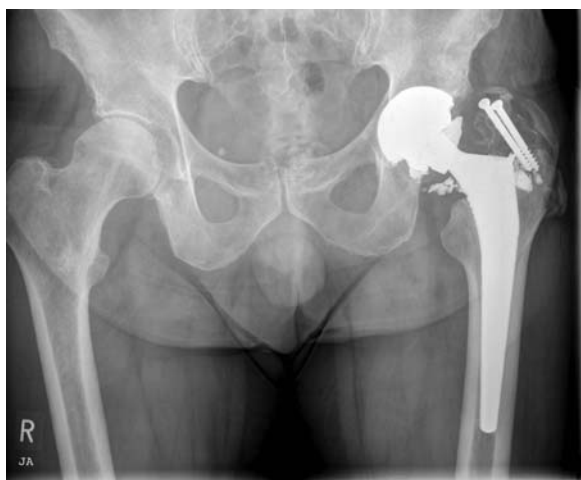

Figure 3
Intraoperative view of the ceramic head exhibiting signs of wear

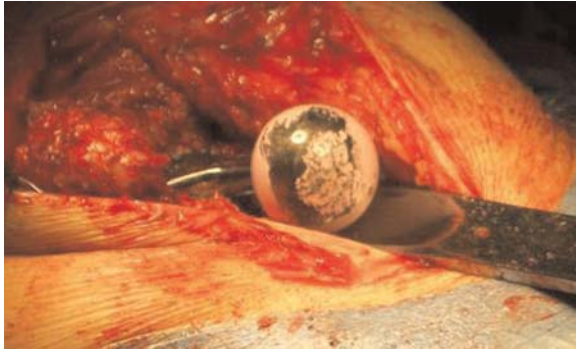
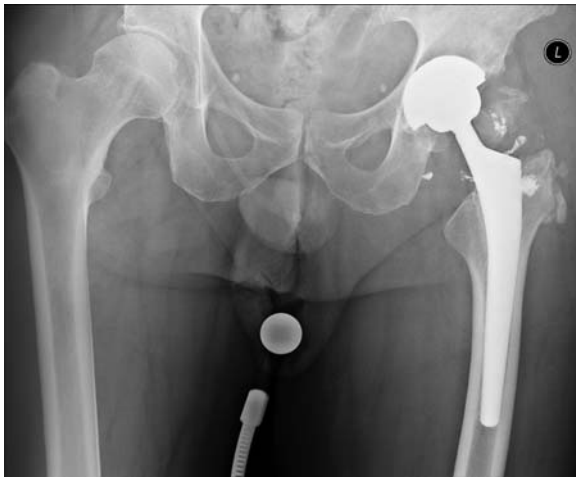


Figure 4
Anteroposterior radiograph of the pelvis, at the last follow-up



avulsion or abductor insufficiency, the use of an alternative bearing surface (other than ceramic)

should be considered. Further studies on the effect of abductor insufficiency and its effect on the biomechanics of ceramic bearings would shed more light to this mode of catastrophic failure.

References

- 1 D'Antonio J, Capello W, Manley M, Naughton M, Sutton K. Alumina ceramic bearings for total hip arthroplasty: five-year results of a prospective randomised study. *Clin Orthop Relat Res* 2005;**436**:164–71
- 2 Lusty PJ, Tai CC, Sew-Hoy RP, Walter WL, Walter WK, Zicat BH. Third-generation alumina-on-alumina ceramic bearings in cementless total hip arthroplasty. *J Bone Joint Surg [Am]* 2007;**89**:2676–83
- 3 D'Antonio J, Capello W, Manley M, Bierbaum B. New experience with alumina-on-alumina ceramic bearings for total hip arthroplasty. *J Arthroplasty* 2002;**17**:390–7
- 4 Toni A, Traina F, Stea S, *et al*. Early diagnosis of ceramic liner fracture. Guidelines based on a twelve-year clinical experience. *J Bone Joint Surg [Am]* 2006;**88**:55–63
- 5 Regis D, Sandri A, Bartolozzi P. Delayed diagnosis of low-symptomatic ceramic acetabular liner fracture in ceramic-on-ceramic total hip arthroplasty. *Orthopedics* 2008;**31**:1–3
- 6 Poggie RA, Turgeon TR, Coutts RD. Failure analysis of a ceramic bearing acetabular component. *J Bone Joint Surg [Am]* 2007;**89**:367–75
- 7 Ha YS, Kim SY, Kim HJ, Yoo JJ, Koo KH. Ceramic liner fracture after cementless alumina-on-alumina total hip arthroplasty. *Clin Orthop Relat Res* 2007;**458**:106–10
- 8 Walter WL, O'Toole GC, Walter WK, Ellis A, Zicat BA. Squeaking in ceramic-on-ceramic hips: the importance of acetabular component orientation. *J Arthroplasty* 2007;**22**:496–503
- 9 Allain J, Roudot-Thoraval F, Delecrin J, Anract P, Migaud H, Goutalier D. Revision total hip arthroplasty performed after fracture of a ceramic femoral head: a multicenter survivorship study. *J Bone J Surg [Am]* 2003;**85**:825–30
- 10 Nevelos J, Ingham E, Doyle C, *et al*. Microseparation of the centers of alumina-alumina artificial hip joints during simulator testing produces clinically relevant wear rates and patterns. *J Arthroplasty* 2000;**15**:793–5