

## Bisphosphonate-related osteonecrosis of the jaw in a multiple myeloma patient: A case report with characteristic radiographic features

Byung-Do Lee<sup>1,\*</sup>, Moo-Rim Park<sup>2</sup>, Kyung-Hwan Kwon<sup>3</sup>

<sup>1</sup>Department of Oral and Maxillofacial Radiology and Wonkwang Dental Research Institute, College of Dentistry, Wonkwang University, Iksan, Korea

<sup>2</sup>Department of Internal Medicine, School of Medicine, Wonkwang University, Iksan, Korea

<sup>3</sup>Department of Oral and Maxillofacial Surgery, College of Dentistry, Wonkwang University, Iksan, Korea

### ABSTRACT

A 59-year-old male who had suffered from multiple myeloma for nine years and had been administered bisphosphonates for seven years visited a dental hospital for pain relief due to extensive caries in his left maxillary molars. The molars were extracted, leaving an exposed wound for three months. The radiograph showed sequestra formation and irregular bone destruction in the left maxilla. Sudden pain and gingival swelling in the right mandibular molar area occurred six months later. The interseptum of the right lower second molar was observed to be necrotic during surgery. These findings coincided with the features of bisphosphonate-related osteonecrosis of the jaw (BRONJ). In this case, the long intravenous administration of bisphosphonates and tooth extraction were likely the etiologic factors of BRONJ in a patient with multiple myeloma; moreover, the bilateral occurrence of BRONJ is a characteristic feature. (*Imaging Sci Dent* 2015; 45: 199-203)

**KEY WORDS:** Multiple Myeloma; Bisphosphonate-Associated Osteonecrosis of the Jaw; Tooth Extraction

Multiple myeloma is a systemic clonal proliferation of plasma cells in the bone marrow that characteristically secrete a monoclonal immunoglobulin.<sup>1</sup> Multiple myeloma is one of the three clinically distinct plasma cell disorders, as well as solitary plasmacytoma of the bone and extramedullary plasmacytoma.<sup>2,3</sup>

Multiple bone involvement is common, with conversion to multiple myeloma occurring at least several years after the initial development of solitary plasmacytoma of the bone.<sup>4</sup> The most common clinical signs and symptoms of multiple myeloma are bone pain or swelling in localized areas, fatigue, and anemia.<sup>5</sup> Radiographic examinations usually reveal generalized bone rarefaction with osteoporotic changes, as well as punched-out lesions involving multiple bones.<sup>6</sup> Jaw involvement is common and often

occurs in the advanced stages of the disease.<sup>7,8</sup>

Bisphosphonates are important drugs in the treatment of multiple myeloma.<sup>9</sup> They are able to inhibit the progression of the disease and can even prolong survival.<sup>10</sup> However, in the case of dental infections, they can lead to bisphosphonate-related osteonecrosis of the jaw (BRONJ).<sup>11</sup> Additionally, tooth extractions have been shown to increase the risk of BRONJ in individuals taking bisphosphonates.<sup>12</sup>

This report describes the characteristic radiographic features of BRONJ in a patient with multiple myeloma, in whom the administration of bisphosphonates and tooth extraction were likely the etiologic factors of BRONJ.

### Case Report

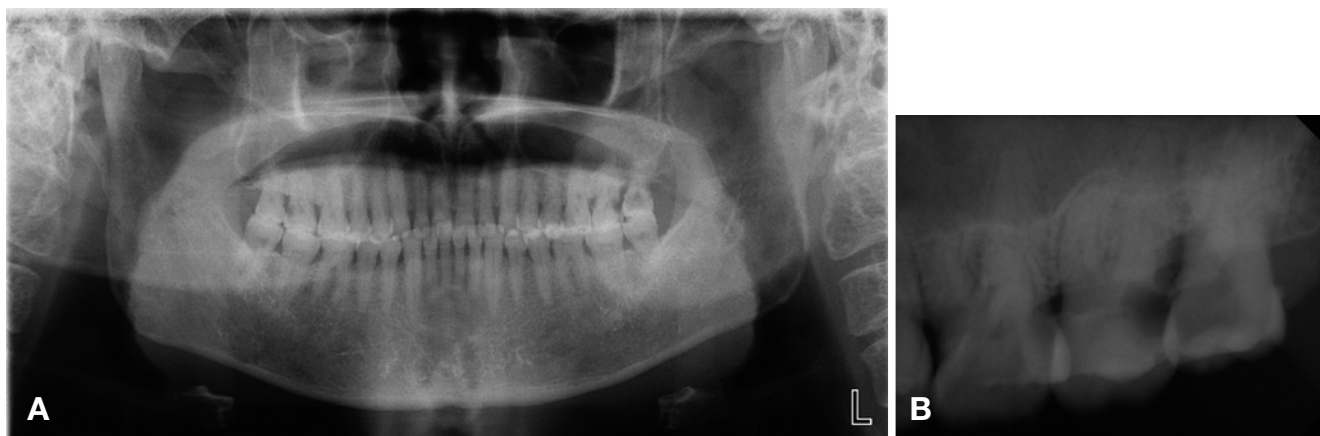A 59-year-old male visited the Wonkwang Dental Hospital complaining of tooth pain around the left maxillary molars. An intraoral examination revealed deep dental caries in the second and third molars and moderate mo-

\*This study was supported by Wonkwang University in 2013.

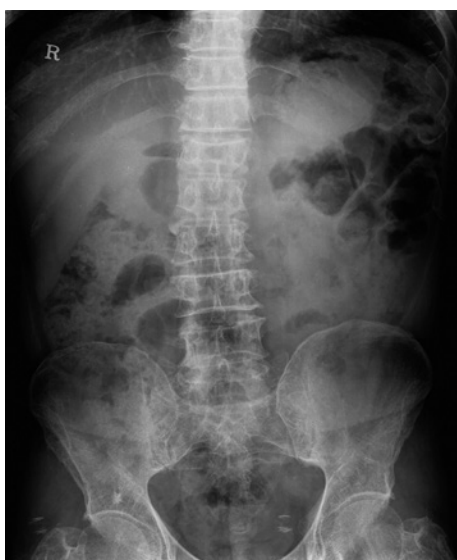Received March 14, 2015; Revised May 11, 2015; Accepted May 24, 2015

\*Correspondence to : Prof. Byung-Do Lee

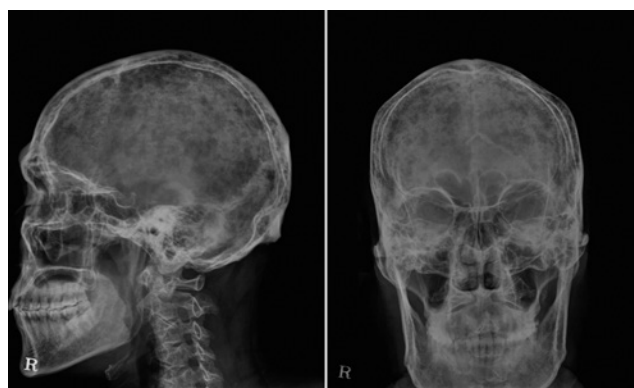Department of Oral and Maxillofacial Radiology, College of Dentistry, Wonkwang University, Iksan-daero 460, Iksan, Jeonbuk 570-749, Korea  
Tel) 82-63-859-2912, Fax) 82-63-857-4002, E-mail) eebydo@wonkwang.ac.kr



**Fig. 1.** A panoramic radiograph (A) and periapical radiograph (B) show a carious lesion on the maxillary first, second, and third molars extending into the subgingival area, with a suspected mucosal antral cyst in the left maxillary sinus.

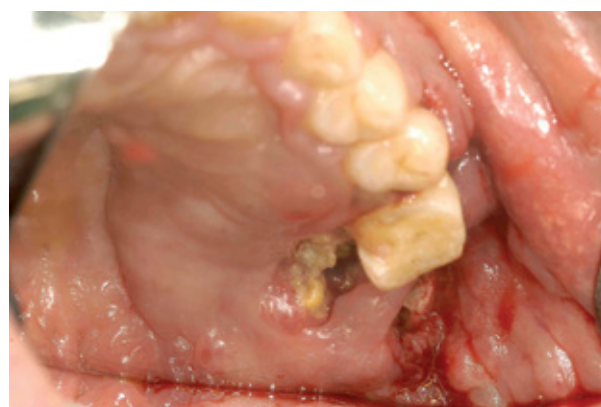

**Fig. 2.** Compression fracture of T12 and diffuse osteopenia of the pelvic bone.



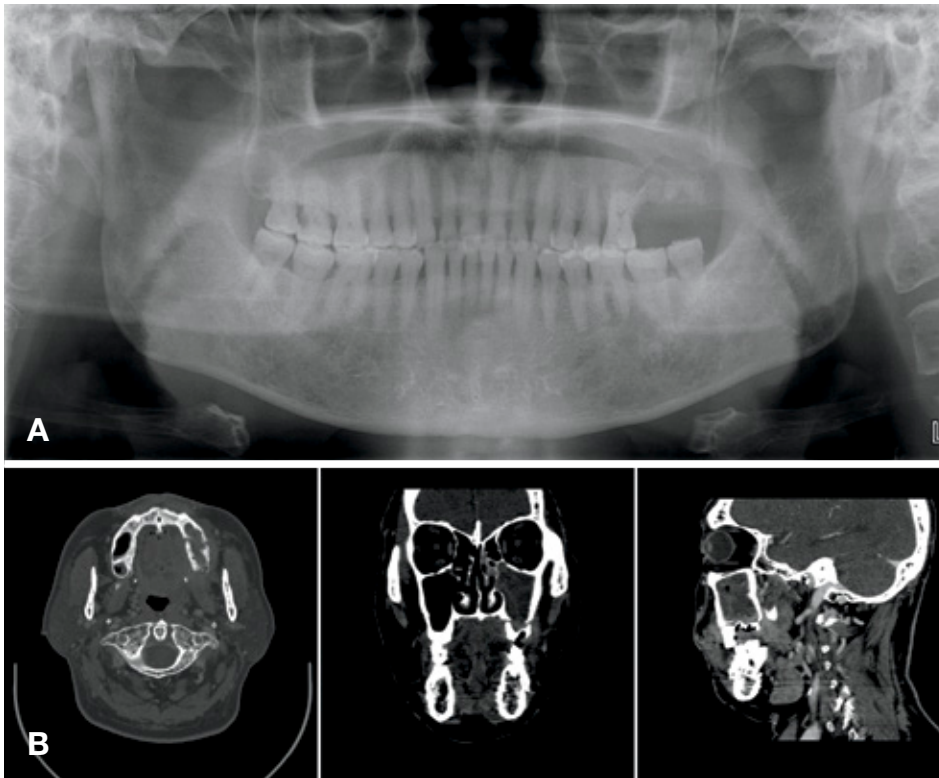
**Fig. 3.** Skull radiographs show a punched-out appearance.

bility of the third molar. Panoramic and periapical radiographs showed a carious lesion on the teeth extending into the subgingival area, but the radiographs did not show a bony destructive lesion in the left maxillary posterior region (Fig. 1). Since the endodontic treatment of subgingival carious lesions cannot be guaranteed to be successful, extraction was considered. However, BRONJ was a concern because the patient had been administered pamidronate for two years, followed by zoledronate for five years, to treat multiple myeloma. Moreover, the patient did not accept extraction as a treatment option, so tooth extraction was postponed. This patient had been diagnosed with multiple myeloma (IgG kappa type) nine years previously and



**Fig. 4.** At 50 days after extraction, pus discharge from the wound and sequestra formation are observed.

had undergone multimodal examinations and treatment at the Wonkwang Medical Hospital. The diagnosis of multiple myeloma was based on multiple tests, including serum

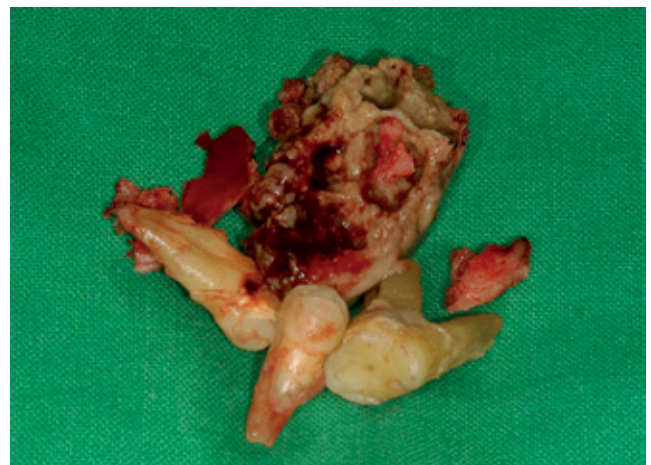

**Fig. 5.** A panoramic radiograph (A) and a computed tomograph (B) reveal the separation of the alveolar ridge from the surrounding maxillary bone, sequestra, and irregular bone destruction. Chronic sinusitis is seen in the left maxillary sinus.

and urine protein electrophoresis, bone marrow biopsy, and radiographs of the bones commonly involved in multiple myeloma. Plain pelvic radiographs showed diffuse decreased bone density and a compression fracture (wedge deformity) of T12 (Fig. 2). Skull radiographs showed a characteristic punched-out appearance (Fig. 3). The patient was initially treated with melphalan-based high-dose chemotherapy and autologous stem cell transplantation followed by interferon maintenance therapy. Six years later, he relapsed and was retreated with bortezomib and dexamethasone chemotherapy. Bisphosphonates had been administered for seven years.

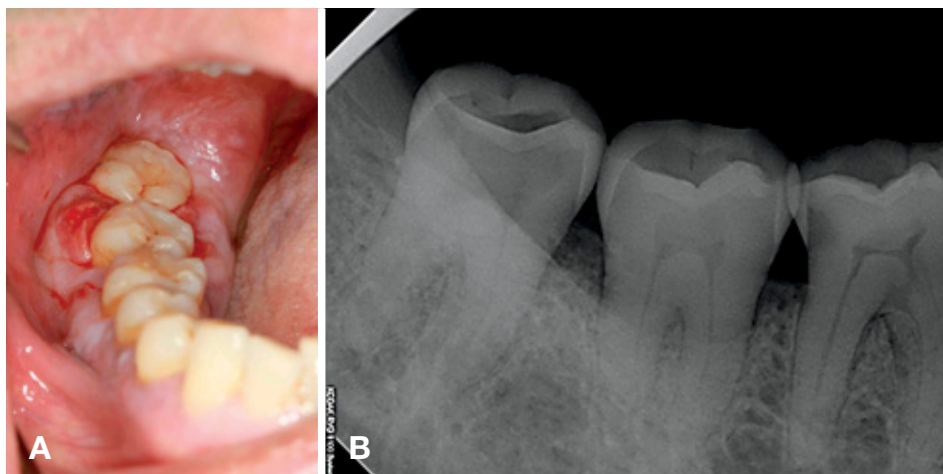
The patient returned to our emergency dental hospital four months later because he suddenly suffered from extreme pain due to a vertical fracture of the left maxillary second molar. The left second and third molars were extracted under local anesthesia. Unfortunately, the extraction resulted in a perforation of the left maxillary sinus floor. Ten days after the tooth extraction, the patient complained of discomfort and occasional pain around the extraction wound. Approximately 50 days after the extraction, pus discharge was observed from the wound (Fig. 4), and the patient was tentatively diagnosed with BRONJ. We continued to administer antibiotics and analgesics, in addition to saline rinsing of the wound.

A panoramic radiograph and computed tomograph per-

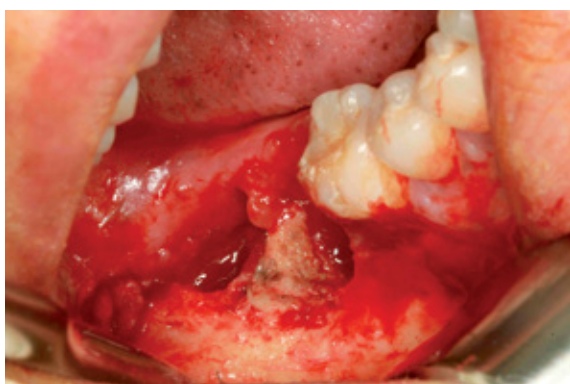

**Fig. 6.** A photograph shows the extracted premolars, the first molar, and a necrotized bone fragment.

formed 11 months later showed the pathologic bony fracture, sequestra formation, and irregular bone destruction (Fig. 5). Chronic maxillary sinusitis was also observed in the left maxillary sinus. The premolars and first molar were extracted, followed by the surgical removal of necrotized bone fragments and alveoplasty (Fig. 6), and the patient underwent continuous follow-up. After the removal of the necrotic bone and the surrounding tissue, the symptoms were relieved. Sudden pain and gingival swell-



**Fig. 7.** A. An intraoral photograph shows gingival swelling around the lower second and third molars. B. A periapical radiograph shows moderate periodontitis and proximal caries on the distal surface of the first molar.



**Fig. 8.** A photograph shows the necrotic interseptum of the right lower second molar.

ing occurred in the right mandibular posterior teeth six months later. An intraoral examination showed gingival swelling around the second and third molars. A periapical radiograph showed only moderate periodontitis and proximal caries on the distal surface of the first molar, but no specific finding of osteolysis related to osteonecrosis around the root surface was observed (Fig. 7). The interseptum of the right lower second molar was observed to be necrotic during surgery (Fig. 8). The diagnosis of BRONJ in the left maxilla and right mandible in a multiple myeloma patient was made based on these clinical and radiographic findings.

### Discussion

The diagnosis of multiple myeloma is based on several criteria, including the identification of an atypical plasma cell population on biopsy, abnormalities of immunoglobulin production, and evidence of end-organ damage, such

as osteolytic bone lesions, anemia, hypercalcemia, or renal insufficiency.<sup>13</sup> Multiple myeloma is common in patients older than 40 years of age, with a peak incidence rate at 60-70 years, and is rare in people younger than 30 years of age.<sup>14</sup> This patient was diagnosed at 50 years of age. The initial laboratory findings were 3.14 g/dL of serum M protein, clonal plasma cells comprising more than 10% of the bone marrow, and extensive osteolytic bone lesions without anemia, hypercalcemia, or renal insufficiency. Therefore, the patient was diagnosed with multiple myeloma of the IgG kappa type at Durie-Salmon stage IIIA.

Multiple myeloma commonly shows numerous punched-out areas of radiolucency on plain radiographs.<sup>15</sup> The osteolytic lesions of multiple myeloma are most commonly observed in the pelvis, spine, ribs, and skull.<sup>16</sup> Radiographic evidence of multiple myeloma in the jaw bones usually appears after extensive involvement of other bones, particularly the skull.<sup>8,17</sup> The mandible is more commonly affected by multiple myeloma than the maxilla, and the posterior region is more commonly involved than the anterior region.<sup>18</sup> In this case, the characteristic radiographic features of multiple myeloma were the punched-out appearance of the skull, the absence of detectable jaw lesions, and osteoporotic changes in the spine and pelvis. This presentation was similar to what has been described in other studies.<sup>17</sup> Interestingly, the jaw lesion, including the maxilla and mandible, did not show the characteristic bony rarefaction of multiple myeloma despite having existed for nine years.

BRONJ is a severe complication of bisphosphonate therapy.<sup>9</sup> Because of the prolonged duration of bisphosphonate treatment in multiple myeloma patients, BRONJ has frequently been observed in patients with multiple myeloma. With the increasing use of the bisphosphonate

class of drugs, dental professionals are likely to encounter more cases of BRONJ.<sup>19</sup>

The diagnostic criteria for BRONJ developed by the American Association of Oral and Maxillofacial Surgeon (AAOMS) include a history of bisphosphonate use, no history of radiotherapy, and the presentation of exposed, necrotic jaw bone for more than eight weeks.<sup>20</sup> Dental procedures or traumatic injuries are another significant factor contributing to the likelihood of osteonecrosis in the jaw.<sup>21</sup> Theoretically, trauma to the mucosa and the exposure of bone and surrounding tissues to microbial flora creates an acidic inflammatory milieu.<sup>19</sup>

In this case, the exposed bone area of the left maxilla was relatively large. The left maxilla had a pathologic bony fracture, sequestra formation, and irregular bone destruction, which are characteristic features of BRONJ on computed tomography. These radiographic and clinical features corresponded to the AAOMS criteria for BRONJ. BRONJ of the left maxilla occurred after tooth extraction, suggesting that an invasive dental procedure and the long administration of bisphosphonates were likely the etiologic factors. The right lesion occurred spontaneously, with the most likely etiologic factor being the prolonged administration of bisphosphonates.

In this case report, the characteristic radiographic features of multiple myeloma and BRONJ were presented. Interestingly, the maxillary and mandibular lesion showed no bony rarefaction, which is characteristic of multiple myeloma, but did show an osteonecrotic lesion related to bisphosphonate administration.

## References

1. Kyle RA. Multiple myeloma: review of 869 cases. *Mayo Clin Proc* 1975; 50: 29-40.
2. Batsakis JG. Pathology consultation. Plasma cell tumors of the head and neck. *Ann Otol Rhinol Laryngol* 1983; 92: 311-3.
3. Wingo PA, Tong T, Bolden S. Cancer statistics, 1995. *CA Cancer J Clin* 1995; 45: 8-30.
4. Holland J, Trenkner DA, Wasserman TH, Fineberg B. Plasmacytoma. Treatment results and conversion to myeloma. *Cancer* 1992; 69: 1513-7.
5. Kyle RA. Diagnostic criteria of multiple myeloma. *Hematol Oncol Clin North Am* 1992; 6: 347-58.
6. Lee SH, Huang JJ, Pan WL, Chan CP. Gingival mass as the primary manifestation of multiple myeloma: report of two cases. *Oral Surg Oral Med Oral Pathol Oral Radiol Endod* 1996; 82: 75-9.
7. Epstein JB, Voss NJ, Stevenson-Moore P. Maxillofacial manifestations of multiple myeloma. An unusual case and review of the literature. *Oral Surg Oral Med Oral Pathol* 1984; 57: 267-71.
8. Lambertenghi-Deliliers G, Bruno E, Cortelezzi A, Fumagalli L, Morosini A. Incidence of jaw lesions in 193 patients with multiple myeloma. *Oral Surg Oral Med Oral Pathol* 1988; 65: 533-7.
9. Mondello P, Pitini V, Arrigo C, Mondello S, Mian M, Altavilla G. Necrotizing fasciitis as a rare complication of osteonecrosis of the jaw in a patient with multiple myeloma treated with lenalidomide: case report and review of the literature. *Springerplus* 2014; 3: 123.
10. Coleman R, Gnant M, Morgan G, Clezardin P. Effects of bone-targeted agents on cancer progression and mortality. *J Natl Cancer Inst* 2012; 104: 1059-67.
11. Lee SH, Chan RC, Chang SS, Tan YL, Chang KH, Lee MC, et al. Use of bisphosphonates and the risk of osteonecrosis among cancer patients: a systemic review and meta-analysis of the observational studies. *Support Care Cancer* 2014; 22: 553-60.
12. Utreja A, Almas K, Javed F. Dental extraction as a risk factor for bisphosphonate related osteonecrosis of the jaw in cancer patients: an update. *Odontostomatol Trop* 2013; 36: 38-46.
13. Sukpanichnant S, Cousar JB, Leelasiri A, Graber SE, Greer JP, Collins RD. Diagnostic criteria and histologic grading in multiple myeloma: histologic and immunohistologic analysis of 176 cases with clinical correlation. *Hum Pathol* 1994; 25: 308-18.
14. Bladé J, Kyle RA, Greipp PR. Multiple myeloma in patients younger than 30 years. Report of 10 cases and review of the literature. *Arch Intern Med* 1996; 156: 1463-8.
15. Matsumura S, Kishino M, Ishida T, Furukawa S. Radiographic findings for solitary plasmacytoma of the bone in the anterior wall of the maxillary sinus: a case report. *Oral Surg Oral Med Oral Pathol Oral Radiol Endod* 2000; 89: 651-7.
16. Croucher PI, Apperley JF. Bone disease in multiple myeloma. *Br J Haematol* 1998; 103: 902-10.
17. Mozaffari E, Mupparapu M, Otis L. Undiagnosed multiple myeloma causing extensive dental bleeding: report of a case and review. *Oral Surg Oral Med Oral Pathol Oral Radiol Endod* 2002; 94: 448-53.
18. Yaegaki K, Kameyama T, Takenaka M, Kimura T, Sujaku C, Tanimura A. Myelomatosis (IgD, lambda) discovered by oral manifestation. *Int J Oral Surg* 1985; 14: 381-4.
19. Badros A, Weikel D, Salama A, Goloubeva O, Schneider A, Rapoport A. Osteonecrosis of the jaw in multiple myeloma patients: clinical features and risk factors. *J Clin Oncol* 2006; 24: 945-52.
20. Advisory Task Force on Bisphosphonate-Related Osteonecrosis of the Jaws, American Association of Oral and Maxillofacial Surgeons. American Association of Oral and Maxillofacial Surgeons position paper on bisphosphonate-related osteonecrosis of the jaws. *J Oral Maxillofac Surg* 2007; 65: 369-76.
21. Assael LA. New foundations in understanding osteonecrosis of the jaws. *J Oral Maxillofac Surg* 2004; 62: 125-6.