



# Effectiveness of Computed Tomography for Blow-out Fracture

Seung-Hyun Rhee, Tae-Seup Kim, Jae-Min Song, Sang-Hoon Shin, Jae-Yeol Lee

Department of Oral and Maxillofacial Surgery, School of Dentistry, Pusan National University

## Abstract

**Purpose:** This study assessed the association between eye symptoms (enophthalmos or diplopia) and site of damage, volume, deviated inferior rectus muscle (IRM) and type of fracture with computed tomography (CT). The intent is to anticipate the prognosis of orbital trauma at initial diagnosis.

**Methods:** Forty-five patients were diagnosed with fractures of the inferior wall of one orbit. Fracture area, volume of displaced tissue, deviated IRM, and type of fracture were evaluated from coronal CT by one investigator. The association of those variables with the occurrence of eye symptoms (diplopia and enophthalmos) was assessed.

**Results:** Of 45 patients, 27 were symptom-free (Group A) and 18 had symptoms (Group B) of enophthalmos and/or diplopia. In Group B, 12 had diplopia, one was enophthalmos, and five had both. By CT measurement, group A mean area was 192.6 mm<sup>2</sup> and the mean volume was 673.2 mm<sup>3</sup>. Group B area was 316.2 mm<sup>2</sup> and volume was 1,710.6 mm<sup>3</sup>. The volume was more influential on symptom occurrence. Each patient was categorized into four grades depending on the location of IRM. Symptom occurrence and higher grade were associated. Twenty-six patients had trap-door fracture (one side, attached to the fracture), and 19 had punched-out fracture (both sides detached). The punched-out fracture was more strongly associated with symptoms and had statistically significantly higher area and volume.

**Conclusion:** In orbital trauma, measurement of fracture area and volume, evaluation of the deviated IRM and classification of the fracture type by coronal CT can effectively predict prognosis and surgical indication.

**Key words:** Orbital injury, Blow-out fractures, Computed tomography, Volume measurement

## Introduction

Blow-out fracture of the inferior orbital wall is defined as fracture of an outer wall that supports the lower part of an orbit by the impact of blunt trauma, producing increased internal pressure[1]. Orbit damage makes up 18% to 50% of maxillofacial trauma[2]. The importance of the diagnosis to treatment of the blow-out fracture is rising

because of industrialization, increasing transportation speed, and increased violent accidents[3].

For the diagnosis of orbital trauma, computed tomography (CT) is the most accurate radiologic imaging technique. Although a fracture of the orbital inferior wall was in the past often difficult to detect by two-dimensional radiography, CT allows these injuries to be diagnosed much more readily. The coronal plane of CT is especially useful

RECEIVED September 25, 2014, REVISED October 8, 2014, ACCEPTED October 29, 2014

Correspondence to Jae-Yeol Lee

Department of Oral and Maxillofacial Surgery, Pusan National University Hospital, School of Dentistry, Pusan National University  
179 Gudeok-ro, Seo-gu, Busan 602-739, Korea  
Tel: 82-51-240-7431, Fax: 82-51-231-7429, E-mail: omslly@pusan.ac.kr

Copyright © 2014 by The Korean Association of Maxillofacial Plastic and Reconstructive Surgeons. All rights reserved.

© This is an open access article distributed under the terms of the Creative Commons Attribution Non-Commercial License (<http://creativecommons.org/licenses/by-nc/3.0>) which permits unrestricted non-commercial use, distribution, and reproduction in any medium, provided the original work is properly cited.

for the inferior wall fracture. While CT is more accurate, there are no obvious guidelines to predict prognosis or to decide surgical repair[4]. Evaluating the location and amount of fracture with altered volume and extents of orbit provides objective indicator of a blow-out fracture.

This study assessed the association between eye symptoms (enophthalmos or diplopia) and site of damage, volume, deviated inferior rectus muscle (IRM) and type of fracture with CT. The intent is to anticipate the prognosis of orbital trauma at the early stage and provide indications to decide surgical repair.

## Materials and Methods

From January 2009 to April 2014, 63 patients who came to Pusan National University Hospital with a chief complaint of orbital injury were diagnosed with orbital floor fracture. Patients with fracture of both orbits were excluded because it was impossible to measure the relative value of fragment deviation. This study included 45 patients with one-sided blow-out fracture. Of these patients, 39 were males and six were females. The mean age was 38.9 years. Every patient underwent CT, and age, sex, cause of injury, location of fracture, and symptoms were documented in the medical record. Of the patients who underwent surgery, the following were evaluated: operating method, material, change in symptom, diplopia, and the limit of eyeball movement. Symptoms of diplopia and enophthalmos were evaluated. Enophthalmos was measured using Hertel's exophthalmometer[5]. If the difference was more than 2 mm, it was judged that patient had enophthalmos[6]. Diplopia was evaluated based on patients' subjective complaint.

One inspector measured the area and volume of bony fragmentation by coronal CT image. The boundary was sectioned into anterior border (50% of infraorbital rim using coronal plane image's boundary), posterior border (optic canal), and medial border (ethmoidomaxillary suture) (Fig. 1)[7]. To measure the area and volume, the length of orbital floor (L), length between medial anatomic landmark to fragment's internal border (X) and external border (Y), and each fragment of volume in the bone fragment's movement was measured. For each measured value, CT slice (3 mm) was multiple to estimate the area of bone fragment

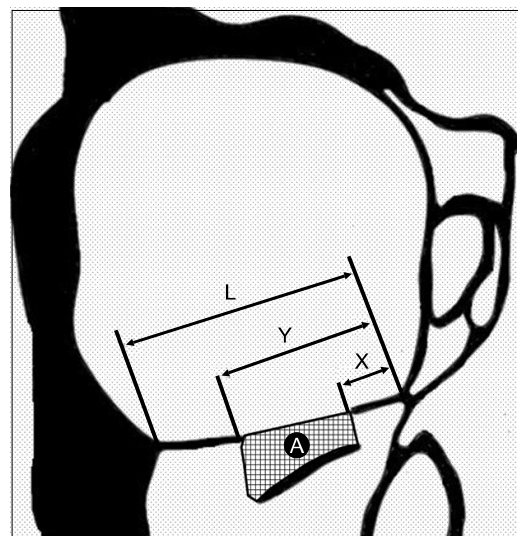
as well as the absolute value of malposition volume. Relative value was calculated by dividing non-damaged side of orbital floor length and volume of orbit[8].

$$V = \frac{(S \times \sum_n^{N-1} A_n)}{V_0}$$

$$E = S \times \sum_n^{N-1} \left( \frac{Y-X}{L} \right)$$

V=displaced tissue volume, S=slice (3 mm), N=total number of slices, V<sub>0</sub>=volume of opposite orbital side, E=area of fracture segment

Displacement of the IRM increases the risk of eye symptoms. IRM displacement was classified by the relative location of IRM and an imaginary line between the medial and lateral boundary of the fracture site on the sagittal plane (Fig. 2). If the line is located just above the orbital floor, IRM displacement is classified as Grade 1, the line lying on the orbital floor but more than half located inside the orbit is Grade 2, more than half of the line outside of the orbit is classified as Grade 3, and completely outside of the orbit is Grade 4[9]. Lastly, symptoms by fracture type were examined. There are two broad types of inferior orbital wall fracture: trap-door (one side of bone fragment is attached to the orbital floor), and punched-out (both



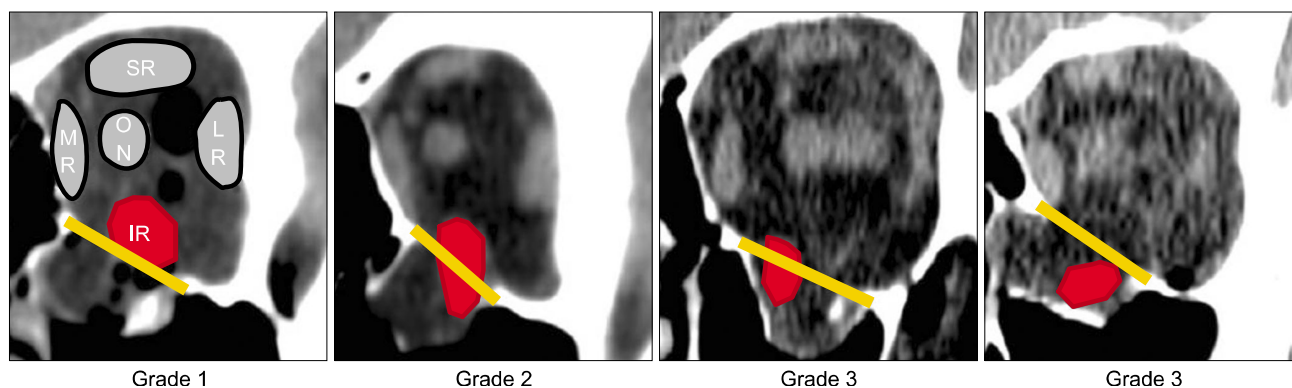
**Fig. 1.** Schematic drawing of right orbit. The distances from the ethmoidomaxillary suture to the medial (X) and lateral boundary (Y) of the fracture and to the lateral border of the orbital floor (L) are shown. The area of displaced tissue (A) is shown as a lattice pattern.

sides of bone fragment are unattached) (Fig. 3). In this study, 34 patients suffered trap-door fractures and 11 punched-out.

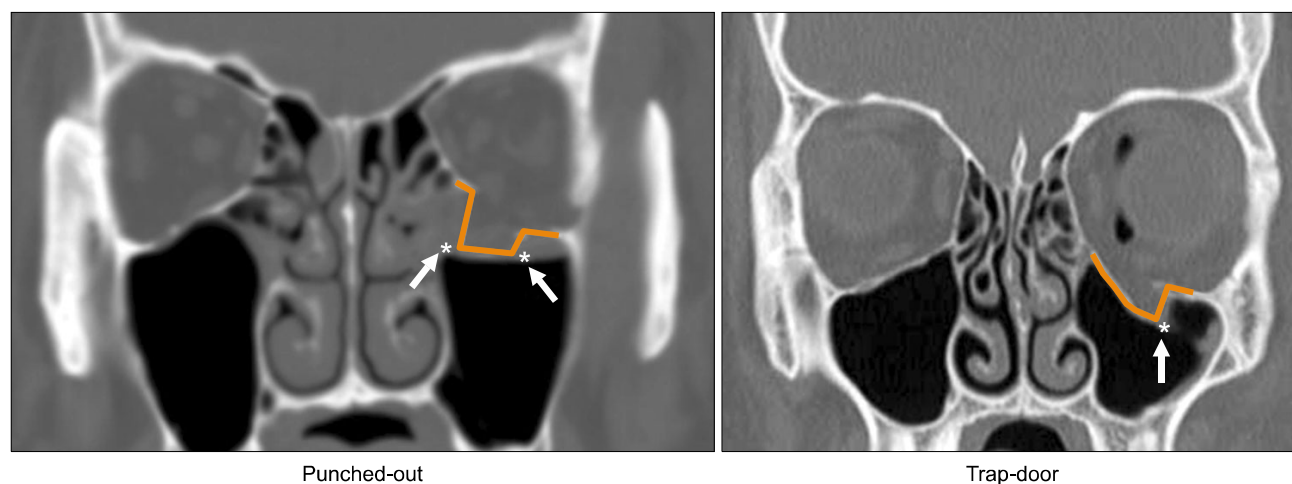
The authors assessed the association between symptom status (enophthalmos or diplopia) and site of damage, volume, deviated IRM and type of fracture with CT using the non-parametric Mann-Whitney test or Kendall's tau as appropriate. Kendall's tau (a type of rank correlation) provides a distribution-free test of independence and a measure of the strength of association between two variables. Null hypotheses of no association were rejected if *P*-values were less than 0.05. Data were analysed using the IBM SPSS Statistics ver. 20.0 (IBM Co., Armonk, NY, USA).

## Results

Of 45 patients, 39 (86.7%) were male and 6 (13.3%) were female. The mean age was 38.5 years. The patients were sorted into two groups based on symptom status (enophthalmos or diplopia). The symptom-free group (Group A) included 27 patients, of whom five underwent surgery. Although these five patients had no symptoms, they underwent surgical reconstruction of the orbital floor because their displacement was large enough to predict delayed symptom occurrence. The symptomatic group (Group B) had enophthalmos and/or diplopia. This group consisted of 18 people: 12 with diplopia, one with enophthalmos, and five with both. All patients who had symp-



**Fig. 2.** Coronal computed tomographic slices and schematics of left fractured orbits representing the muscular subscore. If the line is located just above the orbital floor, IR displacement is classified as Grade 1, the line lying on the orbital floor but more than half located inside the orbit is Grade 2, more than half of the line outside of the orbit is classified as Grade 3, and completely outside of the orbit is Grade 4[9]. SR, superior rectus muscle; MR, medial rectus muscle; ON, optical nerve; LR, lateral rectus muscle; IR, inferior rectus muscle.



**Fig. 3.** The two types of inferior orbital wall fracture. There are two broad types of inferior orbital wall fracture: trap-door (one side of bone fragment is attached to the orbital floor), and punched-out (both sides of bone fragment are unattached). Arrows are instruct the fracture line.

toms underwent surgery (Table 1). The association of the primary outcome, symptoms of diplopia or enophthalmos, was tested with three predictor variables: the extent of the damaged area by volume, the amount of IRM deviation, and type of fracture.

**1. The effect of fracture area and the herniated volume on symptom status**

By CT measurement, the average fracture area was 242.0 mm<sup>2</sup> (12.4~737.0 mm<sup>2</sup>) and average herniated volume of inferior wall was 10,88.2 mm<sup>3</sup> (13.2~4,172.2 mm<sup>3</sup>) (Table 2). The Group A mean area was 192.6 mm<sup>2</sup> (12.4~426.0 mm<sup>2</sup>) and mean volume was 673.2 mm<sup>3</sup> (13.2~2,343.0 mm<sup>3</sup>). The Group B area was 316.2 mm<sup>2</sup> (95.7~737.0 mm<sup>2</sup>) and volume was 1,710.6 mm<sup>3</sup> (275.4~4,172.2 mm<sup>3</sup>). Symptom status was associated with both affected area and herniated volume (*P*<0.05). The comparative effect of volume and area on symptom status was analyzed by Kendall's tau test. The association of volume with symptom

status by Kendall's tau was 0.07, smaller than the association of area with symptom status, 0.28. Our interpretation is that volume is more influential in symptom status. Whether symptom status included both diplopia and enophthalmos or just one symptom did not affect the associations with area and volume.

**2. Does the displacement degree of IRM affect the symptom occurrence?**

IRM displacement was categorized into four grades by the location of rectus muscle. In Group A, 12 patients were grade 1, 11 were Grade 2, four were Grade 3, and none were Grade 4. Of Group B patients, three were Grade 1, two were Grade 2, six were Grade 3, and six were Grade 4 (Table 3). Symptom status and higher grade were associated based on the correlation analysis in groups (*P*<0.05). Although correlation between the displacement of IRM and the area of fracture site was low, the connection with displaced volume is statistically significant. Also, both

**Table 1.** Patients by symptom status

Group	Age (yr)	Location (right:left)	Symptom (diplopia:enophthalmos)	Surgical treatment
Group A (n=27)	44.05 (17~72)	13:14	None	6 (22.2)
Group B (n=18)	34.3 (10~57)	8:10	11:2 (5 were both)	18 (100)
Total (n=45)	38.5 (10~72)	21:24		6 (13.3)

Values are presented as median (range), number only, or number (%).

**Table 2.** Relationship of calculated values of orbital volume, extents of fracture segment, herniated volume with symptom status

	Area ( <i>P</i> =0.029)			Volume ( <i>P</i> =0.007)		
	Non-affected site (mm <sup>2</sup> )	Affected site (mm <sup>2</sup> )	Relative area (%)	Non-affected site (mL)	Affected site (mm <sup>3</sup> )	Relative volume (%)
Group A	807.6±23.4	192.6±112.1	23.9±14.1	22.8±1.6	673.2±541.7	3.0±2.3
Group B	832.1±28.3	316.2±181.3	37.7±21.2	22.4±1.8	1,710.6±1,243.7	7.7±5.7
Total	817.4±28.2	242.0±156.0	29.4±18.6	22.6±1.7	1,088.2±1,026.2	4.9±4.6

Values are presented as mean±standard deviation.

**Table 3.** Relationship of IRM position, fracture segment area, and herniated volume in each group

	Group A			Group B		
	No. of patients	Area (mm <sup>2</sup> ) ( <i>P</i> =0.62)	Volume (mm <sup>3</sup> ) ( <i>P</i> =0.03)	No. of patients	Area (mm <sup>2</sup> ) ( <i>P</i> =0.53)	Volume (mm <sup>3</sup> ) ( <i>P</i> =0.02)
Grade 1	12	88.4±179.1	311.3±179.1	3	113.5±17.0	380.5±94.5
Grade 2	11	258.8±659.3	659.3±135.7	3	133.2±31.0	476.9±52.4
Grade 3	4	40.9±420.8	1,797.0±420.8	6	308.1±57.0	1,452.2±192.1
Grade 4	0	0	0	6	517.0±130.5	3,250.9±716.0

Values are presented as number only or mean±standard deviation. Symptom status and higher grade were associated based on the Mann-Whitney test (*P*=0.001).

diplopia and enophthalmos occurred when IRM displacement degree was high.

### 3. Are type of fracture and symptom occurrence associated?

There were 26 patients with trap-door fracture (one side-attached to the fracture) and 19 with punched-out (both sides detached). In Group A, there were 19 trap-door type and eight punched-out type. In Group B, 11 patients had trap-door type and seven punched-out. The punched-out type is more strongly associated with symptom status and is statistically significantly associated with increase of area and volume ( $P < 0.05$ ) (Table 4). Four out of five patients with two symptoms had punched-out fractures.

## Discussion

Surgical reconstruction of orbit wall must be considered when traumatic diplopia and enophthalmos occur. However, because symptoms can occur not just immediately after the injury but after two or three weeks have passed, deciding whether to treat surgically is difficult[10]. Therefore, it is important to predict whether the orbit wall fracture will cause delayed eye symptoms like diplopia or enophthalmos.

Commonly used surgical indications for reconstructing the orbit wall are clinical diplopia, herniation of orbital tissue on CT image, enophthalmos more than 2 mm, and large fracture that passes over half of orbital bone[11-14]. In this study, criteria predictive of symptom status were examined using the most generalized medium for diagnosis, CT.

Manson *et al.*[5] insisted that the degree of enophthalmos is directly proportional to the herniated volume of orbital tissue caused by a blow-out fracture that widens the fracture area. Measuring the altered area and volume of orbital

floor fracture using CT will be helpful to predict the degree of enophthalmos and to decide the feasibility of surgery. There are many methods for measuring the volume and area of orbital floor fracture. Ploder *et al.*[8] found area and volume of deviated orbital tissue by measuring the width and height of fracture on coronal plane. Jin *et al.*[15] assumed that the deviated fragment is an oval, and calculated the area and volume of tissue fallen off by measuring width, length and height. The volume of the injured orbit can nowadays be compared with the non-affected side using three-dimensional images. In this case, the error can occur up to 7% to 8% in volume difference of both orbits and error can be made by each observer who establishes the orbit area. In this study, area and volume of fragment were calculated by adding up the length and width of bone fragments in each coronal CT image. By using this method, relative accuracy can be secured by measurement reproducibility in definite anatomical structure[16].

In this study, the association of eye symptoms with types of fracture, location of IRM, and area and volume of bone fragment measured using CT was evaluated. The findings were interpreted to mean that as deviated bone fragment area and volume of herniated tissue increase, the more symptoms occur. Also, of volume and area, volume is more strongly associated with symptom status.

Group A and B, divided into four grades of IRM, were compared. The presence of symptoms is highly related to the IRM Grade 3 and 4. Therefore, malposition of IRM by more than half of the orbital floor significantly affects the presence of symptoms. Moreover, aggravation of symptoms is also related to IRM. Three of 13 (23.1%) patients who had one symptom were Grade 4 while three of five (60%) patients who had both eye symptoms were Grade 4 (IRM with complete orbital floor herniation). Schouman *et al.*'s research[9] yielded results similar to ours. Schouman *et al.*[9] insisted that surgery be considered when the Grade was more than 2, and occurrence of symptoms was more

**Table 4.** Relationship of fracture type, area, and volume in each group

	Group A			Group B		
	No. of patients	Area (mm <sup>2</sup> )	Volume (mm <sup>3</sup> )	No. of patients	Area (mm <sup>2</sup> )	Volume (mm <sup>3</sup> )
Punched out ( $P=0.03$ )	8	196.4±90.4	708.1±364.9	11	330.3±165.5	1,705.0±993.0
Trap door ( $P=0.062$ )	19	191.0±120.0	658.5±600.1	7	293.9±201.6	1,719.4±1,558.1

Values are presented as number only or mean±standard deviation.

frequent in Grade 3 and 4.

According to Thaller-Antlanger's research[17], type of fracture had a significant effect on prognosis, with punched-out fracture followed by orbital rim fracture predicting a poor prognosis. We found that punched-out type were less common (42%), and more related to occurrence of symptoms than trap-door type. Punched-out fractures had higher volume and area. In addition, four out of five patients who had enophthalmos and diplopia had punched-out fractures.

A 57-year-old female patient presented with a punched-out type fracture by CT resulting from a pedestrian traffic accident. Her symptoms were not serious, with no transition of bone fragment, and no enophthalmos and/or diplopia. After two weeks, she had delayed surgery because enophthalmos of 2 mm and slight diplopia developed. Presumably, two bone fragments could not support the orbit structure due to gravity and the symptoms developed. Such an unusual case helps support the hypothesis that punched-out type fractures have a stronger association with symptom occurrence.

This study was limited in several ways. The sample size was small, and, especially, Grade 3 and 4 of serious IRM deviation were few. Measurement reproducibility on CT, measuring area and volume of deviated bone fragment was difficult.

To conclude from our results, area, volume, location of IRM, and type of fracture are all related to eye symptoms. In orbital trauma, measurement of fracture area and volume, evaluation of the deviated IRM and classification of the fracture type by coronal CT are effective for predicting the prognosis and surgical indication. Among these, the volume of deviated tissue is more strongly related to symptoms than the area of bone fragment. When the IRM is more than half out of orbital floor, punched-out fractures have a higher risk of symptom occurrence and surgical treatment should be considered to reconstruct the structure.

## Conclusion

This study investigated and targeted 45 patients with orbital blow-out fracture visiting the Department of Oral and Maxillofacial Surgery of the Dental Clinic Center in Pusan National University Hospital located at Busan, in-

cluding both outpatient and emergency room visits from January 2009 to April 2014. The purpose of this study is to review the association between the occurrence of enophthalmos or diplopia, and damaged area, volume, deviated IRM and type of fracture by using the CT, to anticipate the prognosis of orbital trauma on the early stage, and to provide an indicator for the decision of surgical reconstruction of the orbital floor. The results of the investigation are shown below.

1. The more deviated bone fragment area and volume of herniated tissue increase, the stronger the risk of symptom occurrence. Also, between volume and area, volume is more related.

2. Deviation of IRM more than half of orbital floor (Grade 3 and 4) affects significantly the occurrence of symptoms.

3. While punched-out fractures are less common, they are more associated with occurrence of symptoms than trap-door type and are more important in the increase of volume and area.

Injured orbital area, herniated volume, deviation of IRM and type of fracture are all related to eye symptoms. In orbital trauma, measurement of fracture area and volume, evaluation of the deviated IRM and classification of the fracture type by coronal CT are effective for the management of orbital trauma and predicting the prognosis.

## Acknowledgements

This work was supported by a Pusan National University Research Grant, 2014.

## References

1. Kelley P, Crawford M, Higuera S, Hollier LH. Two hundred ninety-four consecutive facial fractures in an urban trauma center: lessons learned. *Plast Reconstr Surg* 2005;116:42e-9e.
2. Cheong EC, Chen CT, Chen YR. Broad application of the endoscope for orbital floor reconstruction: long-term follow-up results. *Plast Reconstr Surg* 2010;125:969-78.
3. Kim HG, Son YH, Chung IK. Facial bone fracture patients visiting Pusan National University Hospital in Busan and Yangsan: trends and risks. *Maxillofac Plast Reconstr Surg* 2014;36:140-5.
4. Gosse EM, Ferguson AW, Lymburn EG, Gilmour C, MacEwen CJ. Blow-out fractures: patterns of ocular motility and effect of surgical repair. *Br J Oral Maxillofac Surg* 2010; 48:40-3.
5. Manson PN, Grivas A, Rosenbaum A, Vannier M, Zinreich J,

- Iliff N. Studies on enophthalmos: ii. The measurement of orbital injuries and their treatment by quantitative computed tomography. *Plast Reconstr Surg* 1986;77:203-14.
6. Jang HS, Leem DH, Baek JA, Shin HK, Ko SO. Degree of enophthalmos according to the extent of orbital wall fracture and volume of herniated orbital tissue. *J Korean Assoc Oral Maxillofac Surg* 2011;37:205-13.
  7. Jeon J, Chon KM, Jung TY, Noh WJ, Kwon JH, Kim YH. Relationship between degree of enophthalmos and orbital volume measured with computed tomography in isolated blow-out fractures of the orbit. *Korean J Otorhinolaryngol-Head Neck Surg* 2009;52:810-5.
  8. Ploder O, Klug C, Voracek M, Burggasser G, Czerny C. Evaluation of computer-based area and volume measurement from coronal computed tomography scans in isolated blowout fractures of the orbital floor. *J Oral Maxillofac Surg* 2002;60:1267-72.
  9. Schouman T, Courvoisier DS, Van Issum C, Terzic A, Scolozzi P. Can systematic computed tomographic scan assessment predict treatment decision in pure orbital floor blowout fractures? *J Oral Maxillofac Surg* 2012;70:1627-32.
  10. Hammer B, Prein J. Correction of post-traumatic orbital deformities: operative techniques and review of 26 patients. *J Craniomaxillofac Surg* 1995;23:81-90.
  11. Dutton JJ. Management of blow-out fractures of the orbital floor. *Surv Ophthalmol* 1991;35:279-80.
  12. Dullely B, Fells P. Long-term follow-up of orbital blow-out fractures with and without surgery. *Mod Probl Ophthalmol* 1975;14:467-70.
  13. Osguthorpe JD. Orbital wall fractures: evaluation and management. *Otolaryngol Head Neck Surg* 1991;105:702-7.
  14. Hawes MJ, Dortzbach RK. Surgery on orbital floor fractures. Influence of time of repair and fracture size. *Ophthalmology* 1983;90:1066-70.
  15. Jin HR, Shin SO, Choo MJ, Choi YS. Relationship between the extent of fracture and the degree of enophthalmos in isolated blowout fractures of the medial orbital wall. *J Oral Maxillofac Surg* 2000;58:617-20.
  16. Parsons GS, Mathog RH. Orbital wall and volume relationships. *Arch Otolaryngol Head Neck Surg* 1988;114:743-7.
  17. Thaller-Antlanger H. Orbital wall fracture from the ophthalmologic viewpoint. *Ther Umsch* 1990;47:279-88.