

Submitted:  
20.12.2016  
Accepted:  
24.04.2017  
Published:  
29.09.2017

## Usefulness of ultrasonography in the diagnosis of hematoma after primary hip arthroplasty

Jerzy Białecki<sup>1</sup>, Paweł Bartosz<sup>1</sup>, Wojciech Marczyński<sup>1</sup>, Jan Zajac<sup>2</sup>

<sup>1</sup> Medical Centre for Postgraduate Education, Professor Adam Gruca Independent Public Teaching Hospital in Otwock, Orthopedics Unit, Department of Endoprosthetics, Otwock, Poland

<sup>2</sup> Medical Centre for Postgraduate Education, Professor Adam Gruca Independent Public Teaching Hospital in Otwock, Department of Medical Imaging, Otwock, Poland

Correspondence: Jerzy Białecki, Konarskiego 13, 05-400 Otwock, Poland, tel.: +48 22 779 40 31 ex. 374, e-mail: klin\_ortop.a.grucy@wp.pl

DOI: 10.15557/JoU.2017.0022

### Keywords

ultrasonography,  
drainage,  
arthroplasty,  
hip

### Abstract

**Introduction:** To date, suction drainage has been routinely used after hip joint replacement. Currently, the validity of this practice is questioned in the literature. Hematoma is a risk factor of periprosthetic infection. Post-operative ultrasonography enables precise assessment of hip joint hematoma. **Aim:** The aim of the study was to evaluate the usefulness of hip joint ultrasonography with respect to the validity of using suction drainage after primary hip arthroplasty. **Material:** Inclusion criteria: coxarthrosis. Exclusion criteria: primary and secondary coagulopathy, renal or hepatic failure and history of venous or arterial thrombosis. In total, 90 patients were enrolled. **Methods:** The study was prospective. The patients were assigned into groups in accordance with simple randomization. On the third day post-surgery, an ultrasound examination was conducted in all patients. **Results:** Deep infection was found in two patients with suction drainage. Hematoma was almost twice bigger in the drainage group. There were no statistically significant differences in the Harris Hip Score between the groups. No statistically significant differences were found between the groups in: complete blood count parameters and C-reactive protein values in the first and third day after surgery, the amount of transfused packed red blood cells, duration of hospital stay, cost of hospital stay and the relationship between osteophyte removal and hematoma size. **Conclusions:** Ultrasonography performed after hip replacement surgeries is useful in the assessment of hematoma. The randomized study did not reveal statistically significant differences between the group with and without drainage, thus suggesting that this practice can be abandoned, except for selected cases. Due to a short hospital stay, it is recommended to conduct an ultrasound scan in addition to routine radiography and laboratory tests in order to reduce the risk of complications.

## Introduction

Ageing of the population as well as higher and higher requirements concerning the quality of life result in an increased number of hip replacement procedures performed each year<sup>(1)</sup>. In the United States, the number of such procedures is projected to increase by 173% from 2015 to 2030<sup>(2)</sup>. According to data of the Polish National Health Fund, the number of primary surgeries performed in Poland was 39,349 in 2013 and 46,685 in 2015, which constitutes an

increase by 18%. The number of revision procedures after hip joint replacement was 3,598 in 2013 and 4,200 in 2015, which is an increase by 16%<sup>(3)</sup>. In the past, nearly all procedures of this type ended with suction drainage for 24–48 hours. Currently, opinions about the validity of this management vary. Moreover, there is no agreement on this issue in the literature<sup>(4–6)</sup>. Supporters of suction drainage of postoperative wounds emphasize the need to remove a hematoma, which increases the risk of periprosthetic infection, from the area of the endoprosthesis. Opponents, on the other

hand, claim that drainage itself increases the risk of such an infection significantly, which confirms the Philadelphia consensus<sup>(7)</sup>. The usage of postoperative ultrasonography enables thorough assessment of the periprosthetic area of the hip joint with its surrounding tissues, helps observe the healing process and detect potential early causes of failure<sup>(8–10)</sup>. Apart from its application in the diagnosis of fluid collections, US also helps in hematoma evacuation by ultrasound-guided aspiration. In a postoperative scan (2–5 days after surgery), the distance between the endoprosthesis and capsule is 6 mm, deep fluid collections is up to 21 mm and superficial fluid collections up to 28 mm<sup>(11)</sup>. US results are deemed abnormal when these values are exceeded. In combination with the clinical data, this information constitutes an important element determining further treatment. The differentiation in US between uncomplicated and infected hematoma is problematic. Typical signs of infection, such as hyperemia or edema, are not diagnostic in the postoperative period. In most cases, it is necessary to collect a sample from a fluid collection for microbiological tests. The usage of ultrasonography is also indicated in evacuation of extracapsular hematomas in order to avoid unnecessary puncture of the capsule and transfer of potential bacterial flora from the hematoma or skin onto the endoprosthesis. Moreover, this imaging modality frequently enables assessment of other pathologies, such as: pseudotumor, gluteus muscle tendinopathy, conflicts between the iliopsoas and prosthetic acetabulum or sciatic nerve injuries<sup>(12,13)</sup>. A US examination is a significant element of postoperative management in both short- and long-term follow-up.

## Aim

The aim of the study was to evaluate periprosthetic hip joint US in terms of the validity of using suction drainage after primary hip arthroplasty.

## Material

This clinical study was approved by the Ethics Committee of the Medical Centre for Postgraduate Education by virtue of the resolution of March 9th 2016. The clinical material consisted of patients hospitalized at the Department of Endoprosthetics, Orthopedics Unit of the Medical Centre for Postgraduate Education in Otwock, Poland from March 14th 2016 to September 19th 2016. The study is ongoing. Inclusion criteria were: primary or secondary hip arthropathy. Exclusion criteria were: primary and secondary coagulopathy, renal or hepatic failure and history of venous or arterial thrombosis.

The investigated group consisted of 90 patients, including 51 women and 39 men. The mean age of the patients was 61 years. The patients were operated with the diagnosis of primary osteoarthritis (51 patients), osteoarthritis with dysplasia (24) and necrosis of the femoral head (15). Suction drainage after surgery was used in 49 patients, and was not used in the remaining 41 patients. The mean follow-up was 18 weeks (2–29).

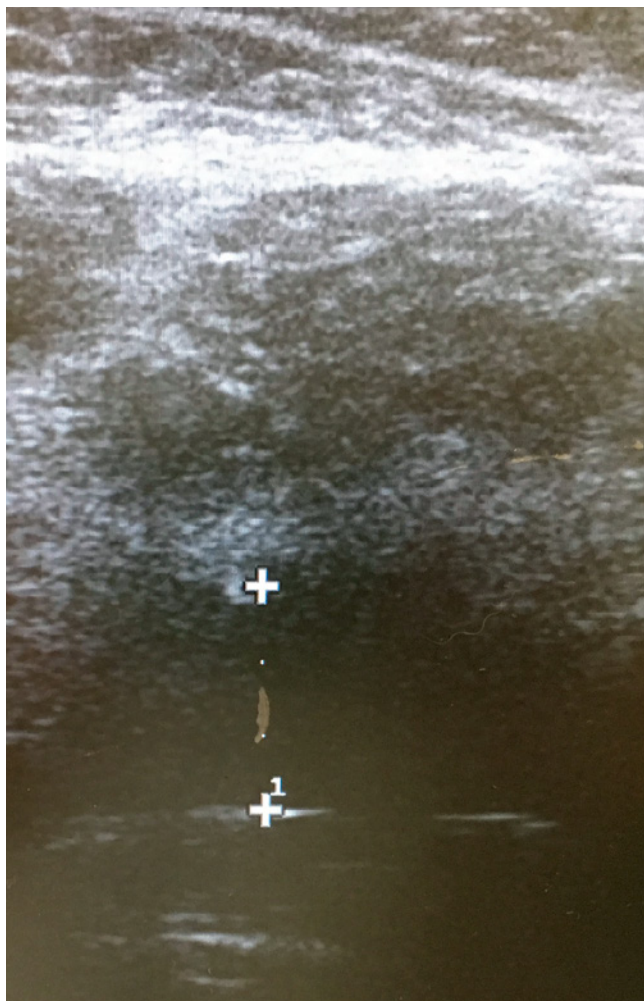
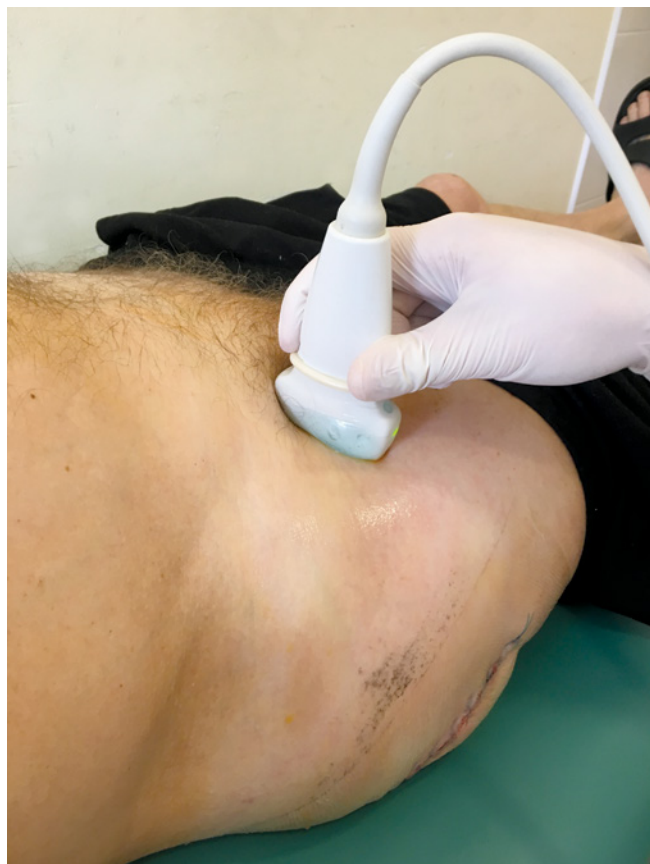

Fig. 1. Fluid level measurement at the prosthesis neck

## Methods

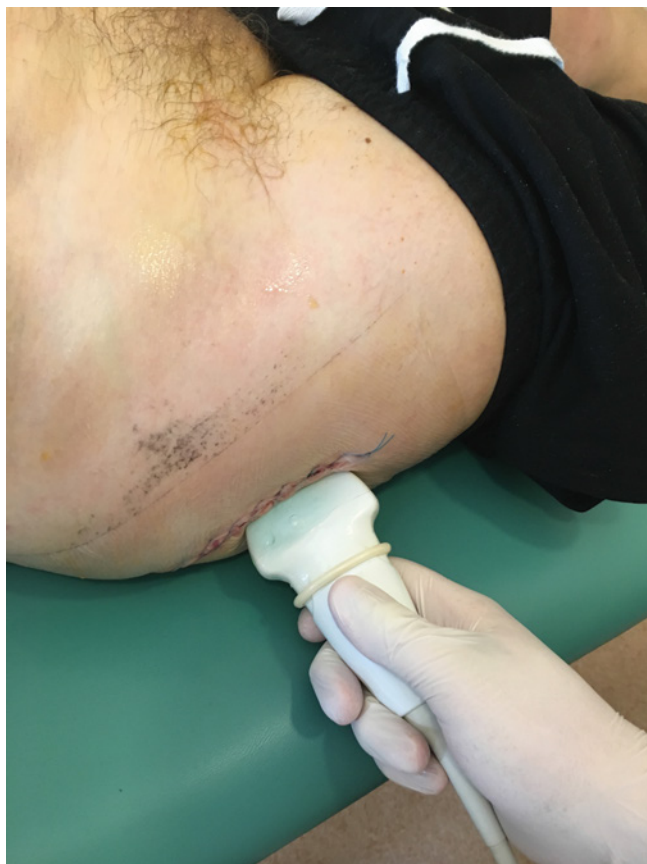The patients were randomized into two groups: with and without drainage, in accordance with simple randomization. The participants were selected based on inclusion and exclusion criteria. All patients gave written consent to the participation in the study. Envelopes with group allocation were opened at the end of the surgery when a decision about drainage was being made. All patients underwent standard perioperative preparation. Antithrombotic prophylaxis with low-molecular-weight heparin was adjusted to body weight. The first dose was administered 12 hours before the procedure. Tranexamic acid (Exacyl) at a dose of 15 mg/kg of the body mass was used in all patients 10 minutes before incision. The procedure was performed by orthopedists with various levels of experience. The surgery was conducted by Moore's posterolateral approach. The patients had cemented and uncemented prostheses implanted, depending on indications. Drainage, if used, was removed on day 2 after surgery. All patients underwent an ultrasound examination of the hip joint on day 3 after surgery in search for a possible postoperative hematoma. The amount of fluid was measured at the level of the prosthesis neck and in peri-



**Fig. 2.** US probe position to evaluate the fluid level

articular spaces (Fig. 1). A US examination was performed with the patients in the supine position. All examinations were conducted with a GE Healthcare system using a linear 10–15 MHz probe or a convex 5–8 MHz probe, depending on the thickness of tissues in the region of the prosthesis. For aseptic purposes, a latex cap, disinfected with an antiseptic agent, was placed on the probe covered with gel (Fig. 2, 3). Ultrasonography provided information about the size of a postoperative hematoma and its location, either in the joint or in the subcutaneous tissues. Apart from US, typical postoperative procedures were carried out in all patients: complete blood count and CRP (C-reactive protein) were controlled and rehabilitation assessment protocols were applied starting from day 2 after surgery. The clinical state of the patients was assessed by the HHS (Harris Hip Score) score. Statistical calculations were performed in Statistica 12. The normality of distribution was checked with the Shapiro-Wilk test. Comparisons between the groups were made using the Student's *t* test for independent samples in the case of variables with normal distribution, and Mann-Whitney *U* test for variables with non-normal distribution.

For quantitative variables, means plus standard deviation or median and minimum plus maximum values were calculated, depending on the type of distribution. For qualitative variables their quantity and percentage distribution was shown. Correlations of parametric variables were analyzed by the Spearman's test. Interrelations between quali-



**Fig. 3.** Probe position at the wound

tative variables were assessed by the chi squared test. The level of statistical significance was  $p < 0.05$ .

## Results

No differences in wound healing were observed between the groups. Two patients with suction drainage were diagnosed with periprosthetic infection based on clinical data and additional tests. Thanks to early diagnosis, a revision procedure, involving prosthesis head and liner replacement, was successfully performed. Infections were not found to occur with a statistically significant frequency in any of the groups [drainage group  $N=2$  (4%), no drainage group  $N=0$ ;  $p>0.05$ ] (Tab. 1, Tab. 2). However, the patients from the drainage group presented twice as large fluid collections at the level of the neck compared with the patients from the other group; medians were 10.05 mm (0–23 mm) and 5.5 mm (1–26.6 mm), respectively. These values were not statistically significant either ( $p = 0.07$ ). No statistically significant differences between the two groups were found with respect to the HHS score on day 3 after surgery ( $p = 0.09$ ). Patients with drainage had the mean HHS score of 44.31, whereas HHS in patients without drainage reached 48.95. In HHS sheets, there were no differences between the groups with respect to the quality of life. The duration of hospital stay was not significantly different between the groups and amounted to 7 days on average.

Similarly, there was no statistically significant difference for hospitalization cost: drainage group PLN 13,470, no drainage group PLN 12,491. There were no correlations between the size of hematoma and coagulation parameters: INR, APTT and PT (international normalized ratio; activated partial thromboplastin time; prothrombin time;  $r = 0.2, p > 0.05$ ;  $r = 0.15, p > 0.05$ ;  $r = 0.20, p > 0.05$ , respectively). The correlation between BMI (body mass index) value and the size of the hematoma showed bordering statistical significance ( $r = 0.21, p = 0.053$ ). Despite the fact that US visualized a hematoma in six patients from the no drainage group and in three patients from the drainage group, this difference was not statistically significant ( $p > 0.05$ ). In both groups, patients did not usually require transfusion of packed red blood cells; in total, 14 units were transfused in the drainage group and 18 units in the no drainage group ( $p > 0.05$ ). There were no statistically significant differences between the groups in hemoglobin and CRP levels on days 1 and 3 after surgery. Also, there were no statistically significant correlations between the size of the hematoma and duration of surgery or statistically significant differences in the size of hematoma depending on acetabular osteophyte removal.

### Discussion

Patients after hip arthroplasty routinely undergo X-ray of an implanted prosthesis in AP and axial projections. This enables assessment of the prosthesis position and possible complications, such as prosthetic luxation and periprosthetic fractures. However, X-ray does not enable assessment of periprosthetic soft tissues. The usage of ultraso-

nography in patients after hip joint replacement makes it possible to assess soft tissue healing processes, identify fluid collections in the area of the hip joint and evaluate indications for postoperative puncture procedures. This test also enables one to conduct a puncture and assess its efficacy in real time as well as evaluate the validity of using drainage after hip joint replacement surgeries. It has been shown that ultrasonography is twice as sensitive as physical examination in identifying hematomas after such operations<sup>(14)</sup>. They are easily recognizable in US as hypoechogenic or anechogenic areas with no flow in the Doppler examination. Development of a large postoperative hematoma is considered one of the factors that increase the risk of septic complications after joint replacement surgeries, which used to be the reason for applying suction drainage after these procedures<sup>(15,16)</sup>. A certain amount of fluid in the hip joint and in the projection of the surgical wound is always visible after hip replacement. In this study, US enabled assessment of the need to conduct joint puncture in order to reduce the risk of complications. It is proposed that the amount of intracapsular fluid should be quantified at the anterior superior margin of the prosthetic neck. It is also suggested to assess the amount

Drainage				
	mean	standard deviation	median	max.-min.
Age	-	-	64	29-81
BMI	28.86	4.7	-	-
Surgery duration (min)	-	-	80	50-110
Infection	N = 2 (4%)	-	-	-
Fluid level	-	-	10.05	0-23
HHS (day 3)	44.31	14.6	-	-
Hospitalization (days)	-	-	7	4-19
Cost (PLN)	-	-	13 470.58	6391.46-26 751.49
INR	-	-	1.05	0.95-1.28
APTT	23.57	3.07	-	-
PT	-	-	13.60	12.2-16.2
Wound hematoma	N = 3 (6.1%)	-	-	-
Packed RBCs	-	-	0	0-2
HB day 1	11.45	1.457	-	-
HB day 3	10.51	1.51	-	-
CRP day 1	-	-	189.9	77-372.8
CRP day 3	-	-	145.8	0.8-335.6

Tab. 1. Values of individual variables. Results

No drainage					
	mean	standard deviation	median	max.-min.	p
Wiek	-	-	63	29-87	0.54
BMI	27.81	4.89	-	-	0.52
Surgery duration (min)	-	-	77.5	43-135	0.47
Infection	N = 0	-	-	-	0.19
Fluid level	-	-	5.5	1-26.6	0.07
HHS (day 3)	48.95	17.57	-	-	0.09
Hospitalization (days)	-	-	7	3-21	0.52
Cost (PLN)	-	-	12941.52	3277.53-43047.86	0.64
INR	-	-	1.05	0.94-1.22	0.27
APTT	23.89	3.42	-	-	0.64
PT	-	-	13.4	12.1-15.4	0.27
Wound hematoma	N = 6 (14.6%)	-	-	-	0.18
Packed RBCs	-	-	0	0-4	0.99
HB day 1	11.39	1.36	-	-	0.75
HB day 3	10.22	1.23	-	-	0.33
CRP day 1	-	-	189.9	34.8-385.2	0.51
CRP day 3	-	-	136.2	19.8-380.4	0.27

Tab. 2. Values of individual variables. Results

of extraarticular fluid collections based on the thickness of the fluid layer in the superficial (between the skin and the fascia lata) and deep (between the fascia lata and the femoral cortex) soft tissues<sup>(11)</sup>.

## Conclusions

1. A US examination conducted after hip arthroplasty is useful in assessing hematomas.
2. This randomized study did not reveal statistically significant differences between the groups with and with-

out drainage, which suggests that this practice can be abandoned, except for selected cases.

3. Due to a short hospital stay, it is recommended to conduct a US examination in addition to routine X-ray and laboratory tests (complete blood count, C-reactive protein) in order to reduce the risk of complications.

## Conflict of interest

*The authors do not declare any financial or personal links to other people or organizations that could adversely affect the content of this publication or claim rights hereto.*

## References

1. Maradit Kremers H, Larson DR, Crowson CS, Kremers WK, Washington RE, Steiner CA *et al.*: Prevalence of total hip and knee replacement in the United States. *J Bone Joint Surg Am* 2015; 97: 1386–1397.
2. Kurtz S, Ong K, Lau E, Mowat F, Halpern M: Projections of primary and revision hip and knee arthroplasty in the United States from 2005 to 2030. *J Bone Joint Surg Am* 2007; 89: 780–785.
3. www.nfz.gov.pl.
4. Zhou XD, Li J, Xiong Y, Jiang LF, Li WJ, Wu LD: Do we really need closed-suction drainage in total hip arthroplasty? A meta-analysis. *Int Orthop* 2013; 37: 2109–2118.
5. Kelly EG, Cashman JP, Imran FH, Conroy R, O'Byrne J: Systemic review and meta-analysis of closed suction drainage versus non-drainage in primary hip arthroplasty. *Surg Technol Int* 2014; 24: 295–301.
6. Ashraf T, Darmanis S, Krikler SJ: Effectiveness of suction drainage after primary or revision total hip and total knee arthroplasty. *Orthopedics* 2001; 24: 1158–1160.
7. Parvizi J, Gehrke T, Chen AF: Proceedings of the international consensus meeting on periprosthetic joint infection. *Bone Joint J* 2013; 95-B: 1450–1452.
8. Matharu GS, Janardhan S, Brash L, Pynsent PB, Dunlop DJ, James SL: The utility of repeat ultrasound imaging in the follow-up of metal-on-metal hip arthroplasty patients. *Ann R Coll Surg Engl* 2016; 98: 143–149.
9. Muraoka K, Naito M, Nakamura Y, Hagio T, Takano K: Usefulness of ultrasonography for detection of pseudotumors after metal-on-metal total hip arthroplasty. *J Arthroplasty* 2015; 30: 879–884.
10. Nishii T, Sakai T, Takao M, Yoshikawa H, Sugano N: Is ultrasound screening reliable for adverse local tissue reaction after hip arthroplasty? *J Arthroplasty* 2014; 29: 2239–2244.
11. Hoefnagels EM, Obradov M, Reijnierse M, Anderson PG, Swierstra BA: Sonography after total hip replacement: reproducibility and normal values in 47 clinically uncomplicated cases. *Acta Orthop* 2007; 78: 81–85.
12. Nestorova1 R, Vlad V, Petranova T, Porta F, Radunovic G, Micu MC *et al.*: Ultrasonography of the hip. *Med Ultrason* 2012; 14: 217–224.
13. Molini L, Precerutti M, Gervasio A, Draghi F, Bianchi S: Hip: Anatomy and US technique. *J Ultrasound* 2011; 14: 99–108.
14. Kong K, Jeyagopal N, Davies SJ: Should we still stitch the subcutaneous fat layer? A clinical and ultrasound assessment in 50 hip operations. *Ann R Coll Surg Engl* 1993; 75: 23–25.
15. Saleh K, Olson M, Resig S, Bershadsky B, Kuskowski M, Gioe T *et al.*: Predictors of wound infection in hip and knee joint replacement: results from a 20 year surveillance program. *J Orthop Res* 2002; 20: 506–515.
16. Eveillard M, Mertl P, Canarelli B, Lavenne J, Fave MH, Eb F *et al.*: [Risk of deep infections in first intention total hip arthroplasties]. *Presse Med* 2001; 30:1868–1875.