

Evaluation of Testicular Workup for Ischemia and Suspected Torsion score in patients presenting with acute scrotum

C. S. Manohar, Avneet Gupta, R. Keshavamurthy, M. Shivalingaiah, B. R. Sharanbasappa, Vinish Kumar Singh

Department of Urology, Institute of Nephrourology, Bengaluru, Karnataka, India

Abstract

Background: Testicular torsion is one of the causes of acute scrotum and it requires timely evaluation and surgical treatment. Color Doppler is considered investigation of choice, but it may delay treatment, as, many times, it may not be available for emergency situations. Barbosa *et al.* created Testicular Workup for Ischemia and Suspected Torsion (TWIST) score based on clinical parameters for clinical diagnosis of testicular torsion. We have evaluated this score in our population.

Materials and Methods: We retrospectively calculated TWIST score in patients of acute scrotum admitted to tertiary teaching institute. Patients without complete TWIST score were excluded from the study. The scoring system consisted of testicular swelling (2 points), hard testicle (2), absent cremasteric reflex (1), nausea/vomiting (1), and high-riding testis (1). Statistical analysis was done to evaluate the validity of scores.

Results: A total of 118 patients were included in the study, out of which 45 (38%) patients had testicular torsion. The mean age of patients was 16.6 years in testicular torsion patients and 15.2 years in other patients. Cutoff for low-risk and high-risk patients was two and five, respectively. Fifty percent, 26.2%, and 23.8% of patients were present in low-, intermediate-, and high-risk groups. Negative predictive value of TWIST score for low-risk patients was 96.61% while positive predictive value for high-risk patients was 92.86%.

Conclusions: TWIST score has high predictive value and can be used for clinical diagnosis of testicular torsion. It can decrease the need of color Doppler in about 50% of cases and can prevent delay in treatment.

Keywords: Acute scrotum, color Doppler, diagnosis, spermatic cord torsion

Address for correspondence: Avneet Gupta, 122/684, Shastri Nagar, Kanpur, Uttar Pradesh - 208 005, India.

E-mail: dravneetgupta@gmail.com

Received: 08.03.2017, **Accepted:** 25.08.2017

INTRODUCTION

Children and adolescents who present with an acute scrotum require prompt evaluation as testicular torsion could be one of the causes. Testicular torsion requires timely and accurate diagnosis, and surgical exploration is recommended in patients with high clinical suspicion. Acute testicular pain is the most common presenting symptom; on physical examination, findings would include

swelling, absent cremasteric reflex, and horizontal lie.^[1] However, clinical overlap between testicular torsion and other common etiology being epididymo-orchitis has to be diagnosed, for which color Doppler is considered investigation of choice. Intervention within 4–8 h is critical to prevent permanent testicular loss or atrophy from compromised testicular arterial flow.^[2] Thereafter, the testicle is often unsalvageable, resulting in orchiectomy

This is an open access article distributed under the terms of the Creative Commons Attribution-NonCommercial-ShareAlike 3.0 License, which allows others to remix, tweak, and build upon the work non-commercially, as long as the author is credited and the new creations are licensed under the identical terms.

For reprints contact: reprints@medknow.com

How to cite this article: Manohar CS, Gupta A, Keshavamurthy R, Shivalingaiah M, Sharanbasappa BR, Singh VK. Evaluation of testicular workup for ischemia and suspected torsion score in patients presenting with acute scrotum. *Urol Ann* 2018;10:20-3.

Access this article online	
Quick Response Code:	Website: www.urologyannals.com
	DOI: 10.4103/UA.UA_35_17

rates of 35%–40%.^[3] A diagnostic tool to help physicians in the clinical evaluation of acute scrotum could potentially decrease ischemic time in testicular torsion and reduce the cost of treatment.

Barbosa *et al.* created Testicular Workup for Ischemia and Suspected Torsion (TWIST) score based on clinical parameters.^[4] It includes five clinical variables including testicular swelling (2 points), hard testicle (2 points), absent cremasteric reflex (1 point), nausea/vomiting (1 point), and high-riding testis (1 point). The total score can range 0–7. Patients were divided into low-, intermediate-, or high-risk groups on the basis of total score (0–2, 3–4, 5–7, respectively). During validation of the score, Barbosa *et al.* found 100% negative predictive value (NPV) for low-risk group and 100% positive predictive value (PPV) for high-risk group. They have suggested that Doppler is not required in low- and high-risk groups, and patients in high-risk group can be directly taken for surgical exploration, thus requiring Doppler study only in 20% of cases.

We have used this score in our population to validate the score.

MATERIALS AND METHODS

After taking approval of the Institutional Research and Review Board, we retrospectively collected the medical records of the patients admitted to our institute with a diagnosis of acute scrotum between October 2007 and February 2016. The oldest patient presented to us with testicular torsion was 28 years old, so we have included the patients up to 28 years of age. TWIST score was calculated for all the patients based on symptoms and signs at presentation. Patients without complete TWIST score were excluded from the study. PPV, NPV, sensitivity, and specificity of the scoring system were calculated for different risk groups [Figure 1].

RESULTS

One hundred and eighty-two patients were admitted to our institution with the diagnosis of acute scrotum during the study period, out of which 64 patients were excluded from the study as complete details were not available to score them. A total of 118 patients were included in the study. Forty-five (38%) patients were found to have testicular torsion, and 73 (62%) patients were with no torsion. The mean age of the patient in testicular torsion group was 16.6 years (range 8–28 years), and the mean age of the patients in no

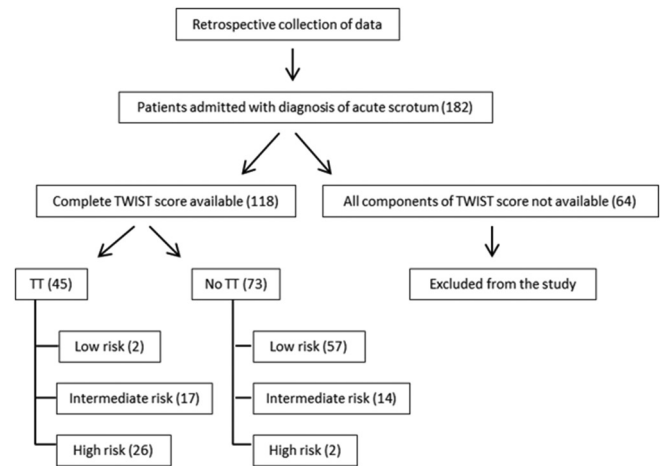


Figure 1: Study design

torsion group was 15.2 years (range 6–28 years). The mean duration of pain before patients presented to our hospital was 50.6 h (range 6 h to 15 days) and 92.2 h (range 10 h to 12 days) in patients with and without torsion, respectively. Left testis was more commonly involved in both the groups [Table 1].

In testicular torsion group, mean TWIST score was 4.75 (range = 2–7). In no torsion group, mean TWIST score was 1.46 (range = 0–5). In testicular torsion group, the number of patients with low, intermediate, and high risk was 2, 17, and 26, respectively, while the number of patients without testicular torsion was 57, 14, and 2 in low-, intermediate-, and high-risk groups, respectively [Table 2]. Only nine patients in torsion group presented within 8 h. Orchiopexy of involved testis was possible only in 11 patients, with an orchiectomy rate of 76%. NPV and sensitivity of TWIST score for low-risk patients were 96.6% and 95.5%, respectively, while PPV and specificity for high-risk patients were 92.8% and 97.2%, respectively.

DISCUSSION

Differential diagnosis of acute scrotum includes testicular torsion, torsion of testicular appendices, epididymo-orchitis, and infected hydrocele. Due to overlapping of symptoms and signs, it is difficult to diagnose testicular torsion only on clinical basis, so color Doppler is frequently ordered. Since it is not readily available all the time in many centers, patients are referred to higher centers, which causes delay in definitive treatment.

We evaluated TWIST score as a clinical diagnostic tool for testicular torsion. One hundred and eighteen patients were included in the study group in whom all the components were available.

Table 1: Comparison of two groups

	Testicular torsion		No torsion	
	Mean	Range	Mean	Range
Number of patients	45		73	
Age of patients	16.6 years	8-28 years	15.2 years	6-28 years
Duration of pain	50.6 h	6 h to 15 days	92.2 h	10 h to 12 days
Testis involved	Left - 70% cases		Left - 62% cases	

Table 2: Testicular workup for ischemia and suspected torsion score of all patients

Risk group	TWIST score	Testicular torsion		No torsion		Total
Low (0-2)	0	0	2	22	57	59
	1	0		20		
	2	2		15		
Intermediate (3-4)	3	5	17	8	14	31
	4	12		6		
High (5-7)	5	12	26	2	2	28
	6	11		0		
	7	3		0		
Total		45		73		

TWIST: Testicular Workup for Ischemia and Suspected Torsion

The mean duration of pain before presenting to our institute in torsion group was 50.6 h. It is more when compared to the mean duration of pain published in previous series.^[4] Only 20% of the torsion cases presented to our hospital within 8 h. It may be due to patient's negligence about their own symptoms and delayed presentation to the primary hospital, inability of primary caregivers to diagnose torsion, or delay due to referral of patients to higher centers. This delayed presentation has resulted in orchiectomy rate of 76% at our center due to nonsalvageability of affected testis at the time of surgical exploration. Previously published series have reported orchiectomy rates of 35%–40%.^[3,5] High orchiectomy rate in our series is due to delayed presentation of patients at our center. This fact especially highlights the need of clinical diagnostic tool in our population for the early management of torsion.

In our study population, in torsion group, no patient had score 0 or 1, and patients in low-, intermediate-, and high-risk groups were 4.4%, 37.7%, and 57.7%, respectively. In the group without testicular torsion, patients in low-, intermediate-, and high-risk groups were 78.0%, 19.1%, and 2.7%, respectively. NPV of TWIST score in low-risk group and PPV in high-risk group were 96.6% and 92.8%, respectively. Barbosa *et al.* reported NPV and PPV of 100% in their series and stated that no patients would be missed with TWIST score. Although NPV and PPV in our series are not as high as the original study, still within acceptable limits to recommend it as a clinical tool.

Barbosa *et al.* have found that only 20% of patients fall in intermediate-risk group (TWIST score = 3–4). He

has recommended that color Doppler is required only in intermediate-risk group. Hence, this investigation can be omitted in 80% of population. In our series, intermediate-risk group includes about 50% of population. Hence, color Doppler is not required in 50% of cases. Color Doppler has a sensitivity of 95%–100% and specificity of 96%–98% in the diagnosis of testicular torsion.^[6] This score is not designed to replace color Doppler but to better define its indication.^[4]

Sheth *et al.* have also evaluated this score in diagnosis of testicular torsion by nonurology emergency room caregivers and found it equally effective.^[7]

In our population of patients with acute scrotum, testicular torsion was found in 38% of patients, which is higher than previously published reports (15%–20%).^[8,9] It may be due to selection bias as our center is tertiary teaching institute where we cater to majority of referral cases. It may be considered as one of the demerits of this study.

CONCLUSIONS

TWIST score has high positive and negative predictive values and can be used as a clinical diagnostic tool for testicular torsion. It can decrease the need of color Doppler in about 50% of cases and can prevent delay in definitive treatment. Future large, multicenter, prospective studies are required for further validation of score.

Financial support and sponsorship

Nil.

Conflicts of interest

There are no conflicts of interest.

REFERENCES

- Davenport M. ABC of general surgery in children. Acute problems of the scrotum. *BMJ* 1996;312:435-7.
- Visser AJ, Heyns CF. Testicular function after torsion of the spermatic cord. *BJU Int* 2003;92:200-3.
- Cost NG, Bush NC, Barber TD, Huang R, Baker LA. Pediatric testicular torsion: Demographics of national orchiopexy versus orchiectomy rates. *J Urol* 2011;185:2459-63.
- Barbosa JA, Tiseo BC, Barayan GA, Rosman BM, Torricelli FC, Passerotti CC, *et al.* Development and initial validation of a scoring system to diagnose testicular torsion in children. *J Urol* 2013;189:1859-64.
- Zhao LC, Lautz TB, Meeks JJ, Maizels M. Pediatric testicular torsion epidemiology using a national database: Incidence, risk of orchiectomy and possible measures toward improving the quality of care. *J Urol* 2011;186:2009-13.
- Gunther P, Schenk JP, Wunsch R, Holland-Cunz S, Kessler U, Troger J, *et al.* Acute testicular torsion in children: The role of sonography in the diagnostic workup. *Eur Radiol* 2006;16:2527-32.

7. Sheth KR, Keays M, Grimsby GM, Granberg CF, Menon VS, Dajusta DG, *et al.* Diagnosing testicular torsion before urological consultation and imaging: Validation of the TWIST score. *J Urol* 2016;195:1870-6.
8. McAndrew HF, Pemberton R, Kikiros CS, Gollow I. The incidence and investigation of acute scrotal problems in children. *Pediatr Surg Int* 2002;18:435-7.
9. Liang T, Metcalfe P, Sevcik W, Noga M. Retrospective review of diagnosis and treatment in children presenting to the pediatric department with acute scrotum. *AJR Am J Roentgenol* 2013;200:W444-9.