


# Small cell carcinoma of the uterine cervix during pregnancy

Rare Tumors  
Volume 11: 1–5  
© The Author(s) 2019  
Article reuse guidelines:  
sagepub.com/journals-permissions  
DOI: 10.1177/2036361319866539  
journals.sagepub.com/home/rtu  


Satoshi Eto<sup>1</sup> , Kentaro Kai<sup>1,2</sup>, Kaei Nasu<sup>1,3</sup>, Masakazu Nishida<sup>1</sup>, Haruto Nishida<sup>4</sup> and Hisashi Narahara<sup>1</sup>

## Abstract

Small cell carcinoma of the uterine cervix is a rare histological entity that has a poor prognosis. We report the case of a patient with small cell carcinoma of the uterine cervix who underwent a radical hysterectomy during pregnancy. A 33-year-old Japanese woman with genital bleeding was referred at 15 weeks' gestation. A speculum exam revealed a 5.4-cm-dia. mass in the cervix, and a cervical biopsy revealed small cell carcinoma of the uterine cervix. Imaging studies demonstrated a tumor confined to the cervix, swelling of intra-pelvic lymph nodes, and no distant spread of the tumor. She was diagnosed as having small cell carcinoma of the uterine cervix, stage IB2, and underwent a radical hysterectomy with pelvic lymphadenectomy. She refused any adjuvant therapies, had a systemic relapse 4 months after surgery, and died of the disease 5 months after surgery. Early-stage small cell carcinoma of the uterine cervix should be treated with a definitive therapy soon after diagnosis whether the patient is pregnant or not. Saving the mother's life should be the top priority.

## Keywords

Uterine cervical neoplasm, small cell carcinoma, pregnancy, hysterectomy

Date received: 6 August 2018; accepted: 2 July 2019

## Introduction

Small cell carcinoma of the uterine cervix (SCCC) is a rare and aggressive tumor, and the survival is poor regardless of the stage. SCCC accounts for 2% of all invasive cervical cancers, presents at a later FIGO stage at diagnosis (high frequency of lymph node and distant metastases), and has a median overall survival (OS) of only 22 months.<sup>1</sup> There is no established treatment for this carcinoma, due to its rarity. In general, clinicians have no other choice but to extrapolate the treatment options for cervical cancer (i.e. surgery followed by chemotherapy or combined chemoradiotherapy) according to the evidence obtained for small cell lung cancer (SCLC), particularly for chemotherapy.<sup>2</sup>

Cervical cancer is one of the most common malignancies during pregnancy, with an incidence of 1.2 cases per 10,000 pregnancies.<sup>3</sup> Because of the paucity of large randomized trials examining pregnant patients with cervical cancer, the treatment is based on the data of non-pregnant

women. In cases in which a pregnant woman with cervical cancer wants to continue the pregnancy, a delay in the initial therapy during the pregnancy presents a risk. For patients with stage IB or higher cervical cancer who opt for pregnancy preservation and are at the gestational age

<sup>1</sup>Department of Obstetrics and Gynecology, Faculty of Medicine, Oita University, Oita, Japan

<sup>2</sup>Department of Obstetrics and Gynecology, Nakatsu Municipal Hospital, Oita, Japan

<sup>3</sup>Division of Obstetrics and Gynecology, Support System for Community Medicine, Faculty of Medicine, Oita University, Oita, Japan

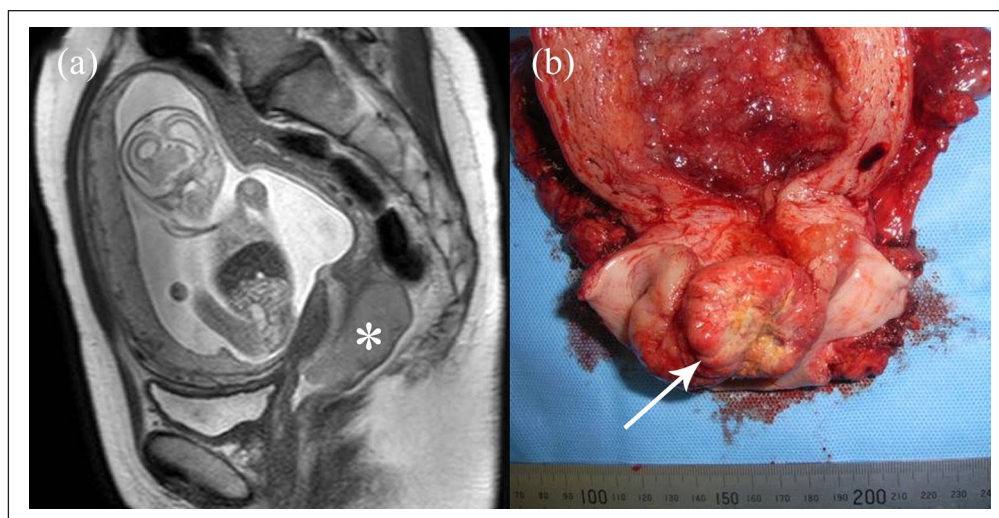
<sup>4</sup>Department of Diagnostic Pathology, Faculty of Medicine, Oita University, Oita, Japan

## Corresponding author:

Satoshi Eto, Department of Obstetrics and Gynecology, Faculty of Medicine, Oita University, 1-1 Idaigaoka, Hasama-machi, Yufu-shi, Oita 879-5593, Japan.

Email: satoshi-e@oita-u.ac.jp





**Figure 1.** (a) Sagittal T2-weighted MRI revealed a cervical tumor growing mainly from the posterior uterine cervix (asterisk). (b) Front view of the nodular cervical tumor with a longitudinal incision of the anterior uterine wall (postoperative photo, white arrow).

<22–25 weeks at diagnosis, neoadjuvant chemotherapy is recommended to delay definitive therapy until after delivery.<sup>4</sup> However, it has been unclear whether this general principle can be applied to the rare and aggressive disease of SCCC.

We report the case of a woman with SCCC who underwent a radical hysterectomy with the fetus in situ during her pregnancy.

## Case report

A 33-year-old nulligravid Japanese woman at 15 weeks of gestation was referred to our institution with abnormal vaginal bleeding due to a uterine cervical tumor. She had become pregnant with the first trial of homologous artificial insemination. Surprisingly, her spectrum examination and screening Pap smear at 11 weeks of gestation did not detect any abnormality. She had no notable medical history and had not received a vaccination against HPV. The fetal growth was appropriate for the gestational date.

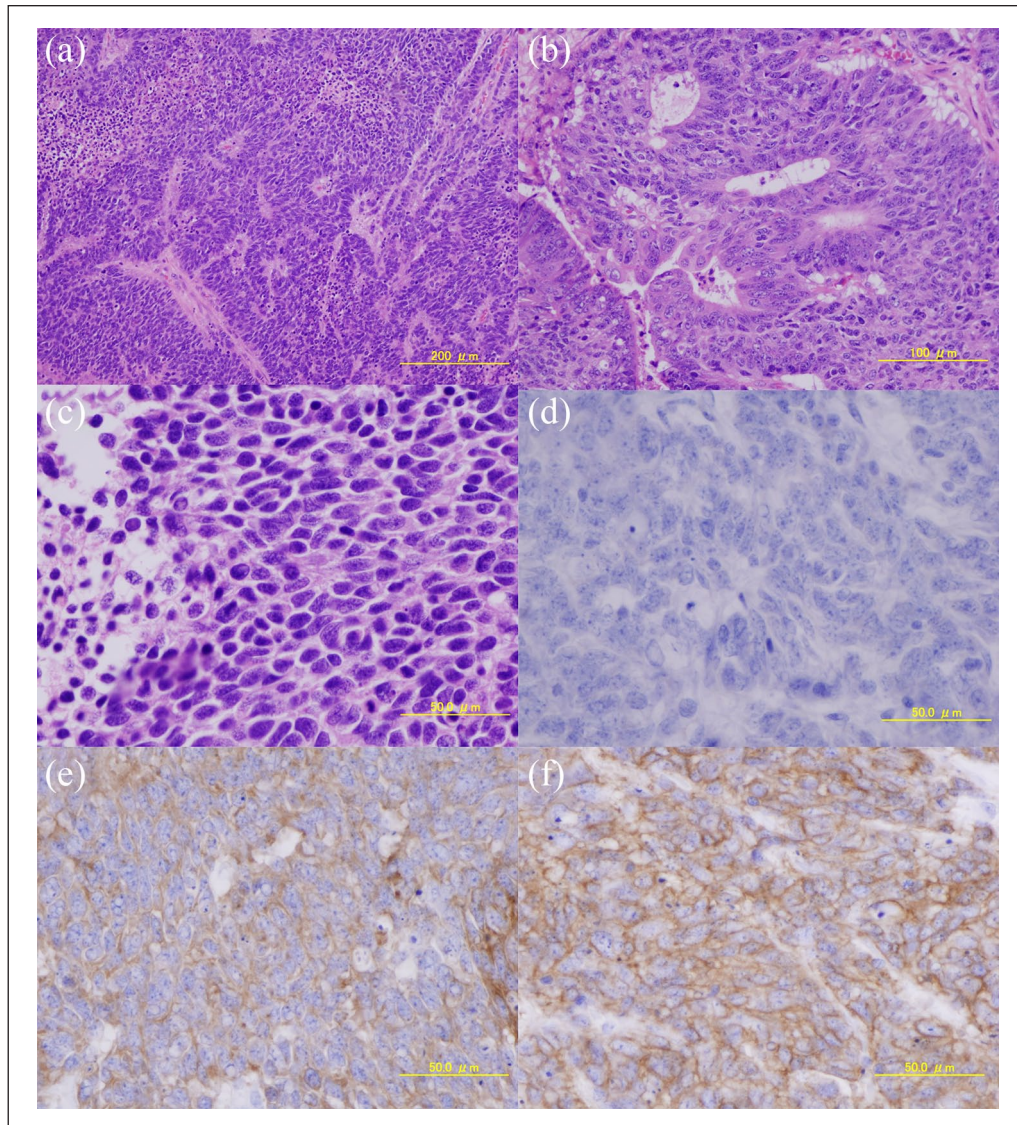
A speculum examination showed a bulky cervical tumor, without involvement of the vagina. Transvaginal echography showed a 5.4-cm-dia. tumor in the cervix, the uterus enlarged by the pregnancy, and a viable fetus. On pelvic and rectal examination, the tumor did not invade to the parametrium and rectal mucosa. Magnetic resonance imaging (Figure 1(a)) and contrast-enhanced computed tomography showed that the tumor was confined to the cervix, and they indicated enlargement of intra-pelvic lymph nodes without evidence of nodal involvement, and no distant metastasis. A cervical biopsy was performed and the specimen was stained with hematoxylin–eosin (HE): the small-size cells of the tumor had a high nuclear-cytoplasmic ratio, finely granular nuclear chromatin, nuclear molding, and

absent or inconspicuous nucleoli, suggesting SCCC (Figure 2(a)–(c)). Immunostains revealed the absence of chromogranin A (Figure 2(d)) but the presence of synaptophysin (Figure 2(e)) and neural cell adhesion molecule (Figure 2(f)), supporting the diagnosis of SCCC. Tumor markers including squamous cell carcinoma, carbohydrate antigen (CA) 125, CA19-9, CA72-4, carcinoembryonic antigen and neuron-specific enolase were within normal range. We diagnosed SCCC, FIGO stage IB2 (cT1b2N1M0).

We and another physician from whom the patient and her husband sought a second opinion offered surgery first, expecting histology-specific aggressive behavior and a lack of response to neoadjuvant chemotherapy. We performed a radical hysterectomy with the fetus in situ, a bilateral salpingo-oophorectomy, and pelvic and paraaortic lymphadenectomy at 18 weeks of gestation (Figure 1(b)). At the laparotomy, there was no finding of lymphadenopathy or obturator lymph nodes. The pathologic examination of the resected specimen demonstrated no direct invasion of the vaginal wall, but lymph node metastasis in obturator and parametrial nodes (pT2bN1M0) was observed. Although we strongly recommended an adjuvant therapy, the patient and her husband selected routine postoperative surveillance only. Four months after the surgery, the patient had a systemic relapse of the disease, but she and her husband selected best supportive care only. She died 1 month after the relapse.

## Discussion

This case had two major clinical implications. First, early-stage SCCC should be treated with a radical hysterectomy and lymphadenectomy soon after diagnosis whether the patient is pregnant or not. Second, clinicians should consider



**Figure 2.** (a) The tumor, with a high nuclear-cytoplasmic ratio, was growing in diffuse sheets, showing a rosette in some parts. Extensive necrosis was present. (b) The tumor consisted of dense sheets of small cells with scant cytoplasm, finely granular nuclear chromatin, frequent mitoses. Nucleoli are inconspicuous or absent. Nuclear molding was present. (c) HE stain at the same magnification ratio as the immunostains. (d) Immunostaining showed the absence of chromogranin A, but the presence of (e) synaptophysin and (f) neural cell adhesion molecule.

the context of the aggressive behavior of SCCCs, and they should make saving the mother's life the top priority.

We performed a radical hysterectomy for SCCC at 18 weeks' gestation in this case. To our knowledge, this is the first report of a radical hysterectomy for SCCC during pregnancy. Since 1990, 10 cases of SCCC during pregnancy<sup>5-7</sup> were reported in the English literature (Table 1). The initial treatment option depended on whether or not the fetus had extrauterine survival potential. Nine of the 10 patients diagnosed after 25 weeks' gestational age underwent elective cesarean section followed by a radical hysterectomy or chemotherapy. Teefey et al.<sup>7</sup> reported a case of SCCC during pregnancy diagnosed at 10 weeks' gestation, and they

performed neoadjuvant chemotherapy with etoposide and cisplatin (EP/PE) because the patient declined a radical hysterectomy. In the present case, we initially performed a radical hysterectomy considering the gestational age at diagnosis and the estimated 10% 5-year survival rate which we calculated from the 10 above-mentioned cases. Although chemotherapy is reported to be relatively safe after the first trimester in breast cancer patients,<sup>8</sup> the efficacy and safety of performing neoadjuvant chemotherapy for the pregnant patients of FIGO stage IB2 or higher cervical cancer until the fetal maturation has not been established.<sup>9</sup> In addition, the Japan Society of Gynecologic Oncology (JSOG) guideline includes either surgery or radiotherapy for stage IIB cases.<sup>10</sup>

**Table 1.** Reported cases of small cell carcinoma of the uterine cervix during pregnancy since 1990.

Author	Year	Age	GA	FIGO stage	Treatment	Outcome
Lewandowski and Copeland <sup>11</sup>	1993	31	28	IB	CS, RH, CT	NED 51 months
Chang et al. <sup>12</sup>	1994	27	36	IB	CS, RH, CT	DOD 2 months
Abeler et al. <sup>13</sup>	1994	NA	NA	IB	CS, RH, CT	NED 54 months
Perrin et al. <sup>14</sup>	1996	23	25	IIA	CS, RH, CT	DOD 6 months
Hirose et al. <sup>15</sup>	1997	30	29	IIB	CS, RH, CT	DOD 7 months
Balderston et al. <sup>16</sup>	1998	22	30	IIA	CS, CT, RT	NED 66 months
Leung et al. <sup>17</sup>	1999	26	31	IB2	CS, CT, RT	NED 14 months
Ohwada et al. <sup>6</sup>	2001	27	27	IB1	CS, RT, CT	NED 13 months
Teefey et al. <sup>7</sup>	2012	31	10	IB1	CT, CS, RT	NED 24 months
Liu et al. <sup>5</sup>	2014	25	32	IIA	CS, RT, CT	DOD 3 months
Present case	2016	33	18	IB2	RT, BSC	DOD 5 months

Source: Modified from Ohwada et al.<sup>6</sup>

GA: gestational age; CS: cesarean section; RH: radical hysterectomy; CT: chemotherapy; NED: no evidence of disease; DOD: dead of disease; NA: not available; RT: radiation therapy; BSC: best supportive care.

In the clinical document issued by the Society of Gynecologic Oncology, Gardner et al.<sup>18</sup> proposed that radical surgery is recommended for I–II SCCC, either primarily or after neoadjuvant chemotherapy. However, the benefit of adjuvant chemotherapy and its regimen remains controversial. Tian et al.<sup>19</sup> and Cohen et al.<sup>20</sup> independently reported that adjuvant chemotherapy for early-stage (less than IIA) SCCC after radical therapy did not improve the OS. Kuji et al.<sup>21</sup> reported that adjuvant chemotherapy significantly improved the progression-free survival (PFS) but not the OS in stage IB1–IIB SCCC cases. However, all of the findings mentioned above are based on retrospective analyses, not prospective studies. Although EP/PE therapy is the most frequent regimen for SCCC based on its use as a treatment for SCLC,<sup>22</sup> irinotecan and cisplatin (IP) for SCLC demonstrated significantly better PFS and OS compared to EP/PE in a randomized, Phase III study.<sup>2</sup> In the present case, we advised the patient to undergo adjuvant chemotherapy with IP or irradiation, but she declined adjuvant therapy because of uncertain benefit of adjuvant chemotherapy and poor prognosis of SCCC.

## Conclusion

We must consider the possibility of malignant disease of the uterine cervix when a pregnant woman complains of atypical vaginal bleeding. Although rare, SCCC can develop during pregnancy, and a radical hysterectomy can be a treatment option. The benefit of combined modality therapy including adjuvant chemotherapy for the OS of SCCC patients remains controversial. Further evaluation in more patients is necessary.

## Conflict of interest

The author(s) declared no potential conflicts of interest with respect to the research, authorship, and/or publication of this article.

## Funding

The author(s) received no financial support for the research, authorship, and/or publication of this article.

## Informed consent

Written informed consent for this report was obtained from the patient and her husband before the initial therapy for their anonymized information to be published in this article.

## ORCID iD

Satoshi Eto  <https://orcid.org/0000-0001-5031-6490>

## References

- McCusker ME, Cote TR, Clegg LX, et al. Endocrine tumors of the uterine cervix: incidence, demographics, and survival with comparison to squamous cell carcinoma. *Gynecol Oncol* 2003; 88(3): 333–339.
- Noda K, Nishiwaki Y, Kawahara M, et al. Irinotecan plus cisplatin compared with etoposide plus cisplatin for extensive small-cell lung cancer. *N Engl J Med* 2002; 346(2): 85–91.
- Duggan B, Muderspach LI, Roman LD, et al. Cervical cancer in pregnancy: reporting on planned delay in therapy. *Obstet Gynecol* 1993; 82(4 Pt. 1): 598–602.
- Amant F, Halaska MJ, Fumagalli M, et al. Gynecologic cancers in pregnancy: guidelines of a second international consensus meeting. *Int J Gynecol Cancer* 2014; 24(3): 394–403.
- Liu H, Yang X, Zhang C, et al. Small cell carcinoma of the cervix at 32-week gestation: a case report and review of the literature. *Lab Med* 2014; 45(1): 52–55.
- Ohwada M, Suzuki M, Hironaka M, et al. Neuroendocrine small cell carcinoma of the uterine cervix showing polypoid growth and complicated by pregnancy. *Gynecol Oncol* 2001; 81(1): 117–119.
- Teefey P, Orr B, Vogt M, et al. Neuroendocrine carcinoma of the cervix during pregnancy: a case report. *Gynecol Oncol Case Rep* 2012; 2(3): 73–74.
- Woo JC, Yu T and Hurd TC. Breast cancer in pregnancy: a literature review. *Arch Surg* 2003; 138(1): 91–98, discussion 99.

9. Fruscio R, Villa A, Chiari S, et al. Delivery delay with neoadjuvant chemotherapy for cervical cancer patients during pregnancy: a series of nine cases and literature review. *Gynecol Oncol* 2012; 126(2): 192–197.
10. Ebina Y, Mikami M, Nagase S, et al. Japan Society of Gynecologic Oncology guidelines 2017 for the treatment of uterine cervical cancer. *Int J Clin Oncol* 2018; 24(1): 1–19.
11. Lewandowski GS and Copeland LJ. A potential role for intensive chemotherapy in the treatment of small cell neuroendocrine tumors of the cervix. *Gynecol Oncol* 1993; 48(1): 127–131.
12. Chang DH-C, Hsueh S and Soong Y-K. Small cell carcinoma of the uterine cervix with neurosecretory granules associated with pregnancy: a case report. *J Reprod Med* 1994; 39(7): 537–540.
13. Abeler VM, Holm R, Nesland JM, et al. Small cell carcinoma of the cervix: a clinicopathologic study of 26 patients. *Cancer* 1994; 73(3): 672–677.
14. Perrin L, Bell J and Ward B. Small cell carcinoma of the cervix of neuroendocrine origin causing obstructed labour. *Aust NZ Obstet Gynaecol* 1996; 36(1): 85–87.
15. Hirose T, Yamada J, Yamamoto Y, et al. Small cell neuroendocrine carcinoma of the uterine cervix: case report with cytological and immunohistochemical studies. *J Jpn Soc Clin Cytol* 1997; 36(2): 233–237. [Article in Japanese]
16. Balderston KD, Tewari K, Gregory WT, et al. Neuroendocrine small cell uterine cervix cancer in pregnancy: long-term survival following combined therapy. *Gynecol Oncol* 1998; 71(1): 128–132.
17. Leung TW, Lo SH, Wong SF, et al. Small cell carcinoma of the cervix complicated by pregnancy. *Clin Oncol* 1999; 11(2): 123–125.
18. Gardner GJ, Reidy-Lagunes D and Gehrig PA. Neuroendocrine tumors of the gynecologic tract: a Society of Gynecologic Oncology (SGO) clinical document. *Gynecol Oncol* 2011; 122(1): 190–198.
19. Tian WJ, Zhang MQ and Shui RH. Prognostic factors and treatment comparison in early-stage small cell carcinoma of the uterine cervix. *Oncol Lett* 2012; 3(1): 125–130.
20. Cohen JG, Kapp DS, Shin JY, et al. Small cell carcinoma of the cervix: treatment and survival outcomes of 188 patients. *Am J Obstet Gynecol* 2010; 203(4): 347.e1–347.e6.
21. Kuji S, Hirashima Y, Nakayama H, et al. Diagnosis, clinicopathologic features, treatment, and prognosis of small cell carcinoma of the uterine cervix; Kansai Clinical Oncology Group/Intergroup study in Japan. *Gynecol Oncol* 2013; 129(3): 522–527.
22. Sundstrom S, Bremnes RM, Kaasa S, et al. Cisplatin and etoposide regimen is superior to cyclophosphamide, epirubicin, and vincristine regimen in small-cell lung cancer: results from a randomized phase III trial with 5 years' follow-up. *J Clin Oncol* 2002; 20(24): 4665–4672.