

# The diagnostic protocol for hereditary spherocytosis-2021 update

Yangyang Wu | Lin Liao | Faquan Lin 

Department of Clinical Laboratory, The First Affiliated Hospital of Guangxi Medical University, Nanning, China

## Correspondence

Faquan Lin, Department of Clinical Laboratory, The First Affiliated Hospital of Guangxi Medical University, Nanning 530021, Guangxi Zhuang Autonomous Region, China.  
Email: fqlin1998@163.com

## Funding information

This study was supported by the National Natural Science Foundation of China, No. 81360263

## Abstract

**Background:** Hereditary spherocytosis (HS), a commonly encountered hereditary hemolytic disease, is mostly inherited in an autosomal dominant manner. The clinical manifestations in patients with HS show obvious heterogeneity. Moreover, the sensitivity or specificity of some HS diagnostic tests are not ideal and may easily result in misdiagnosis or missed diagnosis in some patients. The objective of this study was to propose a simple and practical diagnostic protocol, which can contribute to the diagnosis of HS and its differential diagnosis with different types of hemolytic anemia such as thalassemia (THAL), autoimmune hemolytic anemia (AIHA), and glucose-6-phosphate dehydrogenase (G6PD) deficiency, thus, to provide an alternative simple and reliable method for better clinical diagnosis of HS.

**Methods:** Through combing our research with existing experimental technologies and studies, we propose a simple and practical protocol for HS diagnosis, which will help clinicians to improve HS diagnosis.

**Results:** Compared with the existing HS diagnostic protocols, the HS diagnostic protocol we proposed is simpler. In this new protocol, some experimental tests with ideal diagnostic efficiency are added, such as mean reticulocyte volume (MRV), mean spheroid cell volume (MSCV), mean corpuscular volume (MCV), in combination with the observation of clinical manifestations, family investigation, routine tests for hemolytic anemia, genetic testing, and other screening tests.

**Conclusion:** The HS diagnostic protocol we proposed could improve the clinical practice and efficiency of HS diagnosis.

## KEYWORDS

anemia, diagnostic protocol, dominant inheritance, erythrocyte membrane protein, hereditary spherocytosis

## 1 | INTRODUCTION

Hereditary spherocytosis (HS) is a hereditary hemolytic anemia caused by the mutations in the genes encoding erythrocyte

membrane proteins and is mostly inherited in an autosomal dominant manner.<sup>1-3</sup> HS is classified into four types according to the severity of the disease: trait, mild, moderate, and severe. Commonly, there is heterogeneity of the clinical manifestations in patients

This is an open access article under the terms of the Creative Commons Attribution-NonCommercial-NoDerivs License, which permits use and distribution in any medium, provided the original work is properly cited, the use is non-commercial and no modifications or adaptations are made.

© 2021 The Authors. *Journal of Clinical Laboratory Analysis* published by Wiley Periodicals LLC.

with different HS types. Typical symptoms of HS include anemia, jaundice, and splenomegaly. However, patients with anemia such as thalassemia (THAL) and autoimmune hemolytic anemia (AIHA) also present with anemia, jaundice, and splenomegaly.<sup>4-7</sup> Commonly used diagnostic tests for HS have no ideal sensitivity or specificity. Therefore, some HS patients are easily misdiagnosed or missed.<sup>7-11</sup> Here, we propose a simple and practical diagnostic protocol for HS based on the results of existing experimental technologies and research, in an attempt to help clinicians improve their diagnosis of HS.

## 1.1 | HS is a common hereditary hemolytic anemia

HS has been reported worldwide<sup>12-15</sup> with an incidence of about 1/2000 people in Northern Europe,<sup>14</sup> and it is the most common hereditary hemolytic anemia in Japan.<sup>15</sup> According to a report by Kutler,<sup>16</sup> the incidence of HS is up to 1/150 in men and 1/800 in women, when advanced dual-beam laser technology was used for the screening. In China, there is still a lack of accurate HS epidemiological survey data, but related reports are common. Li et al.<sup>17</sup> reported that HS accounted for 31.5% of 356 cases of hereditary hemolytic disease. Wang et al.<sup>18</sup> found among 140 children with hemolytic anemia admitted to their hospital that 17.9% were diagnosed with HS.

## 1.2 | Ease of misdiagnosis or missed HS

In 2009, Wang et al.<sup>8</sup> proposed the need to improve the diagnostic level of HS in response to its high incidence and difficult diagnosis. However, some reports on misdiagnosis or missed diagnosis of HS still exist in recent years.<sup>10,11,19</sup> Misdiagnosis or missed diagnosis of HS is mainly due to: (a) the obviously heterogeneous clinical manifestations of HS; (b) the sensitivity or specificity of some diagnostic tests commonly used in the current HS diagnostic protocol, such as the mean corpuscular hemoglobin concentration (MCHC) detection, erythrocyte osmotic fragility test (OFT), peripheral red blood cell morphology examination, which are not ideal; and (c) there is insufficient knowledge of HS.

The clinical manifestations of HS (anemia, jaundice, and splenomegaly), and a common complication (cholelithiasis), are similar to those in patients with anemia such as THAL and AIHA. Therefore, it is difficult to distinguish HS from other types of anemia. For

example, a male patient who had jaundice but no symptoms of anemia was misdiagnosed as having autoimmune hepatitis, while his 5-month-old son who had obvious symptoms of anemia and jaundice was misdiagnosed as having AIHA. Both were finally diagnosed with HS.<sup>10</sup> Zhong et al.<sup>19</sup> reported four cases of HS patients who had been treated in many hospitals due to "various degrees of anemia and jaundice," and had been misdiagnosed or informed of having an unknown diagnosis for a long time. Moreover, severe HS with typical symptoms can also be misdiagnosed and mistreated for a long time.<sup>11</sup> Clinical misdiagnosis and mistreatment can both cause physical harm to the patient and increase the patient's medical expenses.

The clinical manifestations and severity of HS are related to the types of membrane protein defects that occur. To date, the main membrane protein defects in HS involve ankyrin,  $\alpha$ -spectrin,  $\beta$ -spectrin, band 3, and protein 4.2, which are encoded by ANK1, SPTA1, SPTB, SLC4A1, and EPB42 genes, respectively (Table 1).<sup>2,9,20</sup> Mariani et al.<sup>21</sup> found that band 3 protein defects accounted for about 54% of 300 European patients with HS. Park et al.<sup>22</sup> found that ankyrin protein defects accounted for about 52% of HS patients in South Korea. Patients with  $\alpha$ -spectrin protein defects have been reported to develop severe anemia, while patients with ankyrin, band 3, and protein 4.2 defects have mild to moderate anemia.<sup>23</sup> In short, there are regional and inter-population differences in the types of membrane protein defects in HS patients, which also bring about difficulties in the diagnosis of HS.<sup>8,21,22</sup>

The HS diagnostic protocol developed by Shen et al.<sup>7</sup> proposed that if a patient has more microspherocytes (>10%) in the peripheral blood, with increased red blood cell permeability and fragility, and a positive family history, he/she, regardless of the symptoms, can be diagnosed with HS. The HS diagnostic guidelines developed by Bolton-Maggs et al.<sup>9</sup> proposed that HS can be confirmed with no need to perform other tests when patients have a positive family history, typical clinical features, and abnormal laboratory test results (peripheral blood spherocytosis, MCHC increase, reticulocyte increase). However, the existing HS diagnosis protocols are usually difficult to be used by the clinicians in the following aspects:

1. When the patients' parents have trait and mild HS with no obvious symptoms, it is easy to report this as a negative family history.
2. The laboratory tests, such as MCHC, OFT, and peripheral red blood cell morphology examinations, are not sufficiently sensitive or specific.

Main defective membrane proteins	Encoding gene	Chromosome	Position	Mode of inheritance
Ankyrin	ANK1	8	p11.2	AD, AR
$\alpha$ -Spectrin	SPTA1	1	q22-23	AR
$\beta$ -Spectrin	SPTB	14	q23-24.1	AD
Band 3	SLC4A1	17	q21-22	AD
Protein 4.2	EPB42	15	q15-q21	AR

TABLE 1 Genetic characteristics related to hereditary spherocytosis

3. Glucose-6-phosphate dehydrogenase (G6PD) deficiency, AIHA, and other diseases can be accompanied by peripheral blood spherocytes.<sup>7,14</sup>
4. OFT can be positive for hereditary elliptocytosis (HE), AIHA, and other diseases.<sup>9,24</sup>
5. The accuracy of the peripheral red blood cell morphology examination is related to the time of specimen placement and the level of inspectors.
6. Increased bilirubin level in the blood can lead to a false increase in MCHC values.<sup>25</sup>

## 2 | LABORATORY TESTS FOR HS

### 2.1 | Routine blood test

Currently, the whole blood cell parameters used for HS diagnosis include hemoglobin (Hb) level, reticulocyte absolute count (Ret), MCHC, mean spheroid cell volume (MSCV), mean corpuscular volume (MCV), and mean reticulocyte volume (MRV). MCHC and MCV are indirect parameters measured by the blood cell analyzer, which are calculated according to the results of red blood cell count (RBC), Hb, and hematocrit (HCT). MCHC is calculated as Hb divided by HCT and MCV as HCT divided by RBC. HCT is a parameter directly measured by blood cell analyzer and can also be multiplied by RBC and MCV.<sup>24,25</sup> After staining with new methylene blue, red blood cells are treated with an acidic and hypotonic solution to form deproteinized spherocytes. Spherocytes will be divided into mature erythrocytes and reticulocytes by a unique technique based on volume, conductivity and light scattering optical detection. The average volume of all erythrocytes (both mature erythrocytes and reticulocytes) is defined as MSCV.<sup>26,27</sup> MRV refers to the average volume of all reticulocytes and is also one of the reticulocyte parameters in the blood analyzer. MCHC, MCV, and MRV can be detected in the hematology analyzers produced by many companies, including Beckman Coulter, Simens, Horiba and Mindray. However, only the hematology analyzer produced by Beckman Coulter can report MSCV.<sup>28-30</sup>

For the trait form of HS, Hb level and Ret (<3%) are normal; for mild HS, Hb level is 110–150 g/L and Ret is 3%–6%; for moderate HS, Hb level is 80–120 g/L and Ret >6%; and for severe HS, Hb level is 60–80 g/L, Ret is >10%.<sup>1,9</sup> We found that when MCHC >355 g/L is used as the threshold for diagnosing HS, the sensitivity and specificity are 41.07% and 94.47%, respectively,<sup>31</sup> when MCHC  $\geq$ 334.9 g/L is used, the sensitivity and specificity are 82.1% and 94.5%, respectively.<sup>29</sup> When the blood bilirubin level increases, MCHC detection may be affected, with a false increase.<sup>25</sup> Chiron et al.<sup>26</sup> found that when MSCV <MCV is used as the threshold for diagnosing HS, the sensitivity and specificity are 100.0% and 93.3%, respectively. Therefore, we selected patients with HS, THAL, and healthy controls as research subjects, and found that when MSCV <MCV is used as the threshold for diagnosing HS, the sensitivity and specificity are 100% and 96.7%, respectively.<sup>32</sup> Our further study also found that the measurement of MCV >MSCV can be considered as an ideal

index to quickly distinguish HS from THAL.<sup>33</sup> We also compared HS, THAL, AIHA, and G6PD deficiency patients with healthy controls. It was found that MRV is a routine and specific screening index for HS, which is of great significance for the differential diagnosis of different types of hemolytic anemia. When MRV  $\leq$ 95.77 fL is used as the threshold for diagnosing HS, the sensitivity and specificity are 86.80% and 91.20%, respectively.<sup>34</sup> Nair et al.<sup>35</sup> compared HS, AIHA, and healthy controls, and the results showed that when MCV - MSCV >10 fL and MRV - MSCV <25 fL are used as the threshold for diagnosing HS, the sensitivity and specificity are 84.2% and 94.7%. Arora et al.<sup>36</sup> found that when MCV - MSCV >10 fL is used as the threshold for diagnosing HS, the sensitivity and specificity are 82.8% and 95.9%. Using an algorithm of MCV - MSCV >10 fL and MRV - MSCV <25 fL, for the differentiation of HS from immune hemolytic anemia, the sensitivity and specificity reach 68.9% and 98.8%, respectively. We select MSCV <MCV and MRV  $\leq$ 95.77 fL as auxiliary indicators in the proposed new HS diagnostic protocol due to the high sensitivity and specificity, while it is convenient for clinicians to use.

### 2.2 | Red blood cell morphology examination

Red blood cell morphology examination is an essential test for hemolytic anemia, and peripheral blood smear indicating spherocytosis is one of the important bases for the diagnosis of HS. The morphological characteristics of spherocytes include the small size, spherical shape, deep staining, and the disappearance of central lightly stained region.<sup>37</sup> Spherocytes in the HS diagnostic guidelines proposed by Bolton-Maggs et al.<sup>9</sup> were only described because the cell number in the peripheral blood increased. The HS diagnostic protocol developed by Shen et al.<sup>7</sup> describes spherocytes and/or microspherocytes as a diagnostic indicator in more detail. Microspherocytes that are deeply stained with small cell bodies and disappearance of central lightly stained region are shown in the blood smear tests. The cell number ranges from 1%–2% to 60%–70%, mostly above 10% (normal value <5%). However, there are also about 20% of HS patients who lack the typical microspherocytes. Patients with AIHA and G6PD deficiency can be accompanied by peripheral blood spherocytes.<sup>7,14</sup>

### 2.3 | OFT

OFT is a semiquantitative test to detect the resistance of red blood cells in different concentrations of hypotonic saline solutions, and positive results are reported in many diseases such as HS, HE, and AIHA.<sup>9,24,38</sup> Shim et al.<sup>39</sup> compared HS patients with non-HS controls and showed a sensitivity and specificity of OFT in HS diagnosis of 66% and 81.8%, respectively. They also found that the use of flow cytometric fragility test (FCMOF) could improve the diagnosis efficiency, with a sensitivity of 91.3% and a specificity of 95.8%. We used FCMOF test to compare between patients with HS, THAL, and healthy controls, and regarded the percentage of the remaining red

blood cells (<23.6%) as the threshold for diagnosing HS, with a sensitivity of 85.71% and a specificity of 97.24%.<sup>40</sup> Compared with OFT, FCMOF was easy to operate, time-saving, and had fewer interference factors, and high sensitivity and specificity in the diagnosis of HS.

## 2.4 | Acidified glycerol lysis test (AGLT)

Due to the affinity of glycerol and membrane lipids for hypotonic glycerol salt buffer with pH = 6.85, the buffer can chemically react with membrane lipids, resulting in slow hemolysis of the red blood cells, and as cell lysis increases, the level of absorbance of the solution decreases gradually. The time taken to perform the AGLT is the time taken for the level of absorbance to drop to half the initial absorbance level.<sup>24,41,42</sup> A study by Bianchi et al.<sup>43</sup> showed that the AGLT time of HS patients was significantly shortened, and the diagnostic sensitivity of 95% was better than that of OFT. However, patients with AIHA and chronic renal failure can also be positive for AGLT.<sup>14,41</sup>

## 2.5 | Eosin-5'-maleimide (EMA) binding test (EMABT)

EMABT is a test in which EMA, a fluorescent dye, binds to erythrocyte membrane molecules, such as band 3.<sup>44,45</sup> EMABT is a flow cytometric test used to detect the fluorescence intensity of EMA-labeled red blood cells. Manciu et al.<sup>1</sup> reported the sensitivity and specificity of EMABT in diagnosing HS as 90–95% and 95–99%, respectively. Patients with erythrocyte membrane defects such as HE, Southeast Asian ovalocytosis, and hereditary pyropoikilocytosis may be positive for EMABT.<sup>46,47</sup> In addition, EMA is relatively sensitive to temperature, and repeated freezing and thawing of the EMA reagent can easily reduce its fluorescence efficiency and affect the test results. Another disadvantage of EMABT is that the normal controls and HS currently established by individual laboratories lack a common reference ranges due to the different mean fluorescence intensity (MFI) scales displayed on flow cytometry from different producers.<sup>14</sup> Harmonization for all clinical laboratory measurement procedures can minimize erroneous clinical, financial, regulatory, or technical decisions. However, standardization of EMABT across laboratories has been an ongoing issue. As is mentioned, a positive result for HS is indicated by a reduction in MFI reading for the EMA-labeled red cells from a patient, i.e., below the cut-off MFI value. Giving the actual MFI readings is the simplest way to report a test result, which can be a number between two and five digits due to the broad range of fluorescence scales on different models of flow cytometers. Thus, it becomes difficult to compare MFI results between laboratories.<sup>48</sup> The guidelines issued by the International Council for Standardization in Hematology (ICSH) listed EMABT as one of the tests in the HS

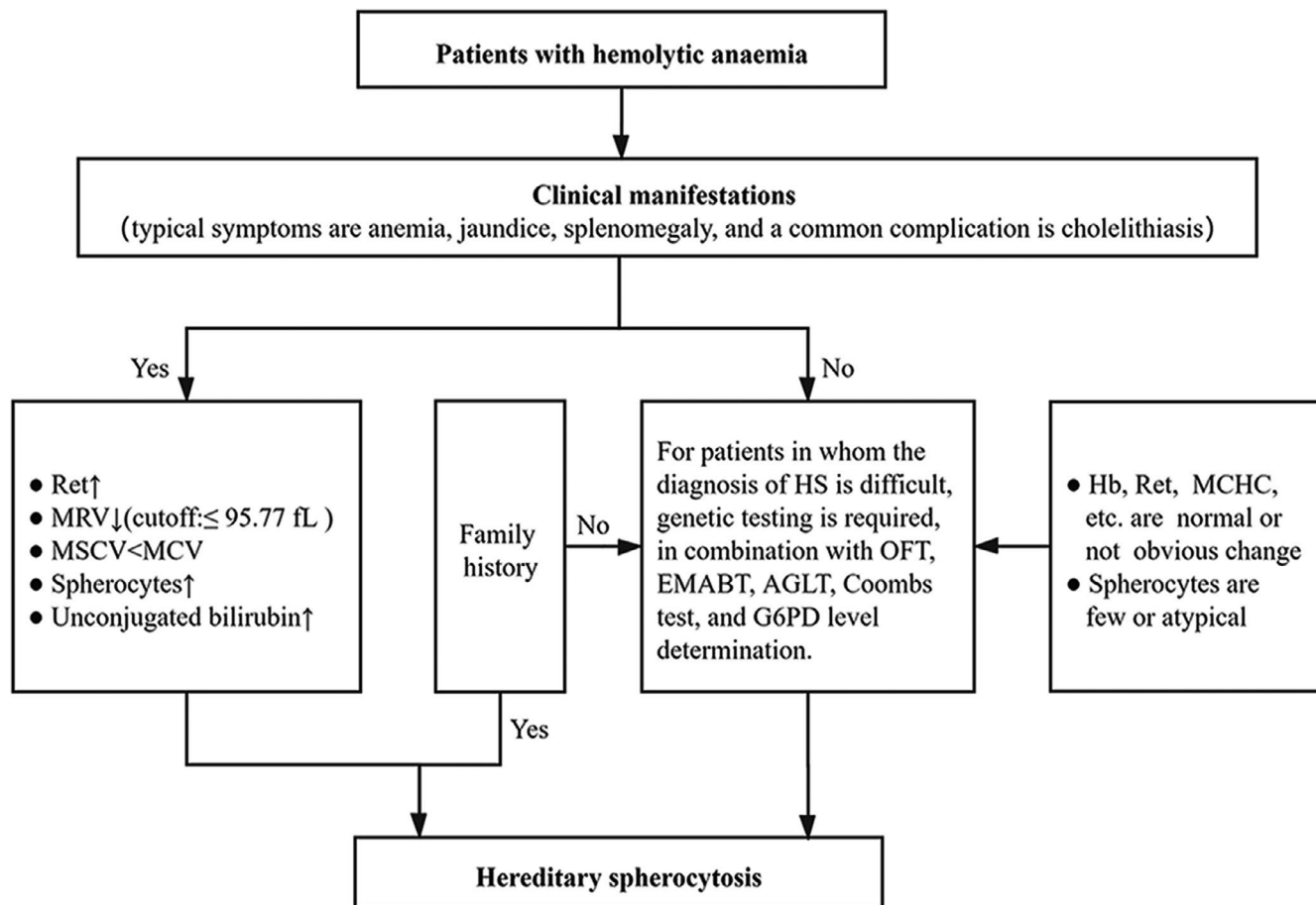
diagnostic protocol and suggests that EMABT can be combined with OFT and AGLT to screen for HS.<sup>14</sup> However, the EMABT is mainly conducted in research centers or professional laboratories of medical institutions. The European Network for Rare Red Cell Anemias (ENERCA) conducted a survey of 25 research centers in Europe and found that only about 60% of research institutions can screen for erythrocyte membrane defects such as HS using EMABT.<sup>49</sup>

## 2.6 | Gene mutation detection

HS involves a variety of gene mutations with scattered mutation sites, and there is no hot spot mutation that can be screened yet.<sup>50</sup> The current analysis method used for HS-related gene mutations is sodium dodecyl sulfate–polyacrylamide gel electrophoresis (SDS-PAGE) technology or real-time fluorescent quantitative polymerase chain reaction (PCR) technology. These can be used to determine the type of membrane protein defects and also to detect the mutation of corresponding genes.<sup>24</sup> However, this method has disadvantages such as that it is time-consuming and expensive, and is not conducive for a wide use in conventional laboratories. In recent years, the emerging high-resolution melting curve has become a genetic analysis method for detecting single-nucleotide polymorphisms. It has the advantages of rapid detection, high throughput, high sensitivity, and high specificity.<sup>51–53</sup> When this method was used to detect the heterozygous change of a single base of a PCR product, the sensitivity and specificity were 95–100% and 99–100%, respectively.<sup>54</sup> Using the high-resolution melting curve to screen for c.166A>G heterozygous mutations of HS-related SLC4A1 gene, both the sensitivity and specificity were 100%.<sup>55</sup> Therefore, the use of high-resolution melting curves to screen HS patients and their families, combined with the direct sequencing methods, can quickly and accurately identify the mutation sites of disease-causing genes. However, the high-resolution melting curve has certain limitations, such as poor identification of A/T or G/C base changes, and lower detection of large fragment-amplified products than small fragment-amplified products.<sup>56</sup> Next-generation sequencing is a new technology for genetic screening and diagnosis, which can measure multiple genes at a time, and has the advantages of high throughput, high speed, and high sensitivity.<sup>57,58</sup> However, this technology cannot detect remote intron mutations, regulatory sequence mutations, and large-scale deletion mutations.<sup>14,59</sup> Compared with conventional inspection methods, the next-generation sequencing has higher cost, and there is a need to improve the current clinical application standards, supervision, and genetic counseling.<sup>60–62</sup>

## 2.7 | Simple and practical protocol for HS diagnosis

As per these existing experimental technologies and studies, combined with our research results,<sup>10,11,29,31–34,63</sup> we propose a simple



**FIGURE 1** Diagnostic process of hereditary spherocytosis. AGLT, acidified glycerol lysis test; EMABT, eosin-5'-maleimide binding test; G6PD, glucose-6-phosphate dehydrogenase; Hb, hemoglobin; MCHC, mean corpuscular hemoglobin concentration; MCV, mean corpuscular volume; MRV, mean reticulocyte volume; MSCV, mean spheroid cell volume; OFT, osmotic fragility test; Ret, reticulocyte absolute count

and practical protocol for HS diagnosis in allusion to the high incidence of HS and the difficulty in HS diagnosis (Figure 1):

1. Clinical manifestations: typical symptoms are anemia, jaundice, splenomegaly, and a common complication is cholelithiasis.
2. Routine laboratory tests: Hb level is normal or decreased (trait form: normal; mild: 110–150 g/L; moderate: 80–120 g/L; severe: 60–80 g/L); Ret is normal or increased (trait form: <3%; mild: 3–6%; moderate: >6%; severe: >10%); MCHC is normal or increased; MRV is decreased (cutoff:  $\leq 95.77$  fL); MSCV < MCV; spherocytes may be increased in number; and serum total bilirubin is increased, mainly presenting with an increase in the level of unconjugated bilirubin.
3. Family investigation: most patients present with autosomal dominant inheritance and have the same examination results and clinical manifestations as one of their parents or other family members.
4. Genetic testing and other screening tests: for patients in whom the diagnosis of HS is difficult, genetic testing is required, in combination with OFT, EMABT, AGLT, Coombs test, and G6PD level determination.

### 3 | CONCLUSION

The diagnosis of HS mainly relies on laboratory tests. As per the HS diagnostic protocol, medical workers rely on MRV, MSCV, MCV, and blood cell morphology examinations when patients present with one of the following clinical manifestations: anemia, jaundice, and splenomegaly. A patient with decreased MRV, MSCV < MCV, and increased number of spherocytes can be initially diagnosed with HS. Then, the patient can be confirmed to have HS if the subsequent family investigation results (routine examination results for hemolytic anemia, including Hb level, Ret, MRV, MSCV, MCV, MCHC, peripheral blood cell morphology, serum total bilirubin and unconjugated bilirubin) and clinical manifestations reveal similar between the patient and one of his/her parents or other family members. For the patients in whom the diagnosis of HS is difficult, genetic testing and other screening tests (OFT, EMABT, AGLT, Coombs test, and G6PD determination) can be selected to confirm the diagnosis.

In summary, compared with the existing HS diagnostic protocols,<sup>7,9</sup> the newly HS diagnostic protocol proposed by us is simple. This new protocol proposes the addition of some experimental tests (with ideal diagnostic efficiency, such as MRV, MSCV, MCV), in combination with the clinical manifestations, family investigation,

routine tests for hemolytic anemia, genetic testing, and other screening tests. Thus, this new HS diagnostic protocol could improve the clinical practice and efficiency of HS diagnosis.

## ACKNOWLEDGEMENT

We thank the Department of Clinical Laboratory, the First Affiliated Hospital of Guangxi Medical University, China.

## CONFLICT OF INTEREST

The authors have no conflicts of interest to declare.

## AUTHOR CONTRIBUTIONS

All authors were involved in formulation of the manuscript. Yangyang Wu and Lin Liao wrote the manuscript. Faquan Lin revised the manuscript. All authors approved the final version of the manuscript.

## DATA AVAILABILITY STATEMENT

The supporting materials used in this study are contained within the article.

## ORCID

Faquan Lin  <https://orcid.org/0000-0002-8631-4339>

## REFERENCES

- Manciu S, Matei E, Trandafir B. Hereditary spherocytosis - diagnosis, surgical treatment and outcomes. A literature review. *Chirurgia (Bucur)*. 2017;112(2):110-116.
- He BJ, Liao L, Deng ZF, Tao YF, Xu YC, Lin FQ. Molecular genetic mechanisms of hereditary spherocytosis: current perspectives. *Acta Haematol*. 2018;139(1):60-66.
- Rets A, Clayton AL, Christensen RD, Agarwal AM. Molecular diagnostic update in hereditary hemolytic anemia and neonatal hyperbilirubinemia. *Int J Lab Hematol*. 2019;41(Suppl 1):95-101.
- Congenital HK, Congenital hemolytic anemia. *Med Clin North Am*. 2017;101(2):361-374.
- Helmi N, Bashir M, Shireen A, Ahmed IM. Thalassemia review: features, dental considerations and management. *Electron Phys*. 2017;9(3):4003-4008.
- Hill QA, Stamps R, Massey E, Grainger JD, Provan D, Hill A. The diagnosis and management of primary autoimmune haemolytic anaemia. *Br J Haematol*. 2017;176(3):395-411.
- Shen T, Zhao YG, eds. *Diagnosis and Curative Criteria of Blood Diseases*, 4th ed. Beijing: Science Press; 2018.
- Wang XQ, Lin GW. Improving the diagnosis of hereditary spherocytosis. *Guoji Shuxue Ji Xueyexue Zazhi*. 2009;32(6):488-489.
- Bolton-Maggs PH, Langer JC, Iolascon A, Tittensor P, King MJ. Guidelines for the diagnosis and management of hereditary spherocytosis-2011 update. *Br J Haematol*. 2012;156(1):37-49.
- Deng Z, Liao L, Yang W, Lin F. Misdiagnosis of two cases of hereditary spherocytosis in a family and review of published reports. *Clin Chim Acta*. 2015;441:6-9.
- Ma S, Deng X, Liao L, et al. Analysis of the causes of the misdiagnosis of hereditary spherocytosis. *Oncol Rep*. 2018;40(3):1451-1458.
- Liu Y, Zheng J, Song L, et al. A novel SPTB gene mutation in neonatal hereditary spherocytosis: a case report. *Exp Ther Med*. 2020;20(4):3253-3259.
- Choi HS, Choi Q, Kim JA, et al. Molecular diagnosis of hereditary spherocytosis by multi-gene target sequencing in Korea: matching with osmotic fragility test and presence of spherocyte. *Orphanet J Rare Dis*. 2019;14(1):114.
- King MJ, Garçon L, Hoyer JD, et al. ICSH guidelines for the laboratory diagnosis of nonimmune hereditary red cell membrane disorders. *Int J Lab Hematol*. 2015;37(3):304-325.
- Yawata Y, Kanzaki A, Yawata A, Doerfler W, Ozcan R, Eber SW. Characteristic features of the genotype and phenotype of hereditary spherocytosis in the Japanese population. *Int J Hematol*. 2000;71(2):118-135.
- Kutter D. Hereditary spherocytosis is more frequent than expected: what to tell the patient? *Bull Soc Sci Med Grand Duche Luxemb*. 2005;1:7-22.
- Li JY, Huang ZX, Xu YQ, et al. Compound heterozygote factor and clinical significance of hemolysis system analysis in the diagnosis of congenital hemolytic anemia: etiologic analysis of 506 cases of anemia and jaundice. *Linchuang Xueyexue Zazhi*. 2005;18(4):204-206.
- Wang H, Zhang H, Li S, Gu M, Hao LC. Clinical analysis of 140 children with hemolytic anemia. *Zhongguo Zonghe Linchuang*. 2011;27(5):545-547.
- Zhong HX, Zhang LJ. Analysis on long term misdiagnosis of hereditary spherocytosis. *Guoji Jianyan Yixue Zazhi*. 2015;36(24):3581-3582+3585.
- Narla J, Mohandas N. Red cell membrane disorders. *Int J Lab Hematol*. 2017;39(Suppl 1):47-52.
- Mariani M, Barcellini W, Vercellati C, et al. Clinical and hematologic features of 300 patients affected by hereditary spherocytosis grouped according to the type of the membrane protein defect. *Haematologica*. 2008;93(9):1310-1317.
- Park J, Jeong DC, Yoo J, et al. Mutational characteristics of ANK1 and SPTB genes in hereditary spherocytosis. *Clin Genet*. 2016;90(1):69-78.
- Perrotta S, Gallagher PG, Mohandas N. Hereditary spherocytosis. *Lancet*. 2008;372(9647):1411-1426.
- Peng MT, ed. *Clinical Blood and Body Fluid Tests*. Beijing: People's Medical Publishing House; 2017.
- Zhong WF, Le JX. Reasons for false increase of MCHC detected using blood cell analyzer and treatment methods. *Xiandai Jianyan Yixue Zazhi*. 2008;23(6):127.
- Chiron M, Cynober T, Mielot F, Tchernia G, Croisille L. The GEN.S: a fortuitous finding of a routine screening test for hereditary spherocytosis. *Hematol Cell Ther*. 1999;41(3):113-116.
- Broséus J, Visomblain B, Guy J, Maynadié M, Girodon F. Evaluation of mean sphered corpuscular volume for predicting hereditary spherocytosis. *Int J Lab Hematol*. 2010;32(5):519-523.
- Buttarelli M. Laboratory diagnosis of anemia: are the old and new red cell parameters useful in classification and treatment, how? *Int J Lab Hematol*. 2016;38(Suppl 1):123-132.
- Liao L, Xu Y, Wei H, et al. Blood cell parameters for screening and diagnosis of hereditary spherocytosis. *J Clin Lab Anal*. 2019;33(4):e22844.
- Fermo E, Vercellati C, Bianchi P. Screening tools for hereditary hemolytic anemia: new concepts and strategies. *Expert Rev Hematol*. 2021;14(3):281-292.
- Tao YF, Deng ZF, Liao L, Qiu YL, Chen WQ, Lin FQ. Comparison and evaluation of three screening tests of hereditary spherocytosis in Chinese patients. *Ann Hematol*. 2015;94(5):747-751.
- Lin FQ, Tang JG, Ju Y, Qiu YL. The diagnostic value of mean sphered cell volume in hereditary spherocytosis. *Shiyong Yixue Zazhi*. 2010;26(14):2537-2539.
- Liao L, Deng ZF, Qiu YL, Chen P, Chen WQ, Lin FQ. Values of mean cell volume and mean sphered cell volume can differentiate hereditary spherocytosis and thalassemia. *Hematology*. 2014;19(7):393-396.
- Xu Y, Yang W, Liao L, et al. Mean reticulocyte volume: a specific parameter to screen for hereditary spherocytosis. *Eur J Haematol*. 2016;96(2):170-174.
- Nair SC, Arora N, Jain S, Inbakumar D, Mammen J, Sitaram U. Mean reticulocyte volume enhances the utility of red cell mean sphered

- cell volume in differentiating peripheral blood spherocytes of hereditary spherocytosis from other causes. *Indian J Pathol Microbiol.* 2015;58(3):307-309.
36. Arora RD, Dass J, Maydeo S, Arya V, Kotwal J, Bhargava M. Utility of mean spheroid cell volume and mean reticulocyte volume for the diagnosis of hereditary spherocytosis. *Hematology.* 2018;23(7):413-416.
  37. Palmer L, Briggs C, McFadden S, et al. ICSH recommendations for the standardization of nomenclature and grading of peripheral blood cell morphological features. *Int J Lab Hematol.* 2015;37(3):287-303.
  38. Farias MG. Advances in laboratory diagnosis of hereditary spherocytosis. *Clin Chem Lab Med.* 2017;55(7):944-948.
  39. Shim YJ, Won DI. Flow cytometric osmotic fragility testing does reflect the clinical severity of hereditary spherocytosis. *Cytometry B Clin Cytom.* 2014;86(6):436-443.
  40. Tao YF, Deng ZF, Liao L, et al. Evaluation of a flow-cytometric osmotic fragility test for hereditary spherocytosis in Chinese patients. *Acta Haematol.* 2016;135(2):88-93.
  41. Zanella A, Izzo C, Rebulli P, Zanuso F, Perroni L, Sirchia G. Acidified glycerol lysis test: a screening test for spherocytosis. *Br J Haematol.* 1980;45(3):481-486.
  42. Ciepela O. Old and new insights into the diagnosis of hereditary spherocytosis. *Ann Transl Med.* 2018;6(17):339.
  43. Bianchi P, Fermo E, Vercellati C, et al. Diagnostic power of laboratory tests for hereditary spherocytosis: a comparison study in 150 patients grouped according to molecular and clinical characteristics. *Haematologica.* 2012;97(4):516-523.
  44. Sharma M. In: Pathogenesis and investigations in hereditary red blood cell membrane disorders. Saxena R, Pati HP, eds. *Hematopathology: Advances in Understanding.* Singapore: Springer; 2019:59-75.
  45. Fanhchaksai K, Manowong S, Natesirinilkul R, Sathitsamitphong L, Charoenkwan P. Flow cytometric test with eosin-5-maleimide for a diagnosis of hereditary spherocytosis in a newborn. *Case Rep Hematol.* 2019;2019:5925731. <https://doi.org/10.1155/2019/5925731>
  46. Jamwal M, Sharma P, Das R. Laboratory approach to hemolytic anemia. *Indian J Pediatr.* 2020;87(1):66-74.
  47. King MJ, Telfer P, MacKinnon H, et al. Using the eosin-5-maleimide binding test in the differential diagnosis of hereditary spherocytosis and hereditary pyropoikilocytosis. *Cytometry B Clin Cytom.* 2008;74(4):244-250.
  48. Hunt L, Greenwood D, Heimpel H, Noel N, Whiteway A, King MJ. Toward the harmonization of result presentation for the eosin-5-maleimide binding test in the diagnosis of hereditary spherocytosis. *Cytometry B Clin Cytom.* 2015;88(1):50-57.
  49. King MJ, Zanella A. Hereditary red cell membrane disorders and laboratory diagnostic testing. *Int J Lab Hematol.* 2013;35(3):237-243.
  50. Deng ZF, Lin FQ. Progress in laboratory examination techniques for hereditary spherocytosis. *Linchuang Jianshan Zazhi.* 2014;32(3):217-219.
  51. Ju M, Bai X, Zhang T, et al. Mutation spectrum of COL1A1/COL1A2 screening by high-resolution melting analysis of Chinese patients with osteogenesis imperfecta. *J Bone Miner Metab.* 2020;38(2):188-197.
  52. Ma SY, Liao L, Bj HE, Lin FQ. Application of high resolution melting curve analysis in detection of SLC4A1 gene mutation in patients with hereditary spherocytosis. *Zhongguo Shiyuan Xueyexue Zazhi.* 2018;26(6):1826-1830.
  53. Islam MT, Sarkar SK, Sultana N, et al. High resolution melting curve analysis targeting the HBB gene mutational hot-spot offers a reliable screening approach for all common as well as most of the rare beta-globin gene mutations in Bangladesh. *BMC Genet.* 2018;19(1):1.
  54. Reed GH, Wittwer CT. Sensitivity and specificity of single-nucleotide polymorphism scanning by high-resolution melting analysis. *Clin Chem.* 2004;50(10):1748-1754.
  55. He BJ, Ma SY, Liao L, Lin FQ. Rapid screening of c. 166A>G in SLC4A1 gene by high-resolution melting analysis. *Zhonghua Jianshan Yixue Zazhi.* 2018;41(5):370-373.
  56. Zheng ZJ, Fu QH, Zhou LM. The development and prospects of high-resolution melting analysis. *Zhonghua Jianshan Yixue Zazhi.* 2017;40(2):77-79.
  57. Koohiyani M. Next generation sequencing and genetics of hereditary hearing loss in the Iranian population: new insights from a systematic review. *Int J Pediatr Otorhinolaryngol.* 2020;129:109756.
  58. Agarwal AM, Nussenzeig RH, Reading NS, et al. Clinical utility of nextgeneration sequencing in the diagnosis of hereditary haemolytic anaemias. *Br J Haematol.* 2016;174(5):806-814.
  59. Li JY, Qian BH, Zha ZS, Jiang JJ. ICSH recommendations for diagnosis of hereditary red cell membrane disorders and research status of related methodology. *Linchuang Xueyexue Zazhi.* 2016;29(6):866-870.
  60. Jamuar SS, Tan EC. Clinical application of next-generation sequencing for Mendelian diseases. *Hum Genomics.* 2015;9(1):10.
  61. Xie GH, Shen LS. The status quo and future prospects of the next generation sequencing technologies in clinical diagnostics. *Zhonghua Jianshan Yixue Zazhi.* 2017;40(7):483-485.
  62. Liu Z, Zhu L, Roberts R, Tong W. Toward clinical implementation of next-generation sequencing-based genetic testing in rare diseases: where are we? *Trends Genet.* 2019;35(11):852-867.
  63. Li X, Liao L, Deng X, et al. Alpha-thalassaemia combined with hereditary spherocytosis in the same patient. *Exp Ther Med.* 2018;15(2):1298-1303.

**How to cite this article:** Wu Y, Liao L, Lin F. The diagnostic protocol for hereditary spherocytosis-2021 update. *J Clin Lab Anal.* 2021;35:e24034. <https://doi.org/10.1002/jcla.24034>