

## Research Article

# The Clinical Effects of Intravascular Ultrasound-Guided Percutaneous Coronary Intervention in Patients with Chronic Total Occlusion: A Meta-Analysis

Zhaoshuang Zhong <sup>1</sup>, Long Zhao <sup>1</sup>, Kaiming Chen <sup>2</sup>, and Shuyue Xia <sup>1</sup>

<sup>1</sup>Department of Respiratory, Central Hospital, Shenyang Medical College, Shenyang, China

<sup>2</sup>Department of Cardiovascular Disease, Central Hospital, Shenyang Medical College, Shenyang, China

Correspondence should be addressed to Shuyue Xia; [dr\\_syxia@qq.com](mailto:dr_syxia@qq.com)

Received 13 January 2022; Revised 8 February 2022; Accepted 2 March 2022; Published 17 March 2022

Academic Editor: Pasquale Mone

Copyright © 2022 Zhaoshuang Zhong et al. This is an open access article distributed under the Creative Commons Attribution License, which permits unrestricted use, distribution, and reproduction in any medium, provided the original work is properly cited.

**Background.** The clinical effects of intravascular ultrasound (IVUS)-guided percutaneous coronary intervention (PCI) in patients with chronic total occlusion (CTO) lesions remain unclear. **Methods.** We identified all full-text published studies that compared the effects of IVUS-guided CTO-PCI with angiography-guided CTO-PCI by searching electric databases including PubMed, Embase, Cochrane Library, and ISI Web of Science from the establishment to Nov 2021. There was no language limitation. The endpoints included the incidence of major adverse cardiac events (MACE), cardiac death, all-cause death, myocardial infarction (MI), and target vessel revascularization (TVR). **Results.** Five studies involving a total of 2320 patients were included in this meta-analysis. Compared to the angiography-guided group, IVUS-guided PCI showed no significant reduction in the incidence of MACE ( $I^2 = 27.4\%$ ,  $P = 0.239$ ; RR 0.929, 95% CI 0.765 to 1.128,  $P = 0.457$ ), cardiac death ( $I^2 = 0.0\%$ ,  $P = 0.459$ ; RR 0.574, 95% CI 0.299 to 1.103,  $P = 0.096$ ), all-cause death ( $I^2 = 0.0\%$ ,  $P = 0.964$ ; RR 0.677, 95% CI 0.395 to 1.163,  $P = 0.158$ ), MI ( $I^2 = 46.7\%$ ,  $P = 0.131$ ; RR 0.836, 95% CI 0.508 to 1.377,  $P = 0.482$ ), and TVR ( $I^2 = 21.2\%$ ,  $P = 0.279$ ; RR 0.929, 95% CI 0.679 to 1.272,  $P = 0.648$ ). **Conclusions.** IVUS-guided PCI demonstrated no significant benefit on MACE, cardiac death, all-cause death, MI, and TVR in patients with CTO lesions. However, given the study's limitations, additional high-quality RCTs are needed.

## 1. Introduction

Percutaneous recanalization of chronic total occlusion (CTO) remains one of the most challenging issues in interventional cardiology, even in the era of drug-eluting stents (DESs) [1, 2]. As a widely used technology, intravascular ultrasound (IVUS) guidance can provide a more accurate evaluation of the lesion's morphological features and procedural information and has been proven to be associated with beneficial effects in percutaneous coronary intervention (PCI) therapy [3–5]. However, though IVUS guidance was effective in complex coronary lesions [6, 7], its superiority in the interventional treatment of CTO lesions was not established. Thus, we performed this meta-analysis to compare the clinical effects of IVUS-guided PCI with

conventional angiography-guided intervention in patients with CTO lesions.

## 2. Methods

This meta-analysis was conducted according to the Preferred Reporting Items for Systematic Reviews and Meta-Analyses (PRISMA) statement [8].

**2.1. Literature Search.** We conducted a comprehensive literature search of all published articles without time and language limitations through Nov 2021, using the following major electronic databases: PubMed, Embase, Cochrane Library, and ISI Web of Science. Search terms included the

keywords of “chronic total occlusion” and “intravascular ultrasound.”

**2.2. Study Selection.** Studies were included if they met the following criteria: (1) randomized controlled trial (RCT) or cohort study, (2) IVUS-guided PCI was performed and compared with conventional angiography-guided intervention for patients with CTO lesions (defined as Thrombolysis In Myocardial Infarction flow grade 0 and occlusion duration > three months [9, 10]), and (3) included at least one of the following clinical outcomes: major adverse cardiac events (MACE, as defined by the authors of the enrolled trials), cardiac death, all-cause death, myocardial infarction (MI), and target vessel revascularization (TVR). Letters, comments, and meeting abstracts were excluded from this meta-analysis.

**2.3. Data Abstraction and Quality Assessment.** Two reviewers (Z.S.Z. and L.Z.) used a predesigned form to extract data from the enrolled studies independently. The extracted data included author, publication year, age, sample size, type of stent, target vessel, intervention strategy, length of follow-up, and the incidence of MACE, cardiac death, all-cause death, MI, and TVR. The methodological qualities of the included trials were evaluated according to the Modified Jadad scale scoring by randomization, double blinding, withdrawals and dropouts, and allocation concealment [11]. In case of discrepancies, a consensus was made by the referral to the senior author (S.Y.X.).

**2.4. Statistical Analysis.** All data were analyzed using STATA version 12.0 (Stata Corp, College Station, TX, USA) with the metan function. We calculated the pooled risk ratios (RRs) with 95% confidence intervals (CI) for dichotomous outcomes and used the  $I^2$  test to assess the heterogeneity among the studies. A fixed-effects (FE) model would be applied if  $I^2 \leq 50\%$ . In case of significant heterogeneity ( $50\% < I^2 \leq 75\%$ ), the sensitivity analysis or the subgroup analysis would be considered. A random-effects (RE) model would be applied if heterogeneity remained significant. The data would be treated as unsuitable for pooling in the case of  $I^2 > 75\%$  [12]. The publication bias was assessed using funnel plots with Begg’s test [13]. A two-sided  $P$ -value  $< 0.05$  indicated a statistical significance.

### 3. Results

**3.1. Selected Studies and Baseline Characteristics.** Our Literature search strategy led to an initial identification of 1075 records, of which 425 duplicate records were removed. After the title and abstract screening, a further 643 records were excluded as case reports, letters, comments, meeting abstracts, or articles not related to our topic. After full-text browsing, another two records were removed for lack of relation to our topic or inappropriate set of an experimental group [14, 15]. Finally, five studies involving 2320 cases were included in the meta-analysis [16–20]. The

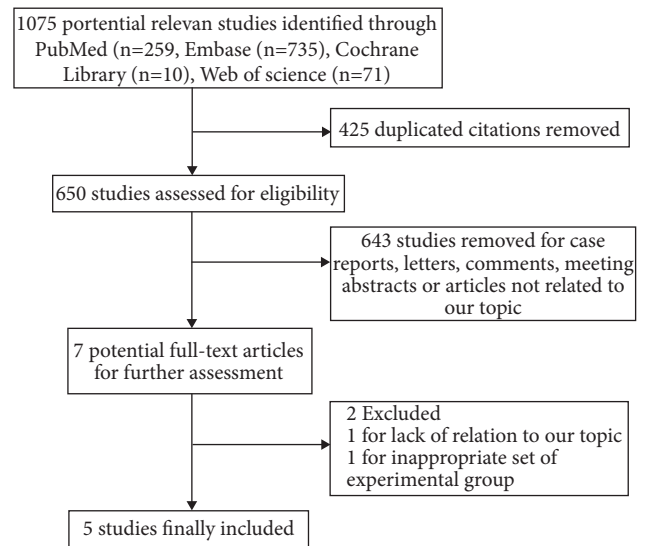


FIGURE 1: Flow chart of study selection.

flow of the literature selection process is illustrated in Figure 1. The baseline characteristics of selected studies are provided in Table 1, and the angiographic and procedural characteristics of enrolled studies are presented in Table 2.

**3.2. Quality Assessment and Publication Bias.** We used the Modified Jadad scale to evaluate the quality of the included literature, and the scores are summarized in Table 3. The publication bias risk was assessed using a funnel plot based on the outcome of cardiac death (Figure 2), and no publication bias was found (Begg’s test,  $P = 0.221$ ).

#### 3.3. Meta-Analysis Results

**3.3.1. MACE.** All studies [16–20] reported the incidence of MACE, and no heterogeneity was found among the studies ( $I^2 = 27.4\%$ ,  $P = 0.239$ ). MACE rate was 13.71% (143/1043) in the IVUS-guided group and 15.66% (200/1277) in the angiography-guided group. The results showed no significant reduction of MACE in the IVUS-guided group (RR 0.929, 95% CI 0.765 to 1.128,  $P = 0.457$ ) (Figure 3).

**3.3.2. Cardiac Death.** All five studies [16–20] reported the incidence of cardiac death. The events rate was 1.15% (12/1043) in the IVUS-guided group and 1.96% (25/1277) in the angiography-guided group. There was a trend towards a decrease of cardiac death (RR 0.574, 95% CI 0.299 to 1.103,  $P = 0.096$ ) in the IVUS-guided group, but it did not reach statistical significance (Figure 4). The FE model was applied since there was no heterogeneity across the studies ( $I^2 = 0.0\%$ ,  $P = 0.459$ ).

**3.3.3. All-Cause Death and MI.** Four enrolled studies [16, 18–20] reported all-cause death ( $I^2 = 0.0\%$ ,  $P = 0.964$ ) and MI ( $I^2 = 46.7\%$ ,  $P = 0.131$ ) incidence with no significant

TABLE 1: Characteristics of included studies.

Study	Year	Study design	IG/CG	Sample size, n	Age, y	Males, %	Hypertension, %	Diabetes,%	Dyslipidemia, %	Smokers, %	Follow-up
Kalogeropoulos et al. [16]	2021	Observational	IG	182	66.5 (57-72.3)	83.5	69.8	22.5	83.5	25.8	49 months (33.0-67.0)
			CG	182	66.0 (58.0-72.0)	84.6	70.3	22.0	80.8	24.2	
Vemmou et al. [17]	2020	Observational	IG	344	64.9 ± 9.8	82.2	92.0	50.4	93.5	24.7	141 days (30-365)
			CG	578	64.8 ± 9.7	82.8	89.9	51.6	94.8	20.5	
Kim et al. [18]	2015	RCT	IG	201	61.0 ± 11.1	80.6	62.7	34.8	NR	35.3	12 months
			CG	201	61.4 ± 10.1	80.6	63.7	33.8		34.3	
Tian et al. [19]	2015	RCT	IG	115	67 ± 10	88.7	74.8	29.6	21.9	39.1	24 months
			CG	115	66 ± 11	80	70.4	27	27.8	39.1	
Hong et al. [20]	2014	Observational	IG	201	62 ± 11	77	58	30	42	29	12 months
			CG	201	62 ± 12	77	60	31	43	31	

IG, intravascular ultrasound-guided group; AG, angiography-guided group; RCT, randomized controlled trial; NR, not reported. Values are presented as mean ± SD or interquartile range.

TABLE 2: Angiographic and procedural characteristics.

Study	IG/ AG	Second-generation DES, %	CTO vessel, %			Successful strategy, %			Number of stents, <i>n</i>	Bilateral injection, %
			LAD	LCX	RCA	AWE	ADR	RA		
Kalogeropoulos et al. [16]	IG	100	25.3	7.1	67.6	60.4	9.3	30.2	2.4(2.0–3.0)	94.0
	AG	100	28.0	9.3	62.6	69.2	9.9	20.9	3.0(2.0–3.0)	90.1
Vemou et al. [17]	IG	NR	32.8	16.7	49.3	53.5	17.4	28.8	2.0(2.0–3.0)	78.1
	AG		23.5	20.5	54.8	57.1	19.8	21.4	2.0(1.0–3.0)	75.5
Kim et al. [18]	IG	100	41.8	14.4	43.8	93.0	7.0		1.7 ± 0.8	50.2
	AG	100	46.8	15.9	37.3	90.5	9.5		1.6 ± 0.7	45.8
Tian et al. [19]	IG	28	44.3	20.9	34.8	89.6	10.4		1.6 ± 0.9	80.9
	AG	20	36.5	14.8	46.1	80.9	19.1		1.5 ± 0.8	89.6
Hong et al. [20]	IG	100	44	16	40			NR	1.71 ± 0.77	NR
	AG	100	34	25	41				1.41 ± 0.69	

IG, intravascular ultrasound-guided group; AG, angiography-guided group; DES, drug-eluting stent; CTO, chronic total occlusion; LAD, left anterior descending artery; LCX, left circumflex coronary artery; RCA, right coronary artery; AWE, antegrade wire escalation; ADR, antegrade dissection reentry; RA, retrograde approach; NR, not reported. Values are presented as mean ± SD or interquartile range.

TABLE 3: Assessment of methodological quality of included studies [11].

Author	Randomization	Double blinding	Allocation concealment	Withdrawals/dropouts	Scores
Kalogeropoulos et al. [16]	NA	NA	NA	NA	NA
Vemou et al. [17]	NA	NA	NA	NA	NA
Kim et al. [18]	Yes	Unclear	Unclear	Yes	5
Tian et al. [19]	Yes	Unclear	Unclear	Yes	5
Hong et al. [20]	NA	NA	NA	NA	NA

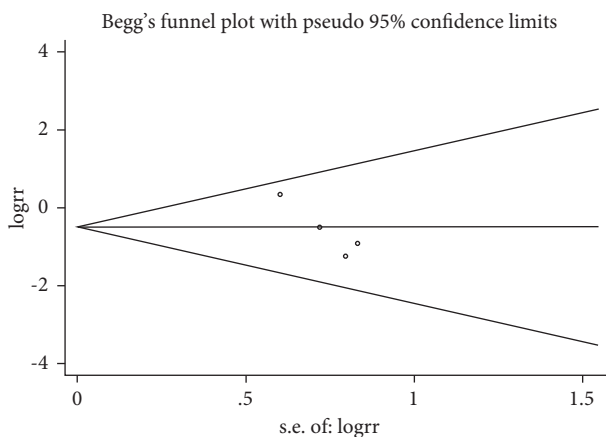


FIGURE 2: Funnel plot for the events of cardiac death.

heterogeneity among the studies. Compared to the angiography-guided group, IVUS-guided PCI showed no significant reduction in the incidence of all-cause death (RR 0.677, 95% CI 0.395 to 1.163,  $P=0.158$ ) (Figure 5) and MI (RR0.836, 95% CI 0.508 to 1.377,  $P=0.482$ ) (Figure 6).

**3.3.4. TVR.** The incidence of TVR was investigated in all five studies [16–20]. The events rate was 6.23% (65/1043) in the IVUS-guided group and 5.95% (76/1277) in the angiography-guided group, indicating no significant difference between the two groups (RR 0.929, 95% CI 0.679 to 1.272,  $P=0.648$ ) (Figure 7). The FE model was used ( $I^2=21.2\%$ ,  $P=0.279$ ).

## 4. Discussion

Several previous studies have reported the advantages of IVUS-guided PCI on coronary vascular disease [21], and meta-analyses further proved its beneficial effects on clinical outcomes in the DES era [22, 23]. A similar relation was expected between CTO lesions and IVUS-guided intervention [24, 25], which led to a broad application of IVUS in the PCI procedure of CTO lesions. However, there are still controversies on the clinical outcomes of IVUS-guided PCI in these patients. On this basis, we conducted this meta-analysis to evaluate the clinical effects of IVUS-guided with angiography-guided PCI in patients with CTO lesions.

Our study, including five studies and a total of 2320 cases, demonstrated that IVUS-guided PCI could not improve the incidence of MACE, cardiac death, all-cause death, MI, and TVR in patients with CTO. In previous studies, IVUS-guided PCI was associated with decreased stent thrombosis [26, 27], which might result from a reduction of procedure-related complications, such as stent under-expansion, malapposition, and incomplete lesion coverage [28–31]. Nevertheless, in the present meta-analysis, the IVUS-guided CTO-PCI showed no significant benefit on clinical outcome indicators compared to angiography-guided treatment. The potential explanation still needs further investigation.

As we all know, IVUS can provide more detailed information on the lesion morphology than angiography-guided intervention, such as reference lumen dimension and lesion length. During the PCI procedure, IVUS is helpful to identify the occlusion point, facilitate the passage of wire in

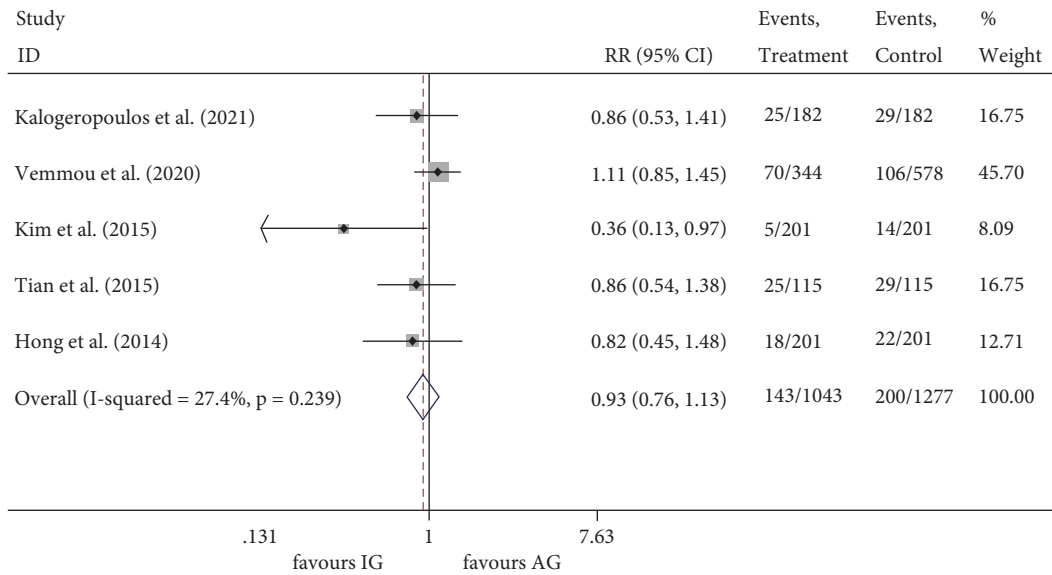


FIGURE 3: RR of the events of MACE. MACE, major adverse cardiac events; RR, relative risk.

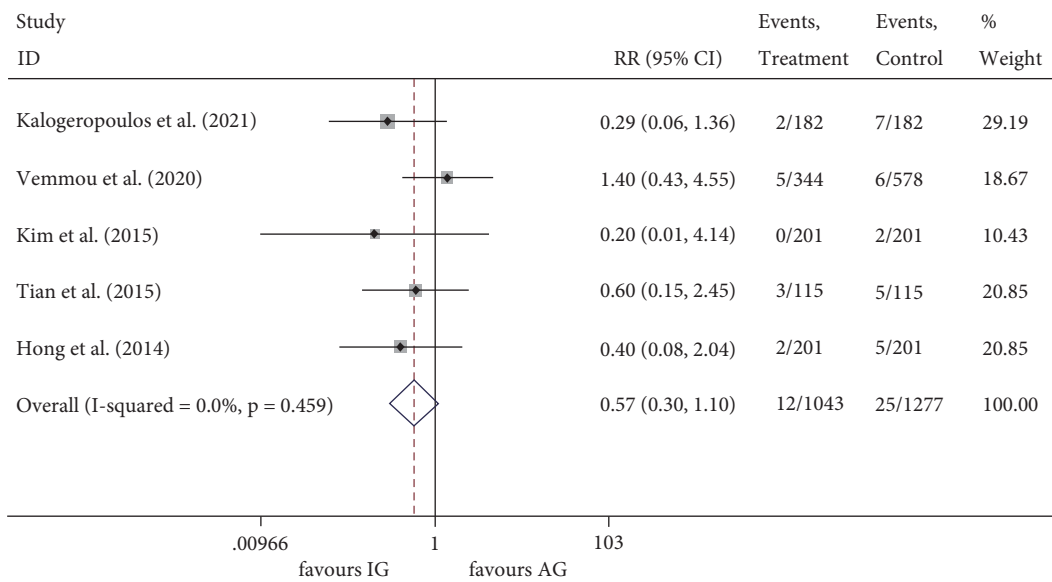


FIGURE 4: RR of the events of cardiac death. RR, relative risk.

cases with a nontapered stump and side-branches nearby the occlusion site [32], ensure a wire in the true lumen and guide the sub-intimal wire into the true lumen after lesion crossing [33], or apply a reverse controlled antegrade and retrograde tracking (CART) technique [34]. However, it should be noted that one of the main characteristics of CTO lesions is calcification. As reported, calcium can be detected in up to 96% of CTO lesions, which may affect the effectiveness of IVUS [35]. The mechanisms leading to coronary calcification may involve the death of inflammatory cells, the release of matrix vesicles, the differentiation of pericytes or vascular smooth muscle cells (VSMCs), and the impact of genetic such as  $\beta$ 2-AR signaling [36]. Calcified CTO was associated with longer procedure and fluoroscopy time, lower technical and procedural success rates, and higher incidence of major

adverse cardiac events [37]. Given the influence of calcification in CTO lesions, some other techniques such as coronary computed tomography angiography (CCTA) [38] and sub-intimal plaque modification (SPM) [39] may be helpful to predict or improve the success rate of attempted PCI.

Some limitations of this study should not be ignored. Firstly, only five trials were enrolled in the present meta-analysis, including three retrospective studies. Though no statistical heterogeneities were observed among the studies, the analysis's power might be restricted due to the limited study number and population size. Secondly, we enrolled two RCTs that did not report the blind method and allocation concealment in detail, leading to potential bias in the present study. Thirdly, this meta-analysis contained trials

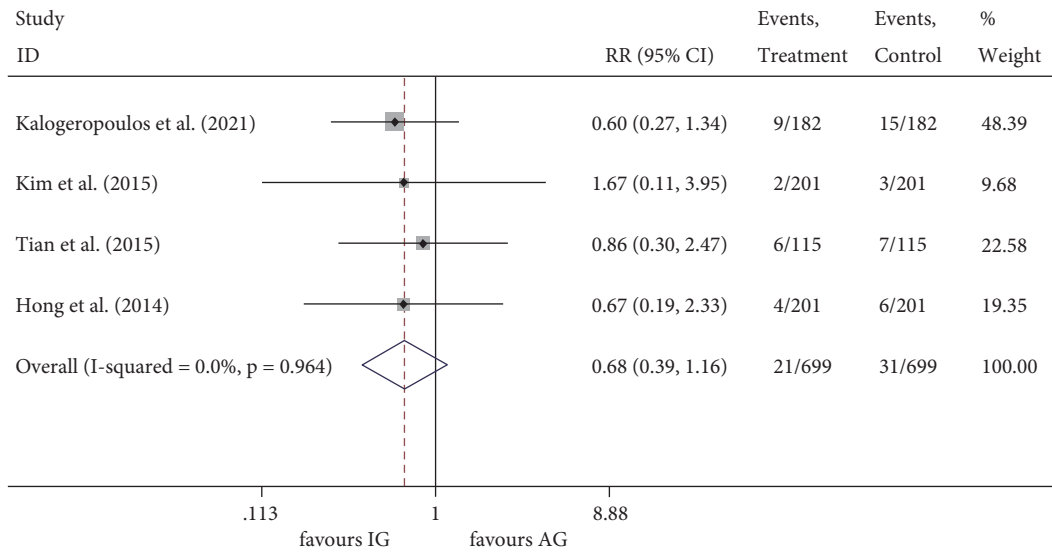


FIGURE 5: RR of the events of all-cause death. RR, relative risk.

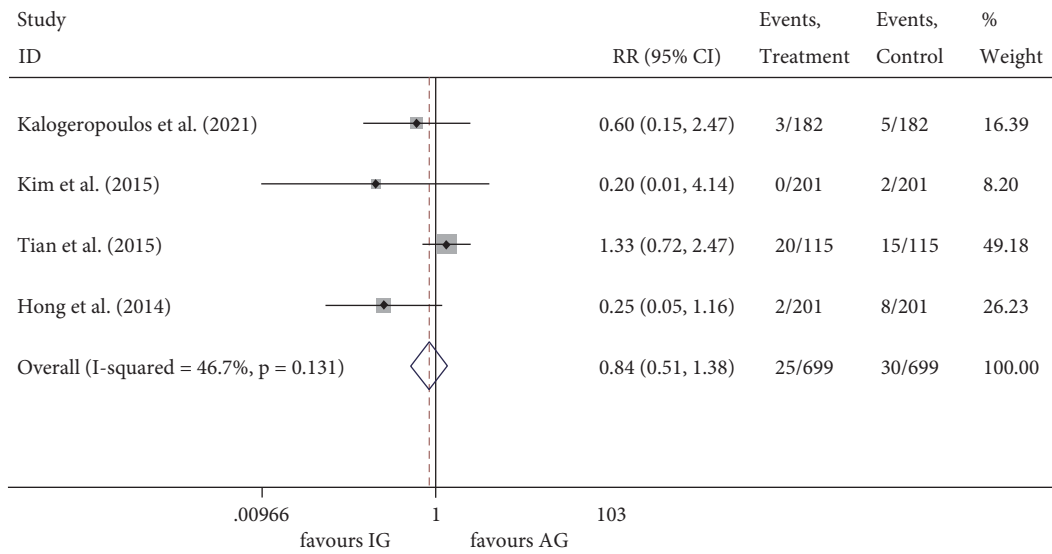


FIGURE 6: RR of the events of MI. MI, myocardial infarction; RR, relative risk.

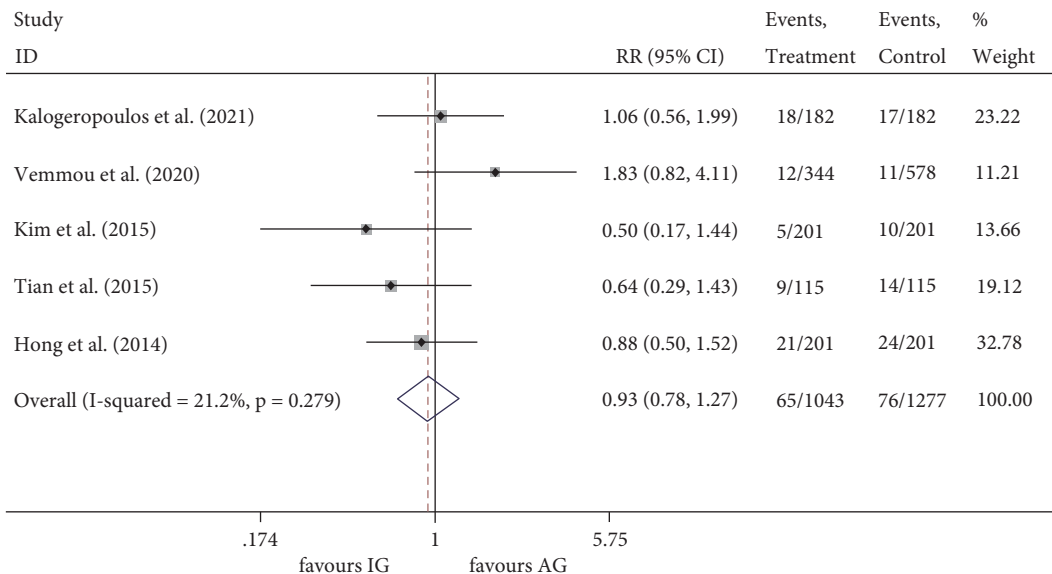


FIGURE 7: RR of the events of TVR. TVR, target vessel revascularization; RR, relative risk.



regardless of patients' condition, the type of stents implanted, the guidance criteria of IVUS procedure, the duration of follow-up, and the occlusion location, which may also influence the outcomes. For these reasons, the study results should be interpreted with care, and more high-quality RCTs are needed.

## 5. Conclusion

IVUS-guided PCI demonstrated no significant benefit on MACE, cardiac death, all-cause death, MI, and TVR in patients with CTO lesions. Given the study's limitations, the findings should be interpreted with caution, and additional high-quality RCTs are needed.

## Data Availability

The data supporting this meta-analysis are from previously reported studies and datasets, which have been cited. The processed data are available from the corresponding author upon request.

## Conflicts of Interest

The authors declare that they have no financial relationships or conflicts of interest regarding the content herein.

## Authors' Contributions

Z.S.Z. and S.Y.X. conceived and designed the study. Z.S.Z. and L.Z. performed the study and wrote the main manuscript text. K.M.C. and S.Y.X. contributed analysis tools and prepared figures. All authors reviewed the manuscript.

## References

- [1] M. R. Patel, S. P. Marso, D. Dai et al., "Comparative effectiveness of drug-eluting versus bare-metal stents in elderly patients undergoing revascularization of chronic total coronary occlusions," *JACC: Cardiovascular Interventions*, vol. 5, no. 10, pp. 1054–1061, 2012.
- [2] B. Van den Branden, B. Rahel, G. Laarman et al., "Five-year clinical outcome after primary stenting of totally occluded native coronary arteries: a randomised comparison of bare metal stent implantation with sirolimus-eluting stent implantation for the treatment of total coronary occlusions (PRISON II study)," *EuroIntervention*, vol. 7, no. 10, pp. 1189–1196, 2012.
- [3] E. Yamamoto, M. Natsuaki, T. Morimoto et al., "Long-term outcomes after percutaneous coronary intervention for chronic total occlusion (from the CREDO-Kyoto registry cohort-2)," *The American Journal of Cardiology*, vol. 112, no. 6, pp. 767–774, 2013.
- [4] J.-S. Kim, T.-S. Kang, G. S. Mintz et al., "Randomized comparison of clinical outcomes between intravascular ultrasound and angiography-guided drug-eluting stent implantation for long coronary artery stenoses," *JACC: Cardiovascular Interventions*, vol. 6, no. 4, pp. 369–376, 2013.
- [5] B. E. Claessen, R. Mehran, G. S. Mintz et al., "Impact of intravascular ultrasound imaging on early and late clinical outcomes following percutaneous coronary intervention with drug-eluting stents," *JACC: Cardiovascular Interventions*, vol. 4, no. 9, pp. 974–981, 2011.
- [6] E. Shlofmitz, R. Torguson, C. Zhang et al., "Impact of intravascular ultrasound on outcomes following percutaneous coronary intervention in complex lesions (iOPEN complex)," *American Heart Journal*, vol. 221, pp. 74–83, 2020.
- [7] K. H. Choi, Y. B. Song, J. M. Lee et al., "Impact of intravascular ultrasound-guided percutaneous coronary intervention on long-term clinical outcomes in patients undergoing complex procedures," *JACC: Cardiovascular Interventions*, vol. 12, no. 7, pp. 607–620, 2019.
- [8] D. Moher, A. Liberati, J. Tetzlaff, D. G. Altman, and P. Group, "Preferred reporting items for systematic reviews and meta-analyses: the PRISMA statement," *Annals of Internal Medicine*, vol. 151, no. 4, pp. 264–269, Article ID W264, 2009.
- [9] G. W. Stone, D. E. Kandzari, R. Mehran et al., "Percutaneous recanalization of chronically occluded coronary arteries," *Circulation*, vol. 112, no. 15, pp. 2364–2372, 2005.
- [10] A. Hoye, R. T. van Domburg, K. Sonnenschein, and P. W. Serruys, "Percutaneous coronary intervention for chronic total occlusions: the Thoraxcenter experience 1992–2002," *European Heart Journal*, vol. 26, no. 24, pp. 2630–2636, 2005.
- [11] M. Oremus, C. Wolfson, A. Perrault, L. Demers, F. Momoli, and Y. Moride, "Interrater reliability of the modified Jadad quality scale for systematic reviews of Alzheimer's disease drug trials," *Dementia and Geriatric Cognitive Disorders*, vol. 12, no. 3, pp. 232–236, 2001.
- [12] M. Cumpston, T. Li, M. J. Page et al., "Updated guidance for trusted systematic reviews: a new edition of the Cochrane Handbook for Systematic Reviews of Interventions," *Cochrane Database of Systematic Reviews*, vol. 10, Article ID ED000142, 2019.
- [13] C. B. Begg and M. Mazumdar, "Operating characteristics of a rank correlation test for publication bias," *Biometrics*, vol. 50, no. 4, pp. 1088–1101, 1994.
- [14] A. Chieffo, A. Latib, C. Caussin et al., "A prospective, randomized trial of intravascular-ultrasound guided compared to angiography guided stent implantation in complex coronary lesions: the AVIO trial," *American Heart Journal*, vol. 165, no. 1, pp. 65–72, 2013.
- [15] L. Bryniarski, J. Dragan, M. Zabojszcz et al., "Intracoronary ultrasound-guided angioplasty for coronary chronic total occlusion," *Kardiologia Polska*, vol. 67, no. 8A, pp. 992–1003, 2009.
- [16] A. S. Kalogeropoulos, O. Alsanjari, J. R. Davies et al., "Impact of intravascular ultrasound on chronic total occlusion percutaneous revascularization," *Cardiovascular Revascularization Medicine*, 2021.
- [17] E. Vemmou, J. Khatri, A. H. Doing et al., "Impact of intravascular ultrasound utilization for stent optimization on 1-year outcomes after chronic total occlusion percutaneous coronary intervention," *Journal of Invasive Cardiology*, vol. 32, no. 10, pp. 392–399, 2020.
- [18] B. K. Kim, D. H. Shin, M. K. Hong et al., "Clinical impact of intravascular ultrasound-guided chronic total occlusion intervention with zotarolimus-eluting versus biolimus-eluting stent implantation: randomized study," *Circulation: Cardiovascular interventions*, vol. 8, no. 7, Article ID e002592, 2015.
- [19] N.-L. Tian, S.-K. Gami, F. Ye et al., "Angiographic and clinical comparisons of intravascular ultrasound- versus angiography-guided drug-eluting stent implantation for patients with chronic total occlusion lesions: two-year results from a

- randomised AIR-CTO study,” *EuroIntervention*, vol. 10, no. 12, pp. 1409–1417, 2015.
- [20] S.-J. Hong, B.-K. Kim, D.-H. Shin et al., “Usefulness of intravascular ultrasound guidance in percutaneous coronary intervention with second-generation drug-eluting stents for chronic total occlusions (from the Multicenter Korean-Chronic Total Occlusion Registry),” *The American Journal of Cardiology*, vol. 114, no. 4, pp. 534–540, 2014.
- [21] S. Ito, T. Suzuki, T. Ito et al., “Novel technique using intravascular ultrasound-guided guidewire cross in coronary intervention for uncrossable chronic total occlusions,” *Circulation Journal*, vol. 68, no. 11, pp. 1088–1092, 2004.
- [22] Y. Zhang, V. Farooq, H. M. Garcia-Garcia et al., “Comparison of intravascular ultrasound versus angiography-guided drug-eluting stent implantation: a meta-analysis of one randomised trial and ten observational studies involving 19,619 patients,” *EuroIntervention*, vol. 8, no. 7, pp. 855–865, 2012.
- [23] J.-S. Jang, Y.-J. Song, W. Kang et al., “Intravascular ultrasound-guided implantation of drug-eluting stents to improve outcome,” *JACC: Cardiovascular Interventions*, vol. 7, no. 3, pp. 233–243, 2014.
- [24] D. Kim, S.-J. Hong, B.-K. Kim et al., “Outcomes of stent optimisation in intravascular ultrasound-guided interventions for long lesions or chronic total occlusions,” *EuroIntervention*, vol. 16, no. 6, pp. e480–e488, 2020.
- [25] Y.-H. Yoon, P. H. Lee, S.-W. Lee et al., “Clinical outcomes after percutaneous coronary intervention for in-stent chronic total occlusion,” *EuroIntervention*, vol. 16, no. 6, pp. e472–e479, 2020.
- [26] P. Roy, D. H. Steinberg, S. J. Sushinsky et al., “The potential clinical utility of intravascular ultrasound guidance in patients undergoing percutaneous coronary intervention with drug-eluting stents,” *European Heart Journal*, vol. 29, no. 15, pp. 1851–1857, 2008.
- [27] B. Witzembichler, A. Maehara, G. Weisz et al., “Relationship between intravascular ultrasound guidance and clinical outcomes after drug-eluting stents,” *Circulation*, vol. 129, no. 4, pp. 463–470, 2014.
- [28] M. C. McDaniel, P. Eshtehardi, F. J. Sawaya, J. S. Douglas Jr., and H. Samady, “Contemporary clinical applications of coronary intravascular ultrasound,” *JACC: Cardiovascular Interventions*, vol. 4, no. 11, pp. 1155–1167, 2011.
- [29] S. Cook, P. Wenaweser, M. Togni et al., “Incomplete stent apposition and very late stent thrombosis after drug-eluting stent implantation,” *Circulation*, vol. 115, no. 18, pp. 2426–2434, 2007.
- [30] K. Fujii, S. G. Carlier, G. S. Mintz et al., “Stent underexpansion and residual reference segment stenosis are related to stent thrombosis after sirolimus-eluting stent implantation,” *Journal of the American College of Cardiology*, vol. 45, no. 7, pp. 995–998, 2005.
- [31] S. Sonoda, Y. Morino, J. Ako et al., “Impact of final stent dimensions on long-term results following sirolimus-eluting stent implantation,” *Journal of the American College of Cardiology*, vol. 43, no. 11, pp. 1959–1963, 2004.
- [32] K. Tsujita, A. Maehara, G. S. Mintz et al., “Intravascular ultrasound comparison of the retrograde versus antegrade approach to percutaneous intervention for chronic total coronary occlusions,” *JACC: Cardiovascular Interventions*, vol. 2, no. 9, pp. 846–854, 2009.
- [33] A. Okamura, K. Iwakura, and K. Fujii, “ViewIT improves intravascular ultrasound-guided wiring in coronary intervention of chronic total occlusion,” *Catheterization and Cardiovascular Interventions: Official Journal of the Society for Cardiac Angiography & Interventions*, vol. 75, no. 7, pp. 1062–1066, 2010.
- [34] S. Rathore, O. Katoh, E. Tuschikane, A. Oida, T. Suzuki, and S. Takase, “A novel modification of the retrograde approach for the recanalization of chronic total occlusion of the coronary arteries,” *JACC: Cardiovascular Interventions*, vol. 3, no. 2, pp. 155–164, 2010.
- [35] K. Fujii, M. Ochiai, G. S. Mintz et al., “Procedural implications of intravascular ultrasound morphologic features of chronic total coronary occlusions,” *The American Journal of Cardiology*, vol. 97, no. 10, pp. 1455–1462, 2006.
- [36] J. Gambardella, X. Wang, P. Mone, W. Khondkar, and G. Santulli, “Genetics of adrenergic signaling drives coronary artery calcification,” *Atherosclerosis*, vol. 310, pp. 88–90, 2020.
- [37] J. Karacsonyi, D. Karpaliotis, K. Alaswad et al., “Impact of calcium on chronic total occlusion percutaneous coronary interventions,” *The American Journal of Cardiology*, vol. 120, no. 1, pp. 40–46, 2017.
- [38] J.-H. Choi, E.-K. Kim, S. M. Kim et al., “Noninvasive discrimination of coronary chronic total occlusion and subtotal occlusion by coronary computed tomography angiography,” *JACC: Cardiovascular Interventions*, vol. 8, no. 9, pp. 1143–1153, 2015.
- [39] I. Xenogiannis, J. W. Choi, K. Alaswad et al., “Outcomes of subintimal plaque modification in chronic total occlusion percutaneous coronary intervention,” *Catheterization and Cardiovascular Interventions*, vol. 96, no. 5, pp. 1029–1035, 2020.