

Resection of Beak-Type Thoracic Ossification of the Posterior Longitudinal Ligament from a Posterior Approach under Intraoperative Neurophysiological Monitoring for Paralysis after Posterior Decompression and Fusion Surgery

Shiro Imagama¹ Kei Ando¹ Zenya Ito¹ Kazuyoshi Kobayashi¹ Tetsuro Hida¹ Kenyu Ito¹
Yoshimoto Ishikawa¹ Mikito Tsushima¹ Akiyuki Matsumoto¹ Satoshi Tanaka¹ Masayoshi Morozumi¹
Masaaki Machino¹ Kyotaro Ota¹ Hiroaki Nakashima¹ Norimitsu Wakao² Yoshihiro Nishida¹
Yukihiro Matsuyama³ Naoki Ishiguro¹

¹Department of Orthopaedic Surgery, Nagoya University Graduate School of Medicine, Nagoya, Aichi, Japan

²Department of Orthopaedic Surgery, Aichi Medical University, Aichigun, Aichi-Ken, Japan

³Department of Orthopaedic Surgery, Hamamatsu University School of Medicine, Hamamatsu, Shizuoka, Japan

Address for correspondence Shiro Imagama, MD, PhD, Department of Orthopaedic Surgery, Nagoya University Graduate School of Medicine, 65, Tsurumai, Showa-Ku, Nagoya, Aichi, 466-8550, Japan (e-mail: imagama@med.nagoya-u.ac.jp).

Global Spine J 2016;6:812–821.

Abstract

Keywords

- ▶ T-OPLL
- ▶ RASPA
- ▶ salvage surgery for paralysis
- ▶ additional dekyphosis
- ▶ spinal cord shortening
- ▶ intraoperative neurophysiological monitoring

Study Design Prospective clinical study.

Objective Posterior decompression and fusion surgery for beak-type thoracic ossification of the posterior longitudinal ligament (T-OPLL) generally has a favorable outcome. However, some patients require additional surgery for postoperative severe paralysis, a condition that is inadequately discussed in the literature. The objective of this study was to describe the efficacy of a procedure we refer to as “resection at an anterior site of the spinal cord from a posterior approach” (RASPA) for severely paralyzed patients after posterior decompression and fusion surgery for beak-type T-OPLL.

Methods Among 58 consecutive patients who underwent posterior decompression and fusion surgery for beak-type T-OPLL since 1999, 3 with postoperative paralysis (5%) underwent RASPA in our institute. Clinical records, the Japanese Orthopaedic Association score, gait status, intraoperative neurophysiological monitoring (IONM) findings, and complications were evaluated in these cases.

Results All three patients experienced a postoperative decline in Manual Muscle Test (MMT) scores of 0 to 2 after the first surgery. RASPA was performed 3 weeks after the first surgery. All patients showed gradual improvements in MMT scores for the lower extremity and in ambulatory status; all could walk with a cane at an average of 4 months following RASPA surgery. There were no postoperative complications.

Conclusions RASPA surgery for beak-type T-OPLL after posterior decompression and fusion surgery resulted in good functional outcomes as a salvage surgery for patients

received
November 9, 2015
accepted after revision
January 4, 2016
published online
February 24, 2016

DOI <http://dx.doi.org/10.1055/s-0036-1579662>.
ISSN 2192-5682.

© 2016 Georg Thieme Verlag KG
Stuttgart · New York

License terms



with severe paralysis. Advantages of RASPA include a wide working space, no spinal cord retraction, and additional decompression at levels without T-OPLL resection and spinal cord shortening after additional dekyphosis and compression maneuvers. When used with IONM, this procedure may help avoid permanent postoperative paralysis.

Introduction

Thoracic ossification of the posterior longitudinal ligament (T-OPLL) causes severe myelopathy and may lead to permanent confinement to a wheelchair. Surgery is required in most cases and while many surgical procedures have been reported,¹⁻¹¹ all carry a high risk of postoperative paralysis. Decompression and instrumented fusion surgery for T-OPLL have recently been shown to have a favorable outcome.^{9,12,13} We have performed posterior decompression and dekyphotic corrective fusion with instrumentation since 1999, especially for beak-type T-OPLL. We reported on the first 20 patients in 2009, most of whom experienced an improvement in preoperative symptoms after the surgery.¹⁴ Patients whose condition did not improve or whose preoperative symptoms were aggravated, subsequently underwent an anterior decompression of the spinal cord with resection of the T-OPLL from the posterior side.

This approach, first reported by Ohtsuka et al,¹⁵ has the major drawback of postoperative aggravation of motor function. Therefore, we performed a modified Ohtsuka procedure with pediclectomy, resection of the transverse process, spinal root sacrifice, and concomitant costotransversectomy as needed under intraoperative neurophysiological monitoring (IONM). We refer to this procedure as “resection at an anterior site of the spinal cord from a posterior approach” (RASPA) surgery. Here, we describe the surgical procedures, IONM, and outcomes as a technical note in three cases treated with RASPA after paralysis resulting from posterior decompression and dekyphotic corrective fusion with instrumentation for beak-type T-OPLL.

Materials and Methods

Patients and Outcomes

Fifty-eight consecutive patients (28 males and 30 females, average age 54 years old) with beak-type T-OPLL underwent posterior decompression and dekyphotic corrective fusion with instrumentation at our institute. Among these patients, 3 (5%) underwent RASPA surgery due to a lack of improvement after the initial surgery, or due to the aggravation of motor paralysis postoperatively. The mean follow-up period was 4.3 years (range, 2 to 7 years). The disease duration, pre- and postoperative ambulatory status with MMT, operative time, estimated blood loss, decompressed and fused area of the thoracic spine, change in Cobb angle of the thoracic spine from before to after surgery, intraoperative ultrasonography findings, IONM findings (transcranial motor evoked potentials [32 channels]), intraoperative and postoperative complications, and outcomes after the first and second surgery

were prospectively evaluated. Outcomes were assessed using the modified Japanese Orthopaedic Association (JOA) score, based on a possible total of 11 points (excluding the cervical score from the original JOA score).^{16,17} An unpaired *t* test and a Fisher exact test were used to compare preoperative JOA scores and surgical outcomes for patients who did and who did not undergo RASPA. This study was approved by the Institutional Review Board of our university.

Surgical Indications and Procedures

The indication for the first surgery—posterior decompression and dekyphotic corrective fusion with instrumentation—was beak-type OPLL with severe anterior spinal cord compression. We described this surgical procedure in 2009.¹⁴ Briefly, after pedicle screws were gently inserted, a temporary rod (titanium alloy or cobalt-chromium alloy rod of ≥ 6 mm in diameter, which was the most rigid rod available at that time) was placed on either side; a laminectomy was then performed using an air drill. In order to achieve further decompression of the spinal cord, rigid bilateral rods for kyphosis reduction were placed using the cantilever technique; this was done with the aid of spinal cord monitoring. The degree of decompression was then checked by ultrasonography. All patients underwent postoperative rehabilitation.

Prior to this surgery, we informed the patients and families about the possible need for a second decompression surgery using RASPA if there was no improvement or if motor paralysis was exacerbated after the first surgery.¹⁸ The RASPA surgery proceeded as follows. First, a unilateral rod and several pedicle screws were removed at the level of the OPLL resection. Because a laminectomy had already been performed in the first surgery, a resection of the transverse process and pedicle was necessary (►Fig. 1A). The spinal root was sacrificed at the OPLL resection level. Next, a posterior partial osteotomy of vertebra adjacent to beak-type T-OPLL levels and an OPLL resection were performed with an air drill from the posterolateral direction, avoiding spinal cord compression (►Fig. 1B). If these surgical devices were obstructed by a posterior rib, a partial resection of the rib (so-called costotransversectomy) was performed. We leaned the air drill as laterally as possible so that we could resect the OPLL of the anterior spinal cord (►Fig. 1C). After resetting the temporary rod, we performed the same procedure on the contralateral side according to OPLL extension (►Fig. 1D). While total resection of the OPLL is ideal, a residual thin OPLL may help avoid cerebrospinal fluid leakage. A thin OPLL does not prevent spinal cord decompression with postoperative dural sac enlargement after floating surgery for cervical OPLL.^{19,20} In our study, the cerebrospinal fluid pressure resulted in the gradual anterior migration of the floating OPLL after about

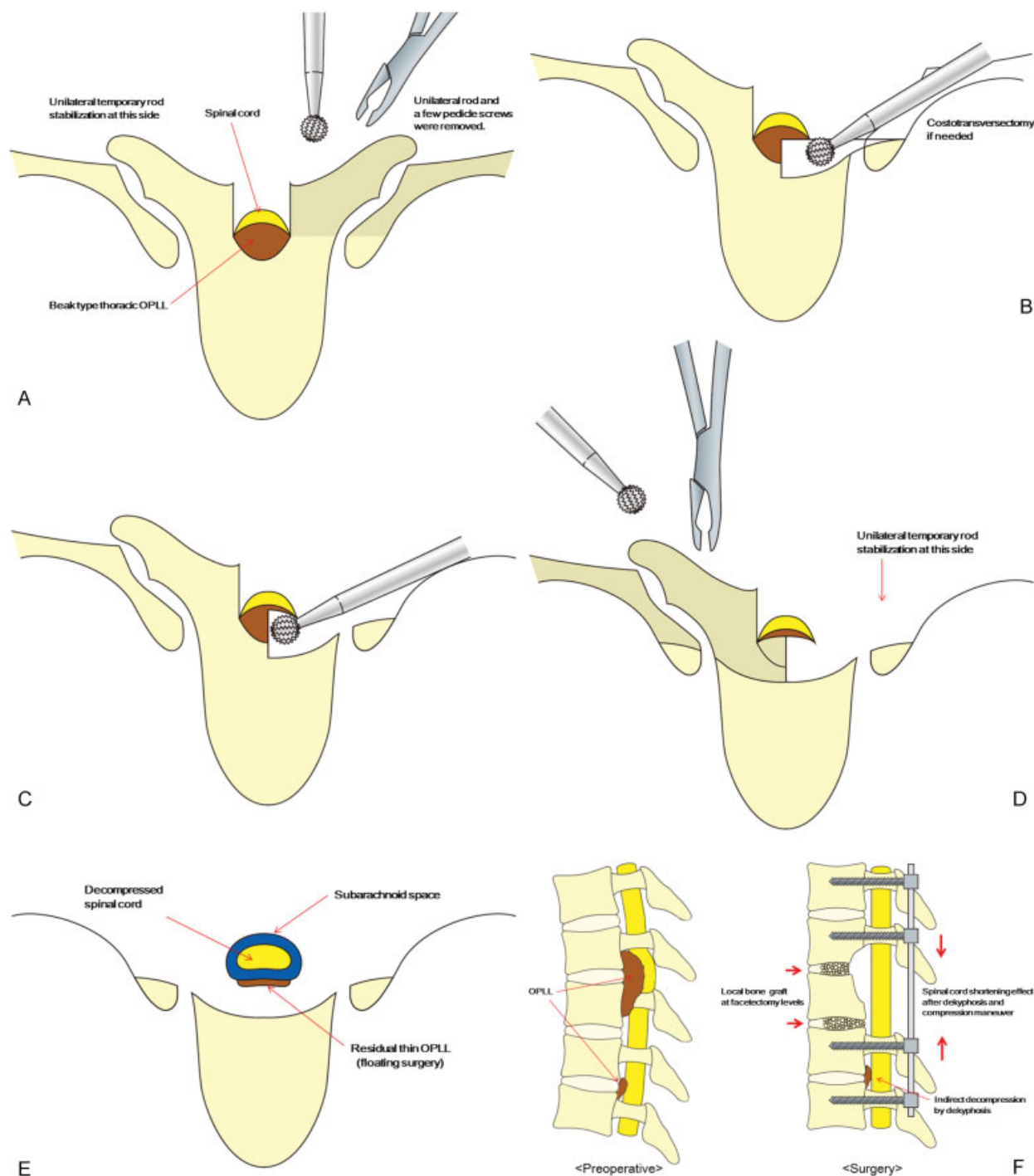


Fig. 1 Surgical procedures in resection at an anterior site of the spinal cord from a posterior approach (RASPA) surgery. (A) Unilateral rod and a few pedicle screws were removed. Resection of the transverse process and pedicle with spinal root sacrifice at the ossification of the posterior longitudinal ligament (OPLL) resection level. (B) Posterior partial osteotomy of vertebra and OPLL resection with an air drill from the posterolateral direction, with costotransversectomy if needed. (C) We did not retract or rotate the vulnerable thoracic spinal cord to avoid spinal cord injury. Surgical devices should be leaned laterally as much as possible. Intraoperative neurophysiological monitoring should be checked frequently during surgery. (D) Same procedure on the contralateral side according to OPLL extension after resetting the temporary rod. (E) Spinal cord decompression was achieved with confirmation of the subarachnoid space in intraoperative ultrasonography. (F) After removal of the OPLL, additional dekyphosis and compression maneuver with a bilateral rod were performed, which gave indirect decompression at other OPLL levels with spinal cord compression and spinal cord shortening. Local bone graft was performed at the OPLL resection level because diskectomy is usually straightforward.

6 weeks. We confirmed the amount of spinal cord decompression and central OPLL resection with ultrasonography, as well as with intraoperative computed tomography (CT) scan when available (►Fig. 1E). IONM was checked frequently

during surgery. Importantly, we did not retract or rotate the vulnerable spinal cord in beak-type T-OPLL because this movement can lead to severe spinal cord damage and permanent motor paralysis after surgery. If the IONM amplitude was

decreased, the surgical procedure was suspended, the surgical field was filled with warm saline, and the blood pressure and body temperature were increased until normal amplitude was restored. After removal of the OPLL, additional dekyphosis with a bilateral rod was performed. This provided indirect decompression at another OPLL level with spinal cord compression. Spinal cord shortening was achieved after dekyphosis and compression. (► Fig. 1F). A posterior interbody fusion with local bone graft was also performed at the OPLL resection level. This procedure was selected because discectomy is typically easy, although in some cases ossification of the anterior longitudinal ligament (OALL) and fusion of the thoracic spine may occur spontaneously after surgery (even if interbody fusion was not achieved).

Postoperatively, patients were prescribed several days of bed rest with drainage tubes in order to avoid a hematoma. Rehabilitation began immediately after surgery while the patient was still in bed. Therapy at this stage included a lower extremity range of motion (ROM) exercise and tilt table standing. Walking exercises were started just after the drainage tubes were removed.

Results

The preoperative data for the three patients is shown in ►Table 1. All of the patients had four levels of beak-type T-OPLL involving ossification of the ligamentum flavum, with severe motor paralysis that prevented walking. As shown in ►Table 2, in the first operation, all of the patients underwent concomitant cervical decompression surgery and five to eight levels of spinal fusion with thoracic dekyphosis. The rate of concomitant cervical laminoplasty and the number of levels of laminectomy and spine fusion did not differ significantly between patients who underwent RASPA and those who did not. In the first surgery, IONM findings deteriorated in all cases, but there were no other intraoperative complications. One patient experienced postoperative motor disturbance during rehabilitation. Two patients showed no improvement and severe postoperative motor paralysis after the first surgery. None of the three patients developed a hematoma or experienced implant failure after the first surgery, but two reoperations were required due to hematoma in patients who did not undergo RASPA. After the first surgery, no motor recovery was found in any of the three patients after several weeks of bed rest.

All three patients underwent RASPA as a second surgery, which was performed 3 weeks after the first surgery. The intraoperative findings in the second surgery are shown in ►Table 3. In the RASPA surgery, one to three levels of the OPLL were resected from the posterior side with two to six pediclectomy and one to four roots sacrificed. Per ultrasound measurement, spinal cord floating was achieved in all cases, as was improved correction of thoracic kyphosis. Frequent IONM revealed that intraoperative improvement of amplitude was achieved. Two of the three patients had an intraoperative pinhole dural tear, both of which were covered with fibrin glue (Beriplast P, CSL Behring, Tokyo, Japan) after dural suture. Overall, there were no postoperative

Table 1 Preoperative characteristics of the three patients

Case	Sex	Age (y)	BMI	OPLL level (beak type)	Coexistence of OLF	Disease duration (mo)	Preoperative JOA score (full score 11)	Preoperative symptoms			Preoperative MMT in lower extremity
								Numbness	Bladder and bowel disturbance	Preoperative gait	
1	Female	64	27.5	4 levels (T4–T5, T5–T6, T6–T7, T7–T8)	Yes	3	3	Yes (trunk and 4 limbs)	No	Not possible	3
2	Male	61	23.3	4 levels (T4–T5, T5–T6, T6–T7, T7–T8)	Yes	5	3	Yes (bilateral lower extremities below inguina)	Yes	Not possible	1
3	Male	31	28.3	4 levels (T1–T2, T2–T3, T7–T8, T8–T9)	Yes	2	1.5	Yes (trunk and left lower extremity)	Yes	Not possible	2

Abbreviations: BMI, body mass index; JOA score, Japanese Orthopaedic Association score; MMT, manual muscle test; OLF, ossification of the ligamentum flavum; OPLL, ossification of the posterior longitudinal ligament.

Table 2 Findings in first surgery

Case	Intraoperative findings						Postoperative findings			
	Concomitant cervical decompression surgery	Fusion level of thoracic spine	Preoperative thoracic kyphosis angle at fusion area ^a (degrees)	Postoperative thoracic kyphosis angle at fusion area (degrees)	Operative time (min)	EBL (mL)	IONM	Intraoperative complication	MMT score in lower extremity just after surgery	MMT score in lower extremity during rehabilitation
1	Yes	8 (T2–T10)	28	17	483	120	Loss of amplitude following full recovery	None	4	2
2	Yes	8 (T2–T10)	24	21	431	1,496	Loss of amplitude without recovery	None	1	1
3	Yes	5 (T6–T11)	30	18	325	1,503	Loss of amplitude without recovery	None	0	0

Abbreviations: EBL, estimated blood loss; IONM, intraoperative neurophysiological monitoring; MMT, manual muscle test.
^aThis angle was measured on a preoperative plain radiograph taken in a standing position.

Table 3 Intraoperative findings in second surgery (RASPA)

Case	Duration after first surgery (d)	Operative time (min)	EBL (mL)	Resection of OPLL levels	Number of pedicles resected	Number of roots sacrificed	Postoperative thoracic kyphosis angle at fusion area (degrees)	Thoracic dekyphosis angle (final – preoperative) (degrees)	IONM	Intraoperative complication
1	20	155	200	T6–T7	2 (Bil. T7)	1 (Lt. T6)	12	16	Loss of amplitude following full recovery	Dural tear
2	22	377	371	T4–T5, T5–T6, T6–T7	6 (Bil. T5, T6, T7)	4 (Bil. T5, T6)	17	7	Loss of amplitude following partial recovery	Dural tear
3	21	326	878	T7–T8, T8–T9	4 (Bil. T8, T9)	4 (Bil. T8, T9)	14	16	Wave appeared after OPLL resection	None

Abbreviations: Bil., bilateral; EBL, estimated blood loss; Lt., left; OPLL, ossification of the posterior longitudinal ligament; RASPA, resection at an anterior site of the spinal cord from a posterior approach; IONM, intraoperative neurophysiological monitoring.

Table 4 Postoperative course after second surgery (RASPA)

Case	Postoperative period until any motor improvement	Postoperative period for full recovery of MMT score for lower extremity	Postoperative period until walking gait	Final ambulatory status	Postoperative JOA score at final follow-up	Recovery of JOA score at final follow-up (%)
1	1 d	3 d	2 wk	Walking with cane	9	75.0
2	2 d	7 mo	6 mo	Walking with cane	10	87.5
3	17 d	4.5 mo	4 mo	Independent gait	9	78.9

Abbreviations: JOA score, Japanese Orthopaedic Association score; MMT, manual muscle test; RASPA, resection at an anterior site of the spinal cord from a posterior approach.

complications. The postoperative course after RASPA surgery is shown in ►Table 4. Each of the three patients experienced an improvement in motor function (beginning on postoperative days 1, 2, and 17, respectively) with a gradual reduction in motor paralysis over several months. All patients had postoperative improvement of motor function (►Fig. 2) and were able to walk with a cane, representing a better ambulatory status than before the first surgery. Good recovery of the JOA score was found at final follow-up.

Pre- and postoperative CT sagittal images from case 2 are shown in ►Fig. 3. The patient showed no improvement after the first surgery (►Fig. 3B, C). Total resection of beak-type T-OPLL and more dekyphosis was achieved after RASPA surgery (►Fig. 3D, E), with gradual improvement of the paralyzed lower extremity. At 4 years after RASPA surgery, CT images showed stability and spinal fusion with OALL extension (►Fig. 3F); at final follow-up the patient’s ambulatory status had improved to walking with a single cane.

Discussion

While there are several approaches for T-OPLL surgery, the optimal method is unclear because of the high rates of postoperative motor disturbance and complications.^{2-11,14} Posterior decompression and fusion surgery for T-OPLL typically results in good surgical outcomes^{12,14,21}; this surgical procedure also has the advantage of concomitant cervical laminoplasty. All three patients who underwent RASPA surgery had concomitant cervical laminoplasty. Because this had no impact on the outcome of the first thoracic surgery there is no need to avoid one-stage combined posterior surgery for cervical and thoracic OPLL. However, some patients experience motor paralysis or severe myelopathy postoperatively. Therefore, we informed all patients prior to the first surgery of the option of additional anterior decompression with a posterior approach if symptoms show no improvement at

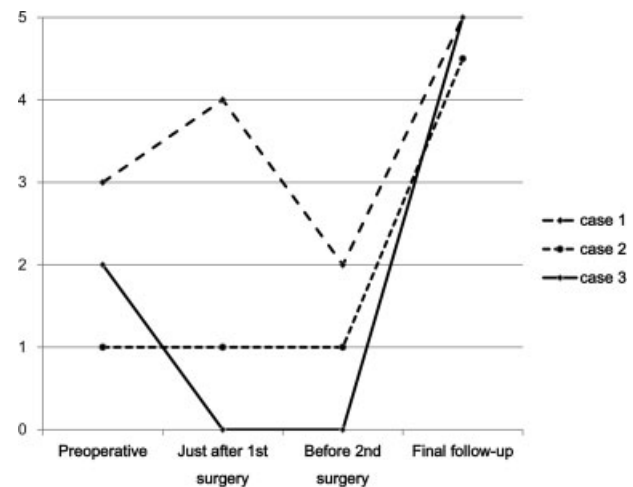


Fig. 2 Preoperative and postoperative course of manual muscle test (MMT) scores for the lower extremity. All cases had postoperative improvement of motor functions. After the second surgery (resection at an anterior site of the spinal cord from a posterior approach), the three cases achieved almost full MMT scores in 3 days, 4.5 months, and 7 months, respectively (shown in ►Table 4).

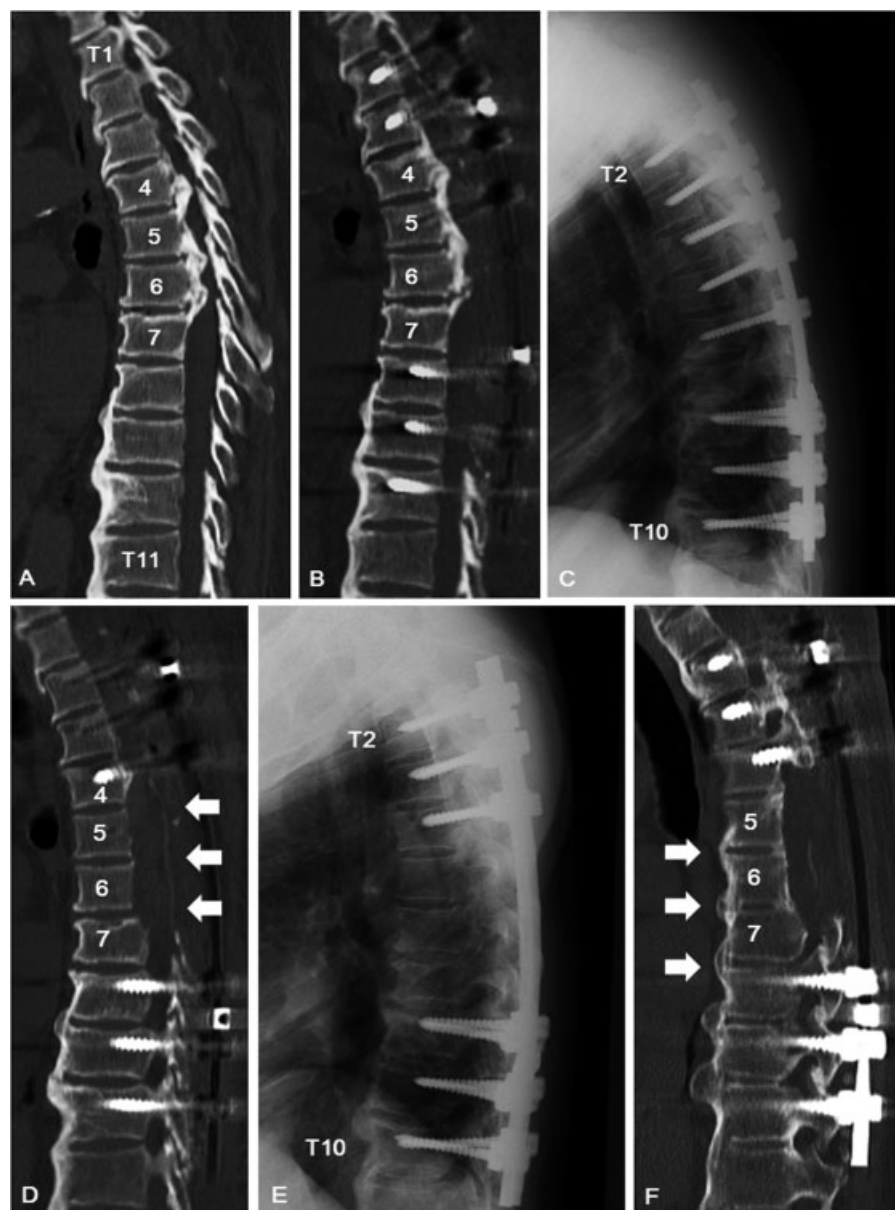

Fig. 3 Case 2, a 61-year-old man. (A) Preoperative computed tomography (CT) sagittal image. (B, C) Lateral plain radiograph and CT sagittal image after posterior decompression and instrumented fusion (first surgery). (D, E) Postoperative lateral plain radiograph and CT sagittal image after resection at an anterior site of the spinal cord from a posterior approach (RASPA; second surgery, arrow). More thoracic dekyphosis was achieved after the second surgery than after the first surgery. (F) At final follow-up, the ossification of the anterior longitudinal ligament was also extended and fused, with stabilization of the thoracic spine (arrow).

about 3 weeks after the first surgery or if symptoms worsen. The two-stage posterior decompression with dekyphosis and anterior decompression surgery proposed by Kawahara et al involve decompression along the circumferential spinal cord with spinal fusion (the ideal decompression).³ Kawahara et al also suggested a need for additional anterior decompression from an anterior approach at 3 weeks after the posterior surgery. We also believe that a second surgery of anterior decompression of the spinal cord with OPLL resection is required if there is no improvement or if symptoms are aggravated at 3 weeks after surgery. However, because improvement is gradual, the second surgery may not be necessary if there is even a slight improvement in symptoms after the first surgery.

Anterior decompression of the spinal cord with OPLL resection can be performed using an anterior or a posterior approach. T-OPLL resection with an anterior approach has been reported as being a good surgical procedure with solid outcomes.^{10,22} The two-stage posterior and anterior combined approach is also a reasonable strategy.^{3,4,6,7} As the anterior approach is technically challenging, it should be performed by surgeons who are familiar with the procedure. The surgeon must have sufficient skills so as to avoid complications such as massive bleeding, postoperative persistent cerebrospinal fluid leakage in the thoracic cage, and pneumocephalus.^{23,24}

It is for the following reasons that we recommend the posterior approach for the second surgery after posterior

decompression and fusion surgery. First, the dura mater and spinal cord are visible during the surgical procedure, which helps avoid injury to the spinal cord. Second, and more importantly, it is possible to perform additional dekyphosis after T-OPLL resection. For multilevel beak-type OPLL, total multilevel resection of the OPLL is ideal but is an invasive surgery with a longer operative time, greater estimated blood loss, and a higher complication rate. The treating surgeon must determine whether a total resection of the OPLL is possible according to the surgical invasiveness and the condition of patients. Therefore, in these cases, we first conduct one or two levels of OPLL resection at the most severe site of spinal cord compression. Following this procedure—in cases without a massive OALL—the more flexible thoracic spine after OPLL resection allows more dekyphosis; the result is greater decompression at the remaining OPLL levels. Third, spinal cord shortening is achieved with dekyphosis and compression, and more blood flow is supplied to the spinal cord. Utilizing a dog model, Kawahara et al found increased blood flow to the spinal cord with spinal shortening.²⁵ This slight spinal cord shortening effect achieved with dekyphosis may also contribute to improvement after RASPA surgery, as well as direct mechanical decompression by OPLL resection. Given this, we typically apply dekyphosis even after the total resection of OPLL. The advantages of posterior surgery are greater than those found in the anterior approach.

Our RASPA procedure is a modified Ohtsuka method. While the original Ohtsuka method is an excellent procedure that enables resection of the total OPLL posteriorly,¹⁵ it also risks spinal cord damage and postoperative paralysis. We note that RASPA surgery may be better described as a new treatment approach, rather than a new operation, because it is based on the Ohtsuka method. However, the resection procedure of beak-type OPLL from a posterior approach has a high risk of intraoperative spinal cord injury, which is why this procedure is not preferred for all cases of beak-type OPLL. We emphasize the importance of this modification in RASPA surgery to achieve a good surgical outcome without intraoperative spinal cord injury for severely paralyzed patients. RASPA surgery is safer due to the wide working space after pediclectomy, total resection of the transverse process, partial resection of the posterior vertebra, costotransversectomy, root sacrifice, and performance of the procedure under IONM. Total pediclectomy at the OPLL resection level, total resection of the transverse process, and partial resection of the posterior vertebra with an air drill and rongeur enable an approach to the central anterior spinal cord without spinal cord retraction. Costotransversectomy is advantageous in thin patients without thick soft tissue because it is possible to position the surgical device to approach the central portion while avoiding the spinal cord.

In order to obtain sufficient working space during RASPA surgery it is necessary to sacrifice the nerve roots. Murakami et al reported that the sacrifice of up to three pairs of thoracic nerve roots, even at the level of the artery of Adamkiewicz, did not result in ischemic neurologic deterioration in total spondylectomy.²⁶ In a dog model, the ligation of bilateral segmental arteries at four or more consecutive thoracic levels

carries a risk of ischemic spinal cord dysfunction.²⁷ Kato et al demonstrated the safety of three or fewer levels of T-OPLL resection with sacrifice of nerve roots from a posterior approach with total pediclectomy.²⁸ Based on this data, we are comfortable performing up to three levels of T-OPLL resection with the sacrifice of nerve roots.

For patients with severe myelopathy, we do not retract and rotate the thoracic spinal cord during RASPA surgery as it may cause spinal cord damage in beak-type T-OPLL. Kato et al recommended dural sac rotation with traction of the sacrificed roots as a novel procedure that enables viewing of the OPLL at the anterior side of the spinal cord from a posterior approach.²⁸ However, we do not recommend nerve root traction in beak-type T-OPLL surgery because IONM has revealed a deterioration in amplitude. We believe that performing the procedure with root traction is more dangerous because it may result in spinal cord retraction and damage.

While it is true that the spinal cord should never be retracted directly, the heat and vibration of the air drill itself may damage the thoracic spinal cord. In the RASPA procedure, this can be addressed by using IONM. As it is often difficult to obtain an IONM wave in patients with severe preoperative motor paralysis, we have utilized multichannel transcranial motor evoked potentials (32 channels) to try and observe a wave in at least one muscle.^{29,30} Multimodal spinal cord monitoring, including somatosensory evoked potential and D (direct)-wave monitoring is also recommended. Vigilance while utilizing IONM is required in order to prevent intraoperative severe spinal cord damage, with appropriate management that may include suspension of the surgical procedure.

Case 1 had a postoperative MMT score of 4, which then deteriorated during rehabilitation. This occurred even after thoracic fusion surgery, and despite the absence of hematoma, implant loosening, or implant breakage. There was no recovery during a few weeks of rest before RASPA surgery, but motor recovery after RASPA started after postoperative day 1. Even after instrumented fixation, rod bending may occur upon standing until bony union of the fixed area is achieved. Even a slight bending of the rod with occult slight hematoma during this period may induce micromotion at the beak-type OPLL level and motor functional deterioration with accompanying spinal cord injury. Most of the thoracic spinal cord is vulnerable to compression, with massive beak-type OPLL and residual spinal cord compression likely to occur in the area of fixation. For these reasons, we recommend a full segmental pedicle screw construct using the most rigid, large diameter rod possible.

This study is limited to three cases because not only is surgery for beak-type T-OPLL relatively uncommon, but it is rare that someone requires a second surgery for OPLL resection after initial T-OPLL surgery. However, there are cases with postoperative aggravation of symptoms or a poor surgical outcome after initial T-OPLL surgery. Given the gravity of paralysis, the findings emanating from this salvage surgery are vital for these patients. One-stage posterior decompression and dekyphotic corrective fusion with instrumentation and RASPA is ideal for spinal cord decompression, but this

procedure is particularly invasive. Thus, we believe that such a procedure should be utilized at least for single- or double-level beak-type T-OPLL at the point of prevention of increasing the surgical invasiveness. Our two-stage strategy may still be appropriate, given the invasiveness of concomitant cervical laminoplasty, posterior decompression and fusion of the thoracic spine, and RASPA surgery. Further studies are required to determine the indication for RASPA surgery before initial beak-type T-OPLL surgery and the timing for RASPA surgery after the initial surgery.

In conclusion, RASPA as a second surgery for beak-type T-OPLL after posterior decompression and fusion surgery contributes to a good functional outcome and improved ambulatory status for paralyzed patients up to 3 weeks after initial surgery. The advantages of RASPA include a wide working space, no retraction of the spinal cord, management based on IONM findings, more decompression at levels without OPLL resection, and spinal cord shortening at the most severe level after additional dekyphosis and compression. This modified surgical procedure gives favorable outcomes with use of IONM for avoidance of postoperative permanent paralysis.

Disclosures

Shiro Imagama: none

Kei Ando: none

Zenya Ito: none

Kazuyoshi Kobayashi: none

Tetsuro Hida: none

Kenyu Ito: none

Yoshimoto Ishikawa: none

Mikito Tsushima: none

Akiyuki Matsumoto: none

Satoshi Tanaka: none

Masayoshi Morozumi: none

Masaaki Machino: none

Kyotaro Ota: none

Hiroaki Nakashima: none

Norimitsu Wakao: none

Yoshihiro Nishida: none

Yukihiro Matsuyama: none

Naoki Ishiguro: none

Acknowledgment

The authors thank Ms. Saho Horiuchi and Ms. Erika Takano for their assistance throughout this study.

References

- 1 Yamazaki M, Koda M, Okawa A, Aiba A. Transient paraparesis after laminectomy for thoracic ossification of the posterior longitudinal ligament and ossification of the ligamentum flavum. *Spinal Cord* 2006;44(2):130–134
- 2 Matsumoto M, Toyama Y, Chikuda H, et al. Outcomes of fusion surgery for ossification of the posterior longitudinal ligament of the thoracic spine: a multicenter retrospective survey: clinical article. *J Neurosurg Spine* 2011;15(4):380–385
- 3 Kawahara N, Tomita K, Murakami H, et al. Circumspinal decompression with dekyphosis stabilization for thoracic myelopathy due to ossification of the posterior longitudinal ligament. *Spine (Phila Pa 1976)* 2008;33(1):39–46
- 4 Ohtani K, Nakai S, Fujimura Y, Manzoku S, Shibasaki K. Anterior surgical decompression for thoracic myelopathy as a result of ossification of the posterior longitudinal ligament. *Clin Orthop Relat Res* 1982;(166):82–88
- 5 Takahata M, Ito M, Abumi K, Kotani Y, Sudo H, Minami A. Clinical results and complications of circumferential spinal cord decompression through a single posterior approach for thoracic myelopathy caused by ossification of posterior longitudinal ligament. *Spine (Phila Pa 1976)* 2008;33(11):1199–1208
- 6 Tokuhashi Y, Matsuzaki H, Oda H, Uei H. Effectiveness of posterior decompression for patients with ossification of the posterior longitudinal ligament in the thoracic spine: usefulness of the ossification-kyphosis angle on MRI. *Spine (Phila Pa 1976)* 2006;31(1):E26–E30
- 7 Tomita K, Kawahara N, Baba H, Kikuchi Y, Nishimura H. Circumspinal decompression for thoracic myelopathy due to combined ossification of the posterior longitudinal ligament and ligamentum flavum. *Spine (Phila Pa 1976)* 1990;15(11):1114–1120
- 8 Yamazaki M, Okawa A, Fujiyoshi T, Furuya T, Koda M. Posterior decompression with instrumented fusion for thoracic myelopathy caused by ossification of the posterior longitudinal ligament. *Eur Spine J* 2010;19(5):691–698
- 9 Matsumoto M, Chiba K, Toyama Y, et al. Surgical results and related factors for ossification of posterior longitudinal ligament of the thoracic spine: a multi-institutional retrospective study. *Spine (Phila Pa 1976)* 2008;33(9):1034–1041
- 10 Fujimura Y, Nishi Y, Nakamura M, Toyama Y, Suzuki N. Long-term follow-up study of anterior decompression and fusion for thoracic myelopathy resulting from ossification of the posterior longitudinal ligament. *Spine (Phila Pa 1976)* 1997;22(3):305–311
- 11 Aizawa T, Sato T, Sasaki H, et al. Results of surgical treatment for thoracic myelopathy: minimum 2-year follow-up study in 132 patients. *J Neurosurg Spine* 2007;7(1):13–20
- 12 Yamazaki M, Mochizuki M, Ikeda Y, et al. Clinical results of surgery for thoracic myelopathy caused by ossification of the posterior longitudinal ligament: operative indication of posterior decompression with instrumented fusion. *Spine (Phila Pa 1976)* 2006;31(13):1452–1460
- 13 Matsuyama Y, Yoshihara H, Tsuji T, et al. Surgical outcome of ossification of the posterior longitudinal ligament (OPLL) of the thoracic spine: implication of the type of ossification and surgical options. *J Spinal Disord Tech* 2005;18(6):492–497, discussion 498
- 14 Matsuyama Y, Sakai Y, Katayama Y, et al. Indirect posterior decompression with corrective fusion for ossification of the posterior longitudinal ligament of the thoracic spine: is it possible to predict the surgical results? *Eur Spine J* 2009;18(7):943–948
- 15 Ohtsuka K, Terayama K, Tsuchiya T, et al. A surgical procedure of the anterior decompression of the thoracic spinal cord through the posterior approach. *Seikei Saigai Geka (Orthopaed Surg Traumatol)* 1983;26:1083–1090
- 16 Hirabayashi K, Miyakawa J, Satomi K, Maruyama T, Wakano K. Operative results and postoperative progression of ossification among patients with ossification of cervical posterior longitudinal ligament. *Spine (Phila Pa 1976)* 1981;6(4):354–364
- 17 Yonenobu K, Abumi K, Nagata K, Taketomi E, Ueyama K. Interobserver and intraobserver reliability of the Japanese Orthopaedic Association scoring system for evaluation of cervical compression myelopathy. *Spine (Phila Pa 1976)* 2001;26(17):1890–1894, discussion 1895
- 18 Imagama S, Ito Z, Ando K, et al. Tips for good surgical results of indirect posterior decompression with corrective fusion for ossification of the posterior longitudinal ligament of the thoracic spine. *Rinsho Seikei Geka (Clinical Orthopaedic Surgery)* 2012;47(9):829–835

- 19 Yamaura I, Kurosa Y, Matuoka T, Shindo S. Anterior floating method for cervical myelopathy caused by ossification of the posterior longitudinal ligament. *Clin Orthop Relat Res* 1999; (359):27–34
- 20 Iwasaki M, Okuda S, Miyauchi A, et al. Surgical strategy for cervical myelopathy due to ossification of the posterior longitudinal ligament: Part 2: Advantages of anterior decompression and fusion over laminoplasty. *Spine (Phila Pa 1976)* 2007;32(6):654–660
- 21 Ando K, Imagama S, Ito Z, et al. Ponte osteotomy during dekyphosis for indirect posterior decompression with ossification of posterior longitudinal ligament of the thoracic spine. *J Spinal Disord Tech* 2014
- 22 Kurosa Y, Yamaura I, Nakai O, Shinomiya K. Selecting a surgical method for thoracic myelopathy caused by ossification of the posterior longitudinal ligament. *Spine (Phila Pa 1976)* 1996; 21(12):1458–1466
- 23 Fujimura Y, Nishi Y, Nakamura M, Watanabe M, Matsumoto M. Myelopathy secondary to ossification of the posterior longitudinal ligament of the thoracic spine treated by anterior decompression and bony fusion. *Spinal Cord* 1997;35(11):777–784
- 24 Min JH, Jang JS, Lee SH. Clinical results of ossification of the posterior longitudinal ligament (OPLL) of the thoracic spine treated by anterior decompression. *J Spinal Disord Tech* 2008; 21(2):116–119
- 25 Kawahara N, Tomita K, Kobayashi T, Abdel-Wanis ME, Murakami H, Akamaru T. Influence of acute shortening on the spinal cord: an experimental study. *Spine (Phila Pa 1976)* 2005;30(6):613–620
- 26 Murakami H, Kawahara N, Tomita K, Demura S, Kato S, Yoshioka K. Does interruption of the artery of Adamkiewicz during total en bloc spondylectomy affect neurologic function? *Spine (Phila Pa 1976)* 2010;35(22):E1187–E1192
- 27 Kato S, Kawahara N, Tomita K, Murakami H, Demura S, Fujimaki Y. Effects on spinal cord blood flow and neurologic function secondary to interruption of bilateral segmental arteries which supply the artery of Adamkiewicz: an experimental study using a dog model. *Spine (Phila Pa 1976)* 2008;33(14):1533–1541
- 28 Kato S, Murakami H, Demura S, Yoshioka K, Hayashi H, Tsuchiya H. Novel surgical technique for ossification of posterior longitudinal ligament in the thoracic spine. *J Neurosurg Spine* 2012;17(6): 525–529
- 29 Muramoto A, Imagama S, Ito Z, et al. The cutoff amplitude of transcranial motor evoked potentials for transient postoperative motor deficits in intramedullary spinal cord tumor surgery. *Spine (Phila Pa 1976)* 2014;39(18):E1086–E1094
- 30 Muramoto A, Imagama S, Ito Z, et al. The cutoff amplitude of transcranial motor-evoked potentials for predicting postoperative motor deficits in thoracic spine surgery. *Spine (Phila Pa 1976)* 2013;38(1):E21–E27