

Primary urothelial carcinoma of the prostate

A rare case report

Jun Zhou, MD^{a,b}, Cheng Yang, MD^{a,b}, Zhaoxiang Lu, MD^{a,b}, Li Zhang, PhD^{a,b}, Yu Yin, MD^{a,c}, Sheng Tai, MD^{a,b}, Chaozhao Liang, MD, PhD^{a,b,*}

Abstract

Rationale: Prostatic urothelial carcinoma is a rare disease. Medical misdiagnosis rates remain high because there are no specific clinical symptoms or imaging features, which decreases patient survival. We report a case of prostatic urethral cancer confirmed by transrectal ultrasound-guided prostate biopsy because of an abnormal digital rectal exam.

Patient concerns: A 55-year-old man was referred to our hospital due to lower urinary tract symptoms that lasted for 5 years.

Diagnoses and Interventions: On digital rectal examination, a hard and enlarged prostate was detected. Computed tomography, bone scintigraphy, and magnetic resonance imaging indicated benign prostatic hyperplasia. The patient underwent transrectal ultrasound-guided prostate biopsy. From the histopathological examination and immunohistochemical markers, a diagnosis of high-grade prostatic urothelial carcinoma was made. We excluded the possibility of urothelial cancer originating in the bladder lining after transurethral resection of the bladder. Radical cystoprostatectomy was performed, followed by 6 cycles of cisplatin and gemcitabine chemotherapy. Postoperative pathology showed primary urothelial carcinoma of the prostate.

Outcomes: The patient recovered smoothly after surgery. After a 6-month follow-up, no evidence of local recurrence or metastatic disease was found.

Lessons: This case reminds clinicians that, for middle-aged men with suspicious digital rectal examinations, a diagnosis of prostatic urothelial carcinoma should be considered. Initial radical surgery followed by combination chemotherapy is suggested for therapeutic management.

Abbreviations: BCG = Bacillus Calmette-Guérin, CIS = carcinoma in situ, MRI = magnetic resonance imaging, PSA = prostate specific antigen.

Keywords: cystoprostatectomy, prostate cancer, robot-assisted laparoscopic surgery, urothelial carcinoma

Editor: N/A.

JZ, CY, and ZXL contributed equally to this manuscript and should be considered co-first authors.

The study was approved by the Ethical Committee the First Affiliated Hospital of Anhui Medical University and informed consent was signed by the patient for the publication of related images and this report.

This work was supported by the National Natural Science Foundation of China (81630019 and 81700662), Junior Research Project Funding of Anhui Natural Science Foundation (No.1708085QH203) and the Natural Science Research Project of Universities in Anhui Province (KJ2018A0195). The authors have no conflicts of interest to disclose.

The authors have no conflicts of interest to disclose.

^a Department of Urology, The First Affiliated Hospital of Anhui Medical University,

^b Institute of Urology and Anhui Province Key Laboratory of Genitourinary Diseases, ^c Department of Pathology, Anhui Medical University, Hefei, China.

* Correspondence: Chaozhao Liang, Department of Urology, The First Affiliated Hospital of Anhui Medical University, 218 Jixi Road, Hefei, 230022, Anhui Province, China (e-mail: liang_chaozhao@ahmu.edu.cn).

Copyright © 2019 the Author(s). Published by Wolters Kluwer Health, Inc. This is an open access article distributed under the terms of the Creative Commons Attribution-Non Commercial-No Derivatives License 4.0 (CCBY-NC-ND), where it is permissible to download and share the work provided it is properly cited. The work cannot be changed in any way or used commercially without permission from the journal.

Medicine (2019) 98:3(e14155)

Received: 11 September 2018 / Received in final form: 14 December 2018 /

Accepted: 24 December 2018

<http://dx.doi.org/10.1097/MD.0000000000014155>

1. Introduction

Primary urothelial carcinoma of the prostate is a rare solid malignant tumor that exhibits highly aggressive biological behavior and has a poor prognosis. Due to the high aggressiveness and strong tendency of local recurrence and distant metastasis to organs such as the bladder, seminal vesicle, and ureter, the overall prognosis of prostatic urothelial carcinoma is poor. These patients all die within 2 years of diagnosis.^[1,2]

Only limited data on this malignancy have been reported.^[3] Due to the lack of specificity, the diagnosis of prostatic urothelial carcinoma is mainly based on pathology and immunohistochemistry. For instance, CK7, P63, and GATA-3 expression are critical evidence for diagnosis.^[4–6]

There are many treatment strategies for prostatic urothelial carcinoma, including surgery, adjuvant chemotherapy, and radiotherapy. Owing to the high aggressiveness and obvious tendency of local recurrence and remote metastases, the overall prognosis of prostatic urothelial carcinoma is poor.^[7] We present the clinical characteristics, histopathological and immunohistochemical findings, and treatment outcomes in a new case of prostatic urothelial carcinoma in a 55-year-old man.

2. Case report

A 55-year-old man was referred to our hospital because of a 5-year history of lower urinary tract obstructive symptoms. Apart

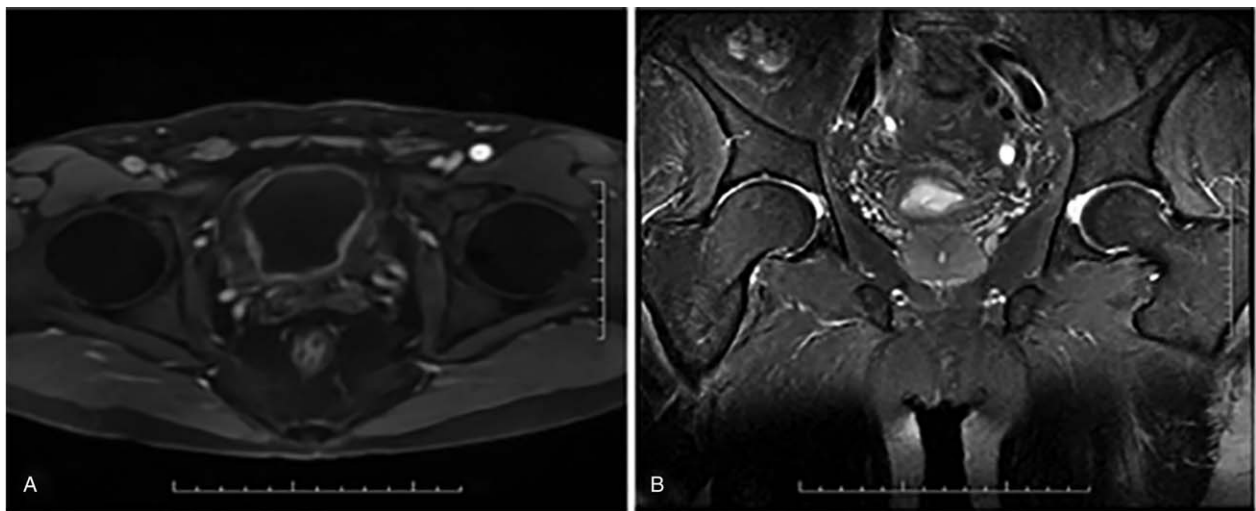


Figure 1. MRI concluded benign prostatic hyperplasia. MRI = magnetic resonance imaging.

from hepatitis B that was treated 10 years previously, no accompanying disease was present. Abdominal examination was unremarkable, and digital rectal examination showed an enlarged and hard prostate with a prostate-specific antigen (PSA) of 0.01 ng/mL. The patient underwent further evaluation, including bone scintigraphy, and magnetic resonance imaging (MRI) (Fig. 1), which revealed no metastasis.

Subsequently, he underwent transrectal ultrasound-guided biopsy of the prostate. Histopathological examination showed high-grade prostatic urothelial carcinoma [Immunohistochemistry: CK5/6(-), CK7(+), CgA(-), GATA-3(+,55%), P40(+), P504s(-), P63(+), PSA(-), Syn(-), uroplakim III(+), and CD56(-)] (Figs. 2 and 3).

The patient subsequently underwent transurethral resection of the bladder, which revealed normal urethral mucosa and bladder

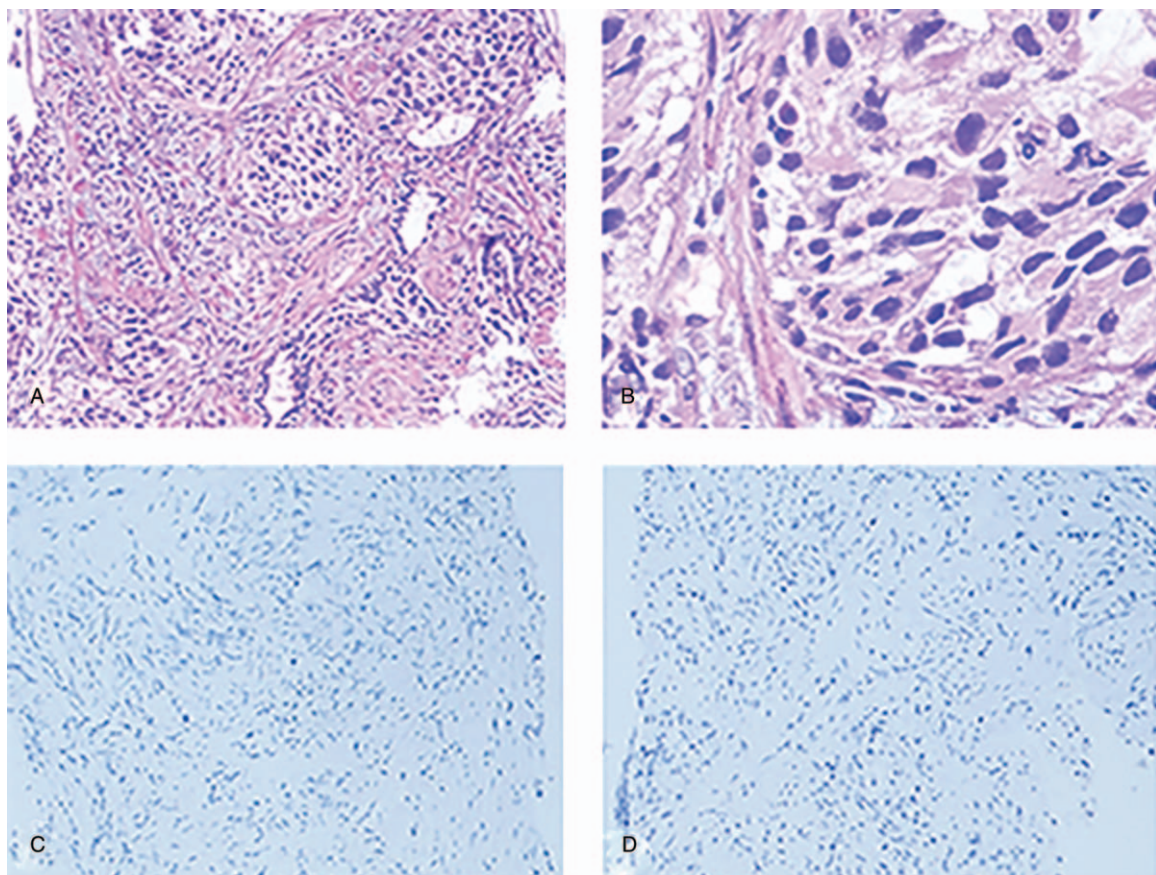


Figure 2. Transrectal prostatic biopsy and negative pathological staining. A. Transrectal prostatic biopsy (HE \times 100) B. Transrectal prostatic biopsy (HE \times 400) C. Diffusely negative staining for PSA. D. Diffusely negative staining for P504 s. MRI = magnetic resonance imaging.

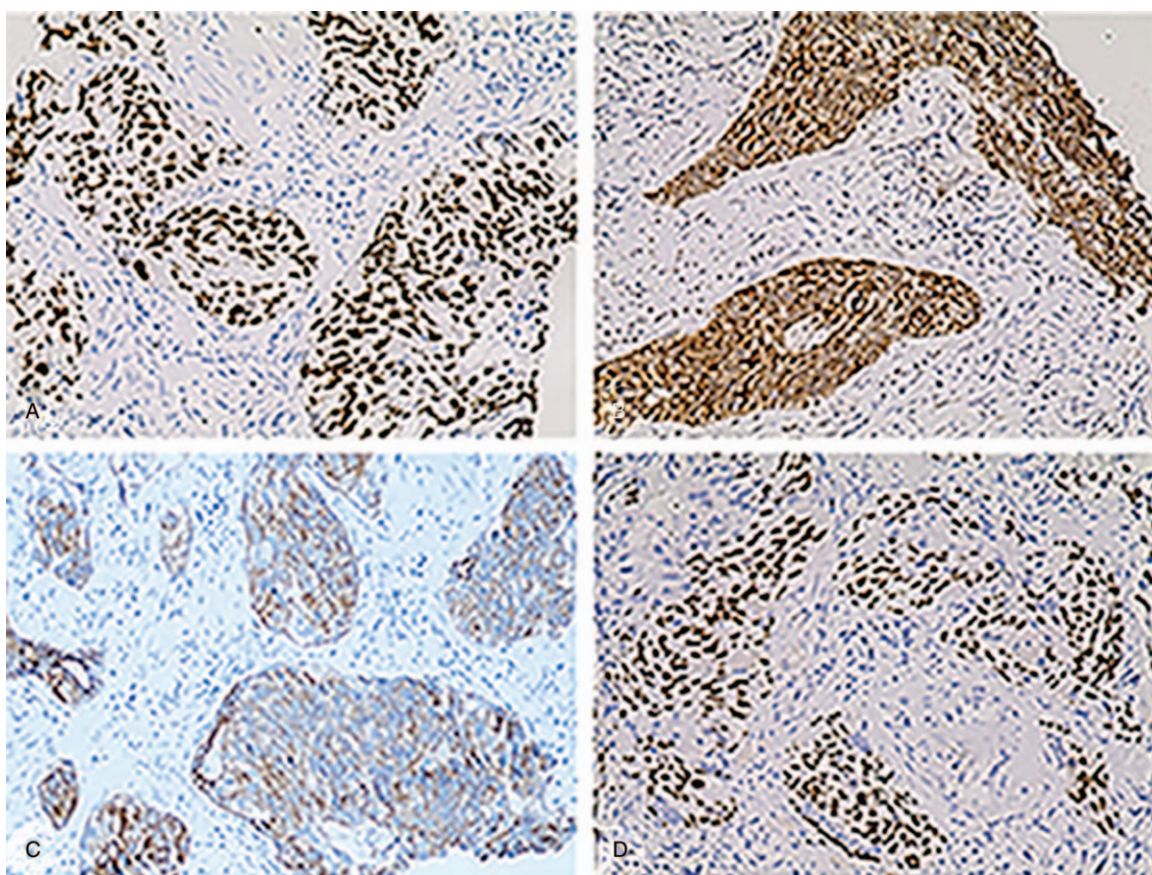


Figure 3. Positive pathological staining. A. Diffusely positive staining for GATA-3. B. Diffusely positive staining for Uroplakin III. C. Diffusely positive staining for CK7. D. Diffusely positive staining for P63.

tissue. Soon after, the patient was readmitted to the urology department and experienced severe dysuria. All of his laboratory data were within the normal ranges, except for a slight increase in reticulocyte (1.61%). Considering his pathological outcome and general health, radical cystoprostatectomy was performed. Ten days after the successful operation, the patient was discharged without any complications. The results of the histopathological examination showed primary urothelial carcinoma of the prostate (Fig. 4A and B). Furthermore, the tumor had invaded the prostatic stroma, duct, acinar, bladder mucosa, and right seminal vesicle. One and 3 lymph node metastases were found around the left and right iliac vessels, respectively (Fig. 4C). After radical surgery, the patient underwent 6 cycles of cisplatin and gemcitabine without any evident harmful reactions. Computed tomography (CT) found no tumor recurrence during the 6-month follow-up period (Fig. 4D). Informed consent was signed by the patients for the publication of related images and this report.

3. Discussion

Primary urothelial carcinoma of the prostate, first reported by Ende et al^[8] in 1963, is an extremely rare tumor, accounting for about 1% to 5% of all prostatic carcinomas.^[9] It manifests in middle-aged men, with a mean age of 54 at diagnosis, and patients are almost 10 years younger than prostatic adenocarcinoma patients.^[1,10] Prostatic urothelial carcinoma presents with nonspecific symptoms, including obstructive voiding, hematuria, and other symptoms similar to the main manifestations of benign

prostatic hyperplasia or prostatic adenocarcinoma.^[8,10–12] Digital rectal examination always reveals that the prostate is enlarged and hard. Laboratory parameters are mostly within normal ranges, and CT, bone scintigraphy, and MRI also do not display any characteristic signs.^[13]

Due to the need to improve the accuracy of preoperative detection, transrectal prostate biopsy and transurethral resection biopsy of the lower urinary tract are recommended to detect the presence of transitional cell carcinoma.^[14] There is a wide spectrum of recommendations for expanding the scope of transurethral resection biopsy. Liedberg et al^[15] recommend the range of transurethral resection biopsy include the area around the verumontanum. Donat et al^[14] recommend examining the bladder neck, trigone, and prostatic urethra by transurethral loop biopsies, along with an ultrasound-guided biopsy of the prostate.

The diagnosis of prostatic urothelial carcinoma is mainly grounded in the combination of histopathology and immunohistochemistry. Pathological examination always shows invasion into the prostate, and the tumor forms many small nests, often with marked nuclear pleomorphism and variably present nucleoli. Immunohistochemically, prostatic urothelial carcinoma is frequently positive for CK7 and CK20,^[13] a vital clue for diagnosis. Moreover, prostatic urothelial carcinoma is generally negative for PSA and P504s, which is also significant for differential diagnosis.^[4–5,13] In addition, almost two-thirds of prostatic urothelial carcinomas have P63 and HMWCK expression. Other markers such as GATA-3 and uroplakin III have also been detected.^[6]

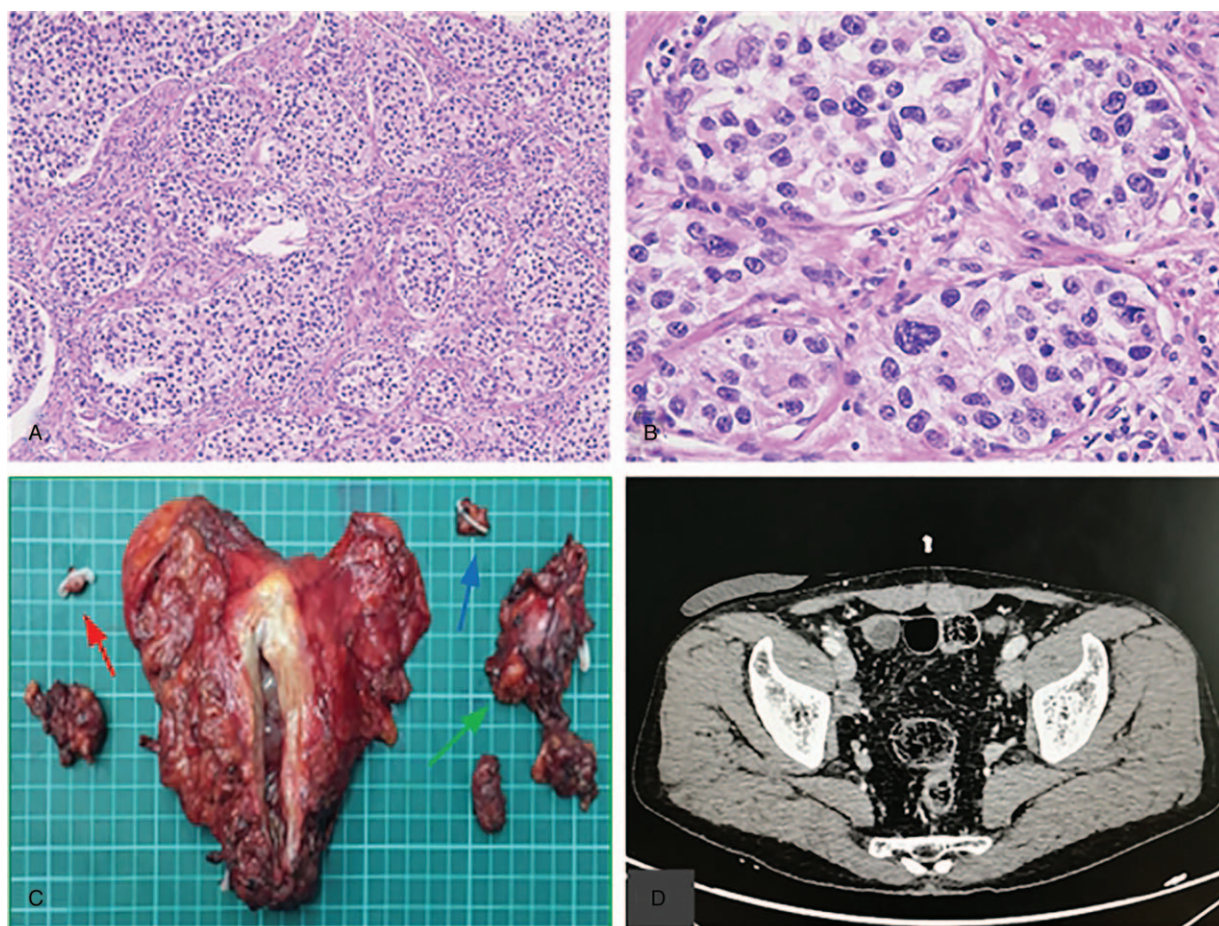


Figure 4. Postoperative pathology and imaging data A. Postoperative prostate tissue (HE \times 100) B. Postoperative prostate tissue (HE \times 400). C. Postoperative gross specimen, Left lymph node (red arrow), right lymph node (blue arrow) and Right ureteral stump (green arrow) D. Postoperative CT image. CT = computed tomography.

Treatment strategies for prostatic urothelial carcinoma are multimodal, including surgery, adjuvant chemotherapy, and radiotherapy. Walsh et al^[16] reported that urothelial carcinoma infiltration of different anatomical locations within the prostate (i.e., the mucosa, acini, ducts, and stroma) was closely correlated with treatment method and prognosis. Several reports have found that complete resection of the visible tumor and intravesical instillation of Bacillus Calmette-Guérin (BCG) is the preferred treatment for carcinoma in situ (CIS) in the prostatic urethral mucosa.^[16–18] Treatment of urothelial carcinoma invading the prostatic ducts is still a controversial issue. Many scholars advocate radical surgery in patients with ductal invasion,^[19,20] whereas Palou Redorta et al reported that patients with CIS involving the prostatic ducts could be treated with intravesical BCG, which has a 70% complete response rate.^[21] When prostatic stromal invasion is identified, radical cystoprostatectomy should be performed. Furthermore, many patients undergo cystoprostatectomy as the initial treatment, which has a survival advantage.^[1,22–23] Little information is available about the results of chemotherapy in patients with prostatic urothelial carcinoma. The current adjuvant chemotherapy regimens of prostatic urothelial carcinoma include doxorubicin, cyclophosphamide, and cisplatin substituted by gemcitabine and cisplatin.^[24–25] When the tumor is confined to the prostate tissue or pelvis, radiotherapy is also recommended.^[26,27]

4. Conclusion

Prostatic urothelial carcinoma is a very rare disease with high aggressiveness and poor prognosis. In middle-aged men with suspicious dysuria or a firm prostate, a diagnosis of prostatic urothelial carcinoma should always be considered. The gold standard to diagnose prostatic urothelial carcinoma is grounded in histologic and immunohistochemical analysis. Combined radical surgery with chemotherapy is recommended to manage the disease.

Author contributions

Investigation: Zhaoxiang Lu.

Methodology: Jun Zhou, Zhaoxiang Lu, Chaozhao Liang.

Resources: Jun Zhou.

Supervision: Cheng Yang, Sheng Tai.

Validation: Li Zhang, Yu Yin.

Writing – original draft: Zhaoxiang Lu.

Writing – review & editing: Chaozhao Liang.

References

- [1] Nicolaisen GS, Williams RD. Primary transitional cell carcinoma of prostate. *Urology* 1984;24:544–9.
- [2] Rubenstein AB, Rubnitz ME. Transitional cell carcinoma of the prostate. *Cancer* 1969;24:543–6.

- [3] Matzkin H, Soloway MS, Hardeman S. Transitional cell carcinoma of the prostate. *J Urol* 1991;146:1207–12.
- [4] Oliari BR, Kahane H, Epstein JI. A clinicopathologic analysis of urothelial carcinomas diagnosed on prostate needle biopsy. *Am J Surg Pathol* 2001;25:794–801.
- [5] Chuang AY, DeMarzo AM, Veltri RW, et al. Immunohistochemical differentiation of high-grade prostate carcinoma from urothelial carcinoma. *Am J Surg Pathol* 2007;31:1246–55.
- [6] Liang Y, Heitzman J, Kamat AM, et al. Differential expression of GATA-3 in urothelial carcinoma variants. *Hum Pathol* 2014;45:1466–72.
- [7] Chevillet JC, Dundore PA, Bostwick DG, et al. Transitional cell carcinoma of the prostate: clinicopathologic study of 50 cases. *Cancer* 1998;82:703–7.
- [8] Ende N, Woods L, Shelley H. Carcinoma originating in ducts surrounding the prostatic urethra. *Am J Clin Pathol* 1963;40:183–9.
- [9] Goebbels R, Amberger L, Wernert N, et al. Urothelial carcinoma of the prostate. *Appl Pathol* 1985;3:242–54.
- [10] Rhamy RK, Buchanan RD, Spalding MT. Intraductal carcinoma of the prostate gland. *J Urol* 1973;109:457–60.
- [11] Johnson DE, Hogan JM, Ayala AG. Transitional cell carcinoma of the prostate. A clinical morphological study. *Cancer* 1972;29:287–93.
- [12] Kirk D, Hinton CF, Shaldon C. Transitional cell carcinoma of the prostate. *Br J Urol* 1979;51:575–8.
- [13] Genega EM, Hutchinson B, Reuter VE, et al. Immunophenotype of high-grade prostatic adenocarcinoma and urothelial carcinoma. *Mod Pathol* 2000;13:1186–91.
- [14] Donat SM, Wei DC, McGuire MS, et al. The efficacy of transurethral biopsy for predicting the long-term clinical impact of prostatic invasive bladder cancer. *J Urol* 2001;165:1580–4.
- [15] Liedberg F, Chebil G, Mansson W. Urothelial carcinoma in the prostatic urethra and prostate. Current controversies. *Expert Rev Anticancer Ther* 2007;7:383–90.
- [16] Walsh DL, Chang SS. Dilemmas in the treatment of urothelial cancers of the prostate. *Urol Oncol* 2009;27:352–7.
- [17] Bretton PR, Herr HW, Whitmore WF Jr, et al. Intravesical bacillus Calmette-Guerin therapy for in situ transitional cell carcinoma involving the prostatic urethra. *J Urol* 1989;141:853–6.
- [18] Cui J, Wang W, Chen S, et al. Combination of intravesical chemotherapy and bacillus calmette-guerin versus bacillus calmette-guerin monotherapy in intermediate- and high-risk nonmuscle invasive bladder cancer: a systematic review and meta-analysis. *Medicine* 2016;95:e2572.
- [19] Hillyard RW Jr, Ladaga L, Schellhammer PF. Superficial transitional cell carcinoma of the bladder associated with mucosal involvement of the prostatic urethra: results of treatment with intravesical bacillus Calmette-Guerin. *J Urol* 1988;139:290–3.
- [20] Solsona E, Iborra I, Ricós JV, et al. The prostate involvement as prognostic factor in patients with superficial bladder cancer. *J Urol* 1995;154:1710–3.
- [21] Palou Redorta J, Schatteman P, Huguet Perez J, et al. Intravesical instillations with bacillus Calmette-Guérin for the treatment of carcinoma in situ involving prostatic ducts. *Eur Urol* 2006;49:834–8.
- [22] Sawczuk I, Tannenbaum M, Olsson CA, et al. Primary transitional cell carcinoma of prostatic periurethral ducts. *Urology* 1985;25:339–43.
- [23] Palou J, Daniel J, Klotz L, et al. Urothelial carcinoma of the prostate. *Urology* 2007;69(suppl 1):50–61.
- [24] Kohei N, Sugiyama K, Chihara I, et al. Impact of relative dose intensity in gemcitabine-cisplatin chemotherapy for metastatic urothelial carcinoma. *SAGE Open Med* 2018;6:2050312118783011.
- [25] Di Lorenzo G, Buonerba C, Bellelli T, et al. Third-line chemotherapy for metastatic urothelial cancer: a retrospective observational study. *Medicine* 2015;94:e2297.
- [26] Kirk D, Hinton CE, Shaldon C. Transitional cell carcinoma of the prostate. *Br J Urol* 1979;51:575–8.
- [27] Wolfe JH, Lloyd-Davies RW. The management of transitional cell carcinoma in the prostate. *Br J Urol* 1981;53:253–7.