



## Case report

## Cannulated cancellous screw fixation for the management of sustentaculum tali fracture: A case report

Arya Surya Pranata<sup>a,\*</sup>, Ketut Siki Kawiyanan<sup>a</sup>, Gusti Ngurah Wien Aryana<sup>a</sup>, Febyan<sup>b</sup><sup>a</sup> Department of Orthopaedics & Traumatology, Faculty of Medicine, Udayana University, Sanglah General Hospital, Denpasar, Bali, Indonesia<sup>b</sup> Department of Orthopaedics & Traumatology, Bhayangkara Denpasar Hospital, Bali, Indonesia

## ARTICLE INFO

## Keywords:

Sustentaculum tali  
Cannulated screw  
Fracture  
Rare site injury  
Case report

## ABSTRACT

**Introduction:** An isolated sustentaculum tali fracture is a rare manifestation of orthopaedic injury involving the supporting bone of the middle calcaneal facet. Globally, the incidence is estimated to be less than 1% of all calcaneus fractures.

**Presentation of case:** We reported a 42-year-old man with persistent ankle pain and instability on the right foot following a week after a motorcycle accident. The Computed tomography evaluation showed an avulsion of the medial sustentaculum tali on the right calcaneus bone. An open reduction and internal fixation procedure was performed using two cannulated cancellous screws applied across the lateral wall through the sustentaculum bone medially. The subjective postoperative evaluation showed that the patient responded well and gradually returned to daily routine activities without pain and instability.

**Discussion and conclusion:** Surgical approach using the cannulated cancellous screw to establish a firm fixation of sustentaculum tali fracture fragment into calcaneus bone and to prevent pathological movement.

## 1. Introduction

An isolated sustentaculum tali fracture is an extremely rare orthopaedic injury involving the supporting bone of the middle calcaneal facet [1]. Globally, the incidence is estimated to be less than 1% of all calcaneus fractures [2]. It is due to the surrounding tendons supporting the structure, which makes it the most stable part of the calcaneus [3].

The choice of the best surgical management approach for sustentaculum tali fractures remains controversial [1]. Moreover, improper management demonstrates the risk of causing long-term complications leading to permanent disability and disrupting the patients' quality of life [3]. Informed consent was obtained from the patient for publication of this case report and images for medical education purposes. The aim of the study is to discuss a successful surgical approach using cannulated cancellous screws presented with favorable post-operative outcome of a rare finding of sustentaculum tali fracture. This case has been reported in line the SCARE criteria [4].

## 2. Presentation of case

A 42-year-old man came to our clinic (In Sanglah General Hospital,

Denpasar, Indonesia. July 2021) with persistent ankle pain and instability on the right foot following a week after a motorcycle accident. He also could not actively perform plantar and dorsiflexion. There was no drug history or family history related. The physical examination revealed no local swelling; however, the patient seemed unable to walk and stand properly. Mild tenderness was present on the right foot, and the ankle range of motion was limited, with the loss in 10° inversion and 5° eversion at the subtalar joint compared to the contralateral joint. There was no functional motor loss noted. Complete blood count, bleeding time, clotting time results were within normal range.

The patient had received conservative treatment using a temporary functional brace and drug medications, including oral analgesic and muscle relaxant. However, the patient came back with unrelieved pain and instability. The patient obtained computed tomography (CT) imaging with three-dimension reconstruction. Computed tomography scan evaluation showed an avulsion of the medial sustentaculum tali on the right calcaneus bone (Fig. 1A, B). The diagnosis was confirmed as a sustentaculum tali fracture on the right foot.

The patient agreed to undergo an open reduction and internal fixation (ORIF) procedure under the C-arm guidance instrument to provide an accurate visualization during reduction and fixation. The patient was

\* Corresponding author.

E-mail address: [aryasuryapranatadr@gmail.com](mailto:aryasuryapranatadr@gmail.com) (A.S. Pranata).<https://doi.org/10.1016/j.ijscr.2021.106661>

Received 25 October 2021; Received in revised form 30 November 2021; Accepted 1 December 2021

Available online 6 December 2021

2210-2612/© 2021 The Authors. Published by Elsevier Ltd on behalf of IJS Publishing Group Ltd. This is an open access article under the CC BY-NC-ND license

<http://creativecommons.org/licenses/by-nc-nd/4.0/>.

prepared in a supine position, and general anesthesia with a tourniquet was applied surrounding the upper thigh. A medial incision was performed beginning over 2 cm distal to the tip of the medial malleolus and extending to the navicular tuberosity. Tibialis posterior tendon and flexor digitorum longus tendon were retracted and protected. After the fracture site of sustentaculum tali was clearly exposed, we performed a reduction and stabilization using two Kirschner-wires (Germany) which passed medially and repositioned the fracture fragment into its anatomical position under C-arm guidance, the procedure was performed by dr. I Gusti Ngurah Wien Aryana, Sp.OT-(K). After obtaining a satisfactory reduction, the final fixation was performed using two cannulated cancellous screws (USA) installed across the lateral wall through the sustentaculum bone medially. Reevaluation was established under C-arm, followed by injecting autologous plasma rich platelet (PRP) 4 cc in the fracture site (Fig. 2A, B). The patient underwent rehabilitation protocol using a functional brace and remained non-weight-bearing for at least four weeks.

The patient was encouraged for range-of-motion exercise starting two days postoperatively. After a month, the patient responded well (Visual analog scale was 2) and was able to perform full weight-bearing. On the 8-week follow-up, the scoring an American Orthopaedic Foot & Ankle Society (AOFAS) score of 90% (the score available: <https://ortho-toolkit.com>) The patient had returned to daily routine activities without any pain or instability.

### 3. Discussion

An isolated fracture of the sustentaculum tali is a rare injury [2]. Several theories exist on its mechanism, which is often associated with high-energy injury [1]. The rarity of this injury makes it the main obstacle in diagnosing and establishing a proper management approach [3]. Clinically, the symptoms of sustentaculum tali fractures include the local pain around the medial malleolus following a traumatic accident or falling from height [4]. Most patients also experience the loss of the ability to walk properly [5]. Tenderness, with or without ecchymosis, may be found in the medial malleolus on physical examination [5]. In

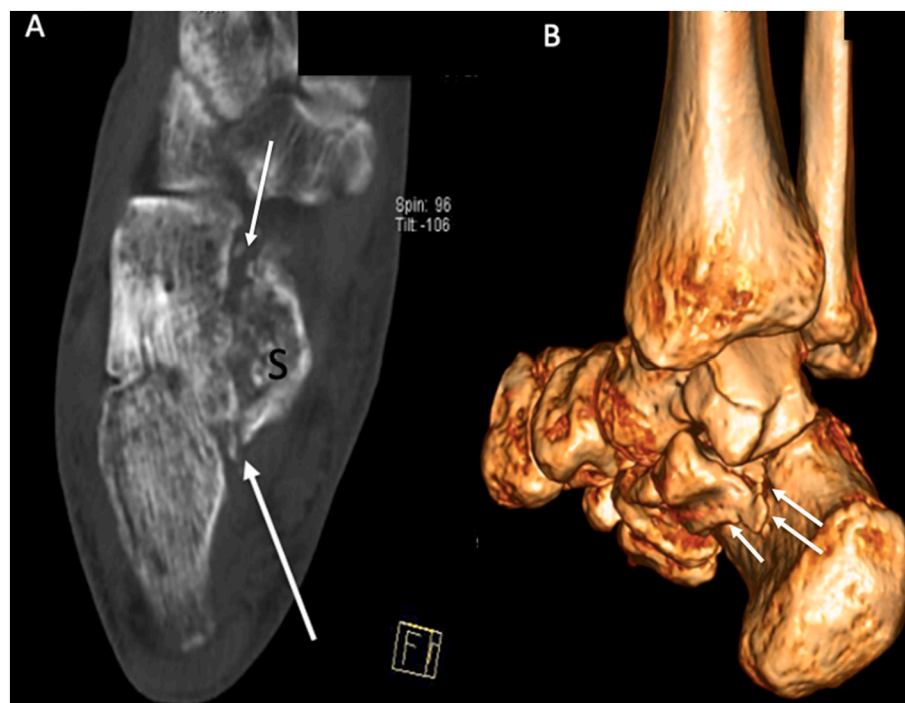
our particular case, the uncompromised instability might be related to the displacement fracture, with or without the complication of lateral or medial talocalcaneal ligament ruptures. A three-dimensional CT scan provides an excellent high-quality reconstructive image to facilitate the diagnostic evaluation of the structures. Magnetic resonance imaging is further suggested to identify the involvement of soft tissue injury [6].

The application of cannulated cancellous screw (USA) fixation using the medial approach is preferred because, theoretically, the lateral approach obstructs the fracture line by the intact calcaneal tuberosity [6]. This reason is supported by McReynolds, who first performed the medial approach for ORIF of sustentaculum tali fracture [7]. Furthermore, Durr et al. reported that this approach provides statistically significant differences in clinical outcome based on the mean AOFAS Ankle and Hindfoot scale. In addition, the medial approach allows a better direct visualization with the small incision, more restoration of the biomechanical function of the calcaneus, reduced the risk of post-traumatic arthritis, and a more reliable approach [8].

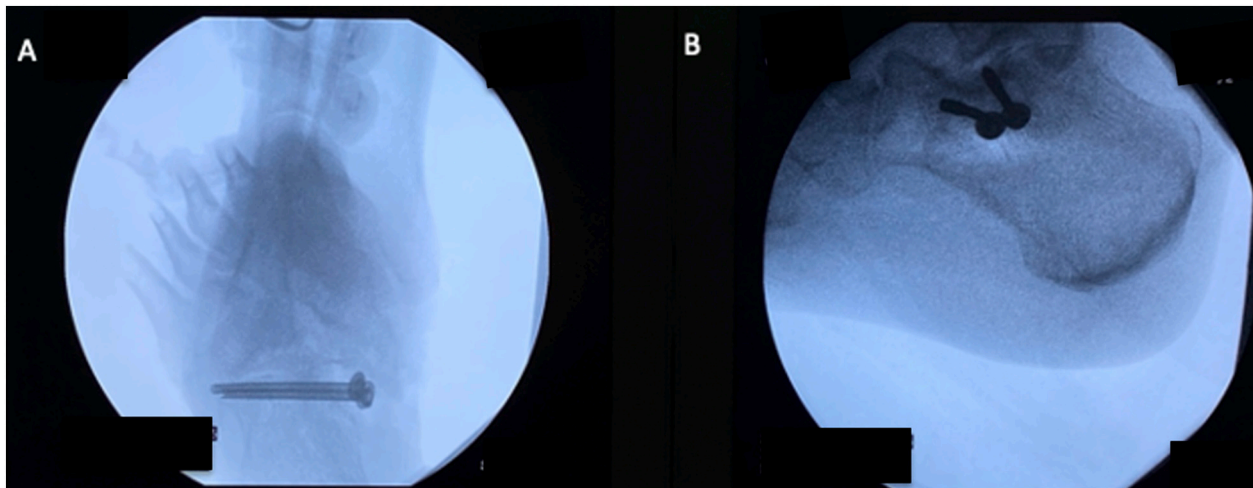
On the other hand, Gitajn et al. [9]. stated that the option of surgical approach, either using medial or lateral approaches, is often dependent on surgeon experiences with these approaches, as the indications for these approaches are still in limited literature [5]. However, they suggested using combined approaches, the medial approach for reducing tuberosity to the sustentacular fragment, followed by a lateral approach to reduce the posterior facet accurately [9].

In addition to the use of a cannulated screw, it must be applied at approximately 40 mm in length and should begin 15 mm below the posterior facet of subtalar joints to ensure a solid fixation of the fracture [10]. The use of screws is vital to replace the fracture fragments into an anatomical position, correct the Bohler angle and hind leg varus, and reduce the subtalar joint dislocation [11]. However, current comparative studies regarding the application of screw vs. plate showed no difference in biomechanical outcomes [12].

In our case, we also injected plasma rich platelet in the fracture site intraoperatively to achieve more satisfactory results. Wajdi et al. emphasized the use of plasma rich platelet to stimulate tissue regeneration and local freshness of non-union calcaneal fracture as benefits



**Fig. 1.** Axial view (a) and three-dimensional reconstruction ct scan (b) demonstrated an avulsion sustentaculum tali fracture (white arrows, “S” as sustentaculum) with the widening of the posterior articular facet of the right calcaneus (white arrows).



**Fig. 2.** Intraoperative of Harris and lateral c-arm radiography views (a and b) showed two cannulated cancellous screws fixated across the lateral wall through the sustentaculum tali part medially.

[13].

The complications of inadequate treatment for sustentaculum tali fractures can be divided into early and late complications. Tarsal tunnel syndrome and flexor hallucis longus tendon damage are the common early complications, while post-traumatic arthritis is often recognized as the late complication [14,15]. Hence, anatomical reduction and rigid fixation should be performed with open reduction and internal fixation (ORIF) considered the best management approach option. Surgical reduction of the fracture fragment increases the bone healing process and prevents these complications [15].

To the best of our knowledge, this patient is the first sustentaculum tali fracture patient in our institution and is also a unique case since the patient developed an fracture after a motorbike accident. The mechanism of injury in our case is related to high-energy axial loading. The patient was successfully managed by the orthopaedic surgeon and resulted in an excellent outcome. Ideally, the treatment requires a minimum 12-month follow-up duration. Nevertheless, further comparative study with a longer follow-up is needed for better establishment of surgical intervention choice.

#### 4. Conclusion

Our report provided a successful outcome of a medial surgical approach using the cannulated cancellous screw to establish a firm fixation of sustentaculum tali fracture fragment into calcaneus bone and to prevent pathological movement. Further prospective studies would likely be required to better compare outcomes in patients who sustain sustentacular tali fractures.

#### Source of funding

No funding was required in preparation of the manuscript.

#### Ethical approval

Ethical approval was no required in the management of the patients in this report.

#### Consent

Written informed consent was obtained from the patient for publication of this case report and accompanying images. A copy of the written consent is available for review by the Editor-in-Chief of this journal on request.

#### Research registration

Not applicable.

#### Guarantor

KSK and GNWA are the guarantors of the submitted article.

#### Provenance and peer review

Not commissioned, externally peer-reviewed.

#### CRedit authorship contribution statement

Author ASP and F contribute to the study concept or design, data collection, analysis, and writing the paper. Author KSK and GNWA contribute to the study concept or design, analysis and interpretation, mentorship external to the core team, and experts for the case and research activity planning including the execution of surgical treatment.

#### Declaration of competing interest

The authors declare that there is no conflict of interests.

#### References

- [1] A. Daftary, A.H. Haims, M.R. Baumgaertner, Fracture of the calcaneus: a review with emphasis on CT, *RadioGraphics* 25 (2005) 1215–1226.
- [2] J.M. Radley, D.A. Nicolaou, Bilateral isolated fracture of the sustentaculum tali, *JBJS Case Connect.* 9 (2) (2019) 1–5.
- [3] A. Razik, M. Harris, Trompeter, calcaneal fractures: where are we now? *Strat. Trauma Limb Reconstr.* 13 (2018) 1–11.
- [4] R.A. Agha, M.R. Borrelli, R. Farwana, K. Koshy, A. Fowler, D.P. Orgill, For the SCARE Group, The SCARE 2018 statement: updating consensus Surgical Case Report (SCARE) guidelines, *Int. J. Surg.* 60 (2018) 132–136.
- [5] G.J. Della Rocca, S.E. Nork, D.P. Barei, L.A. Taitzman, S.K. Benirschke, Fractures of the sustentaculum tali injury characteristics and surgical technique for reduction, *Foot Ankle Int.* 30 (11) (2009) 1037–1041.
- [6] F. Rao, Application of magnetic resonance imaging in evaluating ankle motion injury, *Rev. Bras. Med. Esporte* 27 (3) (2021) 253–256.
- [7] I.S. McReynolds, The case for operative treatment of fractures of the os calcis, in: R. E. Leach, F.T. Houglund, E.J. Riseborough (Eds.), *Controversies in Orthopaedic Surgery*, Philadelphia, Saunders, 1982.
- [8] C. Durr, H. Zwipp, S. Rammelt, Fracture of the sustentaculum tali, *Oper. Orthop. Traumatol.* 25 (2013) 569–578.
- [9] I.L. Gitajn, M. Abousayed, R.J. Toussaint, B. Ting, J. Jin, J.Y. Kwon, Anatomical alignment and integrity of the sustentaculum tali in intra-articular calcaneal fractures, *J. Bone Joint Surg. Am.* 96 (2014) 1000–1005.

- [10] P. Phisitkul, J.P. Sullivan, J.E. Goetz, J.L. Marsh, Maximizing safety in screw placement for posterior facet fixation in calcaneus fractures: a cadaveric radio-anatomical study, *Foot Ankle Int.* 34 (9) (2013) 1279–1285.
- [11] C.D. Basa, E. Sariyekiz, I.E. Kacmaz, A. Er, V. Zhamilov, A. Reisoglu, et al., Definition of sustentacular screw length based on computed tomography measurements for calcaneus intraarticular fracture surgery, *J DEU Med.* 34 (3) (2020) 203–207.
- [12] M.F. Qiang, R.K. Singh, Y.X. Chen, K. Zhang, X.Y. Jia, S. Chen, Computational biomechanical analysis of postoperative calcaneal fractures with different placement of the sustentaculum screw, *Orthop. Surg.* (2019) 1–7.
- [13] B. Wajdi, M.A. Rebai, W. Baya, N. Krid, W. Zribi, H. Keskes, Pseudarthrosis of the calcaneus: advantages of regenerative medicine in the management of a rare entity, a case report and review of the literature, *Open Orthop. J.* 12 (2018) 141–146.
- [14] H. Mu, X. Xiangyang, B. Gang, Isolated fractures of the sustentaculum tali: injury characteristics and surgical technique for reduction management, *J. Foot Ankle Surg. (Asia-Pacific)* 1 (2) (2014) 48–51.
- [15] P. Moonot, G. Sharma, A.R. Kadakia, Mal-union of sustentaculum tali fracture with talo-calcaneal coalition leading to tarsal tunnel syndrome: a case report, *Foot* (2021) 1–5.