



## Cone-beam computed tomography compared to X-ray in diagnosis of extremities bone fractures: A study of 198 cases

Prof. M. Ricci, M. Boldini\*, E. Bonfante, E. Sambugaro, E. Vecchini, G. Schenal, B. Magnan, S. Montemezzi

Università degli Studi di Verona, Verona 37100, Italy

### ARTICLE INFO

**Keywords:**  
Fractures  
CT  
Scaphoid

### ABSTRACT

CBCT is an imaging technique consisting of X-ray computed tomography, in which the x-rays are divergent, forming a cone.

During 2015, a new model of CBCT, New Tom 5G XL (Verona), was used in the Radiology Department of The University of Verona, in collaboration with the Orthopaedics Department. Our study was carried out from October 2015 to October 2016 (198 patients). We compared CBCT with standard x-ray in the diagnosis of foot and ankle fractures (and Lisfranc lesions), tibial plateau fractures, wrist and scaphoid fractures, elbow fractures.

All patients were analyzed, of which 143 were positive or had documented bone lesions, while 55 were with no fractures seen.

Of the 55 negative patients, 19 were considered positive at Standard RX, thus in 34.5% of cases the X-ray Standard examination overestimated the disease (false positive cases).

Similarly, of the 143 positive patients, 21 were negative at RX, resulting in 14.6% of false negatives.

We can say that if compared to standard X-ray, CBCT has higher sensitivity and specificity in the proper identification and typing of these kind of lesions, with low exposition dose if compared to MDCT.

The most common rx-unrecognized fractures were in small bones of carpus and tarsus.

### 1. Introduction

Cone Beam Computed Tomography (CBCT) has recently been described and adopted for extremities imaging in orthopaedics [1,2,7,8].

During 2015, a new model of CBCT, New Tom 5G XL (Verona), was used in the Radiology Department of The University of Verona, in collaboration with the Orthopaedics Department.

This was a development of the well-known cone-beam technology, more similar to a multi detector computed tomography (MDCT).

Indeed, while maintaining unchanged the technical characteristics, the pulsed emission of a cone beam x-ray and a flat panel detector system, it has a horizontal development with a 58 cm gantry and a table on which to place the patient.

Compared to previous models, it was possible to extend the field of application to the osteoarticular apparatus as well, mainly to orthopaedic field, in particular for the pre-operative planning of fractures as well as for post-surgical treatment evaluation, even in the presence of metal internal fixation systems (Fig. 1).

The purpose of the study is evaluating the efficacy of this new CBCT,

especially for the diagnosis of extremities small bone fractures, not easily diagnosed at the conventional X-Rays (Fig. 2).

CBCT is an imaging technique consisting of X-ray computed tomography, in which the x-rays are divergent, forming a cone.

As for MDCT, cone-beam CT is able to produce images in three dimensions, but the way to achieve this, however, is different. What remains practically unchanged is: the X-ray source, the presence of the gantry (in our case), the system of 360° rotation around the patient and a detection system opposed to the source on which the collimated beam is projected.

As a result of the acquisition of two-dimensional projection throughout the rotation, CBCT system generates a complete volumetric dataset with the patient stationary via a single rotation of the x-ray source and detector.

In contrast to CBCT, in MDCT, the patient moves forward through the scanner with the x-ray source and the detector continuously rotating around the gantry.

One of the problems we may encounter when we acquire metal objects, such as synthetic plates or intramedullar nails, is the presence

\* Corresponding author.

E-mail addresses: [matteo.boldini@gmail.com](mailto:matteo.boldini@gmail.com), [boldini.matteo@icloud.com](mailto:boldini.matteo@icloud.com) (M. Boldini).

<https://doi.org/10.1016/j.ejro.2019.01.009>

Received 7 October 2018; Received in revised form 28 January 2019; Accepted 29 January 2019

Available online 13 March 2019

2352-0477/ © 2019 The Authors. Published by Elsevier Ltd. This is an open access article under the CC BY-NC-ND license (<http://creativecommons.org/licenses/by-nc-nd/4.0/>).

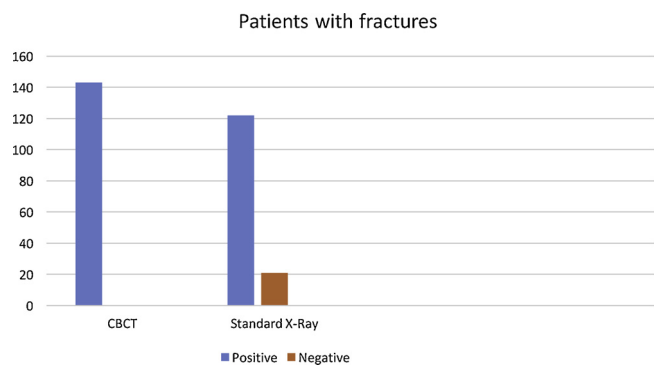


Fig. 1. Patients with fractures.

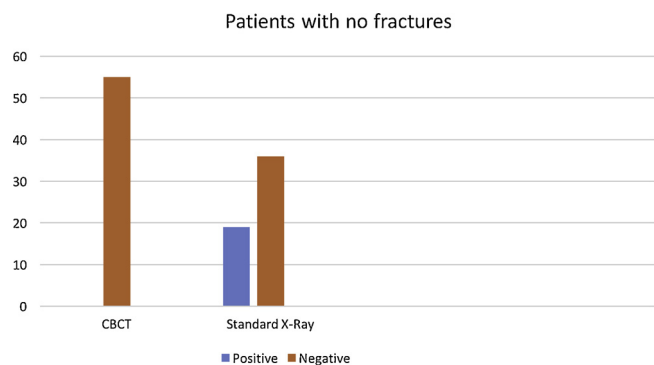


Fig. 2. Patients with no fractures.

of artifacts from the beam hardening.

However with CBCT this type of artifact is significantly reduced compared to MDCT. Recently artifacts reduction algorithms called MAR (Metal Artifact Reduction) have been introduced for the CBCT in order to further reduce these artifacts [3,4].

CBCT system can require up to 35 s (usually 18–26 s) for image acquisition (MDCT requires only 0,3 s). Other limitations of the procedure are the small gantry diameter and the difficult positioning of the patient.

CBCT software sorts the data into a multi-planer reconstruction which has three interactive views: the coronal (x–y axes), the sagittal (z–y axes), and the axial (x–z axes). Plane locator lines can be moved within each section, allowing scanning through the entire volume of information in the three planes. The scanning function allows for a rapid means of inspecting for gross anatomical variants and locating areas of interest useful in designing follow-up studies for more precise viewing.

CBCT imaging produces images with submillimeter isotropic voxel resolution ranging from 0.4 mm to as low as 0.076 mm. Because of this characteristic, subsequent secondary (axial, coronal, and sagittal) and multi-planar reformation (MPR) images achieve an accurate level of spatial resolution.

The data reported in the literature concerning the CBCT effective dose (ED) are about 12 times lower than the MDCT [5].

## 2. Material and methods

Our study was carried out from October 2015 to October 2016. We compared this technique with standard x-ray imaging, in the diagnosis of fractures of extremities bones : wrist, elbow, ankle, foot and knee (tibial plateau).

Our clinical records consist of 198 patients, of which 143 were positive or had documented bone lesions, while 55 were negative, i.e. free from traumatic pathology. We divided patients into four groups: in the first group we included symptomatic patients without evidence of

fracture on the x-ray image. The second group included patients with fractures visible on the imaging but without symptoms. The third group includes patients with fractures confirmed both on x-ray imaging and physical examination needing a surgical CT planning. The last group consists of patients who needed to be evaluated about the fracture reparative process (even if metallic fixation systems were present).

As we said before, we considered only few anatomical parts: wrist, elbow, knee, ankle and foot. This choice was based on an intrinsic limit of New Tom 5 G XL, the small gantry diameter (58 cm).

The large symmetrical joints such as shoulder and hip are unlikely to be positioned at the geometric center of the flat panel. The problem is not only determined by positioning errors, but also from anatomy and acquisition characteristics of the machine. The visualization of these districts is in any case affected by artifacts caused by adjacent structures that will add up to the district to be examined, thus resulting in lower quality images.

According to the district to examine, the patient can be placed supine or prone, on the bed or sitting. This is possible because in contrast to the MDCT, the bed is static.

In particular, for the acquisition of the wrist, the patient is sitting next to the gantry with the upper limb resting on the table, at the sensitive plan. It was observed that this position is much more convenient and easy, especially for elderly patients, if compared to the MDCT.

The study of the various anatomical areas was standardized, using the 15 x 12 cm FOV for the wrist, elbow, ankle and forefoot and the 18 x 16 cm FOV for the study of hand and knee. The thickness of reconstruction was 200  $\mu\text{m}$  except for the study of forefoot and knee that was 300  $\mu\text{m}$ .

As mentioned, the device allows to choose between three different modes of acquisition: 1) regular scan, used for the majority of examinations, a fair compromise between delivered dose and image quality; 2) Eco scan, in which the dose is reduced slightly sacrificing image quality, however, remaining acceptable and of diagnostic value (used especially in paediatrics); 3) Hi Res Scan, this mode is combined with a small FOV to get more detailed anatomic resolution up to 100 $\mu\text{m}$ .

All examinations were conducted with the Regular Scan mode except for patients under 20 years of age on which we preferred the Eco Scan Mode. For each test we also performed multi-planar reconstruction (MPR) and 3D volume rendering.

We conducted, in collaboration with the Medical Unit Physics of our hospital, a targeted dosimetric study, aimed at the joint field. We used Thermo Luminescence Dosimeters within mannequins called RANDO, that reproduces the human anatomy in density and size in order to detect single dose absorbed by organs, thus recovering the ED by the ICRP nr.103 of 2007 factors (International Commission on Radiological Protection) (Tab. 2) [6] containing the weight values for each organ.

The tests were carried out by simulating the following situation: a collaborating adult in sitting position and without protection for an exam in the arm with FOV 15 x 12 cm.

Preliminary results showed that, with a good approximation, the ED to the patient in one arm examination, taken as a reference, was significantly lower with CBCT compared to MDCT. The ED is found to be about 870 mSv for MDCT, while drops to about 40 mSv for CBCT, a data which is in any case distant from the ED of a standard radiography of the arm, of about 4 mSv.

Making a comparison between the absorbed doses for each organ we almost constantly found the ratio 1/23 (CBCT/MDCT).

## 3. Results

Our results consist of 55 negative patients, 19 of these were considered positive at Standard RX, thus in 34.5% of cases the X-ray Standard examination overestimated the disease (false positive cases).

Similarly, of the 143 positive patients, 21 were negative at RX,

resulting in 14.6% of false negatives.

#### 4. Discussion

Many imaging modalities have been used over the years to diagnose scaphoid fractures, from conventional X-rays to CT, bone scintigraphy and MR [10]. Common X-ray can often miss the diagnosis of an undisplaced scaphoid fracture in a patient with pain in the anatomical snuffbox (sensitivity 70–84%). 4 radiographs are usually needed, one AP view, one lateral, one radial oblique and one ulnar oblique view. MR is the most reliable imaging technique for occult scaphoid fractures, but it is often not easily accessible and available.

However, CT is the best tool to define a scaphoid fracture, allowing visualization of the well known “hump deformity” to be performed (with the proximal fragment moving above, and the distal below) [11].

X-rays have to be supported by CT even in tibial plateau fractures, for the correct and early diagnosis and for the surgical planning, when necessary.

Many authors have reported that initial Schatzker rankings and surgical plans based on plain radiographic findings have been modified after preoperative Computer Tomography (CT) or Magnetic Resonance (MR) imaging [13,14]. The correct diagnosis is fundamental to avoid complications of this kind of fracture.

The occult fracture is most often a not-displaced lateral tibial plateau fracture.

Even if in many cases CT findings mirror those of conventional x-ray, studies of tibial plateau fractures have shown that surgical plans based on radiographic findings are modified in 6%–60% of cases after CT [14]. The consequence is the change of surgical plans based on plain radiographic findings by more precisely demonstrating the fracture pattern, depression, and displacement [13,14]. Several articles illustrate that fracture depression and displacement are frequently misrepresented on plain radiographs, and CT usually provides more reliable information [12]; this is fundamental for a correct and early treatment.

In our study, CBCT was an important diagnostic instrument for foot lesions as well, such as fractures and Lisfranc injury.

The clinical evaluation has to be supported by radiographic examination. X-ray images in AP, lateral and oblique planes or stress test in same situations are not clarifying, leading to an inappropriate treatment. For instance, Vouri and Aro reported a series in which in 39% of the cases (59 patients) the diagnostic x-ray imaging was not early performed. If the plain radiographs are negative and the injury is still suspected, Computer Tomography can reveal occult fractures and may also be useful in formulating the surgical treatment plan.

If compared to X-ray, CBCT has higher sensitivity and specificity in the proper identification and typing of these kind of lesions, with low exposition dose if compared to MDCT.

In the analysis of 14.6% of Rx-unrecognized cases, it was observed that traumatic injury hit small bones of the carpus and tarsus and that, even at a retrospective reevaluation, lesions could not be identified on Standard Radiology.

It follows that the CBCT assumes a decisive role in the study of anatomical districts such as the wrist and the hind-foot as it is able to correctly identify traumatic pathology which would not be possible to identify in any case with radiography. This is due to the summation

effect, as occurs in the two-dimensional images of Conventional Radiology, which in the case of small bones, tend to overlap and can not be properly carried out, even through completion of oblique projections, as occurred in 14.6% of our Patients.

The presence of a plaster cast did not influence the evaluation of fracture, both in the most complex as in the small lamellar detachments, very difficult to view and to evaluate at Conventional Radiology controls with cast. The presence of a plaster cast has not affected the quality of both MPR and 3D reconstructions.

#### 5. Conclusions

After two years of use and 198 tests carried out in the orthopaedic field, we can make some considerations regarding the use of CBCT equipment in orthopaedics.

The use of CBCT technique for the study of fractures has been a winning choice since it allows the identification of small bones fractures, even when other imaging techniques are not able to highlight them. In addition, image quality is not affected by the presence of casts. Another considerable advantage is the low impact of internal metal synthesis systems on picture quality. This has enabled to evaluate the healing process accurately already during the treatment. The dosimetric aspect must not be forgotten. With CBCT we can produce very clear and detailed images using a low dosimetric impact mode.

Currently the main limit is due to the low temporal resolution of the detectors, but the continuous research and development by companies is actually trying to overcome this limitation.

#### References

- [1] J. De Cock, K. Mermuys, J. Goubau, et al., Cone-beam computed tomography: a new low dose, high resolution imaging technique of the wrist, presentation of three cases with technique, *Skeletal Radiol.* 41 (2012) 93–96.
- [2] J.A. Carrino, A. Al Muhit, W. Zbajewski, et al., Dedicated Cone-Beam CT System for Extremity Imaging, *Radiology* 270 (3) (2014) 816–824.
- [3] R. Molteni, Prospects and challenges of rendering tissue density in Hounsfield units for cone beam computed tomography, *Oral Surg. Oral Med. Oral Pathol. Oral Radiol.* 116 (2013) 105–119.
- [4] W.C. Scarfe, A.G. Farman, P. Sukovic, Clinical applications of cone-beam computed tomography in dental practice, *février, J Can Assoc* 72 (1) (2006) 75–80.
- [5] R. Pauwels, J. Beinsberger, B. Collaert, et al., Comparative dosimetry of dental CBCT devices and 64 slices CT for oral and maxillofacial radiology, *Eur. J. Radiol.* (2012).
- [6] Translation of ICRP Publication 103, “The 2007 Recommendations of the International Commission on Radiological Protection” by Comitato Internazionale AIRP, Milano, 27<sup>th</sup> June, (2008) ISBN 88-88648-08-9.
- [7] J.M. Ty, S. Lozano-Calderon, D. Ring, Computed tomography for triage of suspected scaphoid fractures, *HAND* 3 (2008) 155–158.
- [8] R. Edlund, M. Skorpil, G. Lapidus, et al., Cone-Beam CT in diagnosis of scaphoid fractures, *Skeletal Radiol.* 45 (2016) 197–204.
- [10] Y. Zhong-Gang, J.B. Zhang, et al., Diagnosing suspected scaphoid fractures, *Clin. Orthop. Relat. Res.* 468 (2010) 723–734.
- [11] Greenspan, Beltran: *Imaging ortopedico* (6th edition).
- [12] B.K. Markhardt, J.M. Gross, J. Monu, Schatzker classification of tibial plateau fractures; use of Ct and MR imaging improves assessment, *RSNA Radiographics* 29 (2) (2009).
- [13] P. Schnyden, R.A. Meuli, Comparison between standard radiography and spiral Ct with 3D reconstruction in the evolution, classification and management of tibial plateau fractures, *Eur. Radiol.* 10 (8) (2000) 1227–1232.
- [14] L. Macarini, M. Murrone, S. Marini, R. Calbi, M. Solarino, B. Moretti, Tibial plateau fractures. Evaluation with multidetector-CT, *Radiol. Med.* 108 (5-6) (2004) 503–514.