

Cite this article as: Heuts S, Sprooten RTM, Heines SJH, Mees BME. Mechanical ventilation variability due to tracheal compression in a patient with a mycotic descending aortic aneurysm: an inverse correlation with blood pressure. *Eur J Cardiothorac Surg* 2020;58:864–6.

# Mechanical ventilation variability due to tracheal compression in a patient with a mycotic descending aortic aneurysm: an inverse correlation with blood pressure

Samuel Heuts <sup>a,\*</sup>, Roy T.M. Sprooten<sup>b</sup>, Serge J.H. Heines <sup>c</sup> and Barend M.E. Mees<sup>d</sup>

<sup>a</sup> Department of Cardiothoracic Surgery, Maastricht University Medical Center, Maastricht, Netherlands

<sup>b</sup> Department of Respiratory Medicine, Maastricht University Medical Center, Maastricht, Netherlands

<sup>c</sup> Department of Intensive Care Medicine, Maastricht University Medical Center, Maastricht, Netherlands

<sup>d</sup> Department of Vascular Surgery, Maastricht University Medical Center, Maastricht, Netherlands

\* Corresponding author. Department of Cardiothoracic Surgery, Maastricht University Medical Center, P. Debyelaan 25, 6229 HX Maastricht, Netherlands. Tel: +31-43-3875073; fax: +31-43-3876543; e-mail: sam.heuts@mumc.nl (S. Heuts).

Received 17 December 2019; received in revised form 10 March 2020; accepted 17 March 2020

## Abstract

Mycotic aortic aneurysms carry significant morbidity and mortality. In the current report, we present a case of a patient with a mycotic descending aortic aneurysm with contained rupture causing variable compression of the trachea, influenced by a variability in blood pressure. In these patients, blood pressure management is paramount as relative hypertensive periods do not only increase the risk of rupture but can also warrant high ventilation pressures or can potentially result in airway occlusion.

**Keywords:** Aortic aneurysm • Mycotic aneurysm • Mechanical ventilation

## INTRODUCTION

First reported by Osler [1] in 1885, primary mycotic (or infected) aneurysms comprise 0.7–2.6% of all aneurysmal cases [2]. Patients often present with a variety in symptoms resulting in high morbidity and mortality rates, as mycotic aneurysms are associated with early rupture, sepsis and a paravisceral location. In the current report, we present a case of a patient with a mycotic descending aortic aneurysm causing variable compression of the trachea, influenced by a variability in blood pressure. Written informed consent was obtained prior to submission of the article.

## CASE REPORT

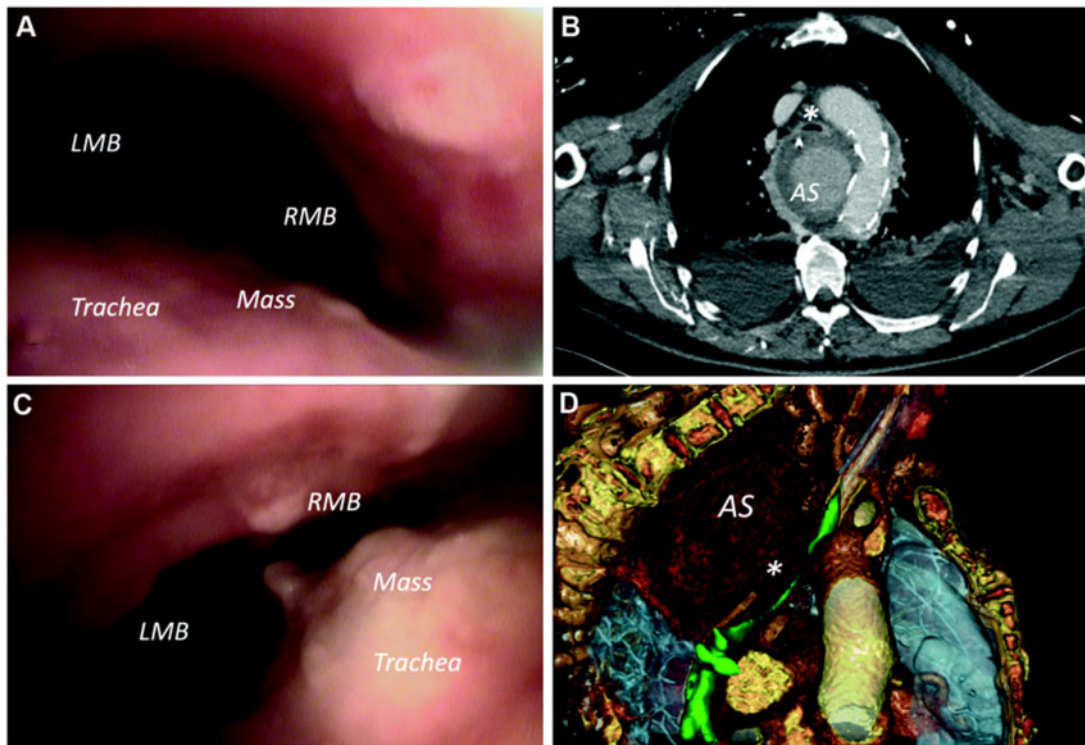
A 65-year-old male patient presented at our department with fever and thoracic pain. Contrast-enhanced computed tomography angiography revealed a descending aortic aneurysm with contained rupture, possibly mycotic in nature because of rapid growth, in close proximity to the trachea and oesophagus. Blood cultures were positive for *Staphylococcus aureus*, after which immediate antibiotic treatment was initiated. The patient was in poor haemodynamic condition and planned for urgent thoracic endovascular aortic repair (TEVAR, with the proximal landing zone distally of the left subclavian artery). After an initial uncomplicated recovery with early extubation, the patient developed

respiratory failure and was reintubated. Bronchoscopy revealed a nearly total extrinsic compression of the trachea by a pulsating mass (Fig. 1A and B; Video 1). Computed tomography angiography and additional 3-dimensional reconstruction showed tracheal compression by the aneurysmal sac (Fig. 1C and D; Video 2), without evidence of endoleak. The severity of compression on bronchoscopy varied and was to be related to a variability in blood pressure. From 16:29h onwards, we observed an inverse relation between tidal volume and blood pressure, with variation in tidal volumes between 354 and 806 ml, necessitating high ventilation pressures during hypertensive periods (Fig. 2).

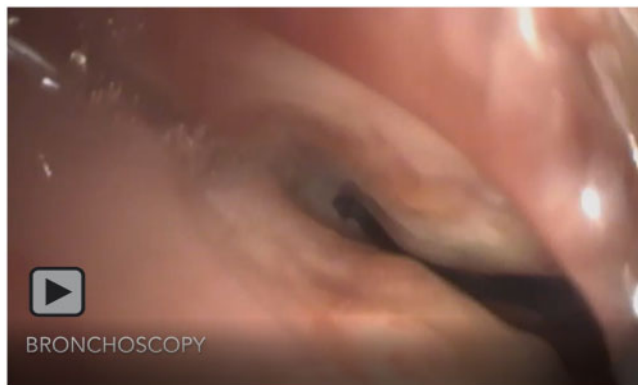
After nasogastric feeding was observed in the tracheal tube, administration of methylene blue confirmed the diagnosis of an oesophago-tracheal fistula. The patient was planned for evacuation of the aneurysmal sac to decompress the trachea and subsequent omentoplasty of the trachea and oesophagus through thoracotomy. Unfortunately, a tracheal defect of >4 cm and an oesophageal rupture of >4 cm were found on inspection after thoracotomy. As the stent was tangible through the aneurysmal sac, and therefore infected, the patient's prognosis was poor.

## DISCUSSION

Mycotic aortic aneurysm is a devastating disease with often lethal outcome. Recent reports have described in-hospital mortality

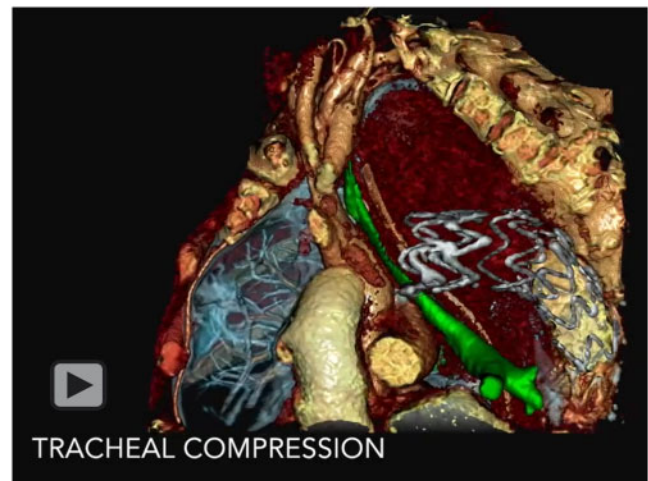


**Figure 1:** Diagnostic imaging. (A, B) Bronchoscopy revealing a pulsating mass with a variable compression of the tracheal lumen. (C, D) Thoracic computed tomography scan and anatomical 3-dimensional reconstruction demonstrating tracheal (green) compression (\*) by the AS. AS: aneurysmal sac; LMB: left main bronchus; RMB: right main bronchus.



**Video 1:** Bronchoscopy images. Bronchoscopy recording revealing a pulsating mass with a variable external compression of the tracheal lumen.

rates up to 55%, with risk factors for mortality being older age and infections by non-*Salmonella* species [3]. TEVAR has proven to be a feasible alternative to immediate open surgical repair, especially in patients in unstable haemodynamical conditions. In this setting, and especially in patients with non-*Salmonella* infections, endovascular repair may function as a bridge to open repair [4]. Besides exclusion of the aneurysm to prevent rupture, blood pressure management is paramount in this patient group as hypertensive periods significantly increase the risk of aneurysmal rupture. Although a previous animal study has described a causative relationship between increased tidal volumes and pulse pressure and stroke volume variation [5], the current report is the first to describe the influence of elevated blood pressures on tidal

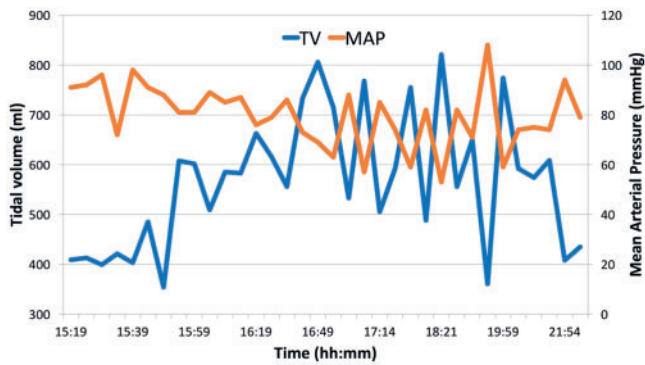


**Video 2:** Three-dimensional computed tomography reconstruction. Three-dimensional computed tomography reconstruction of the thoracic anatomy with the aneurysmal sac as cause of the tracheal (marked in green) compression.

volumes, due to a variable airway compression by the aneurysm of the descending aorta.

## CONCLUSION

Besides rapid endovascular or surgical intervention for mycotic aneurysms, blood pressure management is paramount as relative hypertensive periods do not only increase the risk of rupture but can also result in the need for high ventilation pressures.



**Figure 2:** Graph revealing the inverse relationship between tidal volume and blood pressure. MAP: mean arterial pressure; TV: tidal volume.

## ACKNOWLEDGEMENTS

We gratefully acknowledge Walther van Mook and Marvin Fillet (Vesalius 3D, PS-Medtech, Amsterdam, Netherlands) for the

realization of 3-dimensional anatomical computed tomography reconstructions.

**Conflict of interest:** none declared.

## REFERENCES

- [1] Osler W. The Gulstonian lectures, on malignant endocarditis. *Br Med J* 1885;1:577-9.
- [2] Oderich GS, Panneton JM, Bower TC, Cherry KJ Jr, Rowland CM, Noel AA *et al.* Infected aortic aneurysms: aggressive presentation, complicated early outcome, but durable results. *J Vasc Surg* 2001;34:900-8.
- [3] Hsu RB, Chen RJ, Wang SS, Chu SH. Infected aortic aneurysms: clinical outcome and risk factor analysis. *J Vasc Surg* 2004;40:30-5.
- [4] Sorelius K, Mani K, Bjorck M, Sedivy P, Wahlgren CM, Taylor P *et al.* Endovascular treatment of mycotic aortic aneurysms: a European multi-center study. *Circulation* 2014;130:2136-42.
- [5] Diaz F, Erranz B, Donoso A, Salomon T, Cruces P. Influence of tidal volume on pulse pressure variation and stroke volume variation during experimental intra-abdominal hypertension. *BMC Anesthesiol* 2015;15:127.