



**Case Report**

**Response to Interferon-Free Direct Antivirals (DAAS) Treatment in Hcv-Related Subcutaneous Marginal Zone B-Cell Lymphoma with Lipoma-Like Presentation: Report of Two Cases**

Maria Lucia De Luca<sup>1</sup>, Laura Lombardi<sup>2</sup>, Germana Tartaglia<sup>1</sup>, Francesca Fazio<sup>1</sup>, Alessio Di Prima<sup>1</sup>, Alessandra Serrao<sup>1</sup>, Martina Canichella<sup>1</sup> and Alessandro Pulsoni<sup>1</sup>.

<sup>1</sup> Division of Haematology, Department of Translational and Precision Medicine, Sapienza University of Rome, Italy.

<sup>2</sup> Service D'Hématologie, Hôpital Simone Veil, Troyes, France.

**Competing interests:** The authors have declared that no competing interests exist.

**Abstract.** Many epidemiological, biological and therapeutic studies have extensively investigated the etiological link between HCV infection and B-cell Non-Hodgkin Lymphoma (NHL). Large experiences in the literature demonstrated HCV-related indolent NHL regression after antiviral therapy. While the response to interferon-ribavirin-based antiviral therapy is well documented, evidence of the efficacy of interferon-free Direct-Acting Antivirals (DAAs) in this subset of lymphoma is also currently increasing. Splenic and Nodal Marginal zone Lymphoma (MZL) are frequently associated with HCV chronic infection. In this article we report two cases of HCV-related MZL with an unusual presentation, subcutaneous “lipoma-like” nodules, treated with DAAs. Both patients, a 59-years-old woman and a 72-years-old man, were affected by HCV chronic infection since several years and were referred to our Institute for a diagnosis of MZL with subcutaneous presentation. Given the possible etiological link with HCV infection, both patients were treated with DAAS.

A Sustained virological response (SVR) was reached after few weeks of therapy and at the end of treatment a clinically and radiologically documented reduction of MZL localizations, persisting to date, were obtained in both patients. The two clinical cases presented in this article confirm the efficacy of DAA's as first-line treatment in HCV related NHL, also in this rare entity of MZL with subcutaneous presentation.

**Keywords:** HCV, B-NHL, Lipoma-like Marginal Zone Lymphoma, Direct-acting antiviral (DAAs).

**Citation:** De Luca M.L., Lombardi L., Tartaglia G., Fazio F., Di Prima A., Serrao A., Canichella M., Pulsoni A. Response to interferon-free direct antivirals (DAAs) treatment in Hcv-related subcutaneous marginal zone b-cell lymphoma with lipoma-like presentation: report of two cases. *Mediterr J Hematol Infect Dis* 2019, 11(1): e2019053, DOI: <http://dx.doi.org/10.4084/MJHID.2019.053>

**Published:** September 1, 2019

**Received:** May 23, 2019

**Accepted:** August 10, 2019

This is an Open Access article distributed under the terms of the Creative Commons Attribution License (<https://creativecommons.org/licenses/by-nc/4.0>), which permits unrestricted use, distribution, and reproduction in any medium, provided the original work is properly cited.

Correspondence to: Prof. Alessandro Pulsoni. Tel.: +39 06 857951; Fax: +39 06 44241987. E-mail: [alessandro.pulsoni@uniroma1.it](mailto:alessandro.pulsoni@uniroma1.it)

**Introduction.** HCV infection affects over 180 million people all over the world and Italy is one of the countries with the highest prevalence (> 3%). The most common genotype in the world is genotype 1 (46% of global infections) followed by genotype 3 (22%) and genotype 2 and 4 (13% each).<sup>1</sup> Large evidences in literature suggest the association between chronic HCV infection and B-cell-non-Hodgkin's lymphomas (NHL). In 2003

Mele et al reported the incidence of 17.5% of NHL in HCV positive patients compared to the 5.6% of controls.<sup>2</sup> The most likely pathogenic mechanism of HCV-related NHL is the continuous chronic stimulation of lymphocytes receptors by viral antigens which may induce B cell proliferation and transformation in NHL.<sup>3</sup>

Marginal zone lymphoma (MZL) is a low-grade B-Cell Non-Hodgkin Lymphoma whose most frequent

presentations are extranodal MZL of mucosa-associated lymphoid tissue (MALT), splenic MZL and nodal MZL. It is frequently associated with an infectious etiology and among them, Hepatitis C virus infection is implicated especially in the pathogenesis of splenic and nodal MZL.<sup>4</sup>

Subcutaneous MZL is a rare presentation described in 2010 in 12 HCV chronically infected patients<sup>5</sup>. This disease is characterized by solitary or multiple nodular MZL lesions clinically resembling lipomas. No other similar cases were subsequently described in the literature.

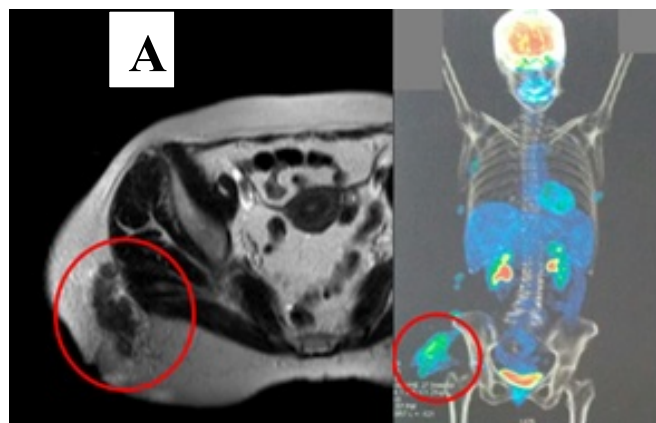
In the setting of HCV related lymphoproliferative disorders, the antigen removal by antiviral treatment represents the first-line therapeutic approach in indolent forms not requiring an immediate chemo-immunotherapy approach, achieving partial or complete regression of NHL.

Peg-Interferon + Ribavirin has been the standard treatment of HCV-related indolent lymphomas and many retrospective studies demonstrated B-NHL complete (CR) or partial (PR) response after HCV eradication. Meta-analysis data showed that lymphoma regression is related to the achievement of a complete HCV-RNA clearance. In a retrospective study promoted by Fondazione Italiana Linfomi (FIL), 100 patients with HCV-related NHL treated with Peg-Interferon + Ribavirin were studied, demonstrating a SVR rate of 80% with an overall hematological response rate of 77%.<sup>6</sup> The introduction of direct-acting antivirals (DAAs) has changed the treatment scenario for chronic HCV infection and extrahepatic manifestations. Isolated case reports and a retrospective collection of 46 cases demonstrated the possibility of complete or partial regression after DAAs therapy in HCV-related lymphoproliferative disorders.<sup>7</sup>

Here we describe two cases of response of subcutaneous MZL with lipoma-like presentation after DAAs treatment.

**Cases Presentation.** The first case concerns a 59-year-old woman affected by chronic HCV infection (genotype 1b) since 2007. In January 2008 the patient started alpha-Interferon therapy, suspended after 6 months for subclinical thyroiditis, obtaining a partial response of HCV infection. In May 2014 the patient developed right gluteus and right intercostal palpable soft nodules of 7 and 3 cm of diameter respectively. Ultrasound showed hypoechoic nodular lesions with intrinsic vascularization. A biopsy specimen of the right intercostal nodule revealed a subcutaneous MZL. The lymphoma cells were CD20+, CD5-, annexin 1-, BCL1-, BCL6-, CD10-, with low proliferative Ki67/MIB-1 index. The same histology was found in the bone marrow. MR and PET/CT scans showed multiple subcutaneous localizations in the right gluteus (SUV max 6, diameter 6 cm, **figure 1A**, and **1B**) and right

intercostal region (SUV max 4, diameter 4 cm) without any lymph node and/or splenic involvement. At the time of lymphoma's diagnosis, HCV-RNA was 346.143 UI/mL.



**Figure 1.** Subcutaneous soft nodular MZL lesion located in the right gluteus of patient n.1, seen at MR (A) and PET/TC (B).

Supposing an etiological link between HCV infection and MZL, even if in a rare presentation, the patient received DAAs treatment with sofosbuvir (400 mg/day) and ribavirin (1000 mg/day) for 24 weeks from November 2014. HCV-RNA decreased rapidly after only one month and during the treatment, a progressive clinical reduction of the palpable subcutaneous nodules was observed. Six months after the end of the antiviral treatment, PET/CT scan showed a reduced FDG uptake (SUV max 2.5) and size of MZL localizations described at the onset (right gluteus 4.5 cm, right intercostal region 1 cm) while HCV-RNA remained undetectable in the serum. After 22 months, the patient developed a new lesion of the right leg with a similar aspect (soft palpable subcutaneous lesion) but with inflammatory features (painful, with cutaneous warmth and redness). Unfortunately, a biopsy was not performed, but the lesion regressed after two weeks of oral steroid treatment. At present, the patient maintained the lymphoma's partial response (PR) with persistent small asymptomatic subcutaneous nodules 42 months after the end of DAAs treatment while in SVR and has never yet received specific treatment for MZL.

The second patient, a 72-year-old man, was affected by HCV infection since 1998 (genotype 2a/2c) but at that time he did not receive any treatment for HCV infection because of no evidence of active hepatitis. On November 2015 the patient presented multiple subcutaneous palpable nodular lesion in the left lumbar region (diameter 11 cm), in the right gluteus (diameter 1,4 cm), in the right leg (3,6 cm,) and in the left popliteal region (diameter 2,5 cm). On Ultrasound, these nodular lesions were described as hypoechoic with inhomogeneous echostructure and vascularization. A biopsy specimen on the right leg nodule documented a subcutaneous MZL. The lymphoma cells were CD20+,

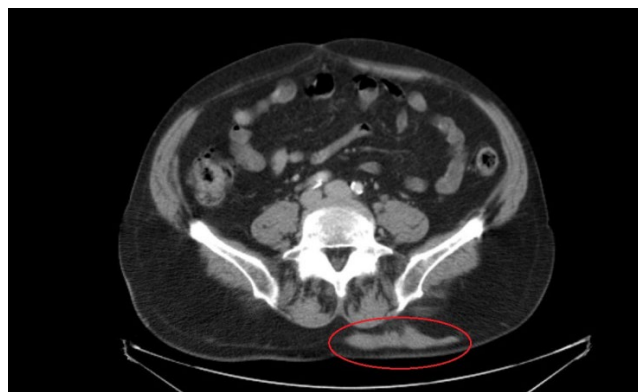
CD79+, BCL2, BCL6-/+ , CD10-, CD3-, CD5-, CD23-, cyclin D-, with a low ki67/MIB-1 index. Bone marrow histology did not document a lymphoma infiltration. When the patient was referred to our center, HCV-RNA was 1.263.000 UI/ml without signs or symptoms of liver cirrhosis. A CT scan documented the subcutaneous nodules (**Figure 2**) excluding any other involvement. The patient received treatment with sofosbuvir (400 mg/day) and ribavirin (1000 mg/day) for six months. On May 2016, the end therapy reevaluation showed SVR, and a partial response of the lymphoma with a >50% reduction of the nodules evaluated both clinically and by ultrasound and CT. Periodical imaging and blood tests confirmed the MZL PR in the absence of symptoms with persisting SVR after 30 months. At present, in both patients, a specific chemo-immunotherapy treatment was never performed while continuing a watch and wait policy.

Both patients signed informed consent to their data publication and collaborated in diagnostic imaging production.

**Discussion.** Our report describes two cases of HCV-related subcutaneous MZL with the lipoma-like presentation, a probably underdiagnosed entity.

Clinical presentation of subcutaneous MZL is similar to lipomas and therefore can be underestimated. Ultrasound characterization of lipomas is typical of benign solid masses: they appear well-circumscribed with variable echogenicity and absent or poor vascularization.<sup>8</sup>

In our two patients, nodular subcutaneous lesions,



**Figure 2.** CT scan showing MZL subcutaneous soft nodular lesion in the left lumbar region of patient n. 2.

even if clinically comparable to lipomas, showed dubious ultrasound features such as inhomogeneous echostructure and increased blood flow on color doppler.

Therefore, in the case of nodular lesions similar to lipomas, an ultrasound is mandatory to evaluate the presence of echographic characteristics of benignity. Any lesion with dubious ultrasound features must be investigated with HCV testing, second-level imaging, and histological characterization.

Although based on only two cases, our experience suggests that the use of DAAs is a valid first-line therapeutic approach also in this rare presentation of HCV related MZL, showing excellent tolerability as well as high and persistent anti-lymphoma effect. A chemo-immunotherapy approach should be only considered in case of the clinical need for immediate treatment or no response to DAAs.

## References:

- Gower E, Estes C, Blach S, Razavi-Shearer K, Razavi H. Global epidemiology and genotype distribution of the hepatitis C virus infection. *J Hepatol.* 2014 Nov;61(1 Suppl):S45-57  
<https://doi.org/10.1016/j.jhep.2014.07.027>  
PMid:25086286
- Mele A, Pulsoni A, Bianco E, Musto P, Szklo A, Sanpaolo MG, Iannitto E, De Renzo A, Martino B, Liso V, Andrizzi C, Pusterla S, Dore F, Maresca M, Rapicetta M, Marcucci F, Mandelli F, Franceschi S. Hepatitis C virus and B-cell non-Hodgkin lymphomas: an Italian multicenter case-control study. *Blood.* 2003 Aug 1;102(3):996-9  
<https://doi.org/10.1182/blood-2002-10-3230>  
PMid:12714514
- Peveling-Oberhag J, Arcaini L, Hansmann ML, Zeuzem S. Hepatitis C-associated B-cell non-Hodgkin lymphomas. Epidemiology, molecular signature and clinical management. *J Hepatol.* 2013 Jul;59(1):169-77  
<https://doi.org/10.1016/j.jhep.2013.03.018>  
PMid:23542089
- Perrone S, D'Elia GM, Annechini G, Pulsoni A. Infectious Aetiology of Marginal Zone Lymphoma and Role of Anti-Infective Therapy. *Mediterr J Hematol Infect Dis.* 2016 Jan 1;8(1):e2016006. doi: 10.4084/MJHID.2016.006  
<https://doi.org/10.4084/mjihid.2016.006>  
PMid:26740867 PMCID:PMC4696464
- Paulli M, Arcaini L, Lucioni M, Boveri E, Capello D, Passamonti F, Merli M, Rattotti S, Rossi D, Riboni R, Berti E, Magrini U, Bruno R, Gaidano G, Lazzarino M. Subcutaneous 'lipoma-like' B-cell lymphoma associated with HCV infection: a new presentation of primary extranodal marginal zone B-cell lymphoma of MALT. *Ann Oncol.* 2010 Jun;21(6):1189-95  
<https://doi.org/10.1093/annonc/mdp454>  
PMid:19858084
- Arcaini L, Vallisa D, Rattotti S, Ferretti VV, Ferreri AJ, Bernuzzi P, Merli M, Varettoni M, Chiappella A, Ambrosetti A, Tucci A, Rusconi C, Visco C, Spina M, Cabras G, Luminari S, Tucci M, Musto P, Ladetto M, Merli F, Stelitano C, d'Arco A, Rigacci L, Levis A, Rossi D, Spedini P, Mancuso S, Marino D, Bruno R, Baldini L, Pulsoni A. Antiviral treatment in patients with indolent B-cell lymphomas associated with HCV infection: a study of the Fondazione Italiana Linfomi. *Ann Oncol.* 2014 Jul;25(7):1404-10.  
<https://doi.org/10.1093/annonc/mdu166>  
PMid:24799461
- Arcaini L, Besson C, Frigeni M, Fontaine H, Goldaniga M, Casato M, Visentini M, Torres HA, Loustaud-Ratti V, Peveling-Oberhag J, Fabris P, Rossotti R, Zaja F, Rigacci L, Rattotti S, Bruno R, Merli M, Dorival C, Alric L, Jaccard A, Pol S, Carrat F, Ferretti VV, Visco C, Hermine O. Interferon-free antiviral treatment in B-cell lymphoproliferative disorders associated with hepatitis C virus infection. *Blood.* 2016 Nov 24;128(21):2527-2532.  
<https://doi.org/10.1182/blood-2016-05-714667>  
PMid:27605512
- DiDomenico P, Middleton W. Sonographic evaluation of palpable superficial masses. *Radiol Clin North Am.* 2014 Nov;52(6):1295-305. doi: 10.1016/j.rcl.2014.07.011. Epub 2014 Nov 4. Review. PubMed PMID: 25444107.  
<https://doi.org/10.1016/j.rcl.2014.07.011>  
PMid