

RESEARCH

Open Access



Correlating factors between vertebral fracture and fracture-associated intervertebral disc vacuum phenomenon after thoracolumbar fracture surgery: a single-centre retrospective study

Yao Fang^{1,2,3}, Yuchao Ye^{1,3}, Qing Wang^{1,3}, Sining Zhang^{1,3}, Guangfeng Ling¹, Kongning Chen¹, Hengmei Chen¹, Wugui Chen^{1*} and Chengzhao Liu^{1*}

Abstract

Study design A retrospective study.

Purpose Some studies have found the correlation between traumatic vertebral fractures and intervertebral disc vacuum phenomenon (IVP), but the study about relationship between thoracolumbar fractures and IVP at one year after fracture is lacking. Therefore, the purpose of this study was to analyze the prevalence of fracture-associated IVP (FAVP) in patients with thoracolumbar spine fracture at 1 year postoperatively and discover the related factors.

Methods This study included patients admitted to the spine surgery department of a university hospital from January 2016 to December 2021 after traumatic single-segment thoracolumbar fractures. IVP was categorized using computed tomography (CT), and the patient's gender, age, fracture type, trauma mechanism, 1-year postoperative outcome of the intravertebral shell phenomenon (ISP), degree of vertebral repositioning, and LSC score were recorded. The correlation between each factor and FAVP was analyzed by Pearson's Chi-square and Student's t test.

Results A total of 236 patients with traumatic single-segment thoracolumbar fractures were included in the study. All patients underwent CT scanning preoperatively, within 3 days postoperatively, and about 1 year postoperatively. 71 patients developed IVP at 1 year postoperatively, of which 47 had FAVP and 24 had degeneration-associated IVP (DAVP). There was a significant correlation between age and both FAVP or DAVP ($P < 0.05$). There was a significant correlation between fracture type, LSC score, trauma mechanism, and 1-year postoperative outcome after ISP and FAVP ($P < 0.05$).

*Correspondence:

Wugui Chen
wugui_chen@sina.com
Chengzhao Liu
andryliu@126.com

Full list of author information is available at the end of the article



© The Author(s) 2025. **Open Access** This article is licensed under a Creative Commons Attribution-NonCommercial-NoDerivatives 4.0 International License, which permits any non-commercial use, sharing, distribution and reproduction in any medium or format, as long as you give appropriate credit to the original author(s) and the source, provide a link to the Creative Commons licence, and indicate if you modified the licensed material. You do not have permission under this licence to share adapted material derived from this article or parts of it. The images or other third party material in this article are included in the article's Creative Commons licence, unless indicated otherwise in a credit line to the material. If material is not included in the article's Creative Commons licence and your intended use is not permitted by statutory regulation or exceeds the permitted use, you will need to obtain permission directly from the copyright holder. To view a copy of this licence, visit <http://creativecommons.org/licenses/by-nc-nd/4.0/>.

Conclusion Patients with thoracolumbar fractures have a higher incidence of postoperative FAVP. FAVP is more likely to occur in patients with an enlarged vertebral cavity 1 year after surgery for the ISP. FAVP needs to be taken into consideration when treating patients with high-energy trauma and older burst fractures.

Keywords Thoracolumbar fracture, Vacuum phenomenon, Disc degeneration, Associated factors, Computed tomography scanning

Background

Intervertebral vacuum phenomenon (IVP) was first described by Magnusson in 1937, referring to the radiologic manifestation of a gaseous collection in the intervertebral disc space at one or more spinal levels, most commonly in the lumbar spine region [1]. In 1942, Knutsson described the IVP as an indicator of disc degeneration, suggesting that intradiscal gas manifests in various tissue fissures, which typically signifies disc injury [2]. Therefore, IVP cannot exist in a normal healthy disc. However, IVP is not only occurred in degenerative diseases of the spine but also equally likely to happen after trauma to the spinal vertebrae resulting in vertebral collapse. Friederike Schömig [3] and Wang et al. [4] identified a higher incidence of intravertebral pressure (IVP) in thoracolumbar burst fractures, particularly in cases involving endplate injuries. Despite the discovery of IVP nearly a century ago and the extensive research on the association between post-traumatic vertebral fractures and IVP, the clinical implications of IVP concerning long-term bone non-healing following vertebral fracture surgery remain ambiguous.

In 1983, Denis first proposed the three-column theory of the spine and categorized spinal fractures into compression and burst fractures, laying a good foundation for the treatment of spinal fractures [5]. The subsequent more detailed AOSpine typing, TLICS score, and LSC score all play an important role in guiding the clinical management of spinal fractures. However, further research is needed on disc injuries due to spinal fractures. Previous studies have proposed that in patients with traumatic fractures of the thoracolumbar spine, based on MRI and MDCT, approximately 65–82% of patients have concomitant disc damage adjacent to the injured vertebrae [6, 7]. Even patients with osteoporotic vertebral fractures have an incidence of over 60% [8, 9]. These traumas may accelerate disc degeneration, leading to symptoms such as spinal instability and chronic back pain [10–12]. The results of the study by Fang et al. [13] showed that about 37.4% of the patients had enlargement of the vertebral cavity or vertebral collapse, and appeared to present with IVP of the adjacent discs. Since disc injury affects the overall stability of the spine, it is critical to understand the relationship between postoperative fracture-associated IVP (FAVP) and traumatic vertebral fracture for the treatment of patients. The aim of this study is to understand the incidence of FAVP and to

analyse the relevant factors influencing FAVP and degenerative IVP(DAVP) by analysing the case and imaging data of patients with thoracolumbar vertebral fractures, in order to provide valuable guidance to clinicians in the management of such patients.

Materials and methods

Study population

This retrospective study included patients admitted to the Department of Spine Surgery of a university hospital from January 2016 to December 2021 after surgery for traumatic thoracolumbar fractures. All included patients underwent preoperative and postoperative CT scans, and all were reviewed with CT scans at 1 year postoperatively. Inclusion criteria: (1) Denis classification of compression or burst single-segment thoracolumbar (T11–L2) fracture [5]; (2) Postoperative CT scan suggesting injured vertebrae with ISP. Exclusion criteria: 1. inadequate imaging; 2. pathologic fracture (i.e., known osteoporosis or malignant disease). A total of 237 patients were enrolled in the study. Surgical methods included 165 cases of percutaneous repositioning pedicle screw internal fixation and 72 cases of incisional repositioning pedicle screw internal fixation. The study protocol was reviewed and approved by the Hospital Ethics Committee.

Observed indicators

The cases of the included patients were reviewed and the gender, age and trauma mechanism of the patients were collected. Taking into account previous studies [15] and the German guidelines for the treatment of patients with serious injuries [16], we classified the trauma mechanism into a total of 2 categories: 1. Low-energy trauma: falls from less than 3 m and falls from standing height; 2. High-energy trauma: falls from more than 3 m and traffic accidents.

Imaging indicators

According to Denis fracture typing, we classified preoperative CT scan fracture types into compression and burst fractures [5]. Based on previous studies [3] and a novel IVP classification method developed by Gaston Camino Willhuber et al. [17], we defined IVPs adjacent to the cephalad or caudal end of the fractured vertebrae as FAVP and the remaining IVPs as DAVP (Fig. 1). Based on the findings of Fang et al., we defined ISP as the first postoperative CT scan of the injured vertebrae with an

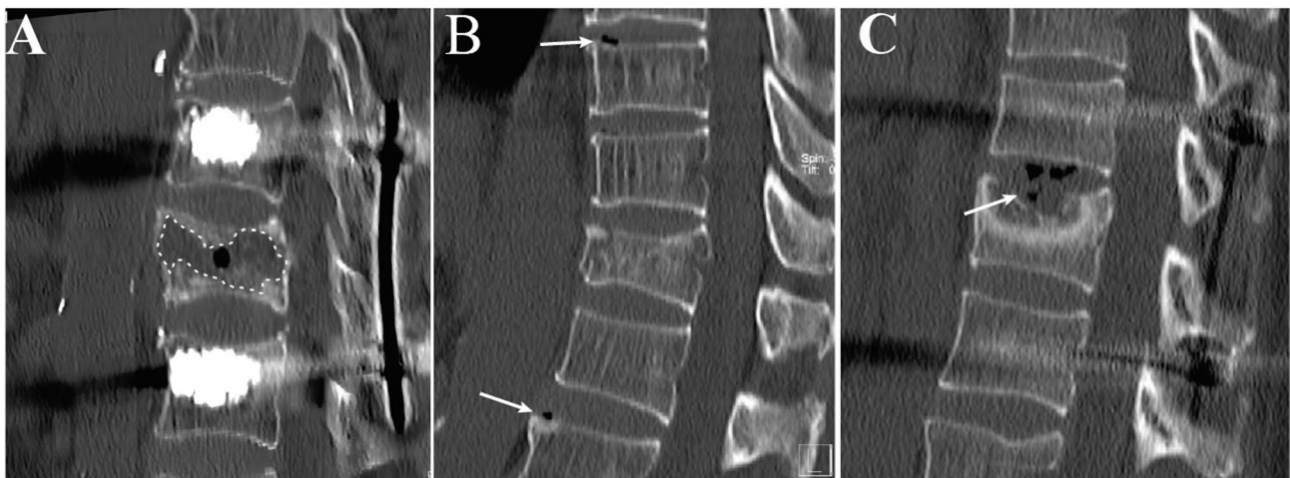


Fig. 1 Schematic diagram of IVP and ISP. (A) The dashed area in the figure is the ISP. (B) The low-density region shown by the arrow is DAVP. (C) The low-density region shown by the arrow is FAVP

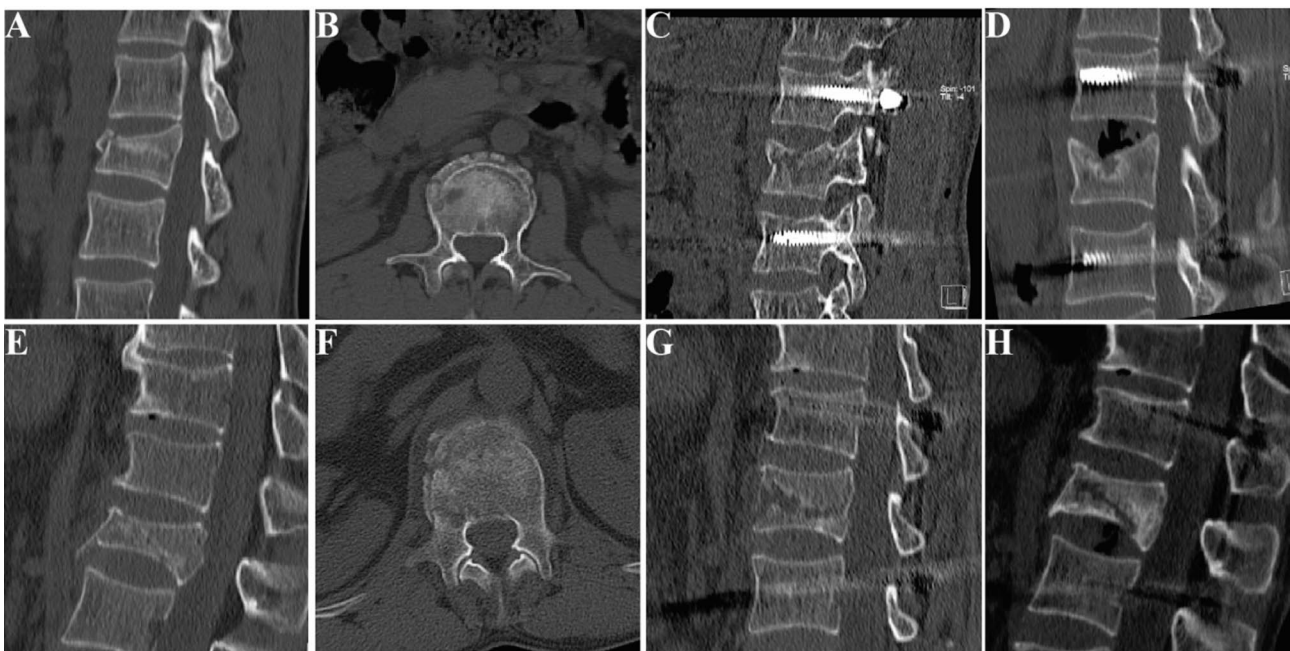


Fig. 2 Schematic diagram of 1-year postoperative outcomes of ISP. From left to right, preoperative sagittal CT, preoperative horizontal CT, first postoperative sagittal CT, and second postoperative CT. (A)(B)(C)(D) Cavity shrinkage. Male, 34 years, traffic accident, burst fracture type B, LSC 7 points, the second follow-up CT at 13 months postoperatively suggested cavity shrinkage but with FAVP. (E)(F)(G)(H) Male, 56 years, falls from > 3 m, burst fracture type C, LSC 6 points, the second follow-up CT at 13 months postoperatively suggested cavity enlargement but with FAVP

eggshell hypodense shadow, and defined outcomes after 1 year of ISP as 2 categories: 1. reduced volume or complete healing of the vertebral body cavity, 2. expansion of the vertebral body cavity with invasion of the adjacent endplate, resulting in endplate collapse and disc invagination (Fig. 2). The effect of fracture comminution on IVP was evaluated using the Load sharing classification (LSC) for thoracolumbar fractures proposed by McCormack et al. in 1994 [18]. Degree of vertebral body repositioning: The height of the injured vertebra was

taken as the average of the sum of the heights of the adjacent upper and lower vertebrae and considered excellent when > 80%; and poor, < 80%. We involved three independent and unbiased clinicians with substantial clinical experience in the collection of imaging data.

Statistical methods

All statistical analyses were performed using SPSS statistical software (version 27.0; IBM Corporation, Armonk, NY). *P* values less than 0.05 were considered to indicate

Table 1 Fracture types, patient characteristics and FAVP distribution

Fracture type	Fracture subtype	Patients (n)	Ages (years, mean ± SD)	LSC (score, mean ± SD)	FAVP (n)
Compression Fractures	A	15 (6.4%)	59.47 ± 8.37	5.53 ± 2.42	0 (0%)
	B	24 (10.2%)	59.63 ± 15.38	5.54 ± 2.36	3 (6.4%)
	C	11 (4.7%)	57.78 ± 6.65	5.27 ± 2.24	2 (4.3%)
	D	29 (12.3%)	59.52 ± 11.12	4.48 ± 2.29	3 (6.4%)
Burst Fractures	A	52 (22.0%)	60.58 ± 8.76	6.19 ± 1.41	13 (27.7%)
	B	70 (29.7%)	59.37 ± 9.39	5.91 ± 1.44	17 (36.2%)
	C	21 (8.9%)	61.52 ± 8.80	6.24 ± 1.41	6 (12.8%)
	D	12 (5.1%)	63.75 ± 8.92	6.42 ± 1.51	2 (4.3%)
	E	2 (0.8%)	45.00 ± 4.24	8.50 ± 0.71	1 (2.1%)

SD= standard deviation;

FAVP= Fracture-associated intervertebral vacuum phenomenon

LSC= Load sharing classification

Table 2 Trauma mechanism, patient characteristics and FAVP distribution

Type of trauma	Trauma mechanism	Patients (n)	Ages(years, mean ± SD)	LSC (score, mean ± SD)	FAVP (n)
Low-energy trauma	Fall from < 3 m	22 (9.3%)	62.14 ± 11.76	5.59 ± 2.09	7 (14.9%)
	Fall from standing height	86 (36.4%)	58.73 ± 9.56	5.60 ± 1.60	8 (17.0%)
High-energy trauma	Fall from > 3 m	76 (32.2%)	62.43 ± 7.84	6.13 ± 1.88	26 (55.3%)
	Traffic accidents	52 (22.0%)	58.19 ± 11.65	6.03 ± 1.70	6 (12.8%)

SD= standard deviation

FAVP= fracture-associated intervertebral vacuum phenomenon

LSC= Load sharing classification

statistical significance. Student’s t test was used to analyze the correlation between age, LSC and IVP. Pearson’s Chi-square was used to analyze the correlation between gender, trauma mechanism, 1-year postoperative ISP outcome, fracture type and IVP. In light of the potential for surgical methodology to act as a confounding factor, it was deemed inappropriate to incorporate it as an analytical factor within the statistical analyses.

Results

General information

A total of 237 postoperative thoracolumbar fracture patients were included in the study, of which 95 were males and 141 were females. The mean age was 58.37 years (58.37 ± 10.81 years). The time to the first postoperative review CT scan was 2.05 days (2.05 ± 0.84 days), and all patients completed the second CT scan at a mean of 341.76 days (356.89 ± 62.38 days) postoperatively. The injured vertebrae with 237 fractures were T11 in 3 cases, T12 in 57 cases, L1 in 124 cases, and L2 in 52 cases. There were 79 compression fractures and 157 burst fractures. Subtypes of compression fractures were categorized as 15 type A, 24 type B, 11 type C, and 29 type D fractures; subtypes of burst fractures were categorized as 52 type A, 70 type B, 21 type C, 12 type D, and 2 type E fractures (Table 1). Among the trauma mechanism, the total number of patients with low-energy trauma was 108, including 86 cases of falling from a standing height and 22 cases of falling from a height of less than 3 m. The total number of patients with high-energy trauma was 128, including

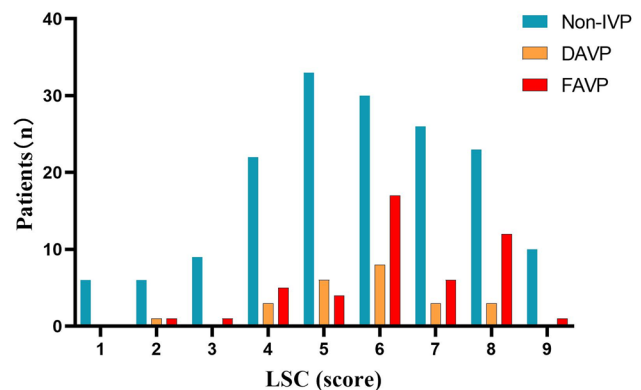


Fig. 3 Distribution of IVP in patients with each LSC score

52 cases of traffic accidents and 76 cases of falling from a height of more than 3 m (Table 2). The total number of patients with excellent postoperative vertebral repositioning of thoracolumbar fractures was 161, and the total number of patients with poor repositioning was 75. The mean LSC for the injured vertebrae was 5.31 scores (5.31 ± 2.39 scores) (Fig. 3).

Correlation of IVP with age and gender

A total of 71 of the 236 patients had IVP in the adjacent discs of the fractured vertebrae, including 47 FAVP and 24 DAVP. Analysis of the relationship between the fractured vertebrae and the two IVPs in all patients showed a significant difference between age and DAVP (P<0.001), and a similarly significant difference between age and

FAVP ($P=0.017$) (Fig. 4). However, there was no significant correlation between either DAVP ($P=0.429$) or FAVP ($P=0.665$) and gender (Fig. 5).

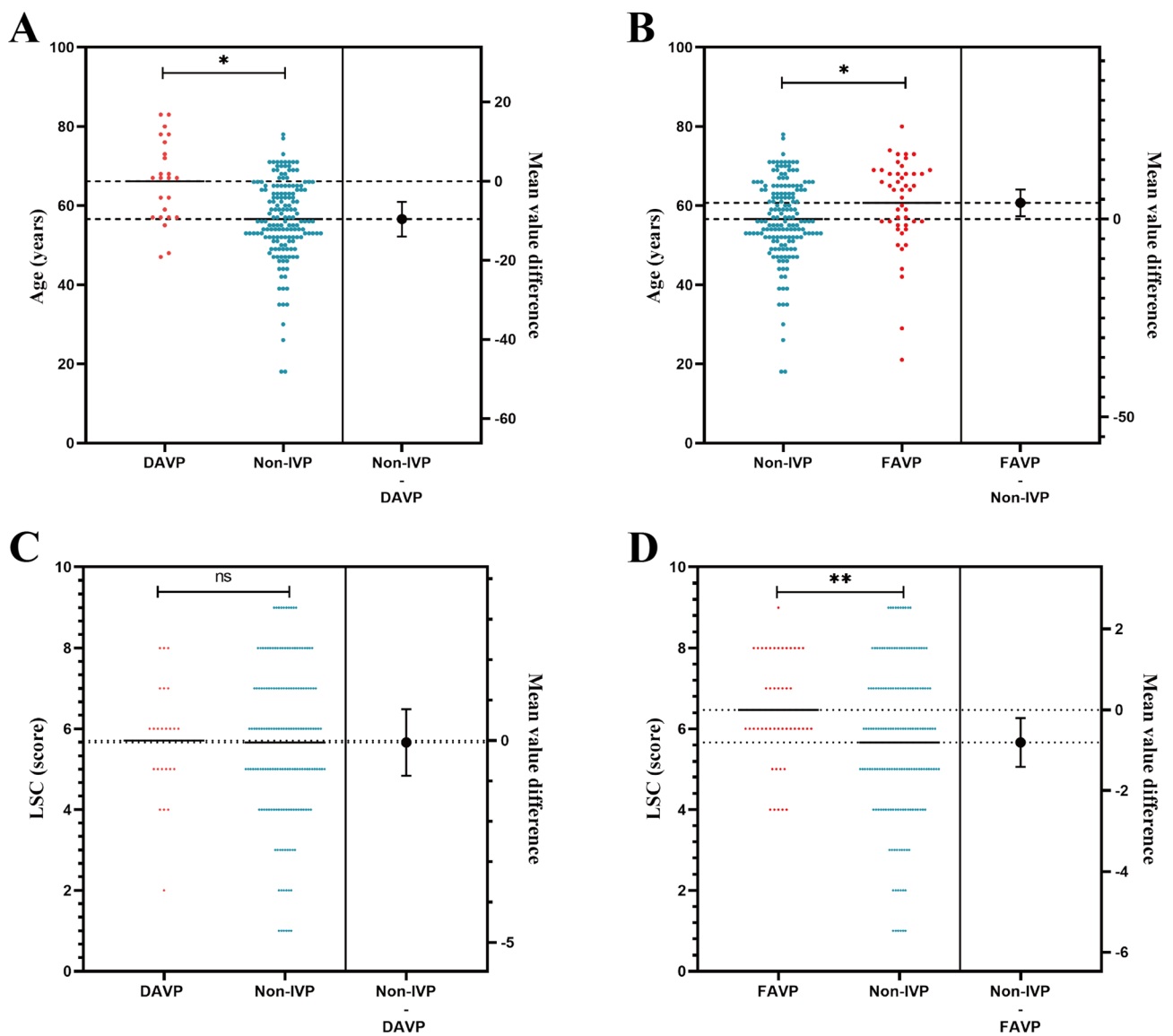
Correlation between IVP and trauma mechanism

There was a significant correlation between FAVP and the trauma mechanism ($P=0.026$) and no significant correlation between DAVP and the trauma mechanism ($P=0.429$) (Fig. 5). Among all the fracture patients, a total of 128 patients belonged to high-energy trauma, including 35 (25.1%) patients with FAVP, and 108 (45.7%)

patients belonged to low-energy trauma, including 15 (13.8%) patients with FAVP (Table 2).

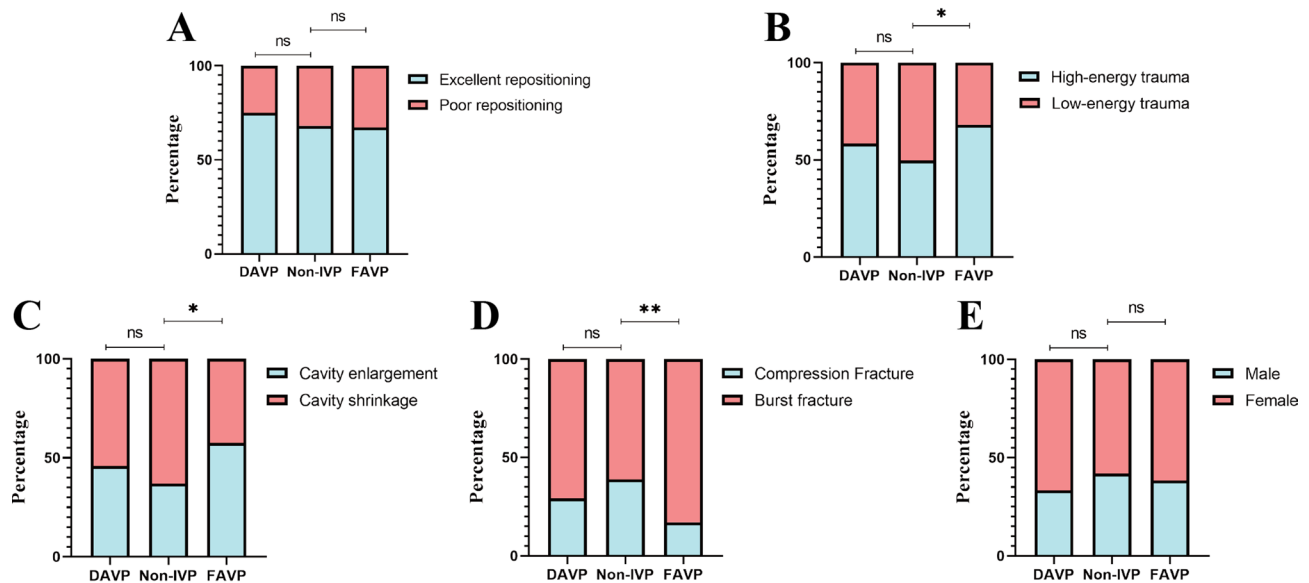
Correlation between IVP and 1-year postoperative ISP outcomes

There was a significant correlation between FAVP and 1-year postoperative ISP outcomes ($P=0.018$) and no significant correlation between DAVP and 1-year postoperative ISP outcomes ($P=0.500$) (Fig. 5). Among all fracture patients, a total of 99 patients (41.9%) had an ISP cavity enlargement and 137 patients (58.1%) had an ISP cavity reduction on the second postoperative review CT results.



* Indicates comparison between the two groups $P < 0.05$;
 * *Indicates comparison between the two groups $P < 0.01$;
 ns Indicates comparison between the two groups not significant.

Fig. 4 Student's t test results. (A) Significant correlation between DAVP and age. (B) Significant correlation between FAVP and age. (C) No significant correlation between DAVP and LSC. (D) Significant correlation between LSC and FAVP



* Indicates comparison between the two groups $P < 0.05$;
 * *Indicates comparison between the two groups $P < 0.01$;
 ns Indicates comparison between the two groups not significant.

Fig. 5 Pearson's Chi-square results (A) There was no significant correlation between the degree of vertebral repositioning and either FAVP or DAVP. (B) Significant correlation between trauma mechanism and FAVP, and no significant correlation with DAVP. (C) Significant correlation between the vertebral cavity and FAVP, and no significant correlation with DAVP. (D) Significant correlation between fracture type and FAVP, and no significant correlation with DAVP. (E) No significant correlation was found between sex and either FAVP or DAVP

Table 3 ISP 1-year postoperative outcomes, patient characteristics, and FAVP distribution

1-year post-operative ISP outcomes	Patients (n)	Ages (years, mean \pm SD)	LSC (score, mean \pm SD)	FAVP (n)
Cavity shrinkage	137(58%)	59.60 \pm 9.14	5.74 \pm 1.90	20(42.6%)
Cavity enlargement	99(42%)	60.85 \pm 10.89	5.81 \pm 1.83	27(57.4%)

SD=standard deviation

FAVP=fracture-associated intervertebral vacuum phenomenon

LSC=Load sharing classification

A total of 27 patients (57.4%) with an ISP cavity enlargement developed FAVP; a total of 20 patients (42.6%) with an ISP cavity shrinkage developed FAVP (Table 3).

Correlation between IVP and fracture type or LSC

Of all the fractured patients included, L1 fractures ($n = 124$, 52.5%) were the most common, followed by T12 fractures ($n = 57$, 24.1%) and L2 fractures ($n = 52$, 22%), and the least common was T11 fractures ($n = 3$, 1.2%). There was a significant correlation between fracture type and FAVP ($P = 0.005$), whereas there was no significant correlation between DAVP and fracture type ($P = 0.363$) (Fig. 5).

There was a significant correlation between fracture type and FAVP ($P = 0.005$) and no significant correlation with DAVP ($P = 0.363$) (Figure. 3). Among patients with FAVP, there were 39 (82.9%) burst fractures with

categorized subtypes including 13 type A, 20 type B, 8 type C, 5 type D, and 1 type E fractures; and 8 (17.1%) compression fractures with categorized subtypes including 0 type A, 3 type B, 2 type C, and 3 type D fractures (Table 1).

For the assessment of LSC for vertebral fracture comminution, there was a significant correlation between FAVP and LSC ($P = 0.009$), whereas there was no significant correlation between DAVP and LSC ($P = 0.176$) (Fig. 4).

Correlation between IVP and degree of vertebral repositioning

There was no significant difference between the degree of repositioning of the fractured vertebrae and either FAVP ($P = 0.672$) or DAVP ($P = 0.701$) (Fig. 5).

Discussion

In this study, there was a strong correlation between age and IVP, both DAVP and FAVP. After a fracture occurs in the vertebral body, especially with endplate damage, it will reduce the blood supply to the neighboring discs and accelerate disc degeneration [19]. Takeshi Sasagawa et al. [20] collected data on 94 intervertebral discs on the cephalad and caudal sides of 47 fractured vertebrae in 45 patients with traumatic thoracolumbar spine fractures due to high-energy injuries, and showed that cephalad and endplate fractures of the vertebral body

were independent risk factors for IVP. In this study, the mean age of the included patients was 58.37 years, and the overall prevalence of IVP was 30.1%, with FAVP being 19.9%, so IVP is not uncommon in older patients, and trauma to the vertebral body and intervertebral discs can increase its incidence.

There is no consensus on the best treatment for patients with thoracolumbar fractures without neurologic symptoms. However, in both conservative and surgical treatments, clinicians have paid little attention to the injury to the disc adjacent to the fracture and have not treated the injured disc appropriately. Previous studies [21, 22] have found that in traumatic thoracolumbar fractures, the presence of concomitant disc injury or IVP can lead to the development of kyphosis. Typically, traumatic forces in the spine are directed from top to bottom, with mechanical stresses being greater at the upper end of the vertebrae. This means that the cephalad end of the vertebrae will be more susceptible to fracture and endplate injuries at the cephalad end are also more likely to occur. In 2013, wang et al. [4] studied 26 patients with single-segment A3 thoracolumbar fractures and found a strong correlation between cephalad endplate fracture and disc degeneration, and concluded that disruption of the endplate trophic pathway was also associated with disc degeneration. There are also other studies that have found disc degeneration to be readily present in vertebral burst fractures [22]. Our study results showed a significant correlation between fracture type and FAVP, which was more likely to occur in patients with burst fractures. The overall data suggest that Type B is most common in patients with FAVP, followed by Type A and Type C, in both burst and compression fractures. All three subtypes of fractures were accompanied by fractures of the endplate, which is consistent with previous studies. In addition, we applied LSC for assessing the degree of comminution of the fractured vertebrae as well as the degree of discrete fracture fragments, and the results showed a significant correlation between LSC and FAVP, and the higher the score of LSC, the higher the frequency of FAVP.

The current conventional surgical treatment for thoracolumbar fractures usually involves internal fixation of the fracture using a pedicle screw-rod system, which maintains the overall stability of the spine and provides for healing of the injured vertebrae. However according to the study of Fang et al. [13], nearly 80% of the patients with thoracolumbar spine fracture had different degrees of ISP after posterior reduction and internal fixation, and the review of CT at 1 year after the surgery showed that the vertebral cavity was enlarged in 37.4% of the patients. The essence of ISP is the area of substantial hypodense bone defects observed on CT scans. After the vertebral body has been traumatized, the trabeculae within

the vertebral body are disarranged or even broken, and are unable to support the vertebral body; and the fracture fragments are discrete and the vertebral body is severely fragmented, making it difficult for the vertebral body to heal. After internal fixation of an injured vertebra, although the shape of the vertebral body is generally restored, the bone inside the vertebral body is not completely aligned, so there are areas of low-density bone defects of varying degrees [23]. This is the vertebral cavity. In some patients with ISP, the cavity fails to close and even further enlarges to encroach on the upper and lower endplates, cutting off the blood and nutrient supply to the neighboring discs, ultimately leading to vertebral collapse, internal herniation of the discs, and the development of IVP [24]. All patients included in this study were patients who underwent internal fixation surgery and underwent CT scan review within 3 days of surgery and about 1 year after surgery. The results showed FAVP in 27.2% of patients with enlarged vertebral cavities. Fang et al.¹³ found that the degree of repositioning of the injured vertebrae was the only factor influencing the 1-year postoperative outcome of ISP. So we conducted research for the relationship between the degree of repositioning of the vertebrae and FAVP, and the results showed no significant correlation. This might be due to the fact that their study did not incorporate factors such as patients' activity characteristics and nutritional status at 1 year after surgery, so inconsistent results occurred.

In the last few years, there have been an increasing number of studies confirming the close association between traumatic fractures and IVP. However, there is a lack of data for the relationship between ISP and IVP in fractured vertebrae, so we designed this retrospective study to understand the relationship between traumatic vertebral fracture and FAVP at 1 year postoperatively. Overall, in vertebrae with endplate injury and vertebral body collapse from various causes, especially in the elderly, disc degeneration is more severe and the incidence of IVP is significantly higher. Symptoms such as kyphosis, spinal instability, and chronic back pain caused by IVP also need to be considered by clinicians when treating patients with thoracolumbar fractures.

The current treatments for IVP include conservative therapy and cemented discoplasty. However, in the early stages of fracture treatment, especially for patients with high-risk factors for FAVP, whether to simultaneously perform preventive treatment on adjacent intervertebral discs remains to be further explored. Excessive interventional treatment may also bring additional unpredictable risks and consequences.

Limitations

There are some limitations to this study. As a single-centre retrospective study, there was variability in the results

of follow-up of patients. Due to the high heterogeneity of fracture patients, selection bias was low at initial selection, but we may have a higher selection bias when selecting patients with concomitant ISP. The follow-up period was short and the relationship between ISP and FAVP was not clear for more distant periods. Because it was a study of patients with internal fixation, the relationship between fractured vertebrae after removal of internal fixation implants and FAVP was also unclear. In addition, we lack multivariate analyses of larger homogeneous groups in prospective studies to increase the reliability of results and conclusions. Finally, our classification for VP was based on CT findings at a single time point, so there may be misclassification between DAVP and FAVP.

Conclusion

FAVP is common in postoperative patients with thoracolumbar fractures, and the incidence is especially higher in patients with an enlarged ISP cavity at 1 year after surgery. Clinicians need to consider the long-term effects of disc injury and FAVP on patients when developing treatment plans regarding high-energy trauma, older patients with thoracolumbar burst fractures. Because of the correlation between ISP and bone mineral density, further study of the potential correlation between bone mineral density and FAVP may be warranted.

Abbreviations

IVP	Intervertebral disc vacuum phenomenon
ISP	Intervertebral shell phenomenon
FAVP	Fracture-associated Intervertebral disc vacuum phenomenon
DAVP	Degeneration-associated Intervertebral disc vacuum phenomenon
CT	Computed tomography
LSC	Load sharing classification

Acknowledgements

We thank all patients who participated and allowed their data to be anonymously used for the present study.

Author contributions

Chengzhao Liu and Wugui Chen were mainly involved in the conceptualization and design of the study. Material preparation, data collection and analysis were performed by Yao Fang, Ye Yuchao, Zhang Sining, Hengmei Chen, Kongning Chen, Guangfeng Ling and Wang Qing. The first draft of the manuscript was written by Yao Fang, and all authors commented on a previous version of the manuscript. All the authors have read and approved the final manuscript.

Funding

This work was supported by the Fujian Provincial Department of Science and Technology, Fujian Provincial Natural Science Foundation (2021J011452, 2022J011513), Ningde Natural Science Foundation (2022J04), Qihang Foundation of Fujian Medical University(2020QH1341).

Data availability

The datasets used and/or analysed during the current study available from the corresponding author on reasonable request.

Declarations

Ethics approval and consent to participate

This retrospective study adhered to local regulations and guidelines and was approved by the Ethics Review Committee of Mindong Hospital, Ningde City, China. Written informed consent was obtained from all patients. Ethics approval number is 2022092018 K. The conducted experiments respect the ethical standards in the Helsinki Declaration of 1975, as revised in 2000, as well as the national law.

Consent for publication

Not applicable.

Competing interests

The authors declare no competing interests.

Author details

¹Mindong Hospital Affiliated to Fujian Medical University, Ningde, PR China

²Department of Pain Management, Beijing Jishuitan Hospital Guizhou Hospital, No. 206 Sixian Road, Guiyang, PR China

³Department of Clinical Medicine, Faculty of Clinical Medicine, Fujian Medical University, Fuzhou, PR China

Received: 3 February 2024 / Accepted: 6 June 2025

Published online: 04 July 2025

References

1. Magnusson W. On the conditions of the protrusion of the true joint of the true joint space on the radiograph. *Acta Radiol.* 1937;18:733–41.
2. Knutsson F. Das Vakuum-Phänomen in Den bandscheiben. *Acta Radiol.* 1942;os-23(2):173–9. <https://doi.org/10.1177/028418514202300207>.
3. Schömig F, Palmowski Y, Nikiforov I, et al. Burst fractures lead to a fracture-associated intervertebral vacuum phenomenon: a case series of 305 traumatic fractures of the thoracolumbar spine. *Eur Spine J.* 2021;30(10):3068–73. <https://doi.org/10.1007/s00586-020-06590-6>.
4. Wang J, Zhou Y, Zhang ZF, Li CQ, Zheng WJ, Liu J. Radiological study on disc degeneration of thoracolumbar burst fractures treated by percutaneous pedicle screw fixation. *Eur Spine J.* 2013;22(3):489–94. <https://doi.org/10.1007/s00586-012-2462-1>.
5. Denis F. The three column spine and its significance in the classification of acute thoracolumbar spinal injuries. *Spine (Phila Pa 1976).* 1983;8(8):817–31. <https://doi.org/10.1097/00007632-198311000-00003>.
6. Su Y, Ren D, Zou Y, Lu J, Wang P. A retrospective study evaluating the correlation between the severity of intervertebral disc injury and the anteroposterior type of thoracolumbar vertebral fractures. *Clinics.* 2016;71(6):297–301. <https://doi.org/10.6061/clinics/2016/06/02>.
7. Pumberger M, Fuchs M, Engelhard N, et al. Disk injury in patients with vertebral fractures—a prospective diagnostic accuracy study using dual-energy computed tomography. *Eur Radiol.* 2019;29(8):4495–502. <https://doi.org/10.1007/s00330-018-5963-4>.
8. Fujiwara T, Akeda K, Yamada J, Kondo T, Sudo A. Endplate and intervertebral disc injuries in acute and single level osteoporotic vertebral fractures: is there any association with the process of bone healing? *BMC Musculoskelet Disord.* 2019;20(1):336. <https://doi.org/10.1186/s12891-019-2719-5>.
9. Sharma A et al. Lumbar osteoporotic fractures develop in segments with less degenerated discs which then become more degenerated. *European spine journal: official publication of the European spine society, the European spinal deformity society, and the European section of the cervical spine research society* 32,4 (2023): 1437–45. <https://doi.org/10.1007/s00586-023-07573-z>
10. Xin J, Wang Y, Zheng Z, Wang S, Na S, Zhang S. Treatment of intervertebral disc degeneration. *Orthop Surg.* 2022;14(7):1271–80. <https://doi.org/10.1111/os.13254>.
11. Yurac R, Marré B, Urzua Alejandro, Munjin M, Lecaros MA. Residual mobility of instrumented and non-fused segments in thoracolumbar spine fractures. *Eur Spine J.* 2006;15(6):864–75. <https://doi.org/10.1007/s00586-005-0939-x>.
12. Nagad P, Rawall S, Kundnani V, Mohan K, Patil SS, Nene A. Postvertebroplasty instability. *J Neurosurg Spine.* 2012;16(4):387–93. <https://doi.org/10.3171/2011.12.SPINE11671>.

13. Fang Y, Zhang S, Ye Y, et al. Analysis of factors influencing the intravertebral shell phenomenon after posterior reduction internal fixation of thoracolumbar fracture: a retrospective study. *BMC Musculoskelet Disord*. 2024;25(1):49. <https://doi.org/10.1186/s12891-024-07168-9>.
14. Sarli M, Pérez Manghi FC, Gallo R, Zanchetta JR. The vacuum cleft sign: an uncommon radiological sign. *Osteoporos Int*. 2005;16(10):1210–4. <https://doi.org/10.1007/s00198-005-1833-4>.
15. Lenga P, Issa M, Krull L, et al. Radiological features in type II odontoid fractures in older adults after High- and Low-Energy trauma. *Global Spine J*. 2023;13(8):2471–8. <https://doi.org/10.1177/21925682221088215>.
16. German Society for Trauma Surgery. (2016). S3 guideline Polytrauma / treatment of severely injured patients. AWMF. https://www.awmf.org/uploads/tx_szlei_tlini_en/01201_9L_S3_Polytrauma_Schwerverted_treatment_2017-08.pdf.
17. Camino Willhuber G, Bendersky M, De Cicco FL, et al. Development of a new Therapy-Oriented classification of intervertebral vacuum phenomenon with evaluation of Intra- and interobserver reliabilities. *Global Spine J*. 2021;11(4):480–7. <https://doi.org/10.1177/2192568220913006>.
18. McCormack T, Karaikovic E, Gaines RW. The load sharing classification of spine fractures. *Spine (Phila Pa 1976)*. 1994;19(15):1741–4. <https://doi.org/10.1097/0007632-199408000-00014>.
19. Dowdell J, Erwin M, Choma T, Vaccaro A, Iatridis J, Cho SK. Intervertebral disk degeneration and repair. *NEUROSURGERY*. 2017;80(3S):S46–54. <https://doi.org/10.1093/neuros/nyw078>.
20. Sasagawa T, Hayashi H, Takagi Y. Factors associated with intradiscal vacuum phenomenon after traumatic thoracolumbar fracture. *Asian J Neurosurg*. 2023;18(03):621–5. <https://doi.org/10.1055/s-0043-1775551>.
21. Kanezaki S, Miyazaki M, Ishihara T, Notani N, Tsumura H. Magnetic resonance imaging evaluation of intervertebral disc injuries can predict kyphotic deformity after posterior fixation of unstable thoracolumbar spine injuries. *Medicine*. 2018;97(28):e11442. <https://doi.org/10.1097/MD.00000000000011442>.
22. Hirahata M, Kitagawa T, Yasui Y, et al. Vacuum phenomenon as a predictor of kyphosis after implant removal following posterior pedicle screw fixation without fusion for thoracolumbar burst fracture: a single-center retrospective study. *BMC Musculoskelet Disord*. 2022;23(1):94. <https://doi.org/10.1186/s12891-022-05051-z>.
23. Wessels M, Hekman EEG, Kruyt MC, Castelein RM, Homminga JJ, Verkerke GJ. Spinal shape modulation in a Porcine model by a highly flexible and extendable non-fusion implant system. *Eur Spine J*. 2016;25(9):2975–83. <https://doi.org/10.1007/s00586-016-4570-9>.
24. Gohil I, Vilensky JA, Weber EC. Vacuum phenomenon: clinical relevance: vacuum phenomenon: clinical relevance. *Clin Anat*. 2014;27(3):455–62. <https://doi.org/10.1002/ca.22334>.

Publisher's note

Springer Nature remains neutral with regard to jurisdictional claims in published maps and institutional affiliations.