

# Newly Detected Pulmonary Nontuberculous Mycobacterial Infection and Peripheral Lung Cancers in Patients During Follow-Up of Idiopathic Interstitial Pneumonia

## Comparison of CT Findings

Sang Young Oh, MD, Mi Young Kim, MD, PhD, Hye Jeon Hwang, MD, Tae Sun Shim, MD, PhD, Chang-Min Choi, MD, PhD, Sung-Soo Kim, PhD, and Dong Soon Kim, MD, PhD

**Abstract:** This article describes the difference between the computed tomography (CT) findings in patients with newly detected pulmonary nontuberculous mycobacterial infection (NTM-IIP) and Cancer-IIP.

We retrospectively evaluated 35 NTM-IIP and 78 Cancer-IIP patients in reference to their null idiopathic interstitial pneumonia CT ( $n = 113$ ), using >10 years of data. Two independent radiologists analyzed the CT characteristics and the axial location of the main opacity.

The interobserver agreement was good ( $\kappa > 0.771$ ). The NTM-IIP patients were older ( $P = 0.034$ ). The median size of the main opacity in the NTM-IIP (27 mm; 11–73) was larger (19 mm; 5–60;  $P = 0.002$ ). Consolidation ( $n = 30$ ; 85.7%; odds ratio [OR], 45) and cavities ( $n = 14$ ; 40%, OR, 25) were more common in NTM-IIP (all  $P < 0.001$ ). The midst of the fibrotic cysts including honeycomb cysts ( $n = 16$ ; 45.7%, OR, 4.95) was more common in NTM-IIP ( $P = 0.006$ ).

NTM-IIP appeared larger, with more frequent consolidation and cavities, and was more likely to have been located in the midst of the fibrotic cysts including honeycomb cysts at the CT, which showed that it was older than Cancer-IIP.

(*Medicine* 94(13):e691)

**Abbreviations:** Cancer-IIP = newly detected lung cancer in an idiopathic interstitial pneumonia patient, CT = computed tomography, CTD = connective tissue disease, IIPs = idiopathic interstitial pneumonia, NSIP = nonspecific interstitial pneumonia, NTM-IIP = newly detected pulmonary nontuberculous mycobacterial infection in an idiopathic interstitial pneumonia patient, Time0 CT = initial CT without main opacity, Time1 CT =

follow-up CT with new main opacity, UIP = usual interstitial pneumonia.

## INTRODUCTION

Idiopathic interstitial pneumonias (IIPs) are a group of diffuse parenchymal lung diseases of unknown etiology characterized by the presence of various degrees of interstitial inflammation and fibrosis. Current treatment guidelines for IIPs recommend steroid and immunosuppressive drugs as the primary therapies,<sup>1,2</sup> as IIPs are expected to increase the risk of pulmonary nontuberculous mycobacterial (NTM) infection.<sup>3</sup> The prevalence of NTM infection has been increasing rapidly in developing countries such as Korea.<sup>4–6</sup> Lung cancer is significantly more prevalent among IIP patients than in the age-matching general population without it.<sup>7,8</sup> This finding was confirmed in a population-based cohort study in the United Kingdom, in which the estimated rate of association was 7.31.<sup>9</sup> The newly detected, clinically silent main opacity on the follow-up computed tomography (CT) in an IIP patient is very challenging to radiologists and pulmonologists. In a previous study, Yoshida et al<sup>10</sup> focused on evaluating the axial location of the earliest CT findings of lung cancer. However, to our knowledge, no reports have compared the CT findings of clinically silent NTM infection in IIP patients (the NTM-IIP group) with the findings of clinically silent lung cancer in IIP patients (the Cancer-IIP group) during a routine IIP follow-up.

This study was conducted to compare the CT features of newly detected pulmonary NTM infections and peripheral lung cancers in IIP patients, focusing on the main opacity.

## MATERIALS AND METHODS

### Patient Characteristics

Our retrospective study was performed at a single, tertiary referral center and was approved by our Institutional Review Board. Securing of the subjects' informed consent was waived.

For the NTM-IIP group, we reviewed 810 patients in the NTM registry (of T.S.S.) from November 2001 to October 2012 in retrospective manner. The eligibility criteria included the presence of underlying IIPs and incidentally detected NTM with the main opacity such as a nodule, consolidation, or a mass (NTM-IIP) ( $n = 35$ ) (Figure 1A). All the patients in the NTM-IIP group were diagnosed with NTM pulmonary infection and met the American Thoracic Society/Infectious Diseases Society of America criteria for the diagnosis of NTM infection.<sup>11</sup> The confirmation methods of NTM pulmonary infection of the patients are revealed in Table 1.

Editor: Mariusz Adamek.

Received: January 27, 2015; revised and accepted: March 3, 2015.

From the Department of Radiology and Research Institute of Radiology (SYO, MYK); Department of Pulmonary and Critical Care Medicine (TSS, C-MC, DSK); Department of Oncology (C-MC), University of Ulsan College of Medicine, Asan Medical Center, Seoul, South Korea; and Hallym University College of Medicine (HJH), Hallym University, Sacred Heart Hospital, Anyang, and Department of Healthcare Management (S-SK), Cheongju University, Cheongju, South Korea.

Correspondence: Mi Young Kim, MD, Department of Radiology and Research Institute of Radiology, University of Ulsan College of Medicine, Asan Medical Center, 86 Asanbyeongwon-Gil, Songpa-Gu, Seoul 138-736, Korea (e-mail: minowdr@amc.seoul.kr).

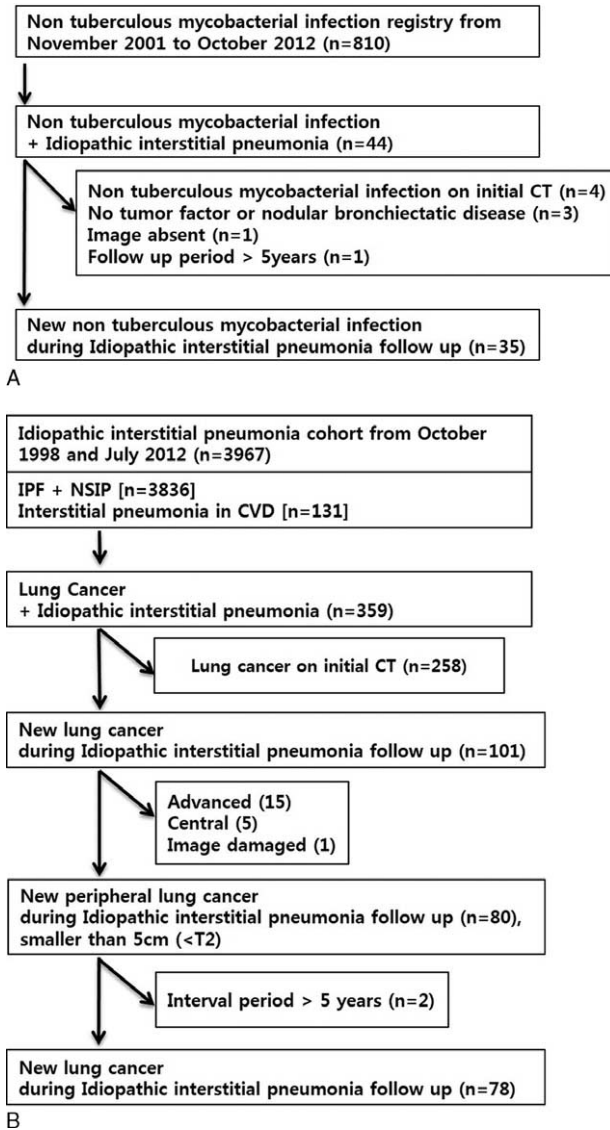
The authors have no funding and conflicts of interest to disclose.

Copyright © 2015 Wolters Kluwer Health, Inc. All rights reserved.

This is an open access article distributed under the Creative Commons Attribution-NonCommercial-NoDerivatives License 4.0, where it is permissible to download, share and reproduce the work in any medium, provided it is properly cited. The work cannot be changed in any way or used commercially.

ISSN: 0025-7974

DOI: 10.1097/MD.0000000000000691



**FIGURE 1.** Inclusion criteria. (A) Newly detected, incidental pulmonary nontuberculous mycobacterial infection during the CT follow-up of idiopathic interstitial pneumonia. (B) Newly detected, incidental lung cancer found during the CT follow-up of idiopathic interstitial pneumonia. CT = computed tomography, CVD = collagen vascular disease, IPF = idiopathic interstitial fibrosis, NSIP = nonspecific interstitial pneumonia.

For the Cancer-IIP group, we retrospectively searched for IIP cohorts from October 1998 to July 2012 (of D.S.K.) from an IIP clinic. We found 365 patients with lung cancer based on a background of pulmonary fibrosis (Cancer-IIP) among 3967 IIP patients (with idiopathic pulmonary fibrosis and nonspecific interstitial pneumonia [NSIP; n = 3836] or interstitial pneumonia [IIP] in collagen vascular disease [n = 131]). We excluded the initial cancer, central cancer,  $\geq T2$  or  $\geq N1$  stage,  $\geq 3$  years CT interval from Time0 CT to Time1 CT, and poor image quality. We analyzed 78 cases with new Cancer-IIP that manifested at a peripheral location (Figure 1B), T1 (n = 54) and up to T2 (n = 24), and with no significant lymphadenopathy (N0

(Figure 1B) according to the Seventh Edition of the TNM Classification.<sup>12</sup>

IIP was diagnosed pathologically from a wedge lung biopsy in 30 of the 35 patients in the NTM-IIP group and in 65 of the 78 patients in the Cancer-IIP group. Eighteen other patients were diagnosed with the radio-clinical criteria from the American Thoracic Society and European Respiratory Society<sup>13</sup> (Table 1).

### CT Examination

#### CT Protocol

Various CT scanners were used for this study. The most representative CT scanner were SOMATOM sensation (Siemens Medical Solutions, Forchheim, Germany; n = 61) or the light-speed volume computed tomography (VCT) (GE Medical Systems, Milwaukee, Wis; n = 15). CT parameters used in each CT scanner were as follows: SOMATOM sensation, 120 kVp, 100 effective mAs with dose modulation, reconstructed using B60 algorithm (3/5-mm thickness and 3/5-mm increment without a gap) and B50 algorithm (1-mm thickness with 5-mm gap); and VCT, 120 kVp, 100–300 mA with dose modulation, reconstructed using lung algorithm (2.5/5-mm thickness and 2.5/5-mm increment without a gap) and bone algorithm (1.25-mm thickness with a 5-mm gap).

All images were viewed at mediastinal [width, 450 Hounsfield unit (HU); level, 50 HU] and lung window (width, 1500 HU; level, - 700 HU) settings of axial mage using our picture archiving and communication system.

#### CT Evaluation

The CT scan nearest in time to the first organism isolation in each patient was selected for the radiologic review. The mean time interval between the first NTM isolation and the CT examination was 11 days (range, 0–220 days).

Two chest radiologists (M.Y.K. and S.Y.O., with 18 and 4 years of experience in thoracic radiology, respectively) who were blinded to all the clinical data except those of all the IIP patients reviewed the serial 226 CT scans and determined the earliest scan that showed NTM-IIP and Cancer-IIP (113 Time1 CT; time of presentation reference to 113 Time0 CT; no main opacity). The randomly mixed 113 Time1 CT scans were independently analyzed with regard to the CT characteristics, that is, the main opacity (size, 3 types [nodule, mass, and consolidation], presence of a cavity, and 4 axial locations) in the two groups according to the glossary of terms.<sup>14</sup> We also analyzed the involved axial locations of the consolidation using the 4 category on the transverse CT image in the 36 patients in this study, subdivided into the interface of the fibrotic cysts (mixed-up area of honeycomb cysts, reticulation, traction bronchiectasis, and emphysema) and a normal lung; the ground-glass opacity; the midst of honeycomb cysts or reticulation; and a normal lung<sup>10</sup> (Figure 2).

#### Statistical Analysis

The  $\chi^2$  or Fisher exact test was used for the categorical variables, and the Mann–Whitney U test was used for the continuous data. The interobserver variation was quantified using a  $\kappa$  coefficient of agreement to account for the degree of disagreement on a categorical scale. We used binary logistic regression to account for the odds ratio (OR). Data with *P* values <0.05 were considered statistically significant. All the data were analyzed using a statistical software package (SPSS,

**TABLE 1.** Clinical Characteristics of 113 Cases (of 112 Patients) of Incidental Pulmonary NTM Infection or New Peripheral Lung Cancer With Underlying Idiopathic Interstitial Pneumonia

Characteristics	NTM (n = 35)	Lung Cancer (n = 78)	Odds Ratio	95% CI	P Value
Age, y					
Median	70	66			
Range	51–80	40–85	1.06	1.00–1.12	0.034
Gender					
Male	27 (77.1)	70 (89.7)	1		
Female	8 (22.9)	8 (10.3)	2.59	0.88–7.60	0.087
Confirmation					N/A
Sputum	31 (91.2)	1 (1.3)			
BAL	3 (8.8)	0 (0.0)			
Histology (biopsy/OP/cytology)	1 (2.9) (1/0/0)	77 (98.7) (6/67/4)			
Underlying CTD	7 (20.0)	4 (5.1)			N/A
Sjogren syndrome	0	1			
Systemic sclerosis	0	2			
Rheumatoid arthritis	7	1			
Dermatomyositis	0	0			
Underlying IIP					N/A
Biopsy-proven UIP	6 (17.1)	22 (28.2)			
Biopsy-proven NSIP	24 (68.6)	43 (55.1)			
Clinico-radiological UIP	0	5 (6.4)			
Clinico-radiological NSIP	5 (14.3)	1 (1.3)			
Others	0	7 (9.0)			
Cell type of lung cancer					N/A
Nonsmall cell	—	61 (78.2)			
Small cell	—	17 (21.8)			
Pathogen of NTM infection					N/A
<i>Mycobacterium avium</i>	9 (25.7)				
<i>M intracellulare</i>	21 (60.0)				
<i>M abscessus complex</i>	2 (5.7)				
Others	3 (8.6)				

BAL = bronchoalveolar lavage, CI = confidence interval, NSIP = nonspecific interstitial pneumonia, N/A = not available, NTM = nontuberculous mycobacterial infection, OP = operation, UIP = usual interstitial pneumonia.

version 20.0; SPSS, Inc., Chicago, IL) by 10 years experienced statistician (S.-S.K.).

## RESULTS

### Patient Characteristics

The univariate analysis showed that the NTM-IIP patients (70 years old, range, 51–80) were older than the Cancer-IIP patients (66 years old, range, 40–85) ( $P=0.034$ ) (Table 1). There were no gender differences between the 2 patient groups (male, 27, and female, 8, in the NTM-IIP group; and male, 70, and female, 8, in the Cancer-IIP group) ( $P=0.087$ ).

The most common pathogen of NTM infection is *Mycobacterium intracellulare* (60%), followed by *M avium* (26%). The ratio of small-cell ( $n=17$ ) to nonsmall-cell ( $n=61$ ) lung cancer is 1 to 4 (adenocarcinoma;  $n=20$ , 32.8%). In this study, more than half of the patients had NSIP, that is, NTM-IIP in 29 (83%) and Cancer-IIP in 44 (56%) patients (Table 1).

Of the 113 study patients, the relative prevalence of newly detected NTM-IIP to new Cancer-IIP was approximately one-half during the nearly 10-year study period (35:78) on the Time1 CT.

### CT Evaluation

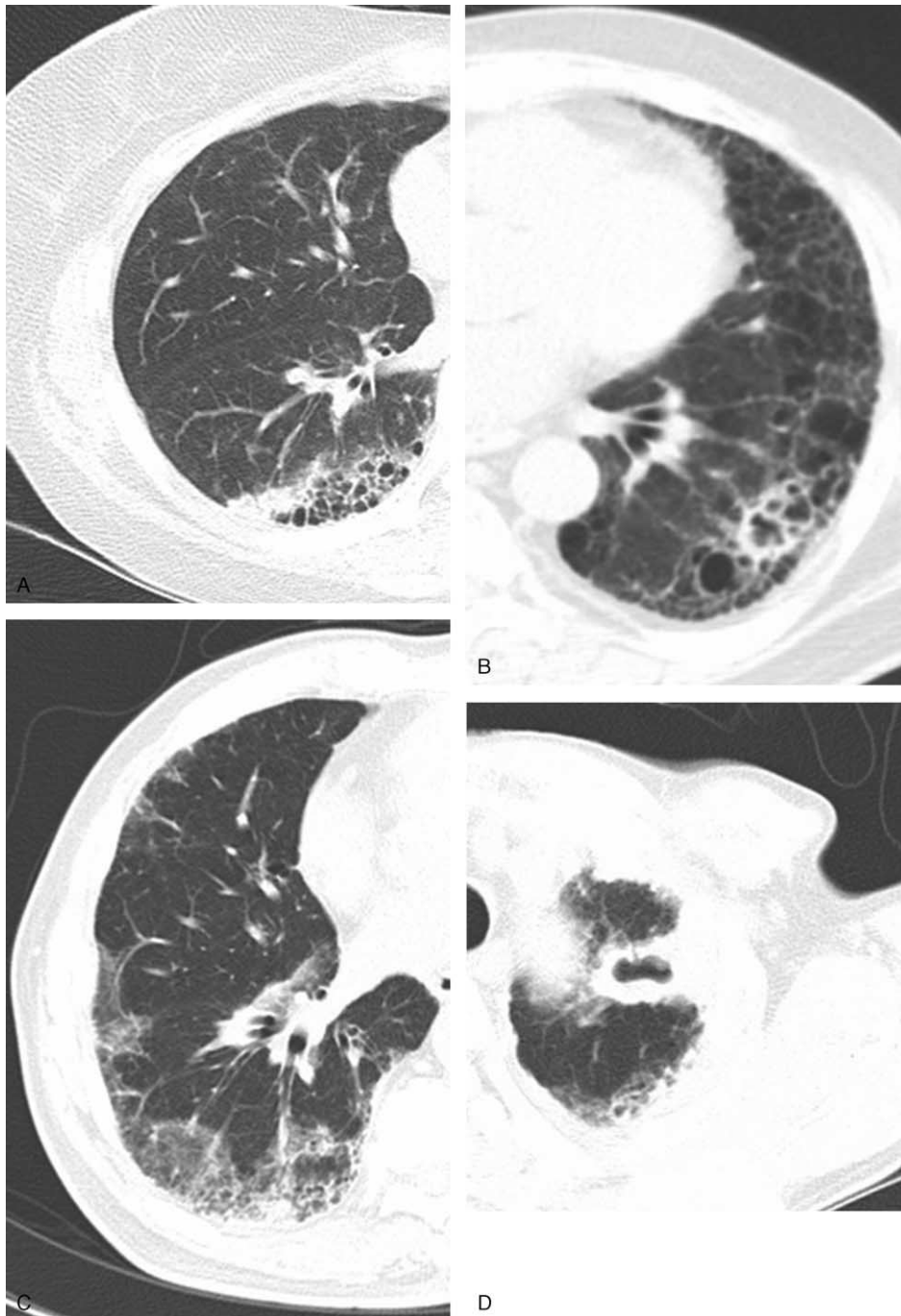
The interobserver agreement regarding the radiological scores was good to very good (Cohen  $\kappa$  value  $>0.771$ ).

The median size of the main opacity at the time of the patient's presentation was significantly larger in the NTM-IIP patients (27.0 mm; range, 11–73) than in the Cancer-IIP patients (19.0 mm; range, 5–60) (OR, 4.63; 95% CI, 1.96–10.90;  $P < 0.001$ ; and reference to the cutoff value, 25 mm).

Consolidation ( $n=30$ ; 85.7%; and OR, 45.00) and cavities ( $n=14$ ; 40%; and OR, 25.33) were seen more often in the NTM-IIP cases (all  $P < 0.001$ ) (Figures 2 and 3). The lung cancer cases showed a nodule ( $n=54$ , 69.2%) or a mass ( $n=15$ , 19.2%) without a cavity ( $n=76$ , 97.4%).

In the axial location, the midst of fibrotic cysts ( $n=16$ ; 45.7%; and OR, 4.95) (Figure 3) and a normal lung ( $n=13$ ; 37.1%; and OR, 4.42) were more common in the NTM-IIP patients than in the Cancer-IIP patients ( $P=0.006$  and 0.013, respectively) (Figures 4 and 5, and Table 2). Lung cancer was mainly manifested at the interface ( $n=34$ , 43.6%), and then at the midst of the fibrotic cysts ( $n=22$ , 28.2%).

The radiologic diagnosis of “first choice” was correct in both the NTM-IIP ( $n=6$ ; 17%) and Cancer-IIP ( $n=57$ ; 73%) patients (Table 2).



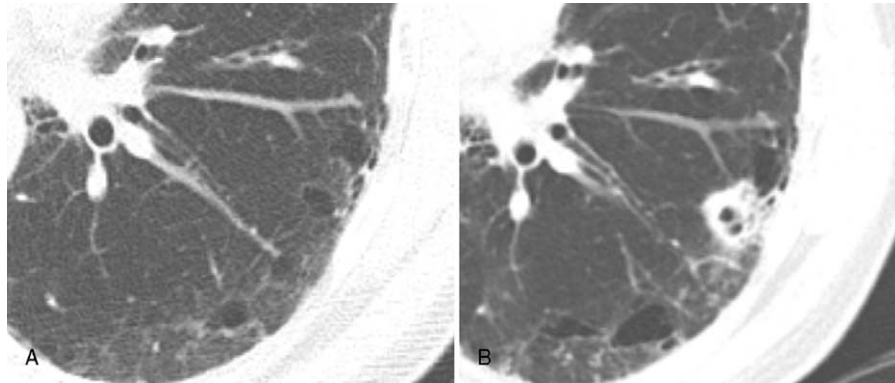
**FIGURE 2.** CT images showing 4 axial locations of lung cancer. The axial location of the main opacity, as seen in the transverse image, is evaluated as the association of the tumor-like lesion with fibrotic lung cysts; mixed-up area of honeycomb cysts, reticulation, traction bronchiectasis, and emphysema. The axial location is subcategorized as (A) at the interface of fibrotic cysts and a normal lung in Cancer-IIP, (B) in the midst of fibrotic cysts in NTM-IIP, (C) within ground-glass opacity in Cancer-IIP, or (D) confined in a normal lung in NTM-IIP. Cancer-IIP = newly detected lung cancer in an idiopathic interstitial pneumonia patient, NTP-IIP = newly detected pulmonary nontuberculous mycobacterial infection.

## DISCUSSION

Advanced IIP patients have simultaneous risks of NTM infection and lung cancer.<sup>1,2,4-9</sup> NTM infections and lung cancers newly detected in IIP patients during routine high-

resolution CT (HRCT) follow-ups exhibit atypical manifestations, unlike those seen in immunocompetent patients without IIP.<sup>10</sup> Furthermore, atypical manifestations of NTM-IIP or Cancer-IIP are challenging both with respect to making the correct diagnosis and the planning therapy, even for clinically





**FIGURE 3.** A 61-year-old man with usual interstitial pneumonia (UIP), proven by the clinical–radiological diagnosis as well as an incidental pulmonary nontuberculous mycobacterial infection that was detected during the UIP follow-up. (A) The initial, null, high-resolution CT transverse image lung window (1-mm reconstruction) at the inferior pulmonary vein level shows no significant main opacity. There are, however, diffuse reticulation, ground-glass opacity, and air cysts with subpleural dominance seen on UIP patterns. (B) At the time of the follow-up 6 months later, a CT transverse image after steroid therapy, obtained in the lung window (1-mm reconstruction) and at the same level, shows a newly appeared nodule with a cavity in the interface of the fibrotic cysts compared to that seen on the null CT image (A). CT = computed tomography.

experienced radiologists and physicians. To our knowledge, comparison of these two disease entities has not been reported yet, despite the high clinical concern about them.

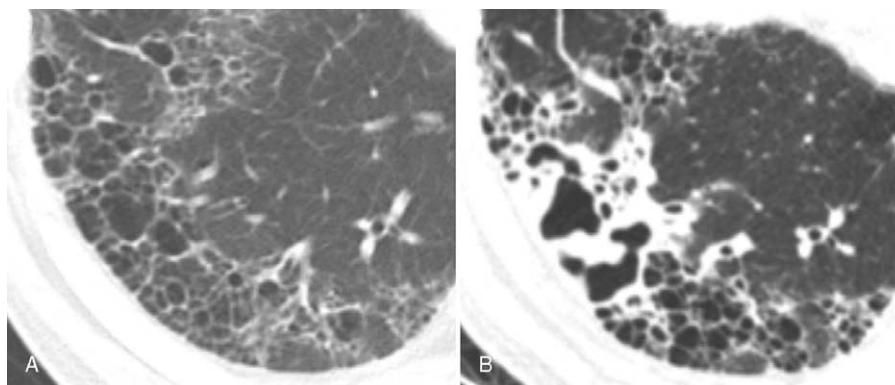
NTM pulmonary infection in IIP patients is characterized as lobar or segmental consolidation with/without a cavity, unlike in immunocompetent patients without IIP, and can mimic other diseases, especially bacterial or fungal infection, as shown in another study of our center.<sup>15</sup>

A study reported the higher prevalence of large opacity (>2 cm) with/without a cavity and ill-defined nodules of NTM pulmonary infection in immunocompromised hosts than in immunocompetent hosts.<sup>16</sup>

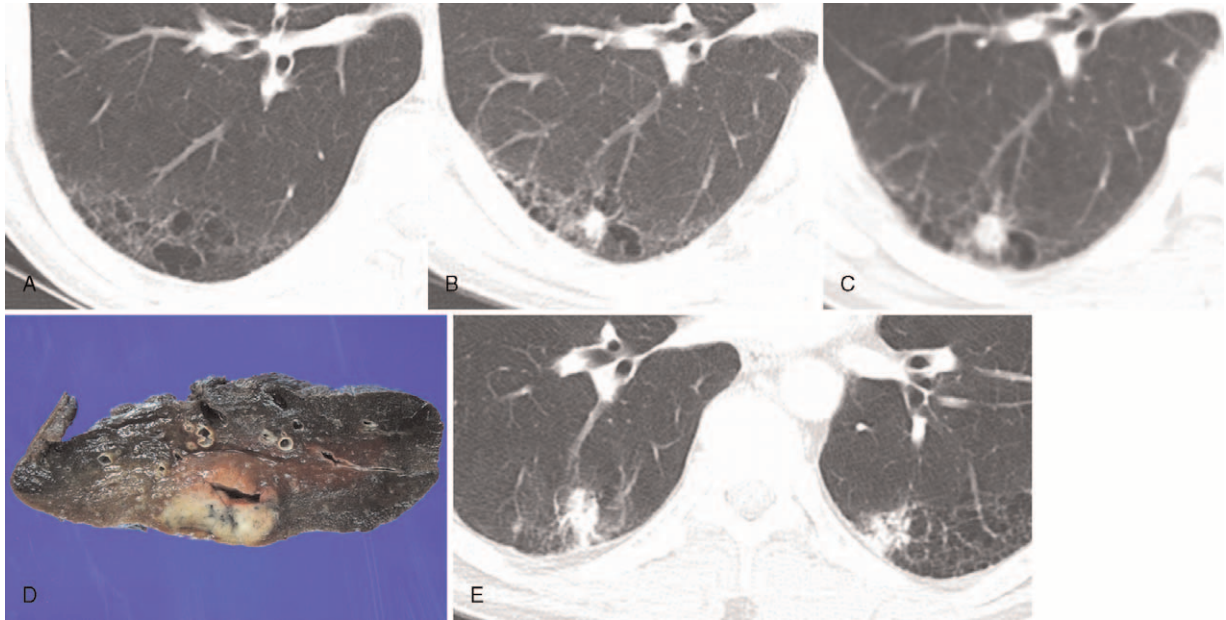
In our study, NTM-IIP was found in patients older than the Cancer-IIP patients. The most common pathogen involved in NTM infections was *M intracellulare* (60%), followed by *M avium* (26%), the so-called *M avium-intracellulare complex* (MAC), similar to that described in another Korean study on patients without IIP.<sup>17</sup>

In several studies in which chest CT scans were used, the presence of bilateral, multisegmental, and bronchocentric lesions—namely, well-defined small nodules and branching centrilobular nodules or those with a tree-in-bud pattern, as well as bronchiectasis distributed primarily in the right middle lobe and the lingular segment was demonstrated as indicative of MAC infection.<sup>18–22</sup> We discovered similar pathogens among the patients with NTM infection, but their CT imaging findings were unlike those in the IIP patients. The patients in the NTM-IIP group had lobar or segmental consolidation with a cavity, the so-called “cavitary disease” that differs from that seen without IIP, namely, “nodular bronchiectatic disease.”<sup>17,23</sup> In our study, there was a much higher rate of fibrocavitary disease in the upper lobe with a main opacity than of nodular bronchiectatic disease.

The radiological diagnosis in our formal report before its confirmation was correct in only 17% of the patients in the NTM-IIP group, but was correct in 73% of the patients in the



**FIGURE 4.** A 61-year-old man with usual interstitial pneumonia (UIP) proven by the clinical–radiological diagnosis as well as an incidental pulmonary nontuberculous mycobacterial infection detected during the UIP follow-up. (A) The initial, null, high-resolution CT transverse image lung window (1-mm reconstruction) at the basal segmental pulmonary artery level shows no significant main opacity. There are diffuse reticulation, ground-glass opacity, and air cysts with subpleural dominance, all of which show a UIP pattern. (B) At the time of the follow-up 10 months later, a CT transverse image in the lung window (1-mm reconstruction) obtained following steroid therapy and at the same level, shows newly appearing, unusually shaped consolidation with a thick irregular cavity in the midst of fibrotic cysts compared to that seen on the null CT image (A). CT = computed tomography.



**FIGURE 5.** A 57-year-old male patient with biopsy-proven, usual interstitial pneumonia and incidental lung cancer. (A) The initial, null, high-resolution CT transverse image lung window (1-mm reconstruction) at the level of the right inferior pulmonary vein shows no significant main opacity. There are diffuse reticulation, ground-glass opacity, and air cysts with subpleural dominancy showing a UIP pattern. (B) Sixteen months later, the first follow-up, high-resolution CT transverse image lung window (1-mm reconstruction) shows a newly appearing, irregular margined nodule at the interface of fibrotic cysts compared to that seen on null CT (A) in the right lower lobe. (C) Six months later, the follow-up, conventional CT transverse image lung window (5-mm reconstruction) shows the increased size of the nodule at the same axial location. (D) The transverse location of the nodule was seen as the “interface” on the gross pathology examination performed following wedge resection. The nodule revealed adenocarcinoma. (E) Seven months later, the follow-up, high-resolution CT transverse image lung window (1-mm reconstruction) shows a new, well-defined nodule at the wedge resection site of the right lower lobe revealing “stump recurrence.” Another new nodule in the left lower lobe in the interface revealed “de novo lung cancer” with a different cell type of adenocarcinoma.

**TABLE 2.** HRCT Findings in 113 Cases (of 112 Patients) With Incidental Pulmonary NTM Infection or New Peripheral Lung Cancer With Underlying Idiopathic Interstitial Pneumonia

Characteristics	NTM (n = 35)	Lung Cancer (n = 78)	Odds Ratio	95% CI	P Value
Size on the transverse scan					
Median	27.0	19.0			
Range	11–73	5–60			
<25 mm	11 (31.4)	53 (67.9)	1		
≥25 mm	24 (68.6)	25 (32.1)	4.63	1.96–10.90	<0.001
Opacity					
Nodule	4 (11.4)	54 (69.2)	1		
Consolidation	30 (85.7)	9 (11.5)	45.00	12.77–158.57	<0.001
Mass	1 (2.9)	15 (19.2)	0.90	0.09–8.67	0.927
Cavity					
Without cavity	21 (60.0)	76 (97.4)	1		
With cavity	14 (40.0)	2 (2.6)	25.33	5.33–120.36	<0.001
Axial location					
Interface	5 (14.3)	34 (43.6)	1		
GGO	1 (2.9)	2 (2.6)	3.40	0.26–44.76	0.352
Midst of fibrotic cysts	16 (45.7)	22 (28.2)	4.95	1.58–15.44	0.006
Normal lung	13 (37.1)	20 (25.6)	4.42	1.37–14.24	0.013

GGO = ground glass opacity, NTM = nontuberculous mycobacterial infection. Midst of fibrotic cysts, mixed-up area of honeycomb cysts, reticulation, traction bronchiectasis, and emphysema.

Cancer-IIP group, as detected during the routine HRCT follow-up of the IIP patients, despite the tertiary referral center in which the follow-up was performed in the presence of several expert chest radiologists. A newly appearing main opacity that shows neither symptoms nor abnormal laboratory findings during the IIP follow-up causes confusion, especially with an indolent type of NTM infection or with incidental lung cancer. In addition, the symptoms of Cancer-IIP often mimic those of focal inflammation or fibrosis.<sup>10</sup> This is why we conducted this research.

Consolidation and a cavity were more common in the NTM-IIP group than in the Cancer-IIP group. The median size of the main opacity at the time of presentation was much larger in the NTM-IIP group than in the Cancer-IIP group. CT scans of the lungs of the Cancer-IIP patients showed small nodules or a mass. There was no cavity in 97% of the Cancer-IIP patients. A larger extent of consolidation with or without a cavity was a characteristic finding in the NTM-IIP patients.

In terms of the location of the main opacity, the midst and the normal lung were more common axial locations in the NTM-IIP group than in the Cancer-IIP group. Most lesions in the Cancer-IIP group were located at the interface of the normal lung tissues and the fibrotic cysts. The NTM-IIP significantly tended to spread out in the midst of honeycomb cysts. On the other hand, Cancer-IIP tended to spread out along the line of the interface in many patients on subsequent HRCT follow-up in our study population. Therefore, we assume that a latent state of pulmonary NTM infection can arise and grow within the stiff fibrotic cysts of underlying IIP among patients with insufficient mechanical and immunological defense mechanisms. However, new cancers in IIP patients begin as scar cancers with intact blood supply as a feeder adjacent to the interface, especially in the subpleural area of both lower lobes.

Our results differ significantly from those of another pertinent study.<sup>24</sup> In cases of idiopathic pulmonary fibrosis with lung cancer (IPF-CA), most of the cancers (64%) were found in the nonfibrotic area on the chest CT scans.<sup>24</sup> However, we found the axial locations of the cancers more closely related to fibrotic lesions (44% at the interface and 28% in the midst of lesions, for a total of 72%) than those seen in the previous study (36%). As that study was performed among fewer patients, it had a different inclusion rate of IPF-usual interstitial pneumonia (UIP) patients and a less detailed CT analysis than in our study.

Prompt and accurate diagnosis of newly detected main opacity in IIP patients is essential because if the diagnosis is delayed, such patients can deteriorate rapidly. Patients with symptomatic UIP with a small functional reservoir are common in our routine practice. An invasive method of pathologic confirmation of intrathoracic main opacity simultaneously burdens patients, clinicians, and interventional radiologists.

Therefore, this pattern of representative main opacity in IIP patients is an important clue for differentiating NTM infection from cancer during follow-up using HRCT.

This study had several limitations. First, as it was a retrospective study, the interval between the two CT examinations of each patient was not determined in advance and showed a variable range. At our medical institution, IIP patients undergo CT scanning at approximately 6-month intervals up to 1 year. Second, it is performed in a tertiary referral center. Therefore, in this study, there could have been patient selection bias. Particularly, as the subjects of this study included patients with overt NTM infection and IIP, there might have been a selection bias, including with respect to patients with more extensive diseases. Third, there were fewer NTM-IIP patients: only half as many as Cancer-IIP patients. These differences in

the numbers of patients in the two groups limited the accuracy of our statistical comparisons. Fourth, different NTM pathogens could have manifested differently on the CT scans, and are so far unknown. Fifth, we did not analyze multisegmental nodules or bronchocentric lesions but focused on the representative main opacity, although such ancillary findings were relatively rare. Finally, as the underlying CTD was 20% in the NTM-IIP group and 5% in the Cancer-IIP group, these could overlap with underlying CTD findings. In our study, many patients had NSIP 83% in the NTM-IIP group and 56% in the Cancer-IIP group.

However, it could be useful to combine knowledge of well-focused CT morphological features with individual clinical characteristics to come up with more detailed assessments to decide on a preemptive or empirical therapy before confirming the pathogen of NTM infection or cancer, especially in a very advanced state of underlying IIP. We believe that diagnosis and therapeutic plans for complicated main opacity should be based on multidisciplinary inputs from infectious disease specialists, radiologists, pulmonologists, and oncologists. This study could provide an evidence-based approach to dealing with certain critically ill and complex patients, despite the study's limitations.

In conclusion, most newly detected cases of NTM-IIP show consolidation of the lesion with a cavity located in the midst of fibrotic cysts including honeycomb cysts that are usually >25 mm in diameter and in older patients. However, the Cancer-IIP group typically showed a nodule or a mass without a cavity, and the lesions were mostly located at the interface of a normal lung and fibrotic cysts that are usually less than 25 mm in diameter and in younger patients.

## REFERENCES

- Scientific Committee in Korean Academy of Tuberculosis and Respiratory Diseases. National survey of mycobacterial diseases other than tuberculosis in Korea. *Tuberc Respir Dis.* 1995;42:277–294.
- Selman M, King TE, Pardo A, et al. Idiopathic pulmonary fibrosis: prevailing and evolving hypotheses about its pathogenesis and implications for therapy. *Ann Intern Med.* 2001;134:136–151.
- Ellis S, Hansell D. Imaging of non-tuberculous (atypical) mycobacterial pulmonary infection. *Clin Radiol.* 2002;57:661–669.
- Falkinham JO. Nontuberculous mycobacteria in the environment. *Clin Chest Med.* 2002;23:529–551.
- Marras TK, Daley CL. Epidemiology of human pulmonary infection with nontuberculous mycobacteria. *Clin Chest Med.* 2002;23:553–567.
- Griffith DE, Aksamit T, Brown-Elliott BA, et al. An official ATS/IDSA statement: diagnosis, treatment, and prevention of nontuberculous mycobacterial diseases. *Am J Respir Crit Care Med.* 2007;175:367–416.
- Matsushita H, Tanaka S, Saiki Y, et al. Lung cancer associated with usual interstitial pneumonia. *Pathol Int.* 1995;45:925–932.
- Ozawa Y, Suda T, Naito T, et al. Cumulative incidence of and predictive factors for lung cancer in IPF. *Respirology.* 2009;14:723–728.
- Hubbard R, Venn A, Lewis S, et al. Lung cancer and cryptogenic fibrosing alveolitis. A population-based cohort study. *Am J Respir Crit Care Med.* 2000;161:5–8.
- Yoshida R, Arakawa H, Kaji Y. Lung cancer in chronic interstitial pneumonia: early manifestation from serial CT observations. *AJR Am J Roentgenol.* 2012;199:85–90.

11. Nguyen V. Diagnosis and treatment of disease caused by nontuberculous mycobacteria. This official statement of the American Thoracic Society was approved by the Board of Directors, March 1997. Medical Section of the American Lung Association. *Am J Respir Crit Care Med.* 1997;156:S1–S25.
12. Goldstraw P, Crowley J, Chansky K, et al. The IASLC Lung Cancer Staging Project: proposals for the revision of the TNM stage groupings in the forthcoming (seventh) edition of the TNM Classification of malignant tumours. *J Thoracic Oncol.* 2007;2:706–714.
13. Travis WD, Costabel U, Hansell DM, et al. An official American Thoracic Society/European Respiratory Society statement: update of the international multidisciplinary classification of the idiopathic interstitial pneumonias. *Am J Respir Crit Care Med.* 2013;188:733–748.
14. Hansell DM, Bankier AA, MacMahon H, et al. Fleischner Society: glossary of terms for thoracic imaging. *Radiology.* 2008;246:697–722.
15. Hwang HJ, Kim MY, Shim TS, et al. Nontuberculous mycobacterial pulmonary infection in patients with idiopathic interstitial pneumonias: comparison with patients without idiopathic interstitial pneumonias. *J Comput Assist Tomogr.* 2014;38:972–978.
16. Lee Y, Song JW, Chae EJ, et al. CT findings of pulmonary nontuberculous mycobacterial infection in non-AIDS immunocompromised patients: a case-controlled comparison with immunocompetent patients. *Br J Radiol.* 2013;86:20120209.
17. Koh W-J, Lee KS, Kwon OJ, et al. Bilateral bronchiectasis and bronchiolitis at thin-section CT: diagnostic implications in nontuberculous mycobacterial pulmonary infection. *Radiology.* 2005;235:282–288.
18. Hartman TE, Swensen SJ, Williams DE. *Mycobacterium avium*-intracellulare complex: evaluation with CT. *Radiology.* 1993;187:23–26.
19. Lynch DA, Simone PM, Fox MA, et al. CT features of pulmonary *Mycobacterium avium* complex infection. *J Comput Assist Tomogr.* 1995;19:353–360.
20. Moore EH. Atypical mycobacterial infection in the lung: CT appearance. *Radiology.* 1993;187:777–782.
21. Primack SL, Logan PM, Hartman TE, et al. Pulmonary tuberculosis and *Mycobacterium avium*-intracellulare: a comparison of CT findings. *Radiology.* 1995;194:413–417.
22. Swensen SJ, Hartman TE, Williams DE. Computed tomographic diagnosis of *Mycobacterium avium*-intracellulare complex in patients with bronchiectasis. *Chest.* 1994;105:49–52.
23. Martinez S, McAdams HP, Batchu CS. The many faces of pulmonary nontuberculous mycobacterial infection. *AJR Am J Roentgenol.* 2007;189:177–186.
24. Park J, Kim DS, Shim TS, et al. Lung cancer in patients with idiopathic pulmonary fibrosis. *Eur Respir J.* 2001;17:1216–1219.