



The Brazilian Journal of INFECTIOUS DISEASES

www.elsevier.com/locate/bjid



Clinical image

Positron emission tomography/computed tomography in cases with tuberculosis mimicking lung cancer

Hasim Boyaci*, Ilknur Basyigit, Serap Argun Baris

Department of Pulmonary Disease, School of Medicine, Kocaeli University, Umuttepe, Turkey

ARTICLE INFO

Article history:

Received 15 May 2012

Accepted 18 May 2012

Available online 7 March 2013

Fluorodeoxyglucose positron emission tomography/computed tomography (PET/CT) is a powerful tool in cancer imaging. The basic principle is the accumulation of the radiopharmaceutical in areas of increased glucose metabolism. However, glucose is also an important substrate for inflammatory cells. Recent studies suggested that PET/CT findings should be interpreted with caution in tuberculosis-endemic regions.^{1,2} Here we reported the images of two cases with pulmonary tuberculosis mimicking lung cancer.

The first case was a 67-year-old female who was admitted with a history of cough and hemoptysis for the last 3 months. The computed tomography of thorax revealed a mass lesion in the left upper lobe of 4.1 cm × 4.5 cm in diameter. The maximum standardized uptake value (SUVmax) of the mass lesion was 13.6 on the PET/CT examination. Other case was a 68-year-old male patient who was admitted with a history of 2 months of cough. The thorax CT revealed a 4 cm × 2 cm mass lesion with spicular radiation in the left upper lobe

with a FDG SUVmax of 9.6 in the PET/CT examination (Figs. 1 and 2).

Flexible fiberoptic bronchoscopy was performed in both cases; however, no visible endobronchial lesion was noted. The results of smear and cytology of the bronchial lavage fluid were negative for acid-fast organisms (AFB) and malignant cells. Transthoracic needle biopsy guided by computed tomography was also negative for malignancy. However, culture of bronchial lavage fluid was positive for tuberculosis in both cases.

These data suggested that besides histological evaluation microbiological culture results for mycobacterium should be pursued since a negative result for AFB in sputum and/or bronchial fluid does not rule out the diagnosis of tuberculosis.

In conclusion, the exact role of PET/CT in tuberculosis is not yet clearly defined. We thought that with the development of more specific radiotracers in the future, PET/CT may play a significant role in the diagnosis of tuberculosis.³

* Corresponding author at: Kocaeli University, School of Medicine, Department of Pulmonary Disease, Umuttepe, Kocaeli, Turkey.

E-mail address: haboyaci@yahoo.com (H. Boyaci).

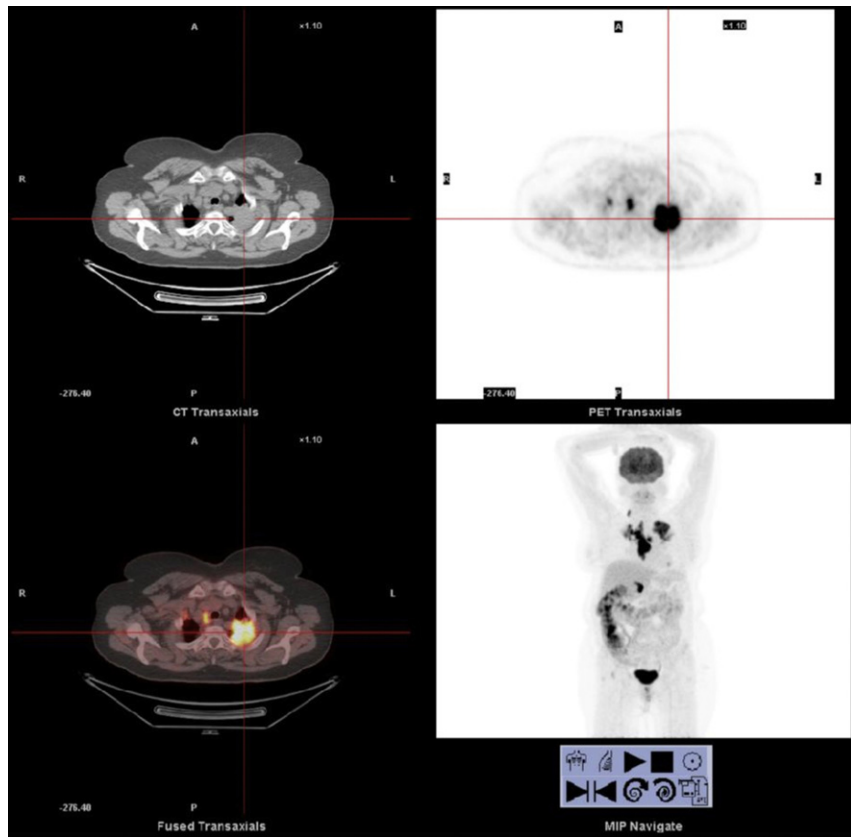


Fig. 1 – The PET/CT images of the first case revealed a mass lesion with a high FDG uptake.

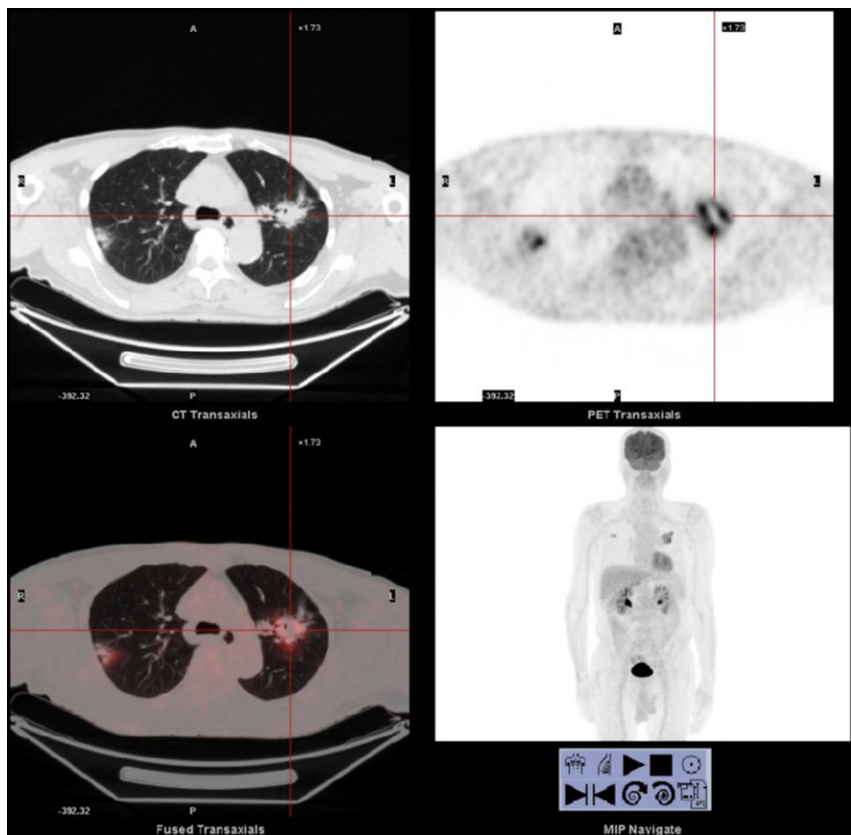


Fig. 2 – The PET/CT images of the second case revealed a mass lesion in the left upper lobe with a high FDG uptake.

Conflict of interest

The authors declare to have no conflict of interest.

REFERENCES

1. Zheng Z, Pan Y, Guo F, et al. Multimodality FDG PET/CT appearance of pulmonary tuberculoma mimicking lung cancer and pathologic correlation in a tuberculosis-endemic country. *South Med J.* 2011;104:440-5.
2. Li Y, Su M, Li F, et al. The value of 18F-FDG-PET/CT in the differential diagnosis of solitary pulmonary nodules in areas with a high incidence of tuberculosis. *Ann Nucl Med.* 2011;25:804-11.
3. Harkirat S, Anand SS, Indrajit IK, et al. Pictorial essay: PET/CT in tuberculosis. *Indian J Radiol Imaging.* 2008;18:141-7.