

Secondary glaucoma after intravitreal dexamethasone implant (Ozurdex) injection in patients with retinal disorder: A retrospective study

Sweta VD, Shibi Dev BN, Sandhya R

Purpose: To investigate the rate of secondary glaucoma after intravitreal (IV) dexamethasone implant (ozurdex) 0.7 mg injection in a retinal disorder over a clinical treatment period of 2 years in a tertiary eye care center. **Methods:** Retrospective study based on the records of patients receiving IV ozurdex 0.7 mg implant for T/t of cystoid macular edema (CME), diabetic macular edema (DME), macular edema due to central retinal vein occlusion/branch retinal vein occlusion (CRVO/BRVO), and choroidal neovascular membrane (CNVM) at a tertiary eye care hospital for 2 years with 6 months of follow-up. The post-T/t intraocular pressure (IOP) and antiglaucoma medication (AGM) required was recorded at day 1, 1 week, 1, 2, 3, 4, and 6 months and analyzed for secondary IOP spike or ocular hypertension defined as IOP >21 mmHg at any point in time. The patients with pre-existing glaucoma and lost to follow-up were excluded. **Results:** A total of 102 eyes of 80 patients were included in the study. The mean baseline IOP was 14.40 + 2.97 mmHg, post-injection was 15.01 + 3.22 mmHg at day 1, 15.15 + 3.28 mmHg at 1 week, 15.96 + 3.62 mmHg at 1 month, 16.26 + 3.95 mmHg at 2 months, 15.41 + 3.33 mmHg at 3 months, 15.38 + 3.28 mmHg at 4 months, and 14.27 + 2.69 mmHg at 6 months. No significant difference was seen from baseline IOP at day 1 ($P = 0.163$), 1 week ($P = 0.086$), and 6 months ($P = 0.748$). Statistically significant difference was seen at 1 month ($P = 0.0009$), 2 months ($P = 0.0001$), 3 months ($P = 0.023$), and 4 months ($P = 0.026$). The mean IOP peak at 2 months recovered to baseline by 6 months subgroup IOP trend shows a similar variation and the results are consistent with the studies in the literature. About 19/102 (18.62%) eyes showed an IOP spike post-T/t. The maximum was seen at 2 months; 16 eyes showed a rise in the range 22–25 mmHg; 8 in the range 26–30 mmHg; and 1 eye had 34 mmHg and required multiple AGM—no surgical intervention was needed. **Conclusion:** A secondary IOP spike post-IV ozurdex 0.7 mg seen in 18.62% of the cases require AGM. The IOP monitoring should be meticulously performed for the variations and secondary IOP spike management to prevent irreversible damage to the optic nerve and visual field.

Key words: AGM- Antiglaucoma medication, BRVO- Branch retinal vein occlusion, CME- Cystoid macular edema, CNVM- Choroidal neovascular membrane, CRVO- Central retinal vein occlusion, DME- Diabetic macular edema, IOP- Intraocular pressure, IV- Intravitreal, T/t- treatment

Intravitreal corticosteroids are effective for treating macular edema secondary to diabetes (diabetic macular edema, DME), retinal vein occlusion/branch retinal vein occlusion (CRVO/BRVO), non-infectious posterior uveitis, chronic/recurrent/refractory macular edema, cystoid macular edema (CME), and choroidal neovascularization^[1-6] but the effect on intraocular pressure (IOP) remains an important potential complication.

The use of intravitreal antiangiogenic agents or corticosteroids has become the first line of treatment in macular edema. A commonly recognized complication of intravitreal corticosteroid is the onset of secondary ocular hypertension and cataract formation. The secondary IOP spike may have early onset due to the increase of intravitreal volume and increased

resistance to the aqueous humor outflow as a secondary effect of steroid in the implant.

A sustained-release dexamethasone implant (ozurdex) is a biodegradable device inserted into the vitreal cavity via the transconjunctival approach using prefilled applicator/ inserter. The implant releases dexamethasone for up to 6 months. Ozurdex 0.7 mg was approved by the Food and Drug Administration in June 2009 and obtained European marketing authorization in July 2010 for the treatment of DME and macular edema due to retinal vein occlusion.

The dexamethasone intravitreal implant has been proven to be effective with reduced side effects compared

This is an open access journal, and articles are distributed under the terms of the Creative Commons Attribution-NonCommercial-ShareAlike 4.0 License, which allows others to remix, tweak, and build upon the work non-commercially, as long as appropriate credit is given and the new creations are licensed under the identical terms.

For reprints contact: WKHLRPMedknow_reprints@wolterskluwer.com

Cite this article as: Sweta VD, Shibi Dev BN, Sandhya R. Secondary glaucoma after intravitreal dexamethasone implant (Ozurdex) injection in patients with retinal disorder: A retrospective study. Indian J Ophthalmol 2022;70:585-9.

Access this article online

Website:

www.ijo.in

DOI:

10.4103/ijo.IJO_684_21

Quick Response Code:



Department of Glaucoma, Nethradhama Superspecialty Eye Hospital, Bangalore, Karnataka, India

Correspondence to: Dr. Shibi Dev BN, Reg No KMC- 56796, Senior Consultant and Head of Department Glaucoma, Nethradhama Superspecialty Eye Hospital, Jayanagar, Bangalore - 560 070, Karnataka, India. E-mail: drshibidev@gmail.com

Received: 31-Mar-2021

Revision: 22-Jul-2021

Accepted: 23-Sep-2021

Published: 27-Jan-2022

to other corticosteroids administered by intravitreal injection (triamcinolone and fluocinolone acetonide) in the onset of corticosteroid-induced hypertension.^[7-9] The implants demonstrated comparable efficacy for macular edema, lower cost, easier administration, and lower complication rates, especially secondary cataract, and glaucoma^[10] have led to its wider adoption.

Nevertheless, the risk of an IOP spike exists and remains a complication to monitor. The episodes of ocular hypertension are transient and reversible. Monitoring can help to limit the spikes in the pressure and prevent the risk of irreversible damage to the optic nerve and visual field. Pressure spike typically occurs by day 60 after injection.^[7] However, the periodicity for monitoring is poorly defined. The purpose of our study was to analyze the short-term changes in the IOP after intravitreal ozurdex implant in order to provide an appropriate monitoring scheme and early management of the IOP spike.

Methods

A retrospective, analytical study was conducted of the records of the patients receiving intravitreal injection of the dexamethasone implant (ozurdex) 0.7 mg for the treatment of DME, CME, macular edema due to retinal vein occlusion (CRVO and BRVO), chronic/recurrent/refractory macular edema, and choroidal neovascular membrane (CNVM). The study was conducted at a tertiary eye care hospital for 2 years; 6 months of follow-up data from the medical records were collected and analyzed. The study was approved by the ethics approval committee.

For the present study, the secondary IOP spike or ocular hypertension is defined as IOP >21 mmHg at any time point during the follow-up visits.

Pre-injection, all the patients received a complete ophthalmologic examination including best-corrected visual acuity (BCVA) using the standard early treatment diabetic retinopathy study chart (ETDRS chart), slit-lamp biomicroscopic examination of the anterior segment and fundus, IOP measurement using a non-contact air puff tonometer (Topcon non-contact tonometer; CT-800), color and monochromatic fundus photography, fluorescein angiography, and spectral-domain optical coherence tomography (SD-OCT) of the macular area (Spectralis HRA + OCT, Heidelberg Engineering, Heidelberg, Germany). Post the ozurdex injection, all the patients received measurement of BCVA, complete slit-lamp examination of the anterior segment and fundus, and IOP measurement by non-contact air puff tonometer (Topcon CT-800).

Data of all enrolled patients were collected from the medical records, IOP measurement recorded at baseline, day 1, 1 week, 1, 2, 3, 4, and 6 months post-injection.

Data of the patients receiving antiglaucoma medications and any secondary procedures for IOP reduction were recorded at the follow-up visits.

The primary endpoint was the percentage of eyes presenting with ocular hypertension >21 mmHg at the follow-up visits.

Inclusion criteria

The patients receiving intravitreal dexamethasone implant (ozurdex) 0.7 mg, for retinal disorder including CME,

DME, macular edema due to CRVO/BRVO, chronic/recurrent/refractory macular edema, and choroidal neovascularization in the specified period were included; 6 months follow-up data were analyzed for secondary IOP spike.

Exclusion criteria

The patients having pre-existing glaucoma and lost to follow-up were excluded from the study.

Statistical analysis

Data were entered into the Microsoft Excel datasheet and were analyzed using the SPSS 22 version software. Continuous data were represented as mean and standard deviation. An independent *t*-test was used as a test of significance to identify the mean difference between the two quantitative variables.

Graphical representation of data: MS Excel and MS Word were used to obtain the various types of graphs.

A *P* value (probability that the result is true) of <0.05 was considered statistically significant after assuming all the rules of the statistical tests.

Statistical software: MS Excel and SPSS version 22 (IBM SPSS Statistics, Somers NY, USA) were used to analyze the data.

Results

Demographics

About 102 eyes of 80 patients received the ozurdex injection in the specified period included in the study which had 48 males and 32 females.

The age range was from 53 to 83 years, the mean age was 66.81 ± 6.55 years.

Subgroups

According to the diagnosis, different subgroups are CME which includes 43 eyes, DME which includes 53 eyes, macular edema due to CRVO which includes 2 eyes, macular edema due to BRVO which includes 3 eyes, and CNVM which includes 1 eye [Table 1].

Mean IOP trend in different subgroups

For the CME patients, the mean baseline IOP was 14.83 ± 3.15 mmHg, post-ozurdex injection, the mean IOP at day 1 was 15.30 ± 3.39 mmHg, at 1 week was 15.39 ± 3.41 mmHg, at 1 month was 15.95 ± 3.54 mmHg, at 2 months was 16.09 ± 4.01 mmHg, at 3 months was 15.72 ± 3.25 mmHg, at 4 months was 15.72 ± 3.34 mmHg, and at 6 months was 14.72 ± 2.58 mmHg.

For the DME patients, the mean baseline IOP was 13.88 ± 2.85 mmHg, the post-injection mean IOP was 14.49 ± 2.83 mmHg at day 1, 14.75 ± 3.26 mmHg at 1 week, 15.75 ± 3.82 mmHg at 1 month, 16.09 ± 3.93 mmHg at 2 months,

Table 1: Subgroups with number of cases

Indication for ozurdex in retinal disorder	No. of eyes
Cystoid macular edema (CME)	43
Diabetic macular edema (DME)	53
Macular edema due to CRVO	2
Macular edema due to BRVO	3
Choroidal neovascular membrane (CNVM)	1

14.96 ± 3.33 mmHg at 3 months, 14.94 ± 3.34 mmHg at 4 months, and 13.73 ± 2.69 mmHg at 6 months.

For macular edema with CRVO patients, the mean baseline IOP was 15 ± 2.82 mmHg, the post-injection mean IOP was 16 ± 2.82 mmHg at day 1, 18 mmHg at 1 week, 17.5 ± 2.12 mmHg at 1 month, 18 mmHg at 2 months, 16.5 ± 0.7 mmHg at 3 months, 16.5 ± 0.7 mmHg at 4 months, and 16.5 ± 3.53 mmHg at 6 months.

For macular edema with BRVO patients, the mean baseline IOP was 16 ± 1.73 mmHg, the post-injection mean IOP was 18 ± 6.24 mmHg at day 1, 16 ± 2 mmHg at 1 week, 18 ± 2 mmHg at 1 month, 20.33 ± 4.5 mmHg at 2 months, 18.66 ± 5.03 mmHg at 3 months, 16.66 ± 3.05 mmHg at 4 months, and 15.66 ± 3.51 mmHg at 6 months.

For the CNVM patients, the mean baseline IOP was 17 mmHg, the post-injection mean IOP was 19 mmHg at day 1, 18 mmHg at 1 week, 18 mmHg at 1 month, 17 mmHg at 2 months, 14 mmHg at 3 months, 16 mmHg at 4 months, and 15 mmHg at 6 months.

According to the different subgroups, the IOP trend is shown in the graph which shows almost similar variation among the groups [Graph 1].

Mean IOP pre- and post-ozurdex injection

Collectively, the baseline mean IOP pre-ozurdex injection was 14.40 ± 2.97 mmHg, post-injection mean IOP was 15.01 ± 3.22 mmHg at day 1, 15.15 ± 3.28 mmHg at 1 week, 15.96 ± 3.62 mmHg at 1 month, 16.26 ± 3.95 mmHg at 2 months, 15.41 ± 3.33 mmHg at 3 months, 15.38 ± 3.28 mmHg at 4 months, and 14.27 ± 2.69 mmHg at 6 months. No statistically significant difference was seen at day 1 ($P = 0.1634$), 1 week ($P = 0.0869$), and 6 months ($P = 0.7488$). However, a statistically significant difference was seen at 1 month ($P = 0.0009$), 2 months ($P = 0.0001$), 3 months ($P = 0.0236$), and 4 months ($P = 0.0265$), which shows that the mean IOP is significantly increased at 1, 2, 3, and 4 months post-op [Table 2 and Graph 2].

Compared to the baseline mean post-op IOP increased by 0.61 mmHg at post-op day 1, 0.75 mmHg at 1 week, 1.56 mmHg at 1 month, 1.86 mmHg at 2 months, 1.01 mmHg at 3 months,

0.98 mmHg at 4 months, and reached the baseline level by post-op 6 months. The IOP spike is seen at 2 months [Graph 3].

IOP spike after ozurdex injection

About 19/102 (18.62%) eyes showed IOP spike post-treatment out of which four eyes had multiple spikes at various follow-ups; 4 (3.92%) eyes showed IOP spike at day 1, 3 (2.94%) eyes at 1 week, 6 (5.88%) eyes at 1 month, 7 (6.86%) eyes at 2 months, 3 (2.94%) eyes at 3 months, and 2 (1.96%) eyes at 4 months. No spike was seen at 6 months. The maximum number of eyes showing the IOP spike was seen at 2 months [Graph 4].

Sixteen eyes showed IOP rise in the range of 22–25 mmHg, 8 in the range of 26–30 mmHg, and 1 eye showed an IOP rise of 34 mmHg and required multiple AGM. No surgical intervention for secondary glaucoma was needed in the study.

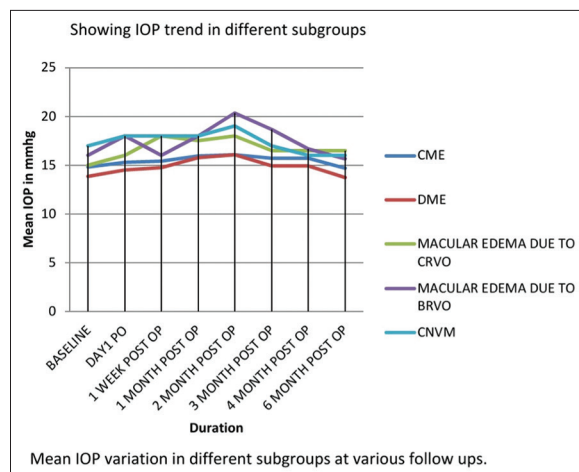
About 16/102 (15.58%) eyes showed mild to moderate IOP drop (mean 2.5 mmHg) at immediate post-op day 1, among which 7 eyes had 1–2 mmHg drop, 9 eyes had 3–4 mmHg drop, which may be attributed to the slight vitreous loss by reflux through the scleral orifice of injection. No major drop in the IOP was seen.

Discussion

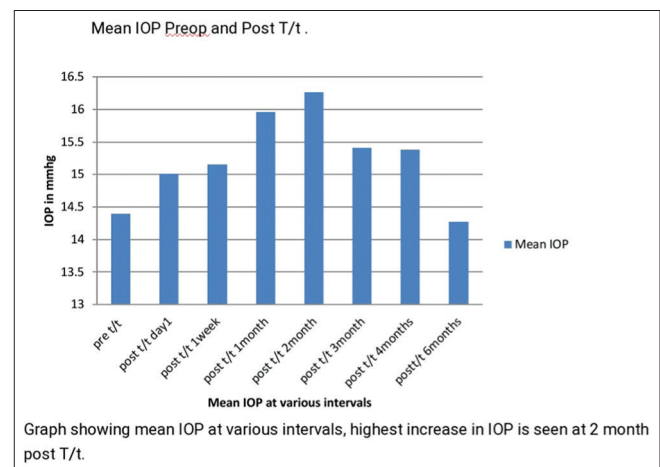
In the present study, no statistically significant difference was seen between the mean IOP pre- and post-op at day 1 ($P = 0.1634$), 1 week ($P = 0.0869$), and 6 months ($P = 0.7488$). However, a statistically significant difference seen at 1 month ($P = 0.0009$), 2 months ($P = 0.0001$), 3 months ($P = 0.0236$), and 4 months ($P = 0.0265$), which shows that the IOP was significantly increased at post-op 1, 2, 3, and 4 months.

The mean IOP was at the peak at 2 months recovered to the baseline by 6 months. The results are consistent with those of the GENEVA study.^[7] A post-op increase of IOP was attributed to the secondary effect of steroid in the implant. Similar studies by Haller et al.^[7] and Boyer et al.^[11] show the maximum increase in IOP at 2 months with dexamethasone implant return to the baseline by 6 months.^[12,13] This corresponds to the result in the present study.

In the present study, the subgroups showed almost similar IOP variation with a spike by 2 months reach baseline by 6 months. The result is consistent with the other studies in the



Graph 1: Line diagram showing mean IOP variation in different subgroups at various follow ups with IOP spike seen at 2 month

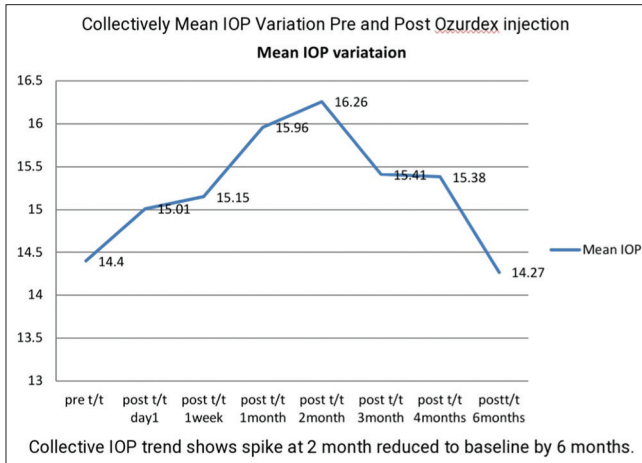


Graph 2: Bar diagram showing collective mean IOP at various follow ups. Highest increase is seen at 2 month post T/t

Table 2: Mean IOP pre- and post-ozurdex injection

	Baseline	Day 1	1 week	1 month	2 months	3 months	4 months	6 months
Mean post-op IOP in mmHg	14.40±2.97	15.01±3.22	15.15±3.28	15.96±3.62	16.26±3.95	15.41±3.33	15.38±3.28	14.27±2.69
P*		0.1634	0.0869	0.0009	0.0001	0.0236	0.0265	0.7488

*No statistical significant difference seen at day 1 ($P=0.1634$), 1 week ($P=0.0869$), and 6 months ($P=0.7488$). *Statistically significant difference seen in mean post-op IOP compared to pre-op mean IOP at 1 month ($P=0.0009$), 2 months ($P=0.0001$), 3 months ($P=0.0236$), and 4 months ($P=0.0265$)



Graph 3: Line diagram showing collective mean IOP variation with spike at 2 month reduce to baseline by 6 months

literature by Haller *et al.*; Ozurdex GENEVA Study Group;^[7] Boyer *et al.*; Ozurdex CHAMPLAIN Study Group;^[11] Haller *et al.*; the Dexamethasone DDS Phase II Study Group^[13] shows that the maximum increase in the IOP (IOP spike) occurs 60 days (2 months) after the injection, with a return to baseline IOP levels within 6 months.

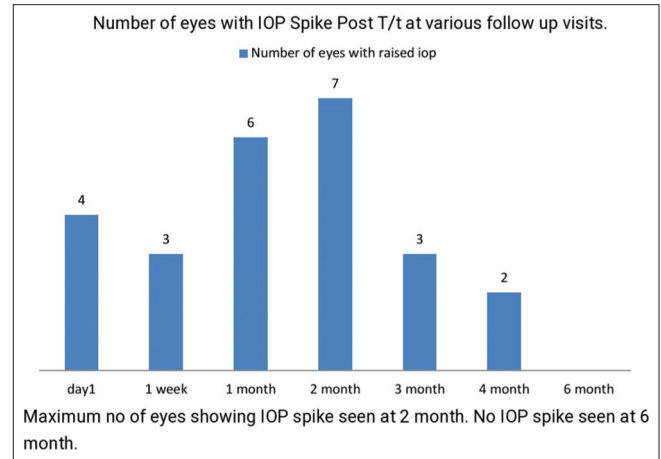
For ozurdex in the eyes with retinal vein occlusion, the GENEVA group observed elevated IOP most commonly at the visit 60 days post-treatment. This elevation resolved in the majority by 6 months.^[5]

Boyer *et al.*, in the Ozurdex MEAD Study Group,^[14] another randomized, controlled trial reporting 3-year results of ozurdex for DME, the mean IOP following retreatment every 6 months (as indicated, mean 4.1 or 4.4 injections over 3 years for 0.35 and 0.7 mg, respectively) peaked between months 2 and 3 and decayed to near baseline by month 6, following a similar pattern after each injection.

In the present study, the IOP spike was seen in 18.62% of the cases which corresponds to the results of some of the previous studies. Haller *et al.*, Ozurdex GENEVA Study Group,^[7] show IOP spike around 16% of cases. In a meta-analysis by Kiddee *et al.*,^[15] after 0.7-mg dexamethasone implants for DME, 14.9% (95% CI 10.2–21.3) of the eyes developed Ocular Hypertension.

The Haller *et al.*^[5] study group showed 4% of the eyes with retinal vein occlusion developed OHT following a single 0.7-mg ozurdex injection at 12 months, however, during the second treatment, 33% of those receiving 0.7 mg exhibited elevated IOP.

In the present study, 19 out of 102 (18.62%) eyes showed secondary IOP spike which included 8 eyes with CME, 9



Graph 4: Bar diagram showing number of eyes with IOP spike post T/t, maximum number of eyes showing IOP spike seen at 2 month, no IOP spike seen at 6 month

eyes with DME, and 2 eyes with BRVO showed IOP greater than 21 mmHg and required multiple AGM. No surgical intervention was needed for any patient. These results are consistent with the GENEVA study in the literature showing that ocular hypertension was well-controlled with local antihypertensive treatment and no filtering surgery was required.^[7]

Several risk factors for the corticosteroid-induced ocular hypertension are young age (<45 years), severe myopia, pre-existing glaucoma, family history of glaucoma, type 1 diabetes, moderate ocular hypertension, and collagen diseases.^[16] In the case of intravitreal injections, the other risk factors seen are IOP \pm 15 mmHg,^[17,18] history of glaucoma and ocular hypertension.^[15-17,19] In the present study, among the 102 eyes, 53 eyes had diabetic macular edema, 43 had CME, 2 eyes had macular edema due to CRVO, and 3 eyes had BRVO, 1 with CNVM showed a high incidence of glaucoma in diabetics, retinal vein occlusion, post-intraocular surgery which emphasized the need for regular monitoring of the IOP, especially when the IV dexamethasone injection was given.

The dexamethasone intravitreal implant is effective in the eye for several months. It has been proven to be effective from the functional standpoint, with reduced side effects compared to the other corticosteroids administered by the intravitreal injection (triamcinolone and fluocinolone acetonide) such as the onset of corticosteroid-induced hypertension^[7-9] and lower complication rates, especially secondary cataract and glaucoma.^[10]

Nevertheless, the risk of the IOP spike/secondary ocular hypertension exists and remains a complication to monitor. The

episodes of ocular hypertension are transient and reversible. Monitoring can help to implement treatment in order to limit the spikes in the pressure and prevent the risk of irreversible damage to the optic nerve and visual field.

Conclusion

Secondary IOP spike/ocular hypertension after intravitreal injection of dexamethasone implant is seen in 18.62% of the cases which required treatment in the form of antiglaucoma medications. Secondary IOP spike was seen as a real complication in some patients requiring special monitoring for early detection and management. The IOP monitoring should be meticulously performed at each follow-up visit, especially in the initial 6 months for IOP variations and secondary IOP spike management.

Limitations of study

Study is retrospective conducted on a small percentage of population (102 eyes) which may bias the results. follow-up is of short duration, long-term follow-up needed to confirm the risk of corticosteroid-induced ocular hypertension for long-term IOP variation.

Pre-existing glaucoma patients were excluded in whom IOP variation may be different.

Risk factors for glaucoma are not evaluated.

Profile of increased IOP after repeated ozurdex implant injections is not evaluated.

Acknowledgments

The authors would like to thank Dr. Sri Ganesh (Chairman and Managing director of Nethradhama hospital PVT. Ltd, HOD Phaco Refractive Department) and Nethradhama Superspeciality Eye Hospital for general support for conducting the research.

Financial support and sponsorship

Nil.

Conflicts of interest

There are no conflicts of interest.

References

- Atmaca LS, Yalcindag FN, Ozdemir O. Intravitreal triamcinolone acetonide in the management of cystoid macular edema in behcet's disease. *Graefes Arch Clin Exp Ophthalmol* 2007;245:451-6.
- Callanan DG, Jaffe GJ, Martin DF, Pearson PA, Comstock TL. Treatment of posterior uveitis with a fluocinolone acetonide implant: Three-year clinical trial results. *Arch Ophthalmol* 2008;126:1191-201.
- Chaudhary V, Mao A, Hooper PL, Sheidow TG. Triamcinolone acetonide as adjunctive treatment to verteporfin in neovascular age-related macular degeneration: A prospective randomized trial. *Ophthalmology* 2007;114:2183-9.
- Chieh JJ, Roth DB, Liu M, Belmont J, Nelson M, Regillo C, *et al.* Intravitreal triamcinolone acetonide for diabetic macular edema. *Retina* 2005;25:828-34.
- Haller JA, Bandello F, Belfort R Jr, Blumenkranz MS, Gillies M, Heier J, *et al.* Dexamethasone intravitreal implant in patients with macular edema related to branch or central retinal vein occlusion twelve-month study results. *Ophthalmology* 2011;118:2453-60.
- Jaffe GJ, Martin D, Callanan D, Pearson PA, Levy B, Comstock T; Fluocinolone Acetonide Uveitis Study Group. Fluocinolone acetonide implant (retisert) for non-infectious posterior uveitis: Thirty-four-week results of a multicenter randomized clinical study. *Ophthalmology* 2006;113:1020-7.
- Haller JA, Bandello F, Belfort R Jr, Blumenkranz MS, Gillies M, Heier J, *et al.*; OZURDEX GENEVA Study Group. Randomized, sham-controlled trial of dexamethasone intravitreal implant in patients with macular edema due to retinal vein occlusion. *Ophthalmology* 2010;117:1134-46.e3.
- Rhee DJ, Peck RE, Belmont J, Martidis A, Liu M, Chang J, *et al.* Intraocular pressure alterations following intravitreal triamcinolone acetonide. *Br J Ophthalmol* 2006;90:999-1003.
- Goldstein DA, Godfrey DG, Hall A, Callanan DG, Jaffe GJ, Pearson PA, *et al.* Intraocular pressure in patients with uveitis treated with fluocinolone acetonide implants. *Arch Ophthalmol* 2007;125:1478-85.
- Arcinue CA, Ceron OM, Foster CS. A comparison between the fluocinolone acetonide (Retisert) and dexamethasone (Ozurdex) intravitreal implants in uveitis. *J Ocul Pharmacol Ther* 2013;29:501-7.
- Boyer DS, Faber D, Gupta S, Patel SS, Tabandeh H, Li XY, *et al.*; Ozurdex CHAMPLAIN Study Group. Dexamethasone intravitreal implant for treatment of diabetic macular edema in vitrectomized patients. *Retina* 2011;31:915-23.
- Haller JA, Dugel P, Weinberg DV, Chou C, Whitcup SM. Evaluation of the safety and performance of an applicator for a novel intravitreal dexamethasone drug delivery system for the treatment of macular edema. *Retina* 2009;29:46-51.
- Haller JA, Kuppermann BD, Blumenkranz MS, Williams GA, Weinberg DV, Chou C; Dexamethasone DDS Phase II Study Group. Randomized controlled trial of an intravitreal dexamethasone drug delivery system in patients with diabetic macular edema. *Arch Ophthalmol* 2010;128:289-96.
- Boyer DS, Yoon YH, Belfort R Jr, Bandello F, Maturi RK, Augustin AJ, *et al.*; Ozurdex MEAD Study Group. Three-year, randomized, sham-controlled trial of dexamethasone intravitreal implant in patients with diabetic macular edema. *Ophthalmology* 2014;121:1904-14.
- Kiddee W, Trope GE, Sheng L, Beltran-Agullo L, Smith M, Strungaru MH, *et al.* Intraocular pressure monitoring post intravitreal steroids: A systematic review. *Surv Ophthalmol* 2013;58:291-310.
- Clark AF. Basic sciences in clinical glaucoma: Steroids, ocular hypertension, and glaucoma. *J Glaucoma* 1995;4:354-69.
- Vasconcelos-Santos DV, Nehemy PG, Schachat AP, Nehemy NB. Secondary ocular hypertension after intravitreal injection of 4 mg of triamcinolone acetonide: Incidence and risk factors. *Retina* 2008;28:573-80.
- Smithen LM, Ober MD, Maranan L, Spaide RF. Intravitreal triamcinolone acetonide and intraocular pressure. *Am J Ophthalmol* 2004;138:740-3.
- Roth DB, Verma V, Realini T, Prenner JL, Feuer WJ, Fechtner RD. Long-term incidence and timing of intraocular hypertension after intravitreal triamcinolone acetonide injection. *Ophthalmology* 2009;116:455-60.