

Acute sensorineural hearing loss as atypical presentation of typhoid fever in adult patient

SAGE Open Medical Case Reports
Volume 8: 1–4
© The Author(s) 2020
Article reuse guidelines:
sagepub.com/journals-permissions
DOI: 10.1177/2050313X20958548
journals.sagepub.com/home/sco



Khaled Al Khodari¹ , Tehniyat Baig²,
Mohammad Husni Alkhateeb¹ and Muhammad Naeem¹

Abstract

Salmonella Typhi is the main cause of an acute febrile, sometimes fatal, multisystemic illness called typhoid fever. The diverse presentations of this disease make it a diagnostic challenge in some patients. Involvement of the neurological system, including cochleovestibular system, is very rare with less than a handful of reported cases. This case report describes the condition of a previously healthy 23-year-old Pakistani man with acute onset of hearing loss associated with fever, headache, and disorientation. The most likely differential diagnoses were bacterial or viral meningoencephalitis, and other bacterial infections, such as Rickettsial and spirochetal diseases. *Salmonella Typhi* grew on blood culture; thus, treatment with intravenous antibiotics and systemic steroids was provided with excellent response. Hearing loss gradually improved and almost completely resolved within 3 to 4 weeks.

Keywords

Salmonella Typhi, typhoid fever, hearing loss, atypical, adult

Date received: 1 February 2020; accepted: 24 August 2020

Background

In most patients, typhoid fever manifests as the classical presentation that usually begins with a high-grade fever, bacteremia, and constipation during the first week, then followed by abdominal pain, diarrhea, and sometimes hepatosplenomegaly and intestinal bleeding. Intestinal perforation occasionally occurs during the second and third weeks, if not treated.¹ Yet, if these patients are detected early and treated with appropriate antibiotics, the disease course is usually benign and life-threatening complications are rare.

Nonetheless, atypical presentations are rising. In a case series from India, 15 (46.9%) out of 32 patients presented with atypical manifestations, including burning micturition, early-onset diarrhea in the first week, early encephalopathy, liver or splenic abscess, pneumonitis, cerebellar ataxia, and even acute psychiatric disorders, such as schizophrenia.² Acute sensorineural hearing loss is a very rare presentation of typhoid fever. It has been reported only in a few cases, most of them being children, which was followed by complete restoration of hearing after appropriate treatment.³ However, permanent hearing loss has also been reported.⁴

Although the exact mechanism of hearing loss in typhoid fever is still unknown, a study on six cases of pathologically confirmed cochleovestibular lesions caused by typhoid fever

found that factors such as host susceptibility, endotoxins, arteritis, and ischemia can significantly contribute to the development of these lesions.³ In another case, mastoid abscess culture was positive for *Salmonella Typhi* in a patient with typhoid fever indicating that the microorganism itself can cause direct injury to cochleovestibular system.⁵

This highlights the importance of being aware of atypical presentations in order to avoid any delay in accurate diagnosis and prompt appropriate treatment, thus preventing progression of hearing loss potentially due to cochleovestibular lesions as well as minimizing the risk of further serious complications caused by typhoid fever

Case presentation

A 23-year-old Pakistani male biomedical engineer, with no significant past or present medical history, presented to the

¹Department of Internal Medicine, Hamad Medical Corporation (HMC), Doha, Qatar

²Weill Cornell Medicine–Qatar, Doha, Qatar

Corresponding Author:

Khaled Al Khodari, Department of Internal Medicine, Hamad Medical Corporation (HMC), P.O. Box 3050, Doha, Qatar.

Email: kalkhodari@hamad.qa



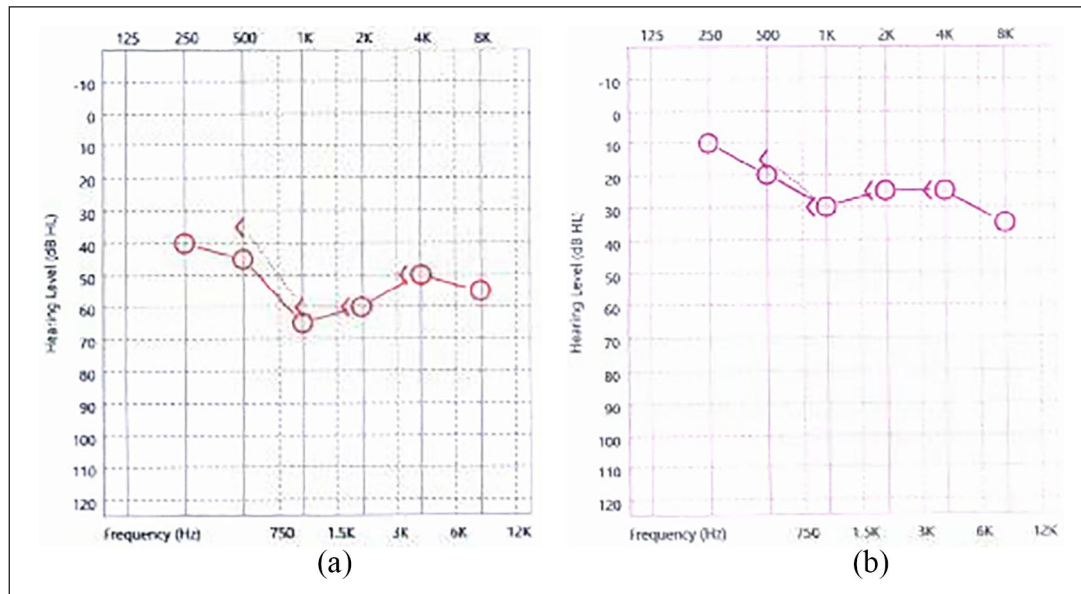


Figure 1. (a) Moderately severe sensorineural hearing loss affecting almost all frequencies upon admission. (b) Significant improvement with mild hearing loss affecting only high frequencies after 15 days in outpatient clinic.

emergency department (ED) with a 3-day history of severe hearing loss that was associated with fever and disorientation. The patient appeared anxious and agitated due to his apparent hearing impairment based on his father. According to him, the patient had reported a history of fever, worsening headache, neck pain, and flu-like symptoms 7 days prior to his presentation. It was treated as an upper respiratory tract infection with minimal improvement. One week before his presentation, he returned to Qatar after a short vacation in Islamabad, Pakistan, with a history of eating local food from roadside stalls. He denied hiking, camping, tick bites, mosquito bites, exposure to lice, mites, animals, and their body fluids.

His father also reported that the patient had diarrhea and abdominal pain while in Pakistan, 10 days prior to his presentation, but without nausea or vomiting. The patient denied history of earache, ear discharge, tinnitus, recent upper respiratory tract infection, vertigo, and dizziness. He denied history of smoking, alcohol intake, and illicit drug use.

In the ED, he was febrile with an oral temperature of 38.9°C, pulse rate of 95 beats/min, respiratory rate of 20 breaths/min, and blood pressure of 115/67 mmHg. Upon physical examination, the patient appeared anxious and disoriented to place. He also showed bilateral impaired hearing ability, raising his voice in order to communicate and struggling to hear questions from the medical team. Otherwise, systematic examination was normal.

Initial investigation showed mild thrombocytopenia with normal white blood cell count and hemoglobin level. He had mild elevation in creatinine at 162 $\mu\text{mol/L}$ (normal <100 $\mu\text{mol/L}$), hyponatremia at 127 mmol/L (normal range 135–145 mmol/L), elevated serum alanine aminotransferase (ALT) at 134 U/L (normal <41 U/L), elevated serum aspartate aminotransferase (AST) at 240 U/L (normal <40 U/L),

and elevated C-reactive protein (CRP) at 185 mg/L (normal <10 mg/L). Alkaline phosphatase (ALP) and total bilirubin were normal. Malaria screening was negative. Initial imaging with chest X-ray and head CT (computed tomography) were normal.

Acute meningitis with or without encephalitis was the top differential diagnosis; lumbar puncture (LP) failed in the ED due to the patient's agitation and non-cooperation. Intravenous normal saline and empirical antibiotics (ceftriaxone 2 g every 12 h, vancomycin 1 g/day, and acyclovir 750 mg every 8 h) were initiated after sending cultures and investigations for sepsis workup. Intravenous dexamethasone (initial loading dose of 3 mg/kg, then 1 mg/kg every 6 h) was also added to the regimen, then shifted to oral prednisolone (60 mg/day) after 2 days.

Pure tone audiometry (PTA) was performed at presentation and 15 days later in the outpatient clinic. The result from the left ear audiometry is shown in Figure 1. It showed moderate bilateral sensorineural hearing loss, to nearly all frequencies during his inpatient admission (shown in Figure 1(a)). PTA was repeated after 15 days and showed marked improvement with mild hearing loss only to high frequencies (shown in Figure 1(b)). Tympanometry and tone decay test were normal upon admission.

One day after admission, the patient's blood culture demonstrated growth of *Salmonella* Typhi. Due to the high prevalence of extensively drug-resistant (XDR) strains in Pakistan, antibiotics were changed to meropenem (2 g every 8 h) and azithromycin (500 mg/day) to ensure coverage of possible drug-resistant strains. According to the World Health Organization (WHO), 5274 (64.4%) cases of XDR typhoid fever were reported out of 8188 typhoid fever cases from 1 November 2016 to 9 December 2018 in Pakistan.⁶ The XDR

strains of *Salmonella* Typhi have shown resistance to first- and second-line antibiotics (e.g. fluoroquinolones) as well as third-generation cephalosporins (e.g. ceftriaxone).^{7,8} Therefore, current treatment options for Pakistani XDR strains of *Salmonella* Typhi are limited to oral azithromycin, and intravenous meropenem or tigecycline.⁹

Two days after admission, blood culture sensitivity results showed *Salmonella* Typhi sensitive to ceftriaxone but resistant to ciprofloxacin. Therefore, antibiotics were de-escalated to intravenous ceftriaxone only, to complete the total duration of 14 days of antibiotics. Head MRI (magnetic resonance imaging) was normal and fluoroscopic guided LP was performed; results showed high protein level without leukocytosis. Cerebrospinal fluid (CSF) culture and viral screen, including herpes simplex viruses, were negative. Workup for tuberculosis from sputum and CSF was negative. Urine analysis and microscopy were normal.

Clinically, the patient improved quite rapidly; fever subsided and hearing loss gradually improved 5 days after the treatment had commenced. The patient's hearing loss continued to improve and almost completely resolved by the end of the first month of treatment. Audiometry was not done after 1 month because the patient had traveled back to his home country and was thus contacted over the phone. Oral prednisolone was gradually tapered down from 60 mg/day and stopped within 3 weeks.

Discussion

The classic presentation of typhoid fever has been changing over the last few years, and the frequency of cases with atypical presentation, like sensorineural hearing loss reported here, has risen accordingly.² Many factors are implicated. According to one study from India, inappropriate use of antibiotics with regard to both type and duration, and MDR (multidrug resistant) and XDR strains play an important role.²

According to an epidemiologic investigation of a typhoid fever outbreak in Malawi–Mozambique in 2009, neurological presentations of typhoid fever have been reported in 40 (13%) out of 303 patients with typhoid fever. Out of those 40 patients, 27 (68%) were hospitalized, 17 (43%) had upper motor neuron signs (e.g. hyperreflexia, ankle clonus, or spasticity), and 5 (13%) died. Other neurological findings included ataxia in 22 (55%), early encephalopathy in 15 (38%), subjective hearing loss in 9 (23%), parkinsonism in 8 (20%), and tremor in 4 (10%) cases. Two patients demonstrated continued symptoms when reassessment was done after 11 months on hospitalized patients.¹⁰

Most cases of acute sensorineural hearing loss are idiopathic. Viral infections are implicated, but bacterial causes, like *Salmonella* Typhi, are very rare.⁷ In a literature review of six cases of pathologically confirmed cochleovestibular lesions due to typhoid fever in adult patients, most cases happened during the second week, five of the six patients were female, and the left ear was more often affected.³ In

our case, hearing loss was worse in the left ear and started during the second week with gradual improvement 5 days after starting antibiotics, until complete recovery was achieved after around 1 month.

The best treatment for sensorineural hearing loss caused by typhoid fever is to treat the infection itself with effective antibiotics. This is especially important in patients who acquired the disease in endemic areas, like our patient. There is a paucity of data on the use of systemic steroids in typhoid fever. However, according to a randomized controlled trial conducted in Indonesia, the addition of high-dose dexamethasone to chloramphenicol for 48 h was associated with a significant reduction in case fatality rate compared to chloramphenicol alone (10% versus 55%). Furthermore, the use of adjunctive dexamethasone did not increase the risk of treatment complications or side effects in a patient with severe typhoid fever, which was defined as bacteremia associated with decreased level of consciousness, disorientation, obtundation, or coma.⁸

Although the benefit of adjunctive dexamethasone in addition to antibiotics is still unclear, due to the ability of systemic steroids to reduce inflammation and edema in the hearing organs, they are commonly used in patients with acute sensorineural hearing loss in order to cover possible idiopathic acute inflammation of the labyrinth or cochlear nerve.^{11,12} The total recommended duration of adjunctive steroids is up to 6 weeks, with little chance of success beyond this time.¹³ Our patient was started on oral prednisolone upon admission and tapered over 3 weeks. Near complete recovery was achieved in 1 month.

Conclusion

We reported this case to highlight the possibility of a rare presentation of typhoid fever, such as acute sensorineural hearing loss. It is of utmost importance for physicians to be aware of such presentations, and to consider including typhoid fever in their differentials in order to avoid delaying accurate diagnosis and prompt appropriate antibiotic treatment, all of which is crucial in preventing severe complications and achieving rapid recovery.

Acknowledgements

We would like to express our thanks and appreciation to the Internal Medicine Residency Program for supporting their residents' research projects and to Qatar National Library (QNL) for funding this project.

Author contributions

Khaled Al Khodari, Tehniyat Baig, and Mohammad Husni Alkhateeb helped in manuscript writing and editing, and Muhammad Naeem contributed to clinical management and was a final reviewer.

Declaration of conflicting interests

The author(s) declared no potential conflicts of interest with respect to the research, authorship, and/or publication of this article.

Ethical approval

Ethical approval to report this case was obtained from Hamad Medical Corporation (HMC) Ethics Committee named ABHATH: ID number MRC-04-19-410.

Funding

The author(s) disclosed receipt of the following financial support for the research, authorship, and/or publication of this article: This article will be funded by Qatar National Library (QNL) after approval.

Statement of ethics

Written consent was taken from the patient. Study protocol was approved by the institute's committee on human research.

Informed consent

Written and verbal informed consents were obtained from the patient(s) for their anonymized information to be published in this article.

ORCID iD

Khaled Al Khodari  <https://orcid.org/0000-0003-0437-8003>

References

1. Typhoid fever clinical presentation: history, physical, causes <https://emedicine.medscape.com/article/231135-clinical> (11 November 2019, accessed 7 July 2020).
2. Dutta TK, Beerasha and Ghotekar LH. Atypical manifestations of typhoid fever. *J Postgrad Med* 2001; 47(4): 248–251.
3. Escajadillo JR, Alatorre G and Zárate A. Typhoid fever and cochleovestibular lesions. *Ann Otol Rhinol Laryngol* 1982; 91(2 Pt 1): 220–224.
4. Faucher B, Zaegel O, Niang A, et al. Surdit e d efinitive au d ecours d'une fi evre typho ide une observation a Dakar (S en egal) [Permanent deafness following typhoid fever: case report from Dakar, Senegal]. *Med Trop* 2009; 69(1): 73–74.
5. Majlesi H, Naderi A, Azar FA, et al. Mastoid abscess in a patient with typhoid fever. *J Indian Med Assoc* 1978; 70(10): 229.
6. World Health Organization. Typhoid fever—Islamic Republic of Pakistan, <https://www.who.int/csr/don/27-december-2018-typhoid-pakistan/en/> (27 December 2018, accessed 7 July 2020).
7. Chau JK, Lin JR, Atashband S, et al. Systematic review of the evidence for the etiology of adult sudden sensorineural hearing loss. *Laryngoscope* 2010; 120(5): 1011–1021.
8. Hoffman SL, Punjabi NH, Kumala S, et al. Reduction of mortality in chloramphenicol-treated severe typhoid fever by high-dose dexamethasone. *N Engl J Med* 1984; 310(2): 82–88.
9. Akram J, Khan AS, Khan HA, et al. Extensively drug-resistant (XDR) typhoid: evolution, prevention, and its management. *Biomed Res Int* 2020; 2020: 6432580.
10. Sejvar J, Lutterloh E, Naiene J, et al. Neurologic manifestations associated with an outbreak of typhoid fever, Malawi–Mozambique, 2009: an epidemiologic investigation. *PLoS ONE* 2012; 7(12): e46099.
11. Wei BP, Stathopoulos D and O'Leary S. Steroids for idiopathic sudden sensorineural hearing loss. *Cochrane Database Syst Rev* 2013; 7: CD003998.
12. Chen WT, Lee JW, Yuan CH, et al. Oral steroid treatment for idiopathic sudden sensorineural hearing loss. *Saudi Med J* 2015; 36(3): 291–296.
13. Stachler RJ, Chandrasekhar SS, Archer SM, et al. Clinical practice guideline: sudden hearing loss. *Otolaryngol Head Neck Surg* 2012; 146(3 Suppl): S1–S35.