

# Rupture of Hepatocellular Carcinoma into the Biliary System with Resulting Bile Duct Thrombi: Report of Two Cases

P. Bigot G.M. Buchanan A. Hamy C. Teyssedou  
P. Pessaux J.P. Arnaud

Department of Visceral Surgery, Angers, France

## Key Words

Hepatocellular carcinoma, rupture · Bile duct thrombi · Obstructive jaundice

## Abstract

We report two cases of hepatocellular carcinoma revealed by jaundice and the presence of free-floating tumoural fragments within the biliary system. Two men (one of 64 and one of 73) presented with isolated jaundice. The results from ultrasound, CT and MRI were suggestive of a cholangiocarcinoma. Surgical intervention demonstrated bile duct thrombi from the primary tumour causing obstructive jaundice.

## Introduction

Intrahepatic invasion of hepatocellular carcinoma (HCC) into the portal vein and its branches (especially portal vein thrombi) is a relatively well-documented phenomenon and is widely accepted as 'normal' and 'acceptable' behaviour for HCC. Esaki et al. [1] and Stuart et al. [2] report 34–40% incidence of portal vein invasion in autopsy series whereas Le Treut et al. [3] reported 65%. It is also possible for the tumour to invade into the hepatic veins and even the inferior aspect of the IVC although this always occurs with accompanying portal vein involvement. Incidence of this is 23% [3, 4].

Bile duct invasion is also a possibility though far rarer than vessel involvement. The incidence of bile duct invasion is significantly less at 1.66–9% [5, 6]. This rare phenomenon can present with obstructive jaundice, haemobilia and free-floating tumour debris in the biliary tree. We report two such cases.

## Patient 1

A 64-year-old male was admitted to hospital presenting with isolated jaundice. He presented with no other complaints and seemed to be in good general health with no pain, abdominal distention, fever or pruritis. On clinical examination, there were no signs of hepatomegaly, splenomegaly, portal hypertension or haemorrhage (melaena or rectal bleeding) and therefore nothing suggestive of HCC.

Investigations showed a total bilirubin of 108  $\mu\text{mol}$  (normal <17  $\mu\text{mol}$ ), a conjugated bilirubin of 74  $\mu\text{mol}$  (normal <4  $\mu\text{mol}$ ),  $\gamma$ -glutamyl transpeptidase of 305 U/l (normal <36) and alkaline phosphatase of 570 IU/l (normal <90). All other tests carried out were normal including blood count, coagulation screen and tumour markers (CEA, CA 19-9 and  $\alpha$ -fetoprotein). Serology for hepatitis B and C was negative. There was no argument for non-alcoholic steatohepatitis syndrome.

Abdominal ultrasound showed dilatation of both the right and left hepatic ducts. The rest of the biliary tree including the common hepatic duct appeared normal. The gallbladder and pancreas were also normal.

Abdominal computed tomography (CT) showed dilatation of both the right and left hepatic ducts and a tumour-like lesion where these two structures converged ([fig. 1](#)). Opacification of the bile ducts showed a net dilatation of the left intrahepatic bile ducts and a weak main bile duct above the cystic duct ([fig. 2](#)). The common bile duct and gallbladder were normal. The diagnosis was that of cholangiocarcinoma at the convergence of the bile ducts.

During surgery it could be seen that the liver was cholestatic and non-cirrhotic. A cholecystectomy, cholangiography and then a choledochectomy were performed. A blood clot was found lodged in the common hepatic duct at the convergence of the right and left hepatic ducts. Endoscopic exploration of the biliary system was normal. A histopathological examination was carried out on the clot and revealed the presence of fragments of HCC. Biopsy showed a non-cirrhotic, cholestatic liver.

Postoperatively, further tests including arteriography with injection of lipiodol and CT scanning were performed in the third week and both were normal. A radiological examination assessing the efficacy of the drain left in place during surgery showed disorganisation and rupture of a bile duct in the right lateral branch. MRI confirmed the presence of a lesion measuring 3 cm in the eighth segment.

A right hepatectomy was then carried out, which showed a well-differentiated HCC without vascular invasion measuring 3  $\times$  3 cm with an endoluminal bud in an ulcerated bile duct ([fig. 3](#)).

The patient was reviewed 37 months later with no signs of recurrence on clinical examination or on ultrasound.

## Patient 2

A 73-year-old male was admitted to hospital presenting with jaundice which had first occurred suddenly three weeks before admission. On clinical examination, he appeared to be in good general health despite jaundice in the skin and mucous membranes with no accompanying fever, pain or pruritis. Investigations revealed a total bilirubin of 450  $\mu\text{mol}$ ,  $\gamma$ -glutamyl transpeptidase of 983 U/l and alkaline phosphatase of 366 U/l.  $\alpha$ -Fetoprotein was elevated at 43 ng/ml (normal <6) whereas other tumoural markers were within the normal ranges. Serology for hepatitis B and C was negative.

Ultrasound revealed dilatation of the hepatic ducts which were hypoechoic in nature. An abdominal and pelvic CT confirmed the presence of a tumour-like lesion in segments VII and VIII with dilatation of the hepatic ducts. The left appeared more significantly dilated due to a suspected cholangiocarcinoma. MRI confirmed the presence of masses in the ducts of segment VIII suggestive of a cholangiocarcinoma with stenosis of about 2 cm above the common bile duct.

During surgery, it could be seen that the liver was cholestatic and non-cirrhotic. A cholecystectomy and cholangiography were performed which showed the contrast passing adequately through into the duodenum but a mass in the hepatic duct. The margins of the mass were hazy, suggestive of neoplastic thrombi. A choledochectomy was performed which allowed the extent of destruction of the right and left hepatic ducts to be seen. Endoscopic examination of the biliary system was normal. A Kehr drain was inserted into the bile ducts. An anatomo-pathological exam confirmed that the thrombi were indeed fragments of HCC.

After surgery, all values returned to normal and postoperative cholangiography confirmed normal right and left hepatic ducts with no evidence of obstruction. Chemoembolisation was carried out 6 weeks after surgery involving a right hepatectomy. Histological examination of the resection specimen confirmed the diagnosis of a well-differentiated HCC, with vascular invasion, Edmonson's grade 2, measuring  $2.5 \times 2.5 \times 2$  cm.

A CT scan showed multifocal liver recurrence 18 months after the right hepatectomy. The  $\alpha$ -fetoprotein maker was elevated at 172 ng/ml (normal <6). The patient died two years after resection.

## Discussion

Although it is relatively common, HCC is a condition with a grim prognosis. However, these cases are further complicated by the involvement of the biliary system due to tumour rupture and therefore care must be taken to avoid reaching the wrong diagnosis.

Jaundice can occur for many reasons and therefore the list of differential diagnoses is long and includes such conditions as hepatitis infection, cirrhosis, haemolytic anaemia, autoimmune hepatitis, malaria, biliary atresia, biliary tract carcinoma and choledocholithiasis [7, 8]. Also included is HCC though this is considered rare and it is even rarer for jaundice to be the main presenting complaint. Jaundice is only present in 19–40% of patients with HCC on diagnosis [7]. In cases like this however, the jaundice can either occur from massive destruction of the hepatocytes and other liver parenchyma, from liver cirrhosis [6, 9] or from mechanical obstruction. Obstruction due to formation of clots or the tumour is quite rare and is only seen in 2.3 to 13% in surgery and autopsy cases [1]. It is important to remember that fragments are not always free-floating and that some can adhere to the walls of the ducts. If this is the case, care must be taken when removing them so as to avoid haemorrhage as they may have had the chance to grow vessels of their own [7].

The presence of jaundice is a good indicator as to the location of the thrombi in the biliary system. Satoh et al. [9] described three groups of patients: in type 1 the thrombi are located in the hepatic ducts but do not reach the convergence of the right and left. In type 2, they are located at the level of the convergence and in type 3 they are further down the biliary tree, for example in the common bile duct. In this study, it was revealed that no patients with type 1 thrombi presented with jaundice whereas 77.8% of patients in type 2 did, and this was increased to 100% of patients with HCC and type 3 thrombi. Statistically therefore, it is likely that patients with HCC who present with jaundice will have a blockage further down the biliary tree [9].

One of the first studies on this subject was carried out in 1947 by Mallory et al. who reported haemobilia causing obstructive jaundice in cases of HCC. Another study was carried out by Lin et al. in 1975–6 [10] which described this phenomenon as 'icteric type hepatoma'. Since these studies, it has often been concluded that the presence of thrombi in the biliary system means the patient has a fairly poor prognosis. However, Shiomi et al. [5] and Satoh et al. [9] reported no significant differences in the survival rates between patients with and without bile duct thrombi. However, some authors report that patients with thrombi have a worse prognosis especially if the thrombi are accompanied with vascular invasion [11]. Some authors reported that underlying disease contributed to a worse prognosis as opposed to the presence of thrombi. However, Minagawa et al. [12] demonstrated that bile duct invasion was an independent prognostic factor. Esaki et al. [1] report that the presence of bile duct thrombi may not be as important a prognostic factor as has been suggested in the past and that portal vein involvement is the most significant factor. The rate of portal vein invasion was significantly higher in patients with

HCC and BDT compared to HCC alone [5], but there was no significant difference between the two groups as far as prognosis was concerned. Although venous involvement is very important for prognosis, patients with BDT have the same prognosis for HCC as those without BDT [9].

However, if the tumour is actually growing within the biliary system itself, the outcome can be very much worse, especially if accompanied by the sudden presence of jaundice. Kojiro et al. published a study in 1982 which came to the conclusion that direct tumour growth with associated marked obstructive jaundice represents the terminal phase of HCC, with the average survival time being 16 days after initial appearance of the jaundice [13].

The most commonly used investigations in these cases are ultrasonography, CT, cholangiography and magnetic resonance cholangiography. Ultrasonography is a good initial investigation and was used in both cases described above. In both cases, bile duct dilatation was seen which indicated the need for other tests such as CT in the first instance and then others such as endoscopic retrograde cholangiopancreatography (ERCP), percutaneous transhepatic cholangiography (PTC) and magnetic resonance cholangiopancreatography (MRCP), which are all imaging techniques used to either assess tumour growth and invasion or to assess the extent of bile duct dilatation. All of these are extremely useful diagnostic tools and, combined with results such as  $\alpha$ -fetoprotein levels, should make the difficult diagnosis of HCC with rupture into the biliary system a little easier [5, 7].

Surgical treatments involving either partial hepatectomy, and thus removal of diseased liver parenchyma, or liver transplantation remain the only viable curable therapies. However, few patients are eligible for hepatectomy due to the presence of liver cirrhosis or the tumour being too close to the porta hepatis [7].

As would be expected, patients treated surgically by hepatic resection have a longer survival period than those treated non-surgically [14]. In patients with bile duct thrombi, the average survival time after resection is 2.3 years with the 3-year survival rate being 47% and the 5-year survival rate being 28%. However, those treated with simple drainage of the biliary system were expected to live only six months [5].

Depending on the size and location of the tumour and fragments as well as the extent of destruction of the bile duct walls, bile duct resection may be indicated in addition to hepatic resection. Satoh et al. [9] studied and compared the survival rates of those patients requiring bile duct resection and those not requiring it and concluded that resection of the bile duct does not affect survival. They then compared the survival rates of those patients who underwent bile duct resection and thus removal of the bile duct thrombi with those whose thrombi were removed by other means and concluded that there was no significant difference. This view was further backed up by Wang et al. [15]. To illustrate it, Shiomi et al. [5] claimed that the 5-year survival rate of patients with thrombectomy through choledochotomy was 31% whereas in patients with hepatic duct resection, the survival rate was 25%. Thus, removal of bile duct thrombi during surgery without bile duct resection is deemed a suitable treatment for HCC with tumour fragments in the biliary system.

Patients who cannot undergo hepatic resection because of poor hepatic function for example only receive palliative treatment such as transcatheter hepatic arterial chemoembolisation (TACE), percutaneous transhepatic biliary drainage (PTBD) involving insertion of a stent (non-surgical) or surgical intubation with T-tube drainage

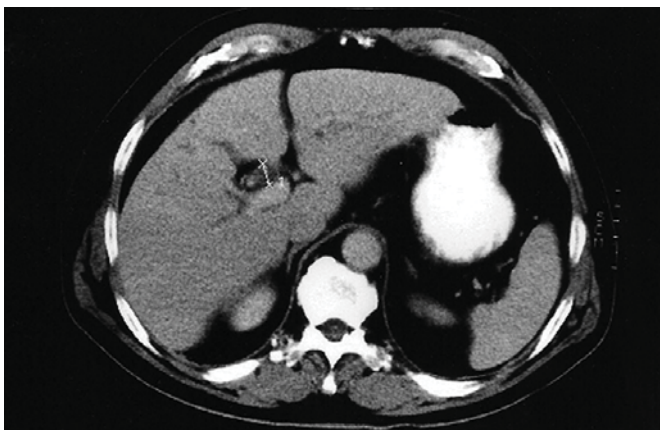
[7]. However, those not eligible for hepatic resection and especially those treated palliatively by non-surgical means have a significantly worse prognosis. One report suggests that the average survival time is 13.4 months if the only treatment administered is TACE, but even this is significantly longer than in patients receiving no treatment at all (3 months). For biliary drainage, the average survival period is 3.9 months only [16]. As reported for cholangiocarcinoma [17], photodynamic therapy to treat malignant biliary obstruction in combination with TACE and/or radiofrequency might be an option.

Unfortunately, as in the case of patient 2 above, the recurrence rate of HCC is quite high even after hepatic resection. This is mainly due to intrahepatic metastases [1, 9] and therefore usually occurs intrahepatically although it does not necessarily involve the biliary system [1]. Suitable therapies in this case are percutaneous ethanol injection therapy (PEI), tumor ablation therapy (RFA), TACE or repeated hepatic resection [1, 9].

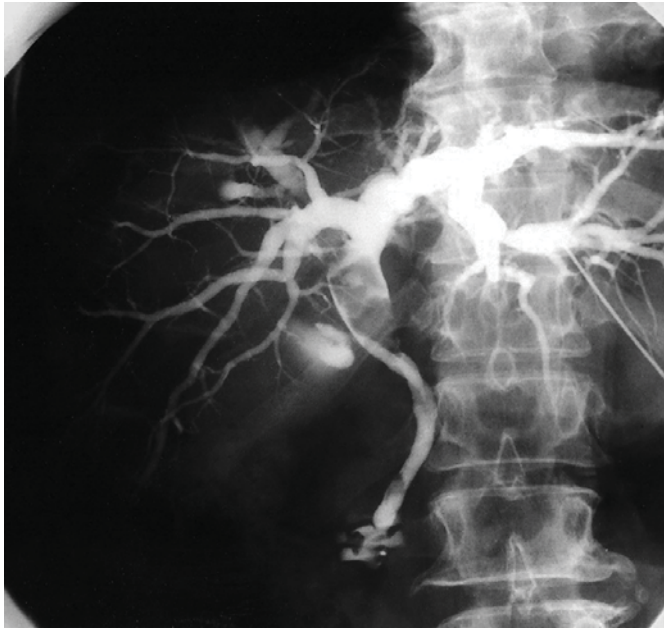
### Conclusion

Tumoural rupture of HCC into the biliary system with resulting bile duct thrombi and obstructive jaundice is relatively rare and has a relatively grim prognosis. However, this depends on the type of treatment chosen. It is widely accepted that aggressive treatment such as hepatic resection with simultaneous thrombectomy is the most effective treatment as this has the longest survival period. However for reasons of tumour location and/or underlying liver disease, surgery is not always a viable option. In such cases, there are several alternative therapies, most of which are palliative with a significantly reduced survival rate.

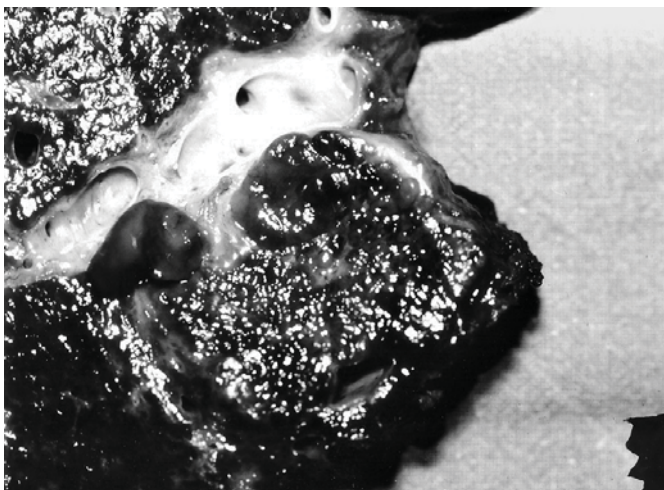
**Fig. 1.** Abdominal CT scan: Dilatation of the right and left hepatic ducts and tumour-like lesion.



**Fig. 2.** Opacification of the bile ducts: Dilatation of intrahepatic bile ducts and main bile duct above the cystic duct. Suspicion of cholangiocarcinoma of the convergence of the bile ducts.



**Fig. 3.** HCC measuring 3 cm with an endoluminal bud in an ulcerated bile duct.



## References

- 1 Esaki M, Shimada K, Sano T, Sakamoto Y, Kosuge T, Ojima H: Surgical results for hepatocellular carcinoma with bile duct invasion: a clinicopathologic comparison between macroscopic and microscopic tumor thrombus. *J Surg Oncol* 2005;90:226–232.
- 2 Stuart K, Anand A, Jenkins R: Hepatocellular carcinoma in the United States. Prognostic features, treatment outcome, and survival. *Cancer* 1996;7:2217–2222.
- 3 Le Treut Y, Hardwigsen J, Ananian P, Saisse J, Gregoire E, Richa H, et al: Resection of hepatocellular carcinoma with tumor thrombus in the major vasculature. A European case-control series. *J Gastrointest Surg* 2006;10:855–862.
- 4 Nakashima T, Okuda K, Kojiro M, Jimi A, Yamaguchi R, Sakamoto K, et al: Pathology of hepatocellular carcinoma in Japan. 232 consecutive cases autopsied in ten years. *Cancer* 1983;51:863–877.
- 5 Shiomi M, Kamiya J, Nagino M, Uesaka K, Sano T, Hayakawa N, et al: Hepatocellular carcinoma with biliary tumour thrombi: aggressive operative approach after appropriate preoperative management. *Surgery* 2001;129:692–698.
- 6 Ueda M, Takeuchi T, Takayasu T, Okamoto S, Tanaka A, Morimoto T, et al: Classification and surgical treatment of hepatocellular carcinoma (HCC) with bile duct thrombi. *Hepatogastroenterology* 1994;41:349–354.
- 7 Chen M, Jan Y, Jeng L, Hwang TL, Wang CS, Chen SC: Obstructive jaundice secondary to ruptured hepatocellular carcinoma into the common bile duct: surgical experiences of 20 cases. *Cancer* 1994;73:1335–1340.
- 8 Lee W, Wang P, Siu K, Wong J: Cholangiography in hepatocellular carcinoma with obstructive jaundice. *Clin Radiol* 1985;35:119–123.
- 9 Satoh S, Ikai I, Honda G, Okabe H, Takeyama O, Yamamoto Y, et al: Clinicopathologic evaluation of hepatocellular carcinoma with bile duct thrombi. *Surgery* 2000;128:779–783.
- 10 Lin T, Chen K, Chen Y, Lin WS, Wang TH, Sung JL: Icteric type hepatoma. *Med Chir Dig* 1975;4:267–270.
- 11 Yeh CN, Jan YY, Lee WC, Chen MF: Hepatic resection for hepatocellular carcinoma with obstructive jaundice due to biliary tumor thrombi. *World J Surg* 2004;28:471–475.
- 12 Minagawa M, Ikai I, Matsuyama Y, Yamaoka Y, Makuuchi M: Staging of hepatocellular carcinoma: assessment of the Japanese TNM and AJCC/UICC TNM systems in a cohort of 13,772 patients in Japan. *Ann Surg* 2007;245:909–922.
- 13 Kojiro M, Kawabata K, Kawano Y, Shirai F, Takemoto N, Nakashima T: Hepatocellular carcinoma presenting as intrabiliary duct tumor growth: a clinicopathologic study of 24 cases. *Cancer* 1982;49:2144–2147.
- 14 Peng S, Wang J, Liu Y, Cai X, Deng G, Xu B, et al: Surgical intervention for obstructive jaundice due to biliary tumour thrombus in hepatocellular carcinoma. *World J Surg* 2004;28:43–46.
- 15 Wang H, Kim J, Kim J, Kim W, Kim M: Hepatocellular carcinoma with tumour thrombi in the bile duct. *Hepatogastroenterology* 1999;46:2495–2499.
- 16 Qin L, Tang Z: Hepatocellular carcinoma with obstructive jaundice: diagnosis, treatment and prognosis. *World J Gastroenterol* 2003;9:385–391.
- 17 Rauws EA: Photodynamic therapy and Klatskin tumour: an overview. *Scand J Gastroenterol Suppl* 2006;243:135–138.