



Contents lists available at ScienceDirect

International Journal of Surgery Case Reports

journal homepage: www.casereports.com

A rare case of an infected tracheal diverticulum requiring emergency intervention: A case report



Shota Akabane*, Jun Kawachi, Ryuta Fukai, Rai Shimoyama, Hiroyuki Kashiwagi, Hidemitsu Ogino, Kazunao Watanabe

Department of General Surgery, Shonan Kamakura General Hospital, Okamoto 1370, Kamakura, Kanagawa, Japan

ARTICLE INFO

Article history:

Received 30 March 2016

Accepted 28 April 2016

Available online 6 May 2016

Keywords:

Tracheal diverticulum

Paratracheal mass

Abscess

Computed tomography

Airway management

ABSTRACT

INTRODUCTION: Recent advancement in radiological imaging has revealed an increasing amount of asymptomatic abnormalities. Tracheal diverticula are relatively rare entities and are incidentally found on radiological imaging such as computed tomography. Here, we present a case of an infected tracheal diverticulum presenting as a paratracheal mass, which required emergency intervention.

CASE PRESENTATION: A 65-year-old Japanese nonsmoker man presented with a fever, lower neck pain, and the aggravation of dyspnea for a week. An enhanced computed tomography scan demonstrated that the trachea was displaced by a paratracheal mass with a well-defined thin wall. His respiratory status was so urgent that emergency intubation and surgical drainage of the abscess were performed. A computed tomography scan performed 4 days after admission demonstrated shrinking of the abscess, and he was extubated and discharged 7 days after admission without any complications.

CONCLUSION: To the best of our knowledge, this is the first report to confirm an infected tracheal diverticulum presenting as a paratracheal abscess, which required emergency intervention. Moreover, computed tomography plays an important role in the differentiation of paratracheal masses.

© 2016 The Author(s). Published by Elsevier Ltd on behalf of IJS Publishing Group Ltd. This is an open access article under the CC BY-NC-ND license (<http://creativecommons.org/licenses/by-nc-nd/4.0/>).

1. Introduction

Recent advancement in radiological imaging has revealed an increasing number of asymptomatic abnormalities. Tracheal diverticula are relatively rare entities and are incidentally found on radiological imaging such as CT [1]. Although the majority of these abnormalities are asymptomatic, they sometimes cause neck pain, chronic cough, dysphagia, odynophagia, hoarseness, or hemoptysis [2]. Here, we present a case of an infected tracheal diverticulum presenting as a paratracheal mass, which required emergency intervention.

2. Case presentation

A 65-year-old Japanese nonsmoker man presented with a fever, lower neck pain, and the aggravation of dyspnea for a week. He also complained of a history of repeated bronchitis during the pre-

ceding year. His medical history included a left upper lobectomy due to lung adenocarcinoma. On physical examination, there was tenderness in the lower neck, and stridor could be heard on his upper chest, with a body temperature of 38.1 °C. The pulse oximeter indicated 90% with 8L/min of oxygen, and laboratory tests revealed elevated inflammatory markers (leukocytes at 10,700/μL, with neutrophilia and a C-reactive protein level of 12.47 mg/dL). An enhanced CT scan demonstrated that the trachea was displaced by a paratracheal mass with a well-defined thin wall (Fig. 1a and b). A CT scan that had been performed as a follow-up of the lung adenocarcinoma 4 years previously had shown a tracheal diverticulum in the same position as the mass (Fig. 2). He was subsequently diagnosed with a paratracheal abscess due to an infected tracheal diverticulum.

His respiratory status was so urgent that emergency intubation and surgical abscess drainage were performed. Surgery was performed via a right neck incision under general anesthesia. The inferior thyroid vessels were ligated, and the right lobe of the thyroid was mobilized to expose the paratracheal lesion. The abscess was identified, and drainage was carried out with dissection. A Penrose drain was inserted into the abscess for continuous postoperative drainage. During the postoperative period, antibiotics (ceftriaxone, 2 g/day) were administered, and his symptoms promptly resolved. A CT scan performed 4 days after admission

Abbreviations: CT, computed tomography.

* Corresponding author.

E-mail addresses: akap.sh.3381@gmail.com (S. Akabane), jkawachi@d7.dion.ne.jp (J. Kawachi), fukai@shonankamakura.or.jp (R. Fukai), rai.shimoyama@tokushukai.jp (R. Shimoyama), kashiwagi@shonankamakura.or.jp (H. Kashiwagi), o-hide@mug.biglobe.ne.jp (H. Ogino), kazuwatanabe@shonankamakura.or.jp (K. Watanabe).

<http://dx.doi.org/10.1016/j.ijscr.2016.04.051>

2210-2612/© 2016 The Author(s). Published by Elsevier Ltd on behalf of IJS Publishing Group Ltd. This is an open access article under the CC BY-NC-ND license (<http://creativecommons.org/licenses/by-nc-nd/4.0/>).

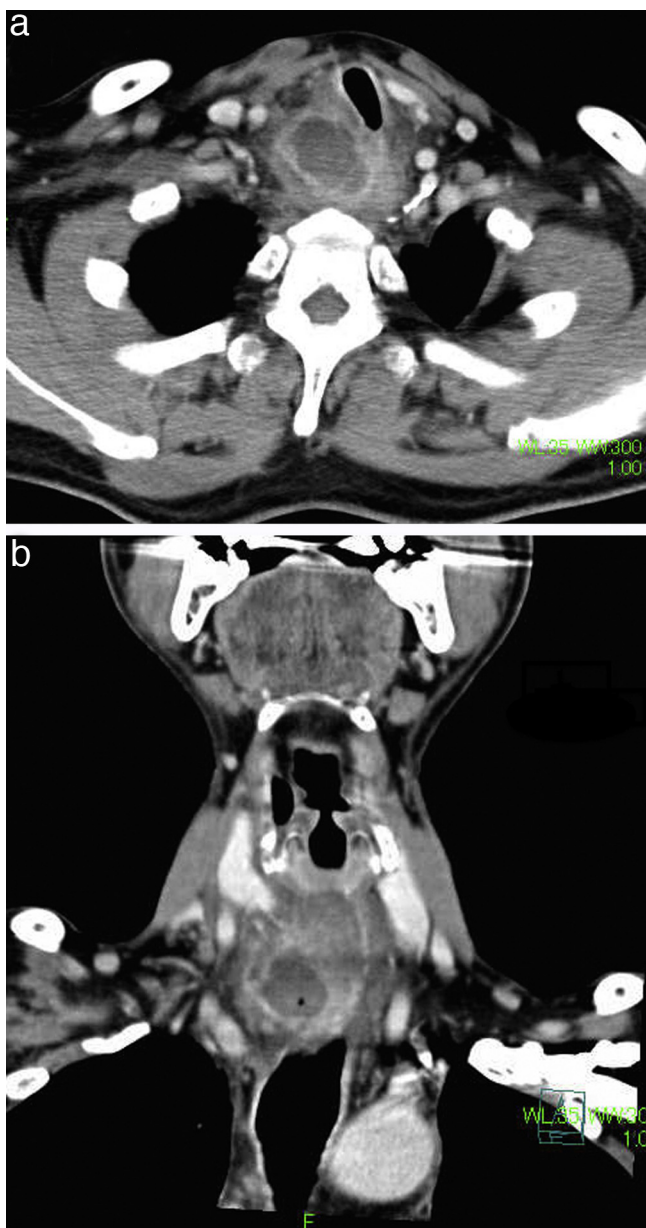


Fig. 1. An enhanced CT scan demonstrating the trachea displaced by a paratracheal mass with a well-defined thin wall (a: axial view, b: coronal view).

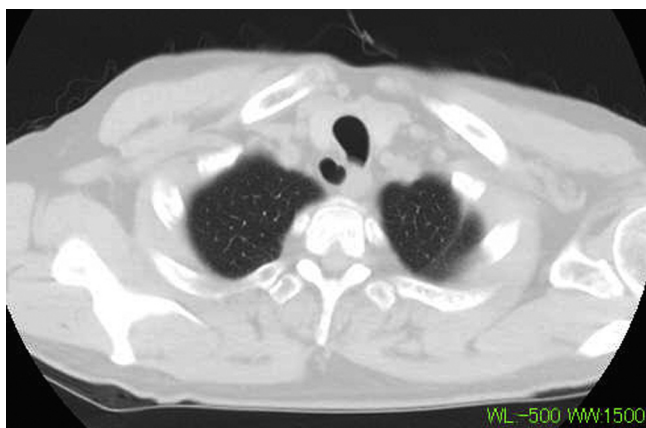

Fig. 2. A CT scan performed 4 years previously showing a tracheal diverticulum in the same position as the mass.

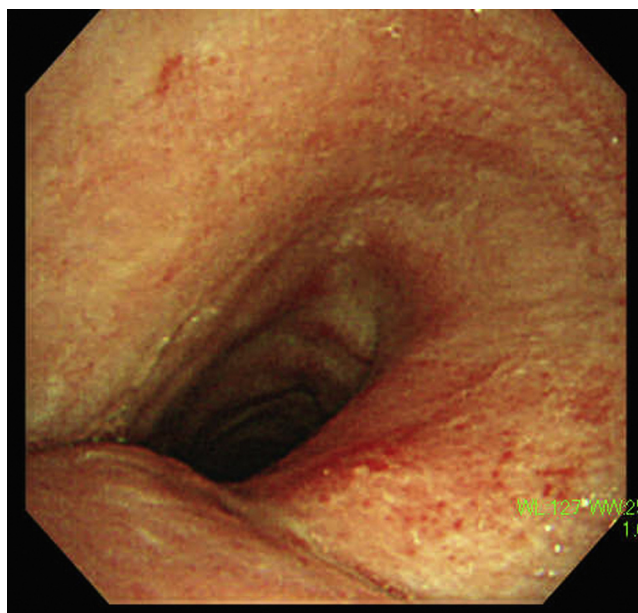


Fig. 3. A bronchoscopy demonstrating an indentation in the posterolateral aspect of the trachea.

demonstrated shrinking of the abscess, and he was extubated and discharged 7 days after admission without any complications.

An upper gastrointestinal tract endoscopy following extubation did not reveal any connection between the esophagus and the abscess. Conversely, a bronchoscopy demonstrated an indentation in the posterolateral aspect of the trachea; however, an obvious connection between the trachea and the abscess could not be detected (Fig. 3).

3. Discussion

In this case, we found out two important clinical issues. Firstly, an infected tracheal diverticulum can present as a paratracheal abscess, impairing the airway. Secondly, a CT scan is helpful for the diagnosis of this condition.

The incidence of tracheal diverticula varies between 2% and 3.7% according to the literature [1,3], and 98% of tracheal diverticula are located at the right posterolateral aspect of the trachea, usually at the level of the thoracic inlet between the T1 and T3 vertebrae [1]. This fact can be explained by the relative positions of the trachea and esophagus or aorta; the supportive effect of the esophagus or aorta on the trachea is along its left posterolateral side, leaving the right side of the trachea relatively unsupported [4,5]. Most patients with tracheal diverticulum have no symptoms. When symptoms occur (sometimes with infection), neck pain, a chronic cough, dysphagia, odynophagia, hoarseness, or hemoptysis are common [4–6]. To our knowledge, this is the first report to describe an infected tracheal diverticulum presenting as a paratracheal mass, impairing the airway and requiring emergency intervention such as intubation and surgical drainage.

The CT features of an abscess are low-attenuation masses with a well-defined thin wall that usually enhances following the intravascular administration of contrast materials [7]. Air bubbles, contiguity or communication with an empyema or a subphrenic abscess, and clinical features may permit the identification of infection [8]. The differential diagnoses for a paratracheal mass include thymoma, germ cell tumors, Hodgkin’s disease, mediastinal carcinoma, lymph node metastasis, and nerve root tumors (schwannomas and neurofibromas) [7]. In addition, an infected Zenker’s diverticulum can also present in such a manner; how-

ever, this is distinguishable if a connection between the esophagus and the diverticulum can be observed by an upper gastrointestinal tract endoscopy. A bronchoscopy is also useful to diagnose a tracheal diverticulum. However, it has been reported that communication between the trachea and a diverticulum was observed in 9 of 25 patients (34.6%) whose CT scans showed a tracheal diverticulum [3]. Other cases have presented as indentations or recess lesions that were assumed to be minor connections between the trachea and a diverticulum. Although tissue examination was not performed in this case, CT performed 4 years previously obtained proof that the mass originated from a tracheal diverticulum. To our knowledge, this is the first report describing a tracheal diverticulum that has progressed to an abscess on CT.

Although the manner by which a tracheal diverticulum turns into an abscess is relatively unknown, it is assumed that repeated upper airway inflammation, such as bronchitis, produces mucus in a diverticulum, which then progresses to an abscess [9]. If this is true, similar to the present case, a minor connection between the trachea and a diverticulum may contribute to the development of an abscess as a result of the insufficient drainage of mucus. A similar progression of a diverticulum into an abscess has been previously reported in cases of calyceal and urethral diverticula [10,11], which can progress into an abscess due to repeated urinary tract infection caused by situations such as urinary lithiasis.

Previous authors have suggested that this condition is only indicated in young symptomatic patients, in whom conservative measures (antibiotics, mucolytics, and physiotherapy) have been unsuccessful [12]. In the present case, emergency interventions such as intubation and surgical drainage were inevitable because the abscess had impaired the airway and respiratory distress had already been noted on physical examination. When surgery is considered, the most commonly described approach is resection via a transverse or lateral neck incision [13]. Other reported options include fulguration, endoscopic cauterization with a laser or electrocoagulation, and endoscopic division with biopsy forceps [4,14].

4. Conclusion

An infected tracheal diverticulum can present as a paratracheal abscess, impairing the airway. Although there are several differential diagnoses for a paratracheal mass, this type of abscess is clinically important because it can require emergency intervention.

Moreover, recent advancement in CT has revealed an increasing number of asymptomatic abnormalities, including tracheal diverticula. The present case suggests that the follow-up of such abnormalities can give clues to obtain the correct diagnosis.

Conflict of interest

None.

Funding

The authors declare that they have no sources of funding.

Ethical approval

All patients received an explanation of the procedures and possible risks of the study, and gave written informed consent.

Open Access

This article is published Open Access at scimedirect.com. It is distributed under the [IJSCR Supplemental terms and conditions](#), which permits unrestricted non commercial use, distribution, and reproduction in any medium, provided the original authors and source are credited.

Consent

Written informed consent was obtained from the patient for publication of this case report and any accompanying images. A copy of the written consent is available for review by the Editor-in-Chief of this journal.

Author contribution

Shota Akabane: study concept, writing the paper.
Jun Kawachi: study concept, review and revision of the paper.
Ryuta Fukai: review and revision of the paper.
Rai Shimoyama: review and revision of the paper.
Hiroyuki Kashiwagi: review and revision of the paper.
Hidemitsu Ogino: review and revision of the paper.
Kazunao Watanabe: review and revision of the paper.

Guarantor

Kazunao Watanabe.

Acknowledgement

We thank Crimson Interactive Pvt. Ltd. for revision and review of the manuscript.

References

- [1] J.M. Goo, J.G. Im, J.M. Ahn, W.K. Moon, J.W. Chung, J.M. Park, et al., Right paratracheal air cysts in the thoracic inlet: clinical and radiological significance, *AJR Am. J. Roentgenol.* 173 (1999) 65–70.
- [2] C.L. Smelley, R. Bowen, C.O. Nathan, Intermittently symptomatic tracheal diverticulum: a case of a rare clinical phenomenon, *Ear Nose Throat J.* 90 (2011) E10–2.
- [3] J.E. Buterbaugh, W.K. Erly, Paratracheal air cyst: a common findings on routine CT examinations of the cervical spine and neck that may mimic pneumomediastinum in patients with traumatic injuries, *AJNR Am. J. Neuroradiol.* 29 (2008) 1218–1221.
- [4] E.K. Early, M.R. Bothwell, Congenital tracheal diverticulum, *Otolaryngol. Head Neck Surg.* 127 (2002) 119–121.
- [5] B.M. Teh, C. Hall, S. Kleid, Infected tracheocele (acquired tracheal diverticulum): case report and literature review, *J. Laryngol. Otol.* 125 (2011) 540–545.
- [6] N. Şahin, A. Solak, B. Genç, A rare case of odynophagia: infected tracheal diverticulum, *Kulak Burun Bogaz İhtis. Derg.* 25 (2) (2015) 126–130.
- [7] M. Jeung, B. Gasser, A. Gangi, A. Bogorin, D. Charneau, J.M. Wihlm, et al., Imaging of cystic masses of the mediastinum, *Radiographics* 22 (2002) S79–93.
- [8] H.S. Glazer, M.J. Siegel, S.S. Sagel, Low-attenuation mediastinal masses on CT, *AJR Am. J. Roentgenol.* 152 (1989) 1173–1177.
- [9] H. Lin, Z. Cao, Y. Qing, Tracheal diverticulum: a case report and literature review, *Am. J. Otol.* 35 (2014) 542–545.
- [10] K. Chan, W. Chu, I. Law, Giant urethral diverticulum calculus representing as scrotal abscess, *Hong Kong Med. J.* 18 (2012) 66–67.
- [11] M. Rebecca, C.B. Jane, V. Sobhan, Caryceal diverticulum—a mimic of different pathologies on multiple imaging modalities, *J. Radiol. Case* 6 (9) (2012) 10–17.
- [12] E. Porbsky, C. Gourin, Surgical treatment of acquired tracheocele, *Ear Nose Throat J.* 85 (2006) 386–387.
- [13] M. Infane, F. Mattavelli, M. Valente, et al., Tracheal diverticulum: a rare cause and consequence of chronic cough: case report, *Eur. J. Surg.* 160 (1994) 315–316.
- [14] L. Johnson, R. Cotton, M. Rutter, Management of symptomatic tracheal pouches, *Int. J. Pediatr. Otorhinolaryngol.* 71 (2007) 527–531.