



Contents lists available at ScienceDirect

## International Journal of Surgery Case Reports

journal homepage: [www.casereports.com](http://www.casereports.com)

## Mesenteric calcification following abdominal stab wound

Caitlin W. Hicks<sup>a</sup>, Catherine G. Velopulos<sup>a</sup>, Justin M. Sacks<sup>b,\*</sup><sup>a</sup> Department of General Surgery, Johns Hopkins Hospital, Baltimore, MD 21287, United States<sup>b</sup> Department of Plastic and Reconstructive Surgery, Johns Hopkins Hospital, Baltimore, MD 21287, United States

## ARTICLE INFO

## Article history:

Received 9 April 2014

Accepted 28 May 2014

Available online 11 June 2014

## Keywords:

Heterotopic ossification

Heterotopic mesenteric ossification

Traumatic myositis ossificans

Trauma

Ventral hernia

## ABSTRACT

**INTRODUCTION:** Heterotopic ossification (HO) refers to the formation of bone in non-ossifying tissue. Heterotopic mesenteric ossification is a rare form of HO that is characterized by the formation of an ossifying pseudotumour at the base of the mesentery, usually following abdominal surgery.

**PRESENTATION OF CASE:** We describe a case of mesenteric HO in a young male who presented for elective ventral incisional hernia repair following a stab wound to the abdomen requiring exploratory laparotomy 21 months earlier. Preoperative workup was unremarkable, but a hard, bone-like lesion was noted to encircle the base of the mesentery upon entering the abdomen, consistent with HO. The lesion was excised with close margins, and his hernia was repaired without incident.

**DISCUSSION:** Traumatic HO describes the ossification of extra-skeletal tissue that specifically follows a traumatic event. It usually occurs adjacent to skeletal tissue, but has been occasionally described in the abdomen as well, usually in patients who suffer abdominal trauma. Overall the prognosis of HO is good, as it is considered a benign lesion with no malignant potential. However, the major morbidity associated with mesenteric HO is bowel obstruction.

**CONCLUSION:** The size, location, and symptoms related to our patient's mesenteric HO put him at risk for obstruction in the future. As a result, the mass was surgically excised during his ventral hernia repair with good outcomes.

© 2014 The Authors. Published by Elsevier Ltd. on behalf of Surgical Associates Ltd. This is an open access article under the CC BY-NC-ND license (<http://creativecommons.org/licenses/by-nc-nd/3.0/>).

## 1. Introduction

Heterotopic ossification (HO) refers to the formation of bone in non-ossifying tissue. Heterotopic mesenteric ossification is a rare form of HO that is characterized by the formation of an ossifying pseudotumour at the base of the mesentery, usually following abdominal surgery. In the present article, we describe a case of mesenteric HO in a young male following a stab wound to the abdomen, including the presentation, likely etiology, clinical workup, and management of this rare disease.

## 2. Case report

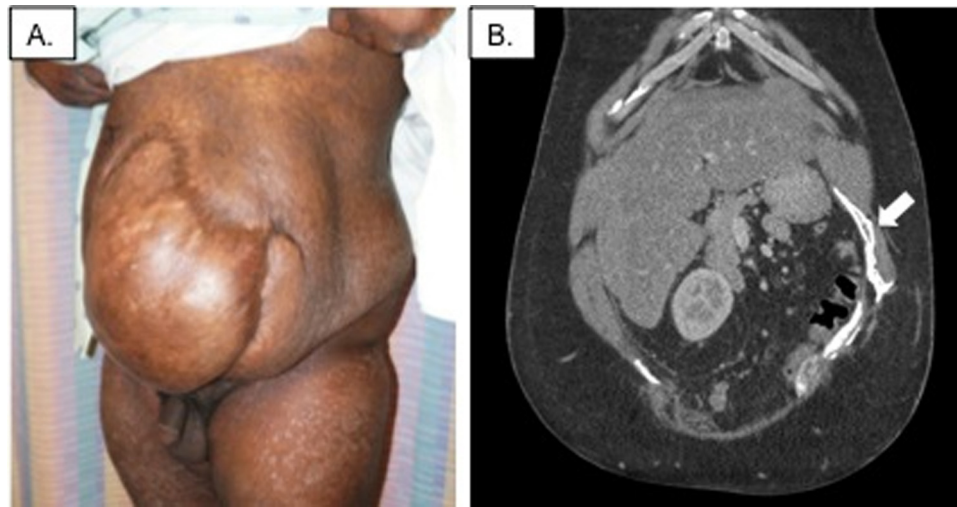A.D. is a 32 year old male who presented for elective ventral incisional hernia repair following a stab wound to the abdomen requiring exploratory laparotomy with small bowel resection and delayed abdominal closure with split-thickness skin graft 21 months earlier (Fig. 1A). Since that time he had recovered without

incident, including a 20 pound weight gain. He complained of mild intermittent abdominal pain, but denied any symptoms of obstruction. Pre-operative computed tomography imaging was notable for the presence of “mesh” lateral to a large non-incarcerated ventral hernia, despite no history of attempted prior hernia repairs (Fig. 1B). Laboratory studies were unremarkable, and the patient was otherwise healthy aside from mild hypertension and a history of smoking.

The patient was taken to the operating room for open surgical repair of his abdominal wall defect in a combined case with the General Surgery and Plastic and Reconstructive Surgery teams. Upon entering the abdomen, a hard, bone-like lesion was noted to encircle the base of the mesentery (Fig. 2A and B). A similar phenomenon was noted along the right lateral edge of the retracted rectus muscle adjacent to a 20 cm × 15 cm fascial defect (Fig. 2C). These findings were consistent with the presence of heterotopic mesenteric ossification. The patient's mesenteric ossification was excised with close margins, along with a 20 cm segment of small bowel with dependant vascular supply from that portion of the mesentery. His ventral incisional hernia was then repaired using an acellular dermal matrix underlay (SurgiMend, TEI Biosciences Inc., Boston, MA) and bilateral myofascial component separation. The patient recovered without incident, and was discharged home in good condition on post-operative day number 7.

\* Corresponding author at: Johns Hopkins Hospital, JHOC 2114C–Department of Plastic and Reconstructive Surgery, 601 North Caroline Street, Baltimore, MD 21287, United States. Tel.: +1 443 287 2025.

E-mail address: [JMSacks@jhmi.edu](mailto:JMSacks@jhmi.edu) (J.M. Sacks).



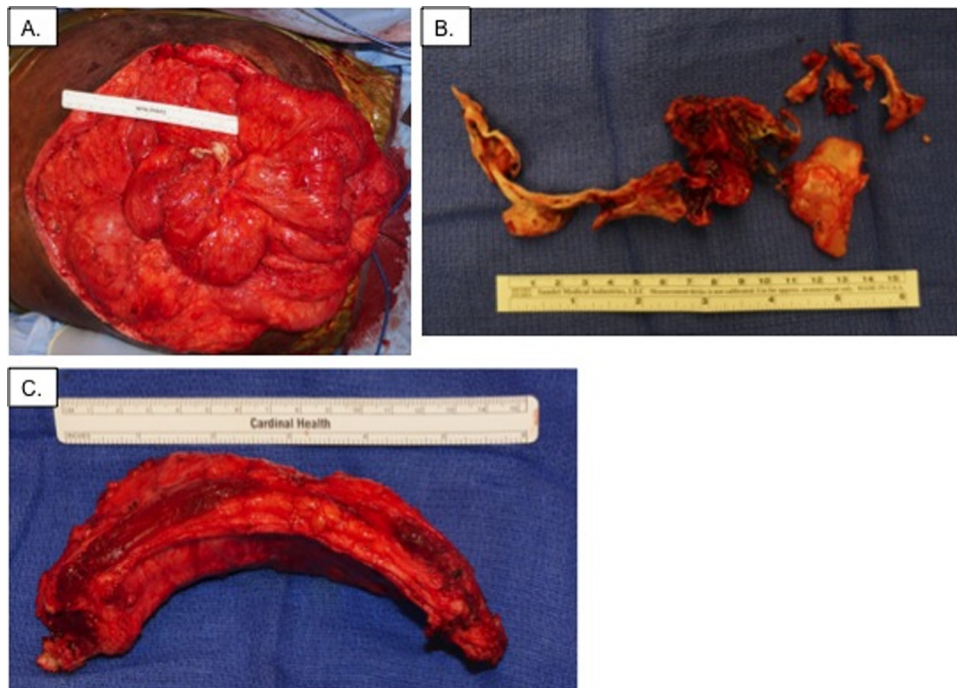
**Fig. 1.** Panel A: Clinical pre-operative exam demonstrating a large ventral hernia covered with skin graft. Panel B: Computed tomography image of purported retained mesh (arrow) lateral to the patient's large non-incarcerated ventral hernia, despite no history of attempted prior hernia repairs.

**3. Discussion**

Heterotopic ossification (HO) refers to the formation of bone in non-ossifying tissue. In contrast to dystrophic calcification, which is a common pathology, HO is a rare pathology characterized by organized calcium deposition comprised of both osteoblasts and structured bone layers.<sup>1</sup> There are three different types of HO, including myositis ossificans progressiva, myositis ossificans circumscripta, and traumatic myositis ossificans. Myositis ossificans progressive, also known as fibrodysplasia ossificans progressive or stone man syndrome, is a hereditary disorder involving a mutation of the gene ACVR1 and is characterized by the progressive ossification of fibrous tissues either spontaneously or following soft tissue damage.<sup>2</sup> Myositis ossificans circumscripta describes a disorder in which there is non-progressive ectopic ossification of a skeletal muscle, usually involving an extremity and idiopathic in nature.<sup>3</sup> It

can occur following trauma (and for this reason is often used synonymously with traumatic myositis ossificans), but has also been described following burn injuries, tetanus, polio, and central nervous system damage.<sup>4</sup> Alterations in local and systemic signaling pathways, as well as disrupted joint proprioception, may stimulate the inappropriate formation of bone.<sup>5</sup>

Traumatic myositis ossificans describes the heterotopic ossification of extra-skeletal tissue that specifically follows a traumatic event.<sup>4</sup> It usually occurs adjacent to skeletal tissue, but has been described in the abdomen as well, usually in patients who suffer abdominal trauma (i.e. gun shot or stab victims) and/or who undergo abdominal surgery.<sup>6</sup> In these cases an ossifying pseudotumour may form at the base of the mesentery, which is variably referred to as heterotopic mesenteric ossification, intraabdominal myositis ossificans, mesenteritis ossificans, or heterotopic ossification of the intestinal mesentery.<sup>7</sup>



**Fig. 2.** Panel A: Intraabdominal lesion surrounding the base of the mesentery. Panel B: Surgical specimen. Panel C: Calcification of the right rectus muscle.

There are approximately 30 cases of heterotopic mesenteric ossification described in the literature to date, the majority of which are related to abdominal surgery.<sup>1,7,8,12</sup> Males are affected 1.5 times more frequently than females, most commonly in mid to late adulthood.<sup>1,11</sup> Presenting symptoms are usually consistent with small bowel obstruction, including nausea/vomiting, abdominal distention, and obstipation. Computed tomography can be used to make the diagnosis, which characteristically demonstrates multiple linear branching opacities with a well-defined cortex containing internal trabecular ossifications.<sup>1,8,13,14</sup> However, as in the case of A.D., these findings can be frequently overlooked or misdiagnosed; often heterotopic mesenteric ossification appears similar to contrast extravasation or dystrophic calcification, or may be misinterpreted as a bony neoplasm (e.g. extraskelatal osteosarcoma or dedifferentiated liposarcoma).<sup>15</sup> Laboratory studies tend to be unremarkable, although alkaline phosphatase elevation has been described as a sensitive – but not specific – indicator, presumably due to increases in osteoblastic activity.<sup>8</sup>

The pathophysiology of HO is currently ill-defined, but thought to be related either to (1) the seeding of osteogenic cells into the abdomen during trauma from small bony particles; or (2) the erroneous differentiation of stem cells into osteoblasts due to severe inflammatory stimuli, such as occurs during trauma.<sup>9,10</sup> In the case of A.D., whose HO was the result of direct trauma, post-traumatic inflammatory stimuli are the most likely cause, as he suffered only a single stab wound during his original trauma and developed HO both at the root of the mesentery and the edge of the rectus abdominus muscle.

Overall the prognosis of HO is good, as it is considered a benign lesion with no malignant potential.<sup>1,11</sup> The major morbidity

### Conflict of interest

Authors C.W.H. and C.G.V. have no conflicts of interest to disclose. Author J.M.S. is consultant/speaker for LifeCell Corporation.

### Funding

This work was completed without financial support.

### Ethical approval

This report is a case report and as such was exempt from IRB approval.

### Author contributions

C.W.H. was responsible for the case report conception, data collection, writing the paper, critical revision, and final approval of the manuscript. C.G.V. was responsible for the case report conception and design, writing the paper, critical revision, and final approval of the manuscript. J.M.S. was responsible for the case report conception and design, data collection, critical revision, and final approval of the manuscript.

### Consent

Written informed consent was obtained from the patient for publication of this case report and accompanying images. A copy of the written consent is available for review by the Editor-in-Chief of this journal on request.

### Key learning points

- Heterotopic ossification (HO) refers to the formation of bone in non-ossifying tissue.
- Heterotopic mesenteric ossification is a rare form of HO that is characterized by the formation of an ossifying pseudotumour at the base of the mesentery, usually following abdominal surgery.
- Overall the prognosis of HO is good, as it is considered a benign lesion with no malignant potential.
- The major morbidity associated with mesenteric HO is bowel obstruction, which usually requires surgical intervention.

associated with the pathology is bowel obstruction, which usually requires surgical intervention. In asymptomatic cases, watchful waiting is recommended. Surgical intervention is reserved for symptomatic patients because of the concern that HO will recur and possibly worsen with repetitive surgery.<sup>1</sup> For those patients undergoing surgery, there is some evidence that post-operative treatment with non-steroidal anti-inflammatory drugs, diphosphonates or even radiotherapy may prevent recurrence.<sup>1</sup>

### 4. Conclusion

In the case described above, the most appropriate course of action would be to excise the tumor and proceed with ventral hernia repair. Although heterotopic mesenteric ossification is a benign ossifying pseudotumour with no malignant potential, its major morbidity is bowel obstruction. Surgery is generally reserved for symptomatic patients, but the size and location of A.D.'s lesion, in combination with his nonspecific complaints of abdominal pain, put the patient at risk for obstruction in the future. In addition, by undergoing surgery he was at risk for worsening HO as a result of the stress of the procedure.

### References

1. Zamolyi RQ, Souza P, Nascimento AG, Unni KK. Intraabdominal myositis ossificans: a report of 9 new cases. *Int J Surg Pathol* 2006;**14**:37–41.
2. Shore EM, Xu M, Feldman CJ, et al. A recurrent mutation in the BMP type I receptor ACVR1 causes inherited and sporadic fibrodysplasia ossificans progressiva. *Nat Genet* 2006;**38**:525–7.
3. Gokkus K, Sagtas E, Suslu FE, Aydin AT. Myositis ossificans circumscripta, secondary to high-velocity gunshot and fragment wound that causes sciatica. *BMJ Case Rep* 2013;**2013**, <http://dx.doi.org/10.1136/bcr-2013-201362>.
4. Muir B. Myositis ossificans traumatica of the deltoid ligament in a 34-year-old recreational ice hockey player with a 15-year post-trauma follow-up: a case report and review of the literature. *J Can Chiropr Assoc* 2010;**54**:229–42.
5. Genet F, Jourdan C, Schnitzler A, et al. Troublesome heterotopic ossification after central nervous system damage: a survey of 570 surgeries. *PLoS ONE* 2011;**6**:e16632.
6. Kim J, Kim Y, Jeong WK, Song SY, Cho OK. Heterotopic ossification developing in surgical incisions of the abdomen: analysis of its incidence and possible factors associated with its development. *J Comput Assist Tomogr* 2008;**32**:872–6.
7. Ioannidis O, Sekouli A, Paraskevas G, et al. Intra-abdominal heterotopic ossification of the peritoneum following traumatic splenic rupture. *J Res Med Sci* 2012;**17**:92–5.
8. Bovo G, Romano F, Perego E, Franciosi C, Buffa R, Uggeri F. Heterotopic mesenteric ossification ("intraabdominal myositis ossificans"): a case report. *Int J Surg Pathol* 2004;**12**:407–9.
9. Di Paolo N, Sacchi G, Lorenzoni P, Sansoni E, Gaggiotti E. Ossification of the peritoneal membrane. *Perit Dial Int* 2004;**24**:471–7.

10. Patel RM, Weiss SW, Folpe AL. Heterotopic mesenteric ossification: a distinctive pseudosarcoma commonly associated with intestinal obstruction. *Am J Surg Pathol* 2006;**30**:119–22.
11. Vlachos K, Archontovasilis F, Karameris A, Tsiambas E, Lagoudiannakis E, Manouras A. Heterotopic mesenteric ossification after gastrectomy for watermelon stomach. *J Gastrointest Liver Dis* 2009;**18**:229–31.
12. Tam V, Zelken J, Sacks JM. Total heterotopic ossification of an acellular dermal matrix used for abdominal wall reconstruction. *BMJ Case Rep* 2013;**2013**, <http://dx.doi.org/10.1136/bcr-2013-009081>.
13. Hakim M, McCarthy EF. Heterotopic mesenteric ossification. *AJR Am J Roentgenol* 2001;**176**:260–1.
14. Hashash JG, Zakhary L, Aoun EG, Refaat M. Heterotopic mesenteric ossification. *Colorectal Dis* 2012;**14**:e29–30.
15. Binesh F, Akhavan A, Navabii H, Ostadi M. Heterotopic mesenteric ossification: report of a case and review of the literature. *BMJ Case Rep* 2012;**2012**, <http://dx.doi.org/10.1136/bcr-02-2012-5793>.

#### Open Access

This article is published Open Access at [scimedirect.com](http://scimedirect.com). It is distributed under the [IJSCR Supplemental terms and conditions](#), which permits unrestricted non commercial use, distribution, and reproduction in any medium, provided the original authors and source are credited.