



Case Report

A case report of juvenile giant fibroadenoma of the breast: How common?

C. A. Mohd Firdaus^a, A. J. Norjazliney^b, Nor Faezan Abdul Rashid^{a*}

^aDepartment of Surgery,
Faculty of Medicine, Universiti
Teknologi MARA 47000 Sungai
Buloh, Selangor, Malaysia,

^bDepartment of General Surgery,
Hospital Selayang, Lebuhraya
Selayang-Kepong, 68100 Batu
Caves, Selangor, Malaysia

Received : 04-Feb-2017
Revised : 06-Mar-2017
Accepted : 15-May-2017

ABSTRACT

Breast lesions are rare prepubescents. The majority of breast lesions in this age group are benign. The most common of these rare lesions is juvenile fibroadenoma, which accounts for only 0.5% of all fibroadenomas. It is uncommon to have a palpable lesion in juveniles as very small lesions show obvious asymmetry. Fibroadenomas can grow to a large size, and surgical intervention is cosmetically challenging, especially in achieving symmetry in a developing breast. A 12-year-old girl presented with right breast swelling associated with tenderness. The mass had initially been small on self-discovery 1 year previously and grew with time. There was no overlying skin changes or any significant risk factors for breast malignancy. Triple assessment showed features of fibroadenoma, but we were unable to rule out a phyllodes tumor. She subsequently underwent excision biopsy of the right breast lesion for symptomatic control and histopathology examination (HPE) of the lesion. The HPE report confirmed the diagnosis of fibroadenoma. The patient recovered well postoperatively with no complications. Juvenile breast lesions are rare, and it is a challenge to provide an adolescent with the best treatment in terms of clinical and psychological care. A surgical approach requires meticulous planning to ensure a fine balance between adequate resection and the best cosmetic outcome for a developing breast.

KEYWORDS: *Benign breast lesion, Case report, Juvenile fibroadenoma*

INTRODUCTION

Pediatric and adolescent breast masses are rare and most are benign lesions [1]. It is a spectrum of disease ranging from congenital abnormalities to abnormal development and neoplastic processes in the growing breast [1]. Although most juvenile breast lesions are benign, the psychological impact on caretakers and the growing child can be significant [1].

The approach to breast lesions in adolescents is slightly different from that in adults [1]. A detailed and comprehensive history and clinical examination are vital for an accurate diagnosis [2,3]. Diagnostic tools used differ from those in adults as ultrasonography is preferred to mammography to avoid unnecessary radiation in a developing breast [3].

Fibroadenoma has the highest incidence of breast lesions in young women between 15 and 30 years old [2,3]. It can exist as a solitary mass or multiple masses [3]. When these enlarged masses are histologically confirmed in young female patients, they are often called juvenile fibroadenomas [4]. The lesions are rare, accounting for only 0.5% of all diagnosed fibroadenomas, and they can grow quite large and cause prominent asymmetry of the breasts [4].

The mainstay of treatment for benign breast lesions in prepubescents and adolescents is conservative to avoid

unnecessary injury to a developing breast [1-3]. If the patient has persistent symptoms, a surgical approach is indicated [4]. In this case report, we highlight the surgical approach to juvenile giant fibroadenoma.

CASE REPORT

A 12-year-old girl was referred from the general practitioner clinic with a 1-year history of a right breast lump, initially measuring 1cm in diameter and rapidly growing. Recently, the patient started to experience mild tenderness over the lump, but there were no skin changes or constitutional symptoms. There was no significant family history of similar problems. Clinical examination revealed asymmetrical breasts with obvious enlargement of the right breast. A large 11 cm × 8 cm mass occupied almost the whole breast [Figure 1]. The left breast appeared to be developing normally (Tanner Stage II) as no obvious lesions were detected. There were no other clinical abnormalities.

Ultrasonography assessment revealed a large solid homogeneous 6.2 cm × 2.8 cm × 5.6 cm lesion. Magnetic

*Address for correspondence:

Dr. Nor Faezan Abdul Rashid,
Department of Surgery, Faculty of Medicine, Universiti Teknologi MARA,
Sungai Buloh Campus, 47000, Sungai Buloh, Selangor, Malaysia.
E-mail: ezan_80@hotmail.com

This is an open access article distributed under the terms of the Creative Commons Attribution-NonCommercial-ShareAlike 3.0 License, which allows others to remix, tweak, and build upon the work non-commercially, as long as the author is credited and the new creations are licensed under the identical terms.

For reprints contact: reprints@medknow.com

How to cite this article: Mohd Firdaus CA, Norjazliney AJ, Abdul Rashid NF. A case report of juvenile giant fibroadenoma of the breast: How common?. Tzu Chi Med J 2017;29:177-9.

Access this article online	
Quick Response Code: 	Website: www.tcmjmed.com DOI: 10.4103/tcmj.tcmj_64_17

resonance imaging showed a homogeneous 4 cm × 6 cm mass with microlobulation occupying the entire right breast with increasing enhancement on postcontrast images [Figure 2]. A big feeding vessel originated from the chest wall and was believed to be the internal mammary artery.

Histopathology examination (HPE) through a core biopsy demonstrated features of fibroadenoma; however, we were unable to exclude a diagnosis of phyllodes tumor, and hence, surgical excision was required for full analysis. Following appropriate preoperative counseling, the patient and family agreed to surgery.

A superior circumareolar incision was used for the best cosmetic outcome. The tumor was located deep in the subdermal layer with a deep margin anterior to the pectoralis major fascia and was well encapsulated and highly vascularized. Normal breast tissue was found inferior to the mass. The lesion weighed 400 g with a resected size of 12 cm × 9 cm × 5 cm [Figure 3].

The postoperative course was uneventful, and the patient was discharged the day after surgery. On gross HPE, the cut section showed a homogeneous brown cut surface with no areas of hemorrhage or necrosis. The stromal mitotic count was <1 per 10 HPF, with focal areas of usual ductal hyperplasia with myoepithelial hyperplasia. There was no clefting or leaf-like pattern seen to suggest a phyllodes tumor. There was no evidence of metaplastic changes. Hence, the final diagnosis was fibroadenoma.

DISCUSSION

Abnormal breast lesions in prepubescents and adolescents occur for various reasons, either physiological or pathological. Physiological breast development (mammogenesis) occurs over several phases, resulting in prominent and developed structures on the chest, which serve as both a sexual characteristic and as mammary glands [5]. During adolescence, breast growth is triggered mainly by female sex hormones [5,6].

Most abnormal breast masses in prepubescents are benign and include fibroadenoma, fibrocystic disease, breast trauma, and breast infection [7]. The most common cause of adolescent benign breast lesions, however, is juvenile fibroadenoma with a prevalence of approximately 2% in women in their second and third decade [7,8].

Fibroadenomas are typically asymptomatic but may cause discomfort over the onset of menses [8]. Most fibroadenomas do not show progressive growth, but the growth phase is followed by a static phase in about 80% of patients, with regression in about 15% and progression in only 5%–10% [7,8]. Giant fibroadenomas are breast lumps larger than 5 cm or 500 mg [9]. Less than 5% of adolescent fibroadenomas are classified as giant juvenile fibroadenomas [1,4]. This lesion is characterized by a unilaterally enlarged, painless mass in which the tumor may be larger than the existing normal breast tissue. Often, the skin overlying the tumor is stretched with dilated superficial veins. The main differential diagnosis of this lesion is phyllodes tumor.

Histologically, phyllodes tumors are fibroepithelial breast tumors that behave in a spectrum of disease [10]. The name



Figure 1: Gross asymmetry between the right and the left breast lesion

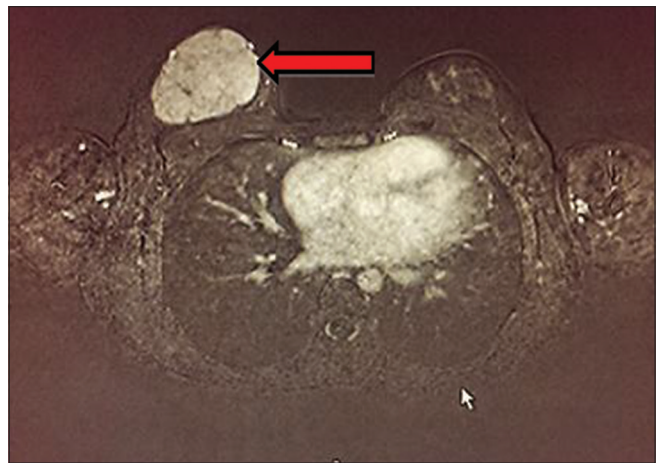


Figure 2: Axial cut of magnetic resonance imaging of the breast

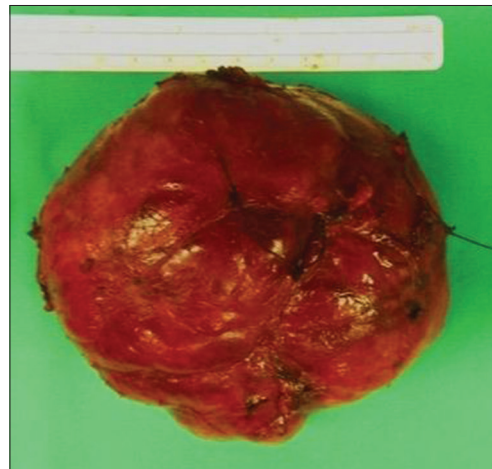


Figure 3: Photograph of the excised and tagged tumor

“phyllodes” is taken from Greek and means “leaf like,” which refers to that fact that the tumor cells grow in a leaf-like pattern [10]. The benign form of phyllodes behaves like fibroadenoma whereas the malignant form tends to be aggressive and metastasizes early [10]. They account for <1% of breast

neoplasms in contrast to fibroadenoma, which is relatively common [10]. It is clinically challenging to differentiate between the two lesions as there is no distinct boundary between fibroadenoma and phyllodes tumor at the benign end of the spectrum except through histopathological examination [10].

As with all breast lesions, the algorithm for investigation is through triple assessment; clinical examination, radiological assessment and histopathological examination [3,4]. Ultrasonography is the investigation of choice for adolescents because there is no radiation exposure [2,3]. Modern ultrasonography is a reliable technique to diagnose fibroadenoma in the hands of experienced breast radiologists [3].

Core needle biopsy remains the gold standard to confirm the diagnosis to differentiate giant fibroadenoma and phyllodes tumor from other breast lesions [8]. Although this method is controversial, we believe that core biopsy will provide clinicians with more solid tissue evidence before embarking with a more invasive intervention. Some clinicians may raise some concerns with regard to psychosocial aspect of the treatment whereby people may question the core biopsies done under local anesthesia; this procedure can also be performed under general anesthesia. Once a solid diagnosis has been made, multidisciplinary discussion is recommended to address the physical, psychosocial, and child developmental aspect on which is the best approach in intervening with such a disease. A juvenile fibroadenoma consists of prominent stromal cellularity, often with intraductal epithelial hyperplasia, in contrast to fibroblastic stroma enclosing glandular nonhyperplastic epithelium as seen in adult fibroadenomas [7]. The diagnosis of cystosarcoma phyllodes can be made based on increased stromal cellularity, pleomorphism, and the presence of mitotic nuclei, clefting, or a leaf-like pattern histologically [11].

The approach to treatment for benign breast lesions in prepubescents and adolescents is mainly conservative to minimize interruption in a physiologically growing breast [1-3]. Unless the lesion is persistently symptomatic or malignancy is suspected, watchful waiting may be considered [2,4]. Surgical treatment of a giant juvenile fibroadenoma ranges from local excision to a simple mastectomy. Local excision is the treatment of choice in most patients, even with a diagnosis of cystosarcoma phyllodes [10]. In very large tumors, an inframammary incision is preferred to preserve the integrity of the normal developing breast parenchyma in adolescents to minimize dissection through the ducts and lobules. This approach can ensure continued development of the breast tissue and the ability to lactate later in life [8]. Aggressive biopsy or dissection in the subareolar developing breast bud can result in significant cosmetic deformity [7]. In cases where multiple juvenile fibroadenomas are present, local recurrence has been reported and can be treated by further resection at the time of recurrence [7].

Surgical planning is crucial and can be complex if the lesion is huge in relation to the normal contralateral breast [1,2,4]. Issues of asymmetry and even underdevelopment of the breast are concerns in prepubescents [7]. Psychological impact on future lactation and self-esteem among peers can be devastating [9]. Treating malignant phyllodes in prepubescents should

follow the same course as in adults [10]. Thorough preoperative investigation and planning with the appropriate disciplines such as a surgeon, radiologist, pathologist, oncologist, and psychologist are advisable to prepare the patient physically as well as mentally for surgery.

CONCLUSION

Juvenile breast lesions are rare. A detailed and comprehensive history and examination are crucial. It is a huge challenge to plan for the best treatment. Multiple factors must be taken into consideration in terms of clinical, physiological, and psychological care and maturation of the adolescent. A surgical approach requires thorough and detailed planning to ensure a fine balance between adequate resection and the best cosmetic outcome for a developing breast.

Declaration of patient consent

The authors of this manuscript state that there are no direct or indirect financial interests or conflicts of interest for disclosure. Each author has contributed to the original work in the manuscript and adhered to the ethical requirements as outlined by the journal.

Financial support and sponsorship

Nil.

Conflicts of interest

There are no conflicts of interest.

REFERENCES

1. Kaneda HJ, Mack J, Kasales CJ, Schetter S. Pediatric and adolescent breast masses: A review of pathophysiology, imaging, diagnosis, and treatment. *AJR Am J Roentgenol* 2013;200:W204-12.
2. Kennedy RD, Boughey JC. Management of pediatric and adolescent breast masses. *Semin Plast Surg* 2013;27:19-22.
3. Pruthi S, Jones KN, Boughey JC, Simmons PS. Breast masses in adolescents: Clinical pearls in the diagnostic evaluation. *Am Fam Physician* 2012;86:325-6.
4. Guray M, Sahin AA. Benign breast diseases: Classification, diagnosis, and management. *Oncologist* 2006;11:435-49.
5. Hynes NE, Watson CJ. Mammary gland growth factors: Roles in normal development and in cancer. *Cold Spring Harb Perspect Biol* 2010;2:a003186.
6. Ruan W, Kleinberg DL. Insulin-like growth factor I is essential for terminal end bud formation and ductal morphogenesis during mammary development. *Endocrinology* 1999;140:5075-81.
7. ACOG Committee on Adolescent Health Care. ACOG Committee Opinion No 350, November 2006: Breast concerns in the adolescent. *Obstet Gynecol* 2006;108:1329-36.
8. Jayasinghe Y, Simmons PS. Fibroadenomas in adolescence. *Curr Opin Obstet Gynecol* 2009;21:402-6.
9. Chung EM, Cube R, Hall GJ, González C, Stocker JT, Glassman LM. From the archives of the AFIP: Breast masses in children and adolescents: Radiologic-pathologic correlation. *Radiographics* 2009;29:907-31.
10. Chaney AW, Pollack A, McNeese MD, Zagars GK, Pisters PW, Pollock RE, et al. Primary treatment of cystosarcoma phyllodes of the breast. *Cancer* 2000;89:1502-11.
11. Simmons RM, Cance WG, Iacocca MV. A giant juvenile fibroadenoma in a 12-year old girl: A case for breast conservation. *Breast J* 2000;6:418-20.