

Gastric Burkitt lymphoma

A case report and literature review

Simona Gurzu, MD, PhD^{a,b,*}, Tivadar Bara, MD, PhD^c, Tivadar Jr. Bara, MD, PhD^c, Mihai Turcu, MD, PhD^a, Ciprian Valentin Mardare^a, Ioan Jung, MD, PhD^a

Abstract

Rationale: Burkitt lymphoma (BL) is an endemic tumor in Africa but rare sporadic cases are diagnosed in Europe.

Patient concerns: A 60-year-old woman was hospitalized with fulminant hematemesis and a history of recurring melena.

Diagnoses: The upper gastrointestinal endoscopy revealed a tumor of the antrum.

Interventions: Emergency gastrectomy was performed.

Outcomes: Gross findings revealed an ulcerated tumor with elevated margins and several perigastric and extragastric lymph nodes. Histological examination showed proliferation of atypical lymphocytes with a Ki67 index of 100%; they were marked by CD20, CD79a, bcl-6, and CD10 and were negative for CD3, CD5, CD23, TdT, bcl-2, and Cyclin D1. The tumor cells crossed the serosa and presented invasion of the lymph nodes. The patient died 10 days after surgery due to bronchopneumonia and acute renal failure.

Lessons: In our department, only one gastric BL was diagnosed in a 61 consecutive lymphomas of the gastrointestinal tract (1.64%). Less than 200 reports about gastric-BL have been published to date. This case highlights the difficulty of diagnosis of rare variants of aggressive gastric lymphomas in medium-income countries without screening programmes.

Abbreviations: BCL-NOS = B-cell lymphoma-not otherwise specified, BL = Burkitt lymphoma, DLBCL = diffuse large B-cell lymphomas, EBV = Epstein-Barr virus, MALT = mucosa associated lymphoid tissue, NHL = non-Hodgkin lymphoma.

Keywords: Burkitt lymphoma, stomach, upper gastrointestinal hemorrhage

1. Introduction

The B-cell-derived highly-malignant Burkitt lymphoma (BL) was first described in 1958 by Dennis Burkitt in the jaw of Ugandan children. The gamma-herpes virus Epstein-Barr (EBV) was 6 years later isolated from cells cultured from BL.^[1]

This tumor especially occurs in patients from the sub-Saharan Africa^[1] and is related on t(8;14)(q24;q32) translocation of *c-myc* and *IgH* genes; *IgH-myc* fusion is characteristic.^[2] The sporadic forms are very rarely encountered in both Europe and Asia, about 4 to 5 cases being yearly diagnosed in large medical centers.^[3]

Although BL is considered a nodal lymphoma, the extranodal involvement is present in more than 80% of the cases.^[3] The extranodal BL especially occurs in gastrointestinal tract (2 quarters of the cases) and head and neck areas (1 quarter); bone marrow, genito-urinary tract, bones, central nervous system, and liver were also reported to be involved.^[3,4] In more than 60% of the cases, the overall survival is below 5 months; the negative prognostic factors are bone marrow and central nervous system involvement^[3] as well as delayed diagnosis.

Regarding primary sporadic BL of the stomach, it is mostly a secondary spread from a retroperitoneal BL, few cases being diagnosed based on gastric cancer-related symptoms. However, <200 reports about gastric-BL have been published to date. In this paper, we present an unusual case of aggressive BL of the stomach diagnosed in a patient with acute life-threatening hematemesis. The incidence of this histological type in our department was also showed and compared with other countries (Table 1).

2. Case report

During 2010 to 2016, in our university hospital, we diagnosed 61 primary lymphomas of the gastrointestinal tract: 34 cases in the stomach, 6 in the small intestine, and 21 cases in the colorectal segments. The 34 gastric lymphomas were diagnosed in both women (n=16) and men (n=18) with a median age of 57.75 ± 14.97 years (range, 23–82 years). Regarding the histological type, 25 of the 34 gastric lymphomas (73.53%) were diagnosed as diffuse large B-cell lymphomas (DLBCL), 6 were mucosa associated lymphoid tissue (MALT) lymphomas (17.65%), 2 were B-cell lymphomas-not otherwise specified (5.88%), and 1 BL (2.94%) was identified (Table 1).

Editor: Tomi Akinyemiju.

SG and TJB have same contribution to the paper.

Conflict of interest: None declared.

^a Department of Pathology, ^b Department of Pathology, Clinical County Emergency Hospital, ^c Department of Surgery, University of Medicine and Pharmacy, Tirgu-Mures, Romania.

* Correspondence: Simona Gurzu, Department of Pathology, University of Medicine and Pharmacy and Clinical County Emergency Hospital, 38 Ghe Marinescu Street, 540139, Tirgu-Mures, Romania (e-mail: simonagurzu@yahoo.com).

Copyright © 2017 the Author(s). Published by Wolters Kluwer Health, Inc. This is an open access article distributed under the Creative Commons Attribution-NoDerivatives License 4.0, which allows for redistribution, commercial and non-commercial, as long as it is passed along unchanged and in whole, with credit to the author.

Medicine (2017) 96:49(e8954)

Received: 1 June 2017 / Received in final form: 3 November 2017 / Accepted: 8 November 2017

<http://dx.doi.org/10.1097/MD.0000000000008954>

Table 1
Geographic distribution of histopathological types of gastrointestinal non-Hodgkin lymphomas^[6,8,9].

Histological type	Stomach				Small intestine				Colon				Multiple sites			
	North America		Romania-present study		North America		Romania-present study		North America		Romania-present study		North America		Romania-present study	
	54%	38%	73.53%	38%	67%	31%	33.33%	50%	83%	76%	31%	8%	8%	31%	15%	8%
DLBCL	54%	38%	73.53%	38%	67%	31%	33.33%	50%	83%	76%	31%	8%	8%	31%	15%	8%
MALT	38%	3%	17.65%	5%	—	34%	33.33%	23%	—	18%	—	—	—	—	—	—
Follicular	—	—	—	23%	—	—	16.67%	8%	17%	—	—	—	—	—	—	—
Mantle-cell	3%	—	—	—	—	—	—	4%	—	—	—	—	—	—	—	—
BL	—	—	2.94%	8%	—	29%	—	8%	—	6%	—	—	—	—	—	—
BCL-NOS	1%	—	5.88%	3%	—	—	—	4%	—	—	—	—	—	—	—	—
T-cell lymphomas	4%	—	—	24%	33%	6%	16.67%	4%	—	—	—	—	—	—	—	—

BL = Burkitt lymphoma, BCL-NOS = B-cell lymphoma-not otherwise specified, DLBCL = diffuse large B-cell lymphoma, MALT = lymphoma of the mucosa-associated lymphoid tissue.

In the present report, we present in detail the unusual case of gastric BL. The patient’s signed consent was obtained for surgical intervention and publication of scientific data.

A 60-year-old woman with a 3-month history of recurring melena, epigastric pain, inappetence, and weight loss (5 kg in 3 months), was hospitalized with fulminant hematemesis. The past medical history included hysterectomy that was performed for leiomyomatosis. Currently, she was treated for NYHA II-cardiac failure.

At the present admission, the emergency gastroscopy and computed tomographic (CT)-scan examination revealed a 50 × 40 mm ulcerated tumor of the antrum. Blood tests did not show significant disorders except leukocytosis (18,750 white blood cells/μL), slight anemia (hemoglobin 9.7g/dL and hematocrit 28.1%), and thrombocytopenia (68,000 platelets/μL). Serology for EBV and hepatitis B and C was negative, the serum LDH value was in normal ranges. No information about the aspect of peripheral leukocytes was available.

Due to massive life-threatening hematemesis and ulcerated aspect of the tumor, emergency surgical intervention was decided. Being about an emergent intervention, no biopsy was performed.

Due to location of the tumor in the distal stomach, distal gastrectomy was performed and transfusion was postoperatively done. The postoperative evolution was unfavorable; broncho-pneumonia and renal failure were installed (urea 117.70 mg/dL, creatinine 4.10 mg/dL, sodium 146.00 mmol/L, and potassium 3.50 mmol/L) and patient died 10 days after surgical intervention. Based on the family refusal, no necropsy was performed.

Gross examination of the surgical specimen revealed a 50 × 40 × 15 mm-sized tumor involving the antrum, greater curvature, and posterior wall of the gastric body. The tumor had elevated margins and was partially-ulcerated and partially-covered by normal gastric mucosa (Fig. 1). On cut section, crossing the serosa was noted. About 19 lymph nodes with a diameter between 8 and 20 mm diameter were identified in the serosa and greater omentum. Another 9 nodes were also seen intraoperatively and removed from the hepatic hilum and surrounding the celiac trunk and medial colic artery.

Microscopically examination revealed proliferation of medium-sized atypical cohesive-lymphocytes invading all gastric layers; pleomorphic nuclei with dispersed chromatin, and a high mitotic rate were also noticed. Several macrophages were admixed with

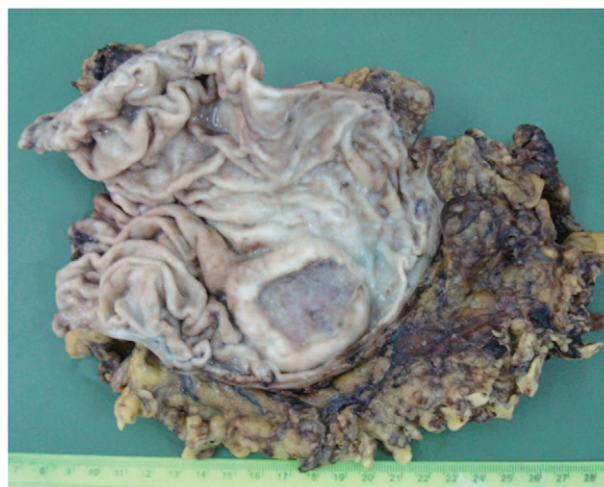

Figure 1. Gastric Burkitt lymphoma—an ulcerated tumor with elevated margins located in the antrum and posterior wall of the gastric body.

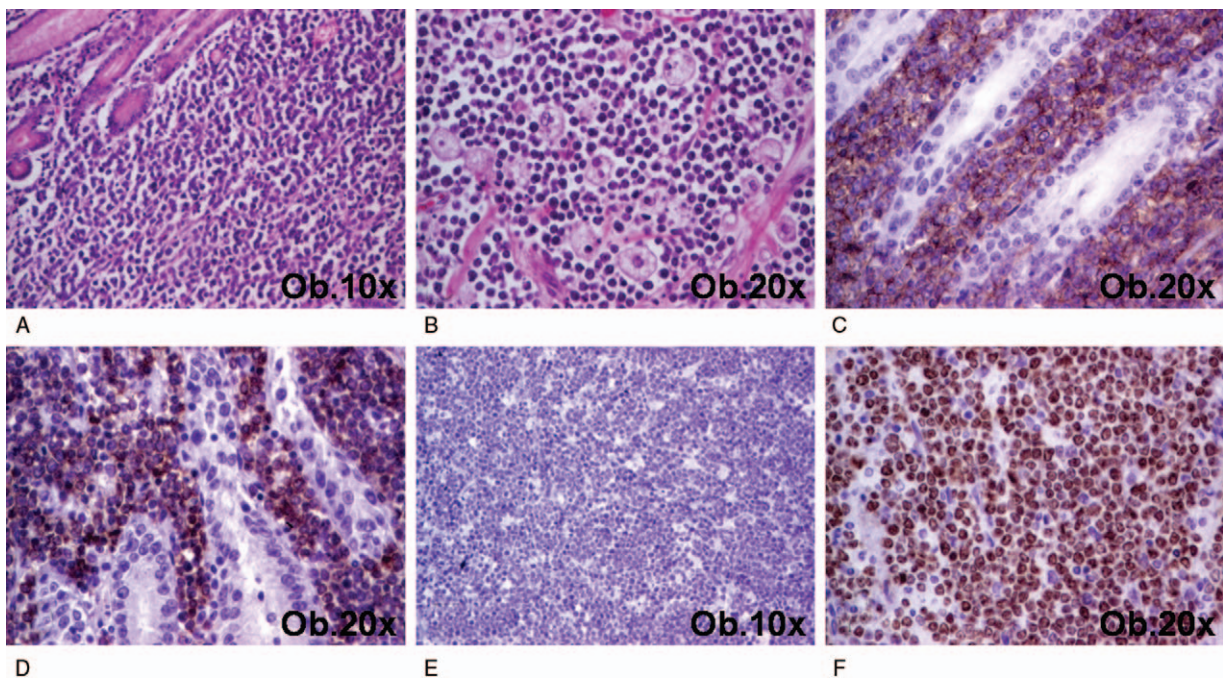


Figure 2. Microscopic findings of gastric Burkitt lymphoma. A, B. In Hematoxylin-Eosine, among glandular structures, proliferation of small Burkitt lymphoma cells admixed with large macrophages is characteristic. C–F. The Burkitt lymphoma cells are marked by CD20 (C) and CD79a (D), are negative for bcl-2 (E), and present a Ki67 index of 100% (F).

the lymphocytes, conferring a “starry-sky” appearance to the lesion (Fig. 2). From the 19 perigastric lymph nodes, 14 presented proliferation of tumor cells that crossed the capsule, invading the surrounding adipose tissue. From the other 9 nodes, 7 were also invaded by tumor cells presented similar architecture with the gastric tumor cells.

Immunohistochemical examination was performed; the neoplastic lymphocytes expressed CD20, CD79a, bcl-6, and CD10, and had a Ki67 index of 100% (Fig. 2). The tumor cells were not reactive for CD3, CD5, CD23, TdT, bcl-2, and Cyclin D1.

On the basis of the above findings, the final diagnosis was BL of the stomach with a highly malignant potential.

3. Discussion

BL is a nodal or extranodal tumor that can be endemic (related on EBV or HIV-infection), sporadic and immunodeficiency-associated.^[2,4,5] As regarding the sporadic BL, although the gastro-intestinal tract is the commonest site, hepatic BL was also reported to occur no later than 1 year after hepatitis B or C virus infection.^[2,4] *Helicobacter pylori* infection, celiac disease, and post-transplant status were associated with extranodal lymphomas and even BL^[6,7] but no papers about concurrent streptococcal infection-related cardiac disorders have been published to date. It is important to mention that associated-eradication of *H pylori* to the chemotherapeutic regimens increased the rate of complete remission in patients with gastric BL.^[7]

However, the population-based yearly incidence of primary malignant gastrointestinal non-Hodgkin lymphoma (NHL) ranges between 0.58 and 1.7/100,000^[8]; with reported increased incidence in North America from 0.13/100,000 in 1999, to 2.39/100,000 in 2007.^[6] From the NHLs of the gastrointestinal tract, 47% to 68% of the cases are diagnosed in stomach (55.74% in our material), >90% of them being B-cell lymphomas.^[6,9]

BL is a very rare variant of gastric lymphomas, representing about 5% of all lymphomas of the stomach and 2.94% in our material (Table 1); large studies revealed no cases of gastric BLs.^[6,9] Gastric BL is mostly diagnosed in middle-aged persons, similar to our case, but young patients were also encountered.^[2,7] It is worthy mentioning that symptoms of patients can be related on the tumor biologic behavior, being about weight loss or progressive anemia, but fatal hemorrhage can also occur, such in the present case.

Postoperatively, diagnosis of BL is very difficult and is mainly based on the immunoprofile and presence of FISH-detected *c-myc* translocation and its fusion with *IgH* gene, which is the trigger of BL-genesis^[10] but can also occur during progression of other types of lymphomas.^[11] Other 70 gene mutations were also described in BL cells including *ID3* (DNA binding protein inhibitor), *GNA13*, *RET*, *IP3K* gene (Inositol-Triphosphate 3-kinase), *PIK3R1*, the *SWI/SNF* genes *ARID1A* and *SMARCA4*, as well as *CCT6B*, *SALL3*, *FTCD*, and *PC*.^[10] In BL-cells it was also observed that *INK4/ARF* gene influences the *p16* and *p14* suppressor genes that control the Rb and p53 pathways.^[9] Due to above mentioned complex genetic background of BL, the genetic determinations should be completed by immunohistochemical stains.^[10] Except *c-myc/IgH* translocation, positivity for B-cell markers CD20 and CD79a, a Ki67 proliferative index >90% and negativity for bcl-2 and/or bcl-6 is required to differentiate BL from DLBCL, which is *c-myc* wild-type, the Ki67 index is >90% and the diagnosis does not depend on the expression of bcl-2 or bcl-6. The intermediate BL/DLBCL lymphomas are diagnosed in cases with Ki67 positivity expressed in >90% of the cells that have 1 of the 2 molecular profiles: cases with *c-myc/IgH* translocation with positivity for at least 1 of the 2 immunohistochemical markers, bcl-2 or bcl-6; or cases without *c-myc/IgH* translocation, independently from the bcl-2/bcl-6 expression.^[10]

In the present case, although the genetic analyses were not performed, being about a postmortem diagnosis, the histological architecture and immunohistochemical profile of the tumor cells (CD10+/bcl-2-/bcl-6+ and a very high Ki67 index) allowed us to establish the diagnosis. However, in the daily practice, certification of diagnosis of BL is necessary to be based on the presence of *c-myc* translocations.

Although BL presents a rapid grow, screening programs could save lives in such cases. Moreover, BL-associated massive hemorrhage can be a life-threatening complication that is very difficult to be therapeutically managed in the advanced-staged cases.

References

- [1] Young LS, Rickinson AB. Epstein-Barr virus: 40 years on. *Nat Rev Cancer* 2004;4:757–68.
- [2] Krugmann J, Tzankov A, Fiegl M, et al. Burkitt's lymphoma of the stomach: a case report with molecular cytogenetic analysis. *Leuk Lymphoma* 2004;45:1055–9.
- [3] Jang SJ, Yoon DH, Kim S, et al. A unique pattern of extranodal involvement in Korean adults with sporadic Burkitt lymphoma: a single center experience. *Ann Hematol* 2012;91:1917–22.
- [4] Sekiguchi Y, Yoshikawa H, Shimada A, et al. Primary hepatic circumscribed Burkitt's lymphoma that developed after acute hepatitis B: report of a case with a review of the literature. *J Clin Exp Hematop* 2013;53:167–73.
- [5] Law MF, Chan HN, Pang CY, et al. Durable survival after chemotherapy in a HIV patient with Burkitt's lymphoma presenting with massive upper gastrointestinal bleeding. *Int J STD AIDS* 2016;27:690–6.
- [6] Howell JM, Auer-Grzesiak I, Zhang J, et al. Increasing incidence rates, distribution and histological characteristics of primary gastrointestinal non-Hodgkin lymphoma in a North American population. *Can J Gastroenterol* 2012;26:452–6.
- [7] Baumgaertner I, Copie-Bergman C, Levy M, et al. Complete remission of gastric Burkitt's lymphoma after eradication of *Helicobacter pylori*. *World J Gastroenterol* 2009;15:5746–50.
- [8] Gurney KA, Cartwright RA. Increasing incidence and descriptive epidemiology of extranodal non-Hodgkin lymphoma in parts of England and Wales. *Hematol J* 2002;3:95–104.
- [9] Geramizadeh B, Keshtkar Jahromi M. Primary extranodal gastrointestinal lymphoma: a single center experience from Southern Iran—report of changing epidemiology. *Arch Iran Med* 2014;17:638–9.
- [10] Aquino G, Marra L, Cantile M, et al. MYC chromosomal aberration in differential diagnosis between Burkitt and other aggressive lymphomas. *Infect Agent Cancer* 2004;8:37.
- [11] Seifert M, Scholtysik R, Küppers R. Origin and pathogenesis of B cell lymphomas. *Methods Mol Biol* 2013;971:1–25.