

# The reduction of volume and fiber bundle connections in the hippocampus of *EGR3* transgenic schizophrenia rats

Ensen Ma,<sup>1,2,\*</sup> Tianbin Song,<sup>3,\*</sup> Hui Zhang,<sup>4,\*</sup> Jie Lu,<sup>5</sup> Liwen Wang,<sup>2</sup> Qichao Zhao,<sup>2</sup> Runcai Guo,<sup>2</sup> Miao Li,<sup>2</sup> Guolin Ma,<sup>2</sup> Guangming Lu,<sup>1</sup> Kefeng Li<sup>6,7</sup>

<sup>1</sup>Department of Medical Imaging, Jinling Hospital, Medical School of Nanjing University, Nanjing, People's Republic of China; <sup>2</sup>Department of Radiology, China-Japan Friendship Hospital, Beijing, People's Republic of China; <sup>3</sup>Department of Radiology, Beijing Shunyi Hospital, Beijing, People's Republic of China; <sup>4</sup>Department of Radiology, First Clinical Medical College, Shanxi Medical University, Taiyuan, People's Republic of China; <sup>5</sup>Department of Radiology, Xuanwu Hospital of Capital Medical University, Xicheng, Beijing, People's Republic of China; <sup>6</sup>School of Medicine, University of California, San Diego, CA, USA; <sup>7</sup>Tianjin SunnyPeak Biotech Co., Ltd, Tianjin, People's Republic of China

\*These authors contributed equally to this work

Correspondences: Guolin Ma  
Department of Radiology, China-Japan Friendship Hospital, No. 2 Yinghua Dongjie, Chaoyang District, Beijing, 100029, People's Republic of China  
Email maguolin1007@qq.com

Guangming Lu  
Department of Medical Imaging, Jinling Hospital, Medical School of Nanjing University, 305 Zhongshan East Road, Xuanwu District, Nanjing, Jiangsu Province, 210002, People's Republic of China  
Email cjr.luguangming@vip.163.com

**Background and objective:** There is a growing consensus that schizophrenia is ultimately caused by abnormal communication between spatially disparate brain structures. White matter fasciculi represent the primary infrastructure for long distance communication in the brain. In this study, we aimed to investigate the white matter connection in schizophrenia susceptible brain regions of *early growth response factor 3 (EGR3)* expressing rats.

**Methods:** A rat model of schizophrenia was created by the transfection of the *EGR3* gene into rat hippocampus. All animals were placed in a fixation system using a commercial rat-dedicated coil. Schizophrenia susceptible brain regions were scanned using in vivo diffusion tensor magnetic resonance imaging. The volume, quantity, average length of fiber bundles, fractional anisotropy, apparent diffusion coefficient, the relative heterosexual fraction, and volume ratio were collected in the whole brain and schizophrenia related brain areas (the hippocampus, thalamus, and prefrontal lobe). MedINRIA software was used for data processing of diffusion tensor and fiber bundles tracking. The fibronectin in relevant brain regions was also analyzed.

**Results:** There was a significant decrease in the volume of the fiber beam through the left hippocampus dentate in the schizophrenia model group in comparison to the control group and the risperidone treatment group ( $P < 0.05$ ). A significant reduction in the volume and number of the fiber bundles was also observed in left prefrontal–left hippocampus, left hippocampus–left thalamus, left prefrontal–left hippocampus–left thalamus areas in the model group (all  $P < 0.05$ ).

**Conclusion:** The volume of hippocampus and the number of fiber bundles were reduced in *EGR3* transgenic schizophrenia rats, and are the most sensitive indicators in schizophrenia. The diffusion tensor imaging technique plays an important role in the evaluation of patients with schizophrenia.

**Keywords:** magnetic resonance imaging, schizophrenia, *early growth response factor 3*, fractional anisotropy, diffusion tensor imaging

## Introduction

Schizophrenia is a chronic mental disorder characterized by severe perturbations in cognition, affect, and behavior.<sup>1</sup> The *early growth response factor 3 (EGR3)* rat is a transgenic insertional mutant that models several aspects of the behavioral and molecular pathology expressed in schizophrenia.<sup>2,3</sup> For instance, the rat mutant shows behavioral abnormalities, including novelty-driven hyperactivity that is manifested as increased circling activity in the open field.<sup>4</sup> As these abnormalities are often diagnosed in patients with schizophrenia, genetically mutant *EGR3* rat might be relevant for understanding or pinpointing psychoses-causing mechanisms.

The magnetic resonance imaging (MRI) technique especially suited for the analysis of white matter tracts makes possible the direct assessment of large axon masses.<sup>5</sup>

Diffusion-weighted MRI can be used to distinguish normal and abnormal tissues on the basis of the molecular motion of water molecules (Brownian motion).<sup>6</sup> The method is sensitive to disruptions of commissural bundles or tracts. It can be used to study regional axonal connectivity, myelin packing, and fiber orientation.<sup>5,6</sup> The brain white matter tract abnormalities, as demonstrated by diffusion tensor imaging (DTI) techniques, are common occurrences in adult schizophrenia.<sup>1,7,8</sup> It is proposed that schizophrenia arises from a unique human brain network associated with directed effort including the dorsal anterior and posterior cingulate cortex, auditory cortex, and hippocampus.<sup>9</sup>

As rats share important biochemical and genomic similarities with humans, *EGR3*-transfected schizophrenia-like rat model could recapitulate certain aspects in patients with schizophrenia. Risperidone is a typical antipsychotic medication used to treat mental illnesses such as schizophrenia, bipolar disorder, and irritability associated with autism disorder.<sup>10</sup> There is no evidence about the changes of brain structure caused by risperidone.

In this study, we first created a rat model of schizophrenia by the transfection of lentiviral particles carrying the *EGR3* gene into the hippocampus. We then investigated the functional connectivity and anatomical connections of white matter tracts in important brain areas (prefrontal cortex, hippocampus, thalamus) in *EGR3* rats using the DTI technique. The changes of functional connectivity in the brain of schizophrenia-like rats before and after risperidone therapy were also explored.

## Materials and methods

### Animals and husbandry

A randomized, controlled animal study was conducted in the School of Medicine, Peking University, People's Republic of China, in accordance with the guidance suggestions for the care and use of laboratory animals, issued by the Ministry of Science and Technology of the People's Republic of China.<sup>10</sup> Twenty-four healthy, male Sprague Dawley rats (aged 4 weeks, weighing 100±10 g) were purchased from Vital River, Beijing, People's Republic of China (license no SCXK [Jing] 2012-0001). Animals were housed in a temperature (22°C–24°C) and humidity (40%–55%) controlled vivarium. The experimental procedures and the animal use and care protocols were approved by the Committee on Ethical Use of Animals of China-Japan Friendship Hospital. Standard rat food was used and the animals had free access to water and food during the whole study.

### Viral vector

Lentiviral particles containing the *EGR3* gene were purchased from the Fuyishengke Biomedical Scientific Research

Service Center, Shanghai, People's Republic of China. The sequence is based on NCBI Reference Sequence: NM\_018781.2. The lentivirus was packaged using a four-plasmid system containing psPAX2 (vector), pMD2G, pLVX-IRES-ZsGreen1 (vector + *GFP*), and pLVX-IRES-ZsGreen1-*EGR3* (vector + *GFP* + *EGR3*).

### *EGR3* transfection

To construct the rat schizophrenia model, the lentivirus particle carrying the *EGR3* gene was injected bilaterally into the hippocampus of rats as previously described.<sup>4</sup> Briefly, the rats were anesthetized by intraperitoneal injection with 10% chloral hydrate (1.5 mL/kg), and placed in a stereotaxic frame (ST-51600; Kopf Instruments, Tujunga, CA, USA). The skin of the calvarium was sterilized with 75% alcohol, and an incision of approximately 0.5 cm was made. After sterilization with 0.05% hydrogen peroxide (H<sub>2</sub>O<sub>2</sub>), the bregma was exposed. Bilateral holes (0.8 mm) were drilled in the skull above the injection site using a cranial drill (Figure S1A). The lentivirus particle was slowly injected into each side of the hippocampus (−3.0 mm anteroposterior and ±2.0 mm mediolateral to bregma; −2.2 mm dorsoventral to the skull surface) using a 1 µL microinjector over 20 minutes (Figure S1B). The needles were maintained in position for a further 20 minutes, and then the incision was sutured. The animals were returned to their home cages when they could move spontaneously. Rats in the sham-surgery group (n=6) underwent an identical procedure except the lentivirus particle carried *GFP* instead of *EGR3*. The location of *EGR3* expression was checked by immunofluorescence staining of rat brain tissues according to previous protocols. The image was acquired using Nikon Ti Eclipse Confocal Microscope (Nikon, Tokyo, Japan). The number of positive cells in the visual field was counted (n=6).<sup>11</sup> Morris water-maze working memory test and the open-field test were used to characterize *EGR3*-transfected schizophrenia model as described before.<sup>4</sup>

After a 2-week recovery period, *EGR3*-transfected rats received intraperitoneal injections of risperidone (0.2 mg/kg) (Sigma, St Louis, MO, USA) for 14 consecutive days. The other three groups received intraperitoneal injections of normal saline at each administration time point corresponding to the risperidone treatment. In summary, four groups were set up in this study with 8–13 replicates in each group including control group (rats without surgery + normal saline), sham group (rats + *GFP* gene + normal saline), schizophrenia model group (rats + *EGR3* gene + normal saline), and treatment group (rats + *EGR3* gene + risperidone).

## DTI imaging acquisition

The imaging data were acquired on a Phillips 3.0 T Achieva scanner (Philips, Amsterdam, the Netherlands) using a standard whole-body rat coil (Shanghai Chenguang Medical Science and Technology, Shanghai, People's Republic of China). The rats were anesthetized by intraperitoneal injection of 10% chloral hydrate (1.5 mL/kg) before scanning. The rats were placed in prone position and the heads of rats were fixed with a vacuum pillow and band to reduce head movement. First, T2WI coronal, axial, and sagittal images were collected using spin echo sequence. T2WI image parameters were as follows: field of view (FOV) = 40×40×10 mm, time of repetition (TR) = 1,696 ms, time of echo (TE) = 96 ms, number of slices = 7, slice thickness = 1.5 mm, layer space = 1.5 mm, and number of signal average (NSA) = 3. Next, larger FOV and more detailed T2WI Images were collected using these parameters: FOV = 40×40×30 mm, TR = 2,800 ms, TE = 96 ms, slice number = 20, slice thickness = 1.5 mm, interlayer space = 0 mm, NSA = 10, flip angle of 90°, a total scan time of 10 minutes and 27 seconds, and an acquisition matrix of 132×127. Further DTI images were obtained using single-shot spin-echo planar imaging (EPI) sequence on coronal imaging of rat brain with the following parameters: 32 different directions were used on diffusion sensitive gradient, TR = 4,000 ms, TE = 85 ms, slice thickness = 1.5 mm, no interval scan, FOV = 40×40×30 mm, acquisition matrix of 116×117, and slice number = 20. Diffusion-weighted coefficients (*b* values) were 0 s/mm<sup>2</sup> and 1,000 s/mm<sup>2</sup>, NSA = 2. Total time was 22 minutes and 44 seconds.

## Data processing and analysis

Diffusion tensor and fiber bundle tracking data were processed using MedINRIA-1 (v9.4). The diffusion tensor matrix, eigenvalues ( $\lambda_1, \lambda_2, \lambda_3$ ), and eigenvector values were calculated by MedINRIA-1. Each point of the main direction is consistent with the maximum eigenvalue eigenvector direction. Fractional anisotropy (FA) value is a parameter commonly used to characterize anisotropy. The apparent diffusion coefficient (ADC) represents tensor tracking and is also frequently used to characterize the anisotropy. Both FA and ADC were calculated using the following formula:

$$FA = \sqrt{\frac{3}{2} \left( \frac{(\lambda_1 - \bar{\lambda})^2 + (\lambda_2 - \bar{\lambda})^2 + (\lambda_3 - \bar{\lambda})^2}{\sum_{i=1}^3 \lambda_i^2} \right)} \quad (1)$$

$$ADC = \sum_{i=1}^3 \lambda_i \quad (2)$$

First, all the imaging data of 24 rats in the four groups were analyzed with whole-brain DTI and fiber bundle

tracking process. Parameter settings were as follows: the threshold of background removal was 200, threshold of FA was 200, threshold of smoothing was 20, minimum length was 10 mm, and samples were 25. The required anisotropy index includes the fiber bundle volume, quantity, average length, FA, ADC, relative anisotropy (RA), and volume ratio (VR). Next, the left and right anterior frontal, left, and right hippocampus and the left and right thalamus were selected as the regions of interest (ROI) to be analyzed with whole-brain DTI and the fiber bundle tracking process, respectively. The required anisotropy index was also calculated for the selected brain regions.

Finally, to perform the DTI and fiber bundle tracking process, the brain ROI were selected. The ROI included the bilateral prefrontal cortex, bilateral hippocampus, thalamus, right anterior frontal lobe–the hippocampus, right prefrontal–thalamus, right side of the hippocampus–thalamus, right prefrontal–hippocampus–thalamus, left anterior frontal lobe–the hippocampus, left anterior frontal lobe–thalamus, left hippocampus–thalamus, and left anterior frontal lobe–hippocampus–hypothalamus (Figure S2). The anisotropy index and fiber connections were also analyzed for the brain ROI.

## Statistical analysis

Statistical analysis was performed using SPSS (v17.0; SPSS, Chicago, IL, USA) and GraphPad Prism 6 (GraphPad Software, Inc., San Diego, CA, USA). All values were expressed as mean ± standard deviation unless stated in the text. One-way ANOVA followed by post hoc Tukey's test were used to calculate the anisotropy index variability among the four groups. A *P*-value less than 0.05 was considered to be significantly different.

## Results

### Verification of EGR3-transfected rat model of schizophrenia

The expression of the *EGR3* gene in the hippocampus of rat brain was analyzed 1 week after the lentivirus injection. The number of *EGR3*-positive cells was 2.67 times higher in the model group than in the *GFP* transfection sham group (Figure S3). Morris water-maze and open-field experiments were used to test whether the rats with *EGR3* gene transfection have schizophrenia-like behaviors. The water maze experiment showed that the escape latency time in rats with *EGR3* gene transfection was significantly longer than in the control group and the sham group ( $P < 0.05$ ), suggesting that the *EGR3* gene transfection group showed poor working memory capacity (Figure S4).

**Table 1** The comparison of whole-brain DTI anisotropy index and fiber bundle tracking index in four groups of rats

Anisotropy index	No surgery + saline	GFP + saline	EGR3 + saline	EGR3 + risperidone
Volume (mm <sup>3</sup> )	861.96±94.45	906.20±53.06	861.92±42.50	837.21±30.90
Number	403±43.31	540.25±37.33	474.66±31.56	441.33±65.62
Length (mm)	13.81±0.50	13.44±0.27	13.67±0.70	13.39±0.19
FA	0.59±0.007	0.59±0.003	0.58±0.013	0.58±0.006
ADC (mm <sup>2</sup> /s)	0.75±0.144	0.84±0.13	0.81±0.18	0.97±0.27
RA	0.26±0.025	0.27±0.022	0.26±0.032	0.28±0.025
VR	0.019±0.0005	0.019±0.0002	0.019±0.0007	0.019±0.0003

**Notes:** N=6,  $F=0.3105$ ;  $P=0.9969$ ; data was mean ± SD.

**Abbreviations:** DTI, diffusion tensor imaging; GFP, green fluorescent protein; EGR3, early growth response factor 3; FA, fractional anisotropy; ADC, apparent diffusion coefficient; RA, relative anisotropy; VR, volume ratio.

## DTI and fiber bundles tracking in whole brain of rats

There was no statistically significant difference in the anisotropy index including fiber bundle volume, number of fibers, average length, FA, ADC, RA, and VR, in the whole brain, among the *EGR3* gene transfection schizophrenic group, sham operation group, risperidone treatment group, and the control group (Table 1).

## DTI and fiber bundles tracking hippocampus

There was no statistically significant difference in the anisotropy index which including fiber bundle volume, number, the average length, FA, ADC, RA, and VR of the right hippocampus, among *EGR3* gene transfection schizophrenic group, sham operation group, risperidone treatment group, and the control group (Table 2).

The white fiber bundle volume in left hippocampus were remarkably decreased in the *EGR3* gene transfection schizophrenic group compared with that in the control group and the sham group (Figure 1). Risperidone treatment restored the volume of white fiber back to normal (Figure 1). No significant changes were observed in the length, FA, ADC,

RA, and VR in the left hippocampus among the four groups ( $P>0.05$ ) (Table 3).

There was a significant reduction of the white fiber bundle volume and number in the bilateral hippocampus in the *EGR3* gene transfection schizophrenic group compared with that in the sham operation group ( $P<0.05$ ). The decrease of white fiber bundle was normalized by risperidone treatment (Figure 2).

## Connectivity between ROI in schizophrenia rat model

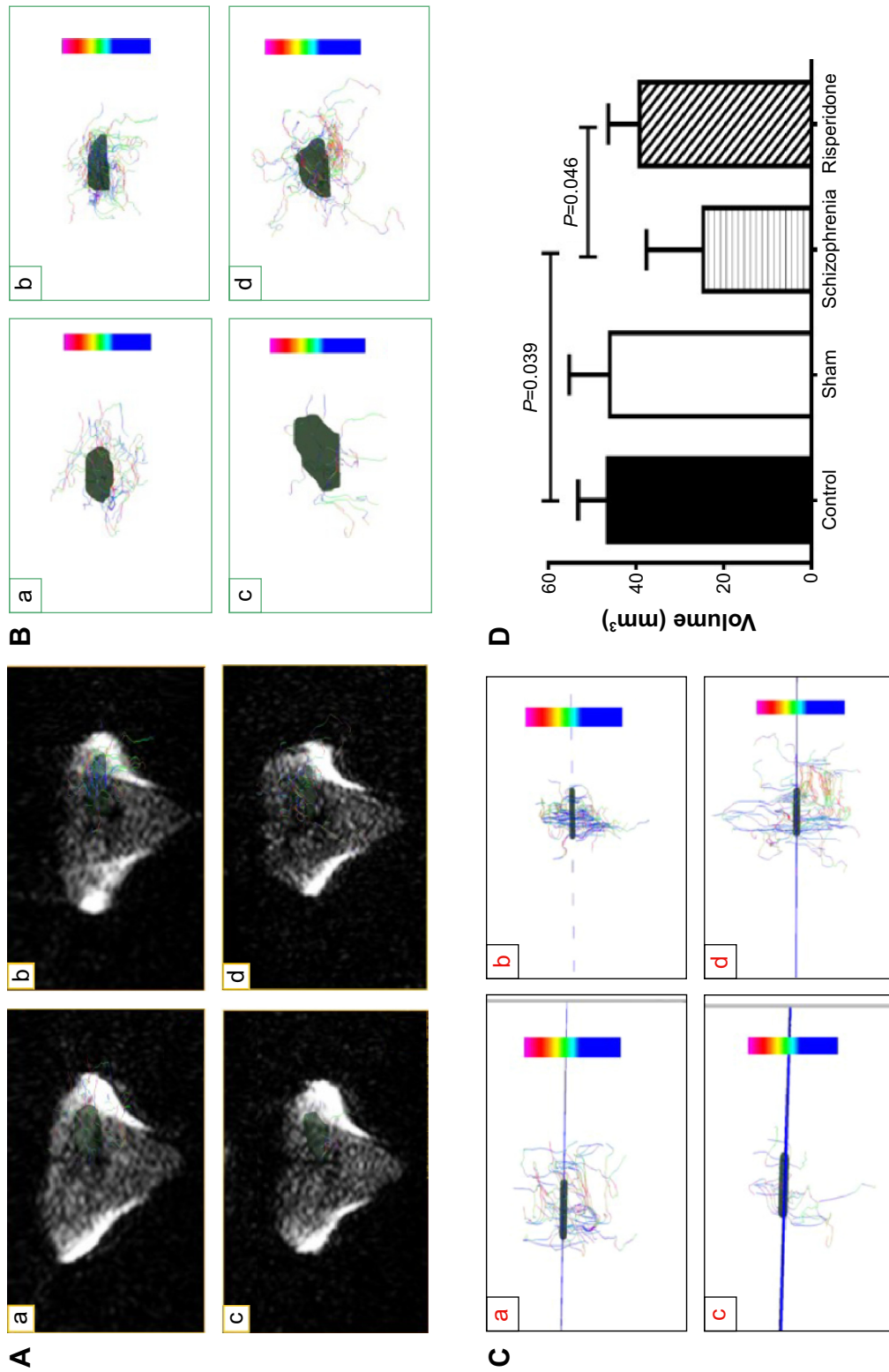
Figure 3 showed the fiber connections between the brain regions. There were no fiber bundle connections (red line) between the left and right sides of the brain regions associated with schizophrenia. A large number of white matter fiber tract connections can be observed in ipsilateral schizophrenia related brain regions (green and blue lines). While fiber bundle connections exist in the right prefrontal–right hippocampus, right anterior frontal lobe–right thalamus, right hippocampus–right thalamus, right prefrontal–right hippocampus–right thalamus, and left prefrontal–left thalamus between the four groups, there were no significant differences among the four groups (green line).

**Table 2** Comparison of right hippocampus DTI anisotropy index and fiber bundle tracking index in four groups of rats

Anisotropy index	No surgery + saline	GFP + saline	EGR3 + saline	EGR3 + risperidone
Volume (mm <sup>3</sup> )	26.56±6.49	25.01±2.30	31.04±4.17	26.22±4.99
Number	14.6±2.97	6.33±1.40	15.83±3.22	21.8±5.13
Length (mm)	13.83±0.67	13.35±0.48	14.21±0.46	14.33±0.50
FA	0.59±0.005	0.60±0.004	0.57±0.009	0.59±0.003
ADC (mm <sup>2</sup> /s)	0.58±0.027	0.55±0.020	0.72±0.114	0.66±0.035
RA	0.23±0.003	0.23±0.006	0.24±0.011	0.25±0.006
VR	0.019±0.0033	0.018±0.0014	0.020±0.0025	0.019±0.0043

**Notes:** N=6,  $F=2.237$ ,  $P=0.07$ ; data was mean ± SD. There were no significant differences among the four groups in terms of volume, the number of fibers, length, FA, ADC, RA, and VR ( $P<0.05$ ).

**Abbreviations:** DTI, diffusion tensor imaging; GFP, green fluorescent protein; EGR3, early growth response factor 3; FA, fractional anisotropy; ADC, apparent diffusion coefficient; RA, the relative fraction of the opposite sex; VR, volume ratio.



**Figure 1** Significant reduction of white fiber bundle volume in left hippocampus of rats with *EGR3* gene transfection. **Notes:** a, control; b, sham group; c, *EGR3* transfection model group; d, risperidone treatment group. **(A)** Registration of white fiber bundle and anatomy; **(B)** DTI demonstrates the white fiber bundle on coronal view; **(C)** DTI demonstrates the white fiber bundle on axial view; **(D)** statistical analysis of white fiber volume,  $P=0.039$  for control vs model group and  $P=0.046$  for schizophrenia vs risperidone treatment group. The color in **B** and **C** indicates the relative directions ( $0^\circ$ - $90^\circ$ ) of fiber bundles in brain white matter. Blue color ( $0^\circ$ ) indicates the fiber bundles were horizontal to the X-axis. Pink color ( $0^\circ$ ) indicates the fiber bundles were vertical to the X-axis. **Abbreviations:** *EGR3*, early growth response factor 3; DTI, diffusion tensor imaging.

**Table 3** Comparison of DTI anisotropy index and fiber bundle tracking index in left hippocampus in four groups of rats

Anisotropy index	No surgery + saline	GFP + saline	EGR3 + saline	EGR3 + risperidone
Volume (mm <sup>3</sup> )	42.6±4.62 <sup>a</sup>	44.23±7.25 <sup>a</sup>	29.28±6.99 <sup>a</sup>	46.52±7.83 <sup>a</sup>
Number	24.8±2.78	27.16±6.13	22.66±4.23	35.4±4.09
Length (mm)	14.70±0.46	14.91±0.43	13.93±0.72	15.19±0.38
FA	0.58±0.006	0.58±0.003	0.58±0.004	0.58±0.003
ADC (mm <sup>2</sup> /s)	0.64±0.04	0.68±0.05	0.62±0.02	0.75±0.06
RA	0.24±0.007	0.25±0.010	0.23±0.006	0.25±0.01
VR	0.019±0.0024	0.020±0.005	0.019±0.0001	0.020±0.005

**Notes:** N=6, data was mean ± SD. Data indexed by different letters in the same line indicated the significant difference among the groups (<sup>a</sup>P<0.05).

**Abbreviations:** DTI, diffusion tensor imaging; GFP, green fluorescent protein; EGR3, early growth response factor 3; FA, fractional anisotropy; ADC, apparent diffusion coefficient; RA, the relative fraction of the opposite sex; VR, volume ratio.

The volume and number of fiber connections between the left anterior frontal lobe and the left hippocampus were significantly decreased in the *EGR3* transfection schizophrenic group compared with the other three groups (Figure 4). There were no significant differences in the length, FA, ADC, RA, and VR of the fiber connections (data not shown). Similarly, we found a significant reduction of fiber connections (both volume and number) between the left hippocampus and the left thalamus and the connections were restored after risperidone treatment (Figure 5). In addition, both the number and volume of the three consecutive connections among left anterior frontal lobe–left hippocampus–left thalamus were significantly decreased in the *EGR3* gene transfection schizophrenic group (Figure 6). No changes in the fiber length were noticed. The volume and number of connections were restored after risperidone treatment.

Correlations between the volume and the number of white fiber bundles were then analyzed in schizophrenia related brain areas. The results showed that the volume and number of the white fiber bundles were highly correlated in the connections of left hippocampus–left thalamus and left anterior frontal lobe–left hippocampus–left thalamus in

the schizophrenia model group, but not in the control group (Figure 7).

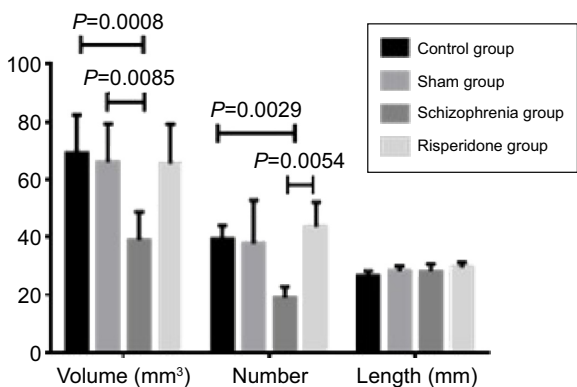
## Discussion

### The methods for DTI data analysis

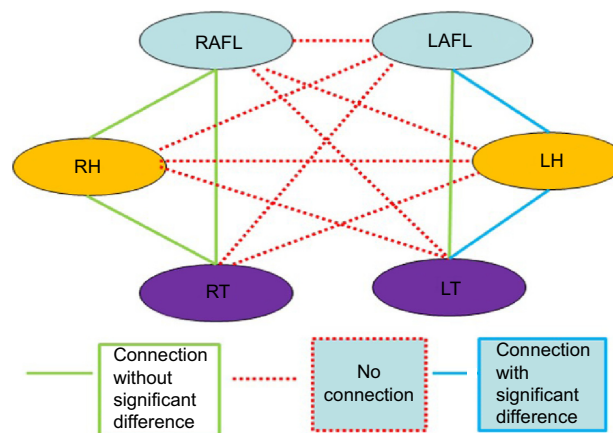
DTI may be used to study the commissural white matter pathways. The method is sensitive to the disruptions of commissural bundles or tracts. Three methods were used to analyze DTI data using ROI drawing with freehand, voxel-based analysis (VBA), and fiber tracking.<sup>11,12</sup>

Although functional and structural brain imaging studies have revealed diverse brain abnormalities in schizophrenia, no single brain region has been either clearly or consistently identified as the site of the disorder.<sup>1</sup> Therefore, the ROI method is difficult to reflect the panorama of the lesion. More and more researchers tend to use VBA.

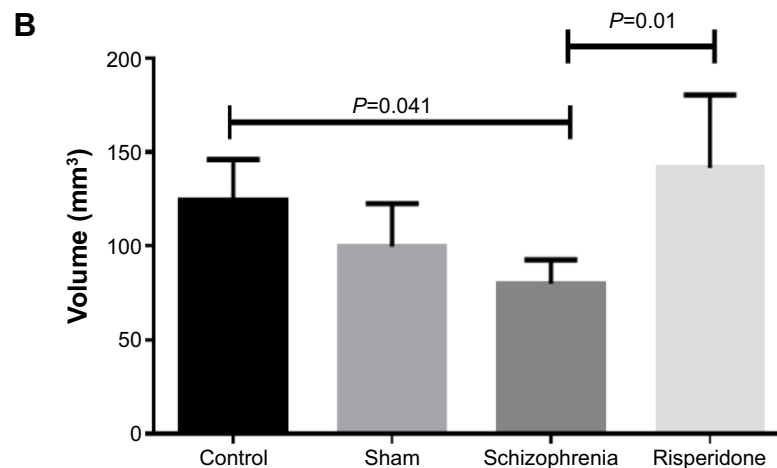
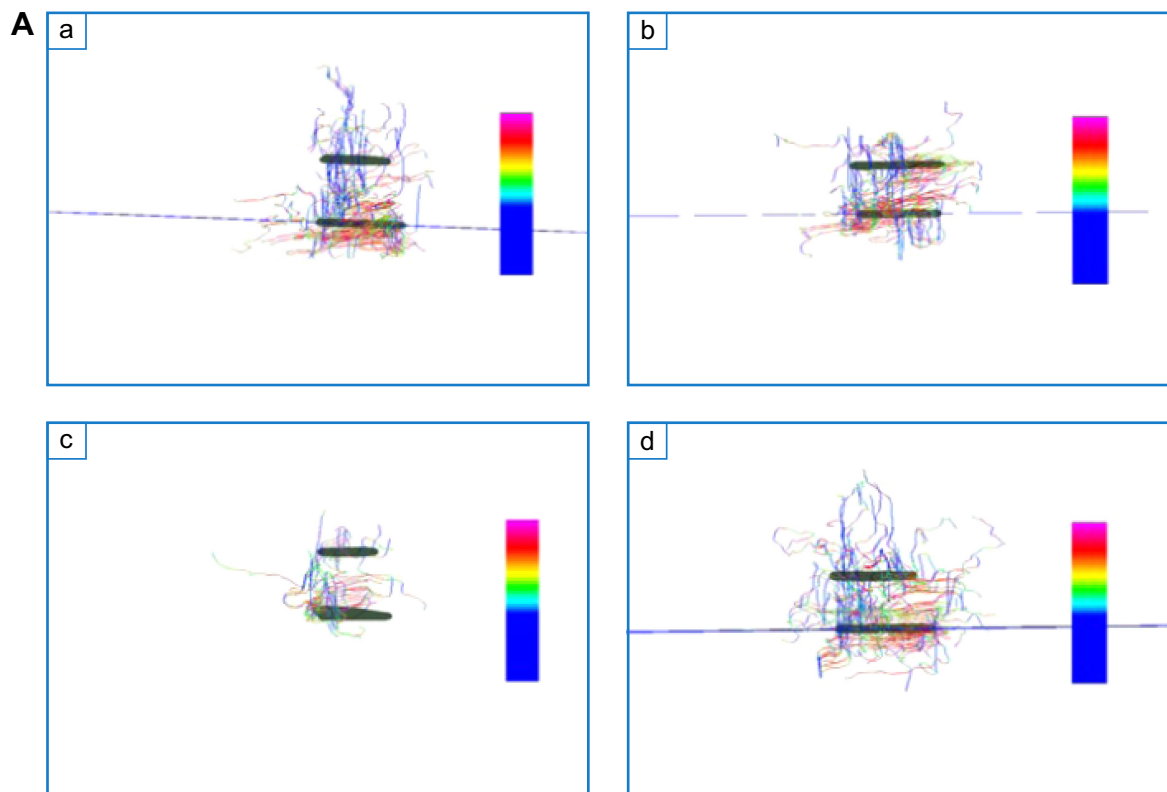
The optimized voxel-based morphometry (VBM) method is a type of morphological study method, with the voxel as a basic unit used to compare the whole brain. The advantages of the VBM method are that there is no bias on a specific



**Figure 2** Statistical analysis of white fiber volume, number, and length in bilateral hippocampus.



**Figure 3** Schematic diagram of brain connections between different brain regions. **Abbreviations:** RAFL, right prefrontal; LAFL, left prefrontal; RH, right hippocampus; LH, left hippocampus; RT, right thalamus; LT, left thalamus.



**Figure 4** The white fiber connection between the left anterior frontal lobe and left hippocampus.

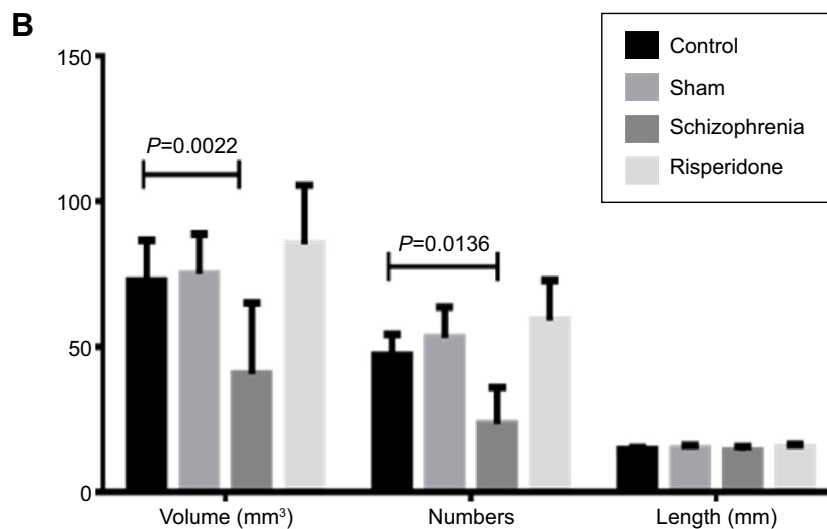

**Notes:** a, control; b, sham group; c, *EGR3* transfection; d, risperidone treatment group. (A) DTI demonstrates the white fiber bundle connection on axial view; (B) statistical analysis of fiber volume,  $P=0.041$  for control vs model group and  $P=0.01$  for model group vs risperidone treatment group.

**Abbreviations:** *EGR3*, early growth response factor 3; DTI, diffusion tensor imaging.

structure, and the method can be used to comprehensively evaluate the whole brain. The method can also reflect abnormal connections between the morphological structures of the whole brain regions. In addition, the method is not restricted to one or a few regions and is more suitable for the diffusion tensor vector analysis in patients with schizophrenia.

Fiber tracking is a technology that could reconstruct the three-dimensional structure along the fiber bundle.

This technique can provide detailed information about anatomical connections between brain areas, and indirectly provide clues on the activation process of each node in the research of functional magnetic resonance imaging (fMRI) neural networks. This kind of information is very important to explore the synchronization between cortical areas and to interpret fMRI results for further determination of the networks involved in the cognitive process.



**Figure 5** White fiber connection between left hippocampus and left thalamus. **Notes:** a, control; b, sham group; c, *ERG3* transfection; d, risperidone treatment group. **(A)** DTI demonstrates the white fiber bundle connection on coronal view; **(B)** statistical analysis of fiber volume,  $P=0.0022$  for control vs schizophrenia in volume and  $P=0.0136$  for control vs model group in number. **Abbreviations:** *EGR3*, early growth response factor 3; DTI, diffusion tensor imaging.

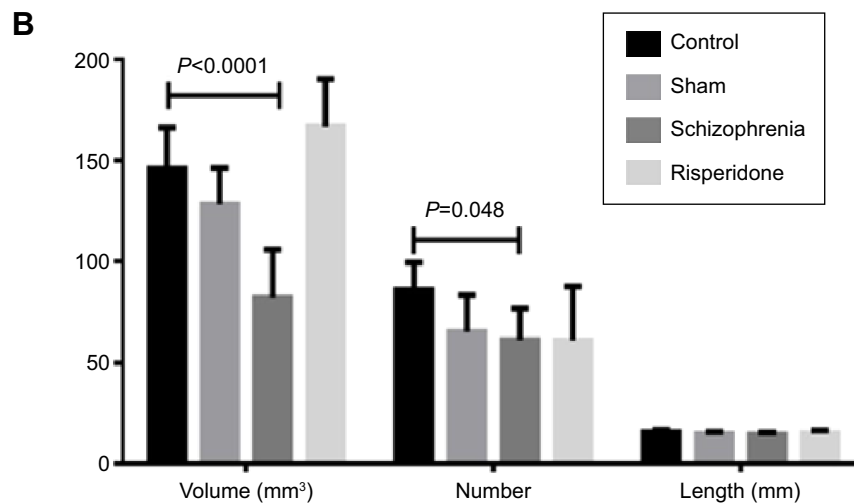
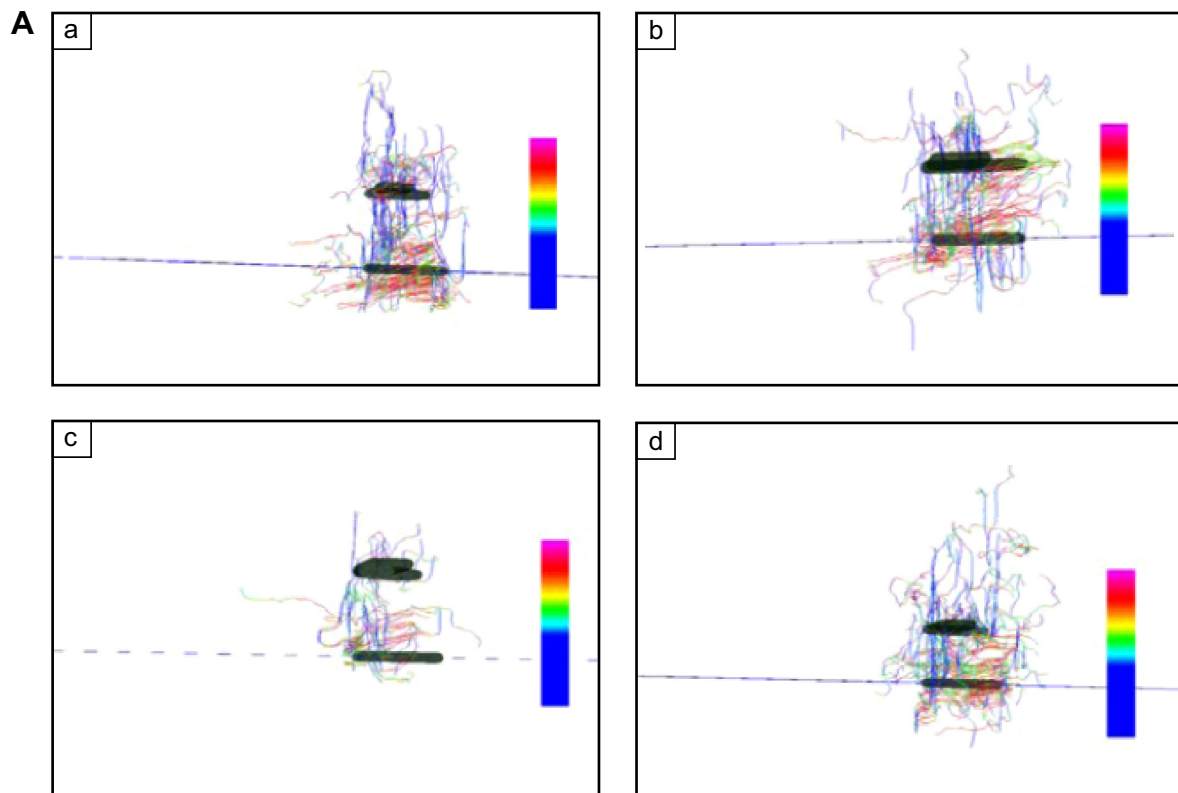
Because there are no standard fMRI brain templates in rats, the whole-brain registration analysis based on voxel and fiber tracking cannot be used. DTI and fiber tracking were obtained by combining the method of copying the freehand drawing of ROI and automatically importing ROI from the software. DTI could reflect abnormal connections between the morphological structures of the whole brain and brain

regions. The DIT technique is more useful for the diffusion tensor vector analysis in patients with schizophrenia.

### The abnormal brain fiber connection in white matter of schizophrenic rats

The previous study reported that the FA value of the left hippocampus head is lower than that in the control group in one





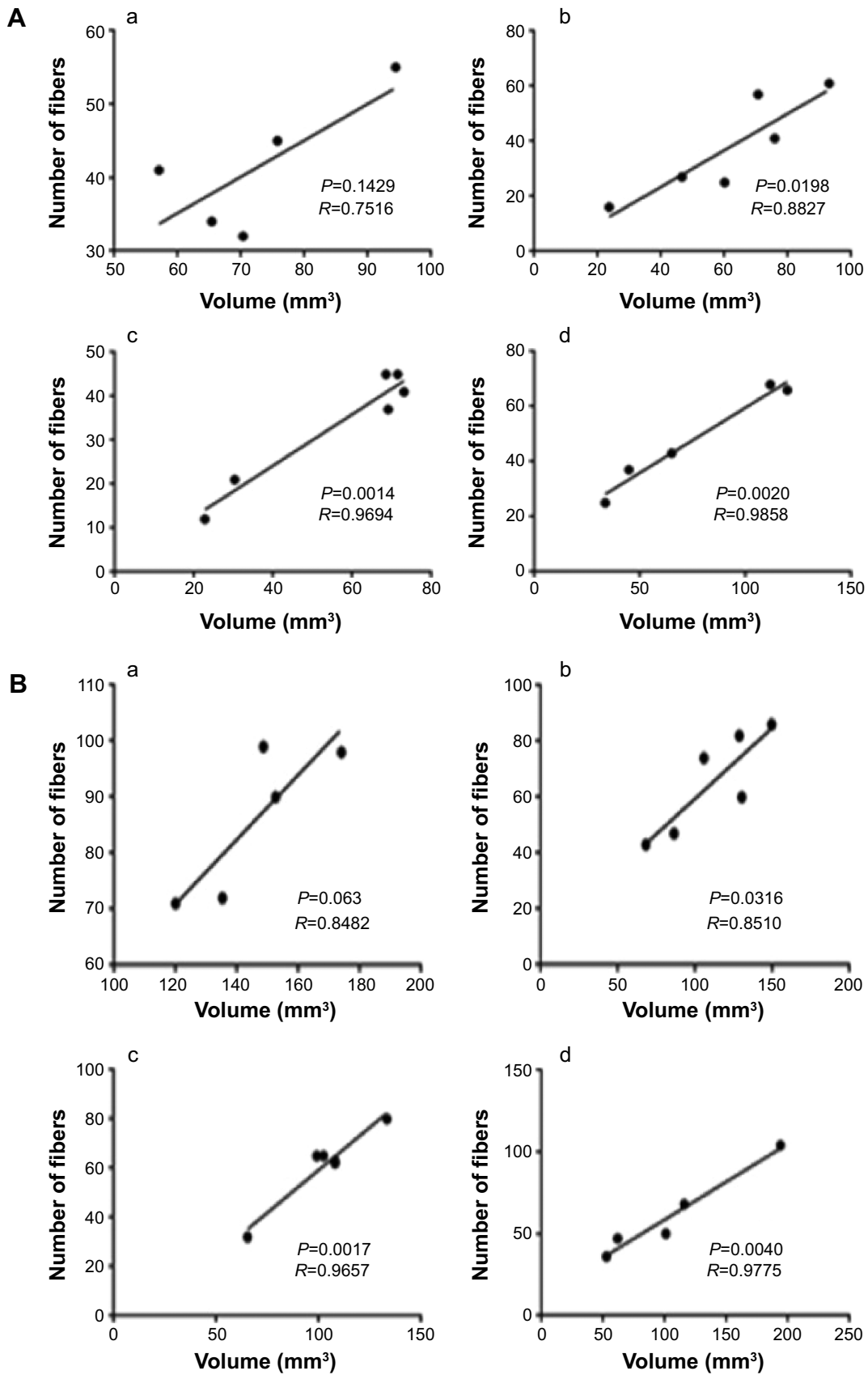
**Figure 6** White fiber consecutive connections of the left anterior frontal lobe–left hippocampus–left thalamus.

**Notes:** a, control; b, sham group; c, *EGR3* transfection; d, risperidone treatment group. (A) DTI demonstrates the white fiber connection on axial view; (B) statistical analysis of fiber volume,  $P < 0.0001$  for control vs model group in volume and  $P = 0.048$  for control vs model group in number.

**Abbreviations:** *EGR3*, early growth response factor 3; DTI, diffusion tensor imaging.

DTI study in patients with first-episode schizophrenia, suggesting that the fiber bundle of the left hippocampus head in patients with first-episode schizophrenia is abnormal.<sup>13</sup> In this study, we also found that the damage of white matter fiber tracts were not in the global brain regions of early schizophrenia. They only appear in susceptibility related brain regions. We found that the left hippocampus is one of the

regions involved during the development of schizophrenia. A meta-analysis of studies on white matter volumes in schizophrenia revealed a reduction of approximately 2% in medial temporal lobe structures.<sup>14</sup> Indeed, regional rather than global reductions are far more relevant to the question of the origins of disconnection and hence are of particular interest in the presence of symptoms.



**Figure 7** Correlation between fiber number and volume.

**Notes:** a, control; b, sham group; c, *EGR3* transfection; d, risperidone treatment group. (A) Connections between left hippocampus and left thalamus; (B) consecutive connections of the left anterior frontal lobe–left hippocampus–left thalamus.

**Abbreviation:** *EGR3*, early growth response factor 3.

No significant differences in the anisotropy index including the fiber bundle volume, number of fibers, average length, FA, ADC, RA, and VR in the right hippocampus were observed in the *EGR3* expressing rat model of schizophrenia. We found that the white fiber bundle volume in the bilateral hippocampus was remarkably decreased in the *EGR3* gene transfection schizophrenic group compared with that in the other three groups. These results further illustrated that the hippocampus is a susceptible brain area. The reduction of the fiber bundle volume and number of fibers is one of the most sensitive detection indexes in schizophrenia.

### Default network analysis of the *EGR3* transgenic schizophrenia model contributes to the understanding of brain function connection mode

Some brain regions, such as the medial prefrontal cortex, anterior and posterior cingulates, as well as inferior temporal, lateral parietal, and cerebellar regions, are particularly active during “rest” and are deactivated during a variety of cognitive tasks. These brain regions form the “default network”.<sup>15,16</sup> This concept has become a central theme in contemporary cognitive and clinical neuroscience. Symptoms of schizophrenia, such as basic personality change, cogitation, emotion, splitting behavior, and lack of coordination between mental activity and the environment, might be associated with an impaired default network.<sup>15</sup> The abnormal connections of the default network might be present in schizophrenia. Disturbances of interconnections between brain structures in schizophrenia were one of the explanations.<sup>15,16</sup> Our DTI studies of *EGR3* transgenic schizophrenia models help understand white matter fiber connections pathways. Disturbances in the connectivity between brain regions, including the frontal lobe, basal forebrain, and limbic system, have been reported in schizophrenia.<sup>17–21</sup> Connections between the prefrontal cortex and other cortical and subcortical regions in the pathophysiology of schizophrenia suggested that a white matter abnormality in this region is critical to the core symptoms of schizophrenia.

Currently, studies on the default network connection of schizophrenia have suggested that the hyperactivity in function activities exists in the schizophrenic default network.<sup>22–25</sup> The exact role of the default network in schizophrenia patients is still not clear. Further fMRI studies are needed to reveal the changes of default network connections in patients with schizophrenia.

Many DTI studies in patients with schizophrenia have demonstrated the damage of cerebral white matter integrity,

mainly related to the white matter fiber of frontal and temporal lobe, as well as the major nerve fiber bundles of the human brain, such as the corpus callosum, anterior cingulate, hook beam, arched beam, and internal capsule.<sup>17,26,27</sup> DTI could demonstrate the abnormal function connection on the basis of abnormal anatomy connection in patients with schizophrenia. A previous study found that anatomical and functional connections can always match each other in the local area or in the globe brain if DTI and static status function connection analysis are combined.<sup>28</sup> Because the widely distributed abnormal function connection exists in patients with schizophrenia, it is necessary to explore the relationship between the anatomical features and functions of the brain.

Our study demonstrated that there were no fiber bundle connections between the left and right sides of the brain regions associated with schizophrenia. Possible reasons for the lack of interhemispheric connections may be related to the direction of white matter fiber, threshold setting in postprocessing, and resolution of the image.<sup>29</sup> Ipsilateral related brain areas have a large number of white matter fiber bundle connections. Right frontal lobe–right hippocampus, right frontal lobe–right thalamus, right hippocampus–right thalamus, right frontal lobe–right hippocampus–right thalamus, and left prefrontal–left thalamus have fiber connections with no significant differences between the schizophrenic rat group and the control group. However, there are fiber connections in left prefrontal–left hippocampus, left hippocampus–left thalamus, and left frontal lobe–left hippocampus–left thalamus with a significant reduction in the schizophrenic rat group in comparison to the control group.

The white fiber bundle connections in the left anterior frontal lobe–left hippocampus, left hippocampus–left thalamus, and left anterior frontal lobe–left hippocampus–left thalamus were also significantly decreased in the *EGR3* gene transfection schizophrenic group compared with the other three groups. Compared with the control group, the fiber bundle volume of left prefrontal–left hippocampus, left hippocampus–left thalamus, and left frontal lobe–left hippocampus–left thalamus have significant differences in the *EGR3* gene transfection schizophrenia group. The fiber bundle volume of left prefrontal–left hippocampus, left hippocampus–left thalamus, and left frontal lobe–left hippocampus–left thalamus decreased significantly in the *EGR3* gene transfection schizophrenia group too. No significant difference was observed in the fiber connections between left prefrontal and left thalamus. This might be because of the long distances between the two brain regions.

Furthermore, in this study, a significant correlation was observed between the volume and number of the white fiber bundles in left hippocampus–the left thalamus ROI and anterior frontal lobe–left hippocampus–the left thalamus ROI. This indicated that the reduction in the number and volume is synchronized.

## Conclusion

Hippocampus is a brain region highly susceptible to damage in *EGR3* transgenic schizophrenia rats. The volume of the hippocampus and number of fiber bundles were significantly reduced in *EGR3* transgenic schizophrenia rats, and are the most sensitive indicators in schizophrenia. The DTI technique may play an important role in the diagnosis and follow-up evaluation of schizophrenia in the future.

## Acknowledgments

This project was supported by the National Science and Technology Support Program (2012BAI10B02) and the National Science Foundation of China (81471652), and an internal grant from China-Japan Friendship Hospital, People's Republic of China (2014-3-MS-18).

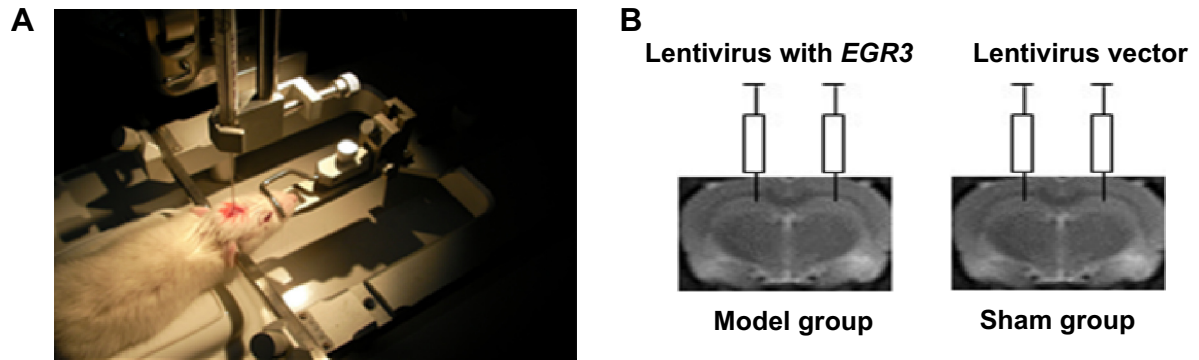
## Disclosure

The authors report no conflicts of interest in this work.

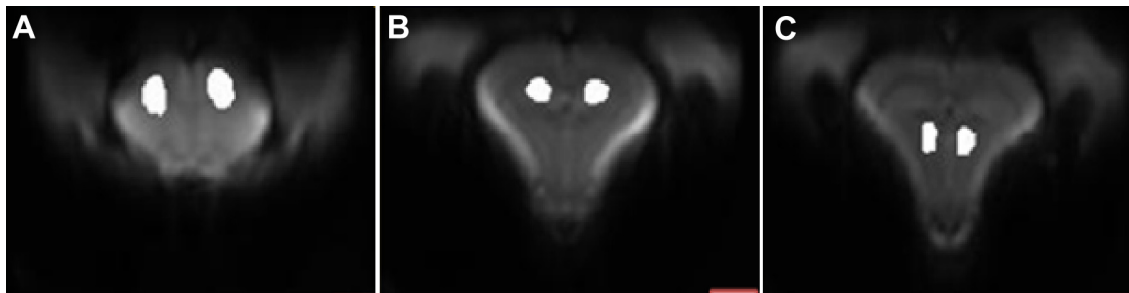## References

- Mueller S, Keeser D, Reiser MF, Teipel S, Meindl T. Functional and structural MR imaging in neuropsychiatric disorders, part 2: application in schizophrenia and autism. *AJNR Am J Neuroradiol*. 2012;33(11):2033–2037.
- Zhang R, Lu S, Meng L, et al. Genetic evidence for the association between the early growth response 3 (*EGR3*) gene and schizophrenia. *PLoS One*. 2012;7(1):e30237.
- Nishimura Y, Takizawa R, Koike S, et al. Association of decreased prefrontal hemodynamic response during a verbal fluency task with *EGR3* gene polymorphism in patients with schizophrenia and in healthy individuals. *Neuroimage*. 2014;85(pt 1):527–534.
- Ma G, Song T, Chen M, et al. Hippocampal and thalamic neuronal metabolism in a putative rat model of schizophrenia. *Neural Regen Res*. 2013;8(26):2415–2423.
- Chin CL, Curzon P, Schwartz AJ, et al. Structural abnormalities revealed by magnetic resonance imaging in rats prenatally exposed to methylazoxymethanol acetate parallel cerebral pathology in schizophrenia. *Synapse*. 2011;65(5):393–403.
- Repovs G, Csernansky JG, Barch DM. Brain network connectivity in individuals with schizophrenia and their siblings. *Biol Psychiatry*. 2011;69(10):967–973.
- Agartz I, Andersson JL, Skare S. Abnormal brain white matter in schizophrenia: a diffusion tensor imaging study. *Neuroreport*. 2001;12(10):2251–2254.
- Ohtani T, Bouix S, Hosokawa T, et al. Abnormalities in white matter connections between orbitofrontal cortex and anterior cingulate cortex and their associations with negative symptoms in schizophrenia: a DTI study. *Schizophr Res*. 2014;157(1–3):190–197.
- Williamson PC, Allman JM. A framework for interpreting functional networks in schizophrenia. *Front Hum Neurosci*. 2012;1(6):184.
- Rosenheck RA, Krystal JH, Lew R, et al. Long-acting risperidone and oral antipsychotics in unstable schizophrenia. *N Engl J Med*. 2011;364:842–851.
- Schneider Gasser EM, Straub CJ, Panzanelli P, Weinmann O, Sassoè-Pognetto M, Fritschy JM. Immunofluorescence in brain sections: simultaneous detection of presynaptic and postsynaptic proteins in identified neurons. *Nat Protoc*. 2006;1:1887–1897.
- Meyer-Lindenberg A, Kohn P, Mervis CB, et al. Neural basis of genetically determined visuospatial construction deficit in Williams syndrome. *Neuron*. 2004;43(5):623–631.
- Chen L, Chen X, Liu W, et al. White matter microstructural abnormalities in patients with late-onset schizophrenia identified by a voxel-based diffusion tensor imaging. *Psychiatry Res*. 2013;212(3):201–207.
- Fitzsimmons J, Kubicki M, Shenton ME. Review of functional and anatomical brain connectivity findings in schizophrenia. *Curr Opin Psychiatry*. 2013;26(2):172–187.
- Gur RE, Gur RC. Functional magnetic resonance imaging in schizophrenia. *Dialogues Clin Neurosci*. 2010;12(3):333–343.
- Wright IC, Rabe-Hesketh S, Woodruff PW, David AS, Murray RM, Bullmore ET. Meta-analysis of regional brain volumes in schizophrenia. *Am J Psychiatry*. 2000;157(1):16–25.
- Bluhm RL, Miller J, Lanius RA, et al. Spontaneous low-frequency fluctuations in the BOLD signal in schizophrenic patients: anomalies in the default network. *Schizophr Bull*. 2007;33(4):1004–1012.
- Tang J, Liao Y, Song M, et al. Aberrant default mode functional connectivity in early onset schizophrenia. *PLoS One*. 2013;8(7):e71061.
- Benes FM. Emerging principles of altered neural circuitry in schizophrenia. *Brain Res Brain Res Rev*. 2000;31(2–3):251–269.
- Bunney WE, Bunney BG. Evidence for a compromised dorsolateral prefrontal cortical parallel circuit in schizophrenia. *Brain Res Brain Res Rev*. 2000;31(2–3):138–146.
- Carlsson A, Waters N, Holm-Waters S, Tedroff J, Nilsson M, Carlsson ML. Interactions between monoamines, glutamate, and GABA in schizophrenia: new evidence. *Annu Rev Pharmacol Toxicol*. 2001;41:237–260.
- Grace AA. Gating of information flow within the limbic system and the pathophysiology of schizophrenia. *Brain Res Brain Res Rev*. 2000;31(2–3):330–341.
- Heimer L. Basal forebrain in the context of schizophrenia. *Brain Res Brain Res Rev*. 2000;31(2–3):205–235.
- Garrity AG, Pearlson GD, McKiernan K, Lloyd D, Kiehl KA, Calhoun VD. Aberrant “default mode” functional connectivity in schizophrenia. *Am J Psychiatry*. 2007;164(3):450–457.
- Auer DP. Spontaneous low-frequency blood oxygenation level-dependent fluctuations and functional connectivity analysis of the ‘resting’ brain. *Magn Reson Imaging*. 2008;26(7):1055–1064.
- Zhou Y, Liang M, Tian L, et al. Functional disintegration in paranoid schizophrenia using resting-state fMRI. *Schizophr Res*. 2007;97(1–3):194–205.
- Kuswanto CN, Teh I, Lee TS, Sim K. Diffusion tensor imaging findings of white matter changes in first episode schizophrenia: a systematic review. *Clin Psychopharmacol Neurosci*. 2012;10(1):13–24.
- Lee SH, Kubicki M, Asami T, et al. Extensive white matter abnormalities in patients with first-episode schizophrenia: a diffusion tensor imaging (DTI) study. *Schizophr Res*. 2013;143(2–3):231–238.
- Samartzis L, Dima D, Fusar-Poli P, Kyriakopoulos M. White matter alterations in early stages of schizophrenia: a systematic review of diffusion tensor imaging studies. *J Neuroimaging*. 2014;24(2):101–110.

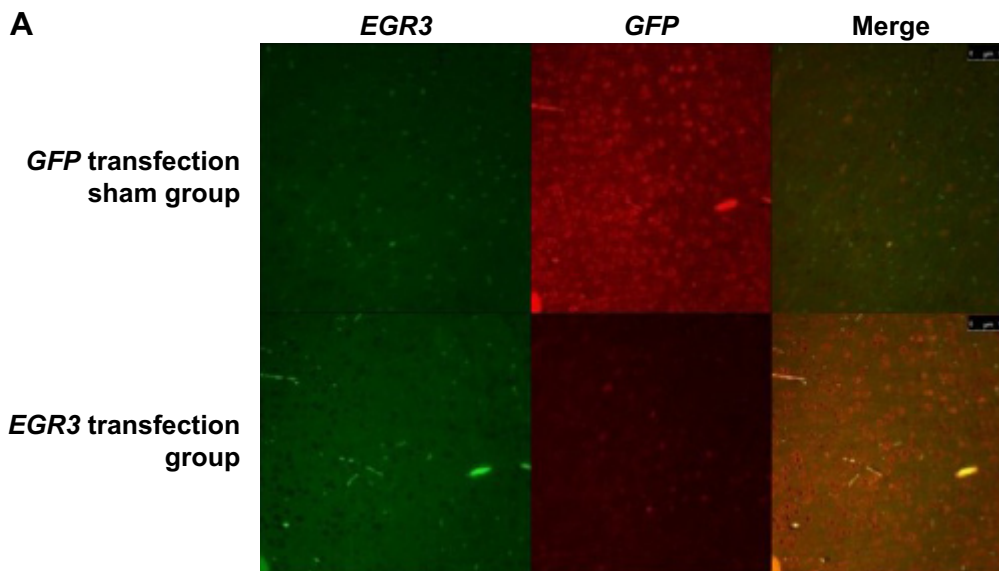
## Supplementary materials



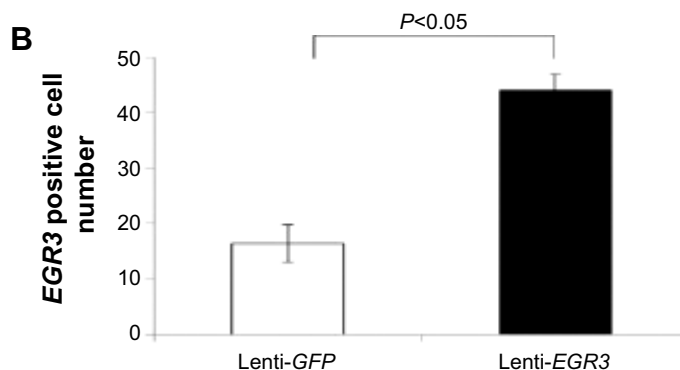
**Figure S1** Stereotactic injection of lentiviral particles into bilateral hippocampus dentate gyrus of rats.  
**Notes:** (A) Lentiviral vector injection using a cranial drill; (B) The lentivirus particle was slowly injected into each side of the hippocampus.  
**Abbreviation:** EGR3, early growth response factor 3.



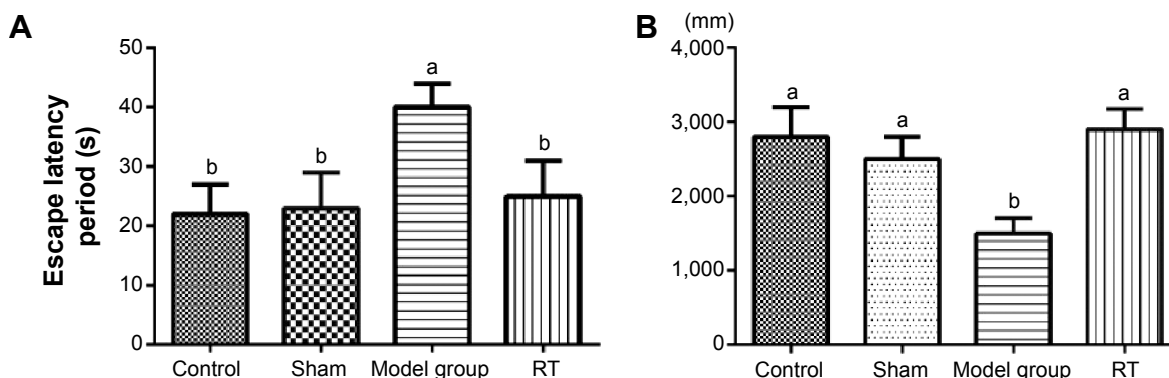
**Figure S2** Schizophrenia susceptible area in rat brain.  
**Notes:** (A) bilateral prefrontal cortex; (B) bilateral hippocampus; (C) bilateral thalamus.



**Figure S3** (Continued)



**Figure S3** Expression of *EGR3* in hippocampus region of rat brain.  
**Notes:** (A) microscopic image; (B) number of *EGR3*-transfected positive cells.  
**Abbreviations:** *EGR3*, early growth response factor 3; *GFP*, green fluorescent protein.



**Figure S4** Schizophrenia-like behavior abnormalities in rats transfected with *EGR3* gene.  
**Notes:** (A) Morris water-maze test for spatial working memory capacity; (B) open-field test for spontaneous activity. Data was mean ± SD (N=8–13). Group indexed by different letters indicated significant differences ( $P < 0.05$ ) according to one-way ANOVA followed by Tukey's test. Model group, rats with *EGR3* transfection; RT group, schizophrenia-like rats treated with risperidone; sham group, rats with *GFP* gene transfection and treated with normal saline; control group, rats without gene transfection and treated with normal saline.  
**Abbreviations:** *EGR3*, early growth response factor 3; *GFP*, green fluorescent protein; RT, right thalamus SD, standard deviation; ANOVA, analysis of variance.

Neuropsychiatric Disease and Treatment



Publish your work in this journal

Neuropsychiatric Disease and Treatment is an international, peer-reviewed journal of clinical therapeutics and pharmacology focusing on concise rapid reporting of clinical or pre-clinical studies on a range of neuropsychiatric and neurological disorders. This journal is indexed on PubMed Central, the 'PsycINFO' database and CAS,

and is the official journal of The International Neuropsychiatric Association (INA). The manuscript management system is completely online and includes a very quick and fair peer-review system, which is all easy to use. Visit <http://www.dovepress.com/testimonials.php> to read real quotes from published authors.

Submit your manuscript here: <http://www.dovepress.com/neuropsychiatric-disease-and-treatment-journal>