

Traumatic aorto-pulmonary artery fistula: a case report

Ruchika Meel ^{1*}, Thumone Govindasamy ¹, and Ricardo Gonçalves²

¹Department of Cardiology, Chris Hani Baragwanath Academic Hospital, University of the Witwatersrand, Johannesburg, South Africa; and ²Olivedale Hospital, Johannesburg, South Africa

Received 7 February 2019; first decision 11 March 2019; accepted 4 July 2019; online publish-ahead-of-print 16 July 2019

Background

Aorta-pulmonary (A-P) artery fistula following a stab wound to the chest with superimposed infective endocarditis (IE) is a rare, often unrecognized presentation. Herein, we report a case of A-P fistula due to stab chest assessed by two- and three-dimensional (3D) imaging.

Case summary

A 30-year-old man presented with a history of being stabbed in the chest with a screwdriver. The chest wall laceration was sutured, an intercostal drain inserted for a haemopneumothorax, and he was subsequently discharged. He presented 3 weeks later with exertional dyspnoea, fever, rigours, and loss of weight. On examination, he had a wide pulse pressure and a harsh continuous murmur in the 2nd left intercostal space associated with a palpable thrill. Blood tests revealed raised infective markers and anaemia. All blood cultures were sterile. On echocardiography, the aortic and pulmonary valve was severely damaged, with suspicion of superimposed vegetations secondary to IE. There was severe aortic and pulmonary valve regurgitation. A fistulous connection was noted between the aorta and main pulmonary artery, just below the commissure adjoining the right and left coronary sinus of the aortic valve. On 3D imaging, the defect was quantified. The patient was subsequently referred for aortic and pulmonary valve replacement and closure of the A-P fistula. The presence of multiple vegetations was confirmed intraoperatively. He also received a 6-week course of intravenous antibiotics.

Discussion

We have described a rare case of an A-P fistula due to a stab wound to the chest complicated by IE. In a patient with stab wound to the chest, a high index of suspicion of cardiac involvement must be maintained, and a careful search for intracardiac shunts must be made on echocardiography, prior to discharge. Furthermore, in addition to two-dimensional imaging, 3D imaging proved useful in providing a comprehensive assessment of the morphology of the lesion prior to surgery.

Keywords

Aorta-pulmonary artery fistula • Infective endocarditis • Chest stab wound • Case report

Learning points

- Aorta-pulmonary artery fistulas may be caused by penetrating trauma to the chest.
- All patients with penetrating chest trauma should undergo a chest X-ray, an echocardiogram by an experienced sonographer, and a computed tomography scan of the chest to exclude cardiac complications on the index admission.
- The patient must be reviewed after the index admission and undergo a repeat chest X-ray and an echocardiogram if clinically warranted.

* Corresponding author. Tel: +27 072 170 2227, Email: ruchikameel@gmail.com

Handling Editor: Sabiha Gati

Peer-reviewers: Marcelo Haertel Miglioranza, Didem Oguz, and Richard Alexander Brown

Compliance Editor: Anastasia Vamvakidou

Supplementary Material Editor: Vishal Shahil Mehta

© The Author(s) 2019. Published by Oxford University Press on behalf of the European Society of Cardiology.

This is an Open Access article distributed under the terms of the Creative Commons Attribution Non-Commercial License (<http://creativecommons.org/licenses/by-nc/4.0/>), which permits non-commercial re-use, distribution, and reproduction in any medium, provided the original work is properly cited. For commercial re-use, please contact journals.permissions@oup.com

Introduction

Aorta-right ventricular fistulas are a rare presentation after penetrating chest trauma.¹ The majority are well-tolerated, but over time, which may result in heart failure if left untreated. Once detected prompt surgical intervention is recommended to prevent sequelae such as heart failure and infective endocarditis (IE).¹ There have been no cases of aorta-pulmonary (A-P) artery fistulas, with concurrent aortic and pulmonary valve regurgitation, reported in the recent literature. One case report, published in 2005, stated that aorta-right ventricular fistula with aortic insufficiency is a rare lesion and only 17 such cases had been previously reported.² Some patients may present early due to haemodynamic instability, whereas others may have a more protracted course resulting in a delayed presentation. In a South African case study, a patient presented 6 years after a penetrating chest injury with exertional dyspnoea and a continuous murmur due to aorta-right ventricular fistula complicated by aortic regurgitation.³ The delayed presentation was explained by gradual fibrosis of the aortic valve cusp and the resultant larger defect. In a case series review of aorta-right ventricular fistula by Samuels *et al.*,⁴ it was concluded that due to unfavourable natural history of these lesions, a definitive repair of this structural defect must be performed at the index hospitalization. In 2015, Dieng *et al.*⁵ reported penetrating trauma to the heart with a screwdriver, in this case, the patient sustained injury to the right ventricle and right coronary vein and underwent surgical repair. In the last decade, case reports pertaining to penetrating wounds to the chest resulting in aorta-right ventricular fistula have been scarce. We present a unique case of an A-P artery fistula complicated by IE and double valve involvement, and its assessment by three-dimensional (3D) echocardiography.

Timeline

Date	Events
24 January 2018	First presentation to the emergency department with stab wound to the chest. Echocardiography did not document any structural heart involvement.
27 January 2018	Discharged from the hospital.
20 February 2018	Second presentation with dyspnoea as the main complaint. Started on antibiotics for suspected pneumonia and possible infective endocarditis. Echocardiogram is done, which showed shunt between the aorta and the pulmonary artery. A transoesophageal echocardiogram confirmed the presence of a shunt and vegetations on the aortic and pulmonary valve.
26 February 2018	Patient remained haemodynamically stable while awaiting surgery.
7 March 2018	Patient undergoes operation (aortic and pulmonary valve replacement with patch repair of the fistula) and is subsequently discharged by the cardiothoracic surgeons. A total of 6 weeks of intravenous antibiotics was completed and a repeat echocardiogram post-operatively confirmed a good surgical repair.

Case presentation

A 30-year-old man with no comorbidities presented to the emergency department with a history of being stabbed in the chest with a screwdriver a few hours prior to arrival. The entry wound was

located in left parasternal region in the second intercostal space (Figure 1). The screwdriver had already been removed. No other injuries were noted. The patient was normotensive (112/74 mmHg), had a tachycardia (112/min), and was tachypnoeic (34 breaths per minute and saturation of 92%). Reduced air entry was noted on the left side of the chest but no murmurs were noted. No blood tests could be traced from the original admission. A chest X-ray confirmed a left haemopneumothorax. The haemothorax occupying about a third of the left hemithorax and the pneumothorax compressed about a third of the left lung. The volume of blood drained was not recorded. No blood transfusion was required. A transthoracic echocardiogram performed in the emergency department seemingly did not detect cardiac pathology. A computed tomography (CT) scan of the chest was not performed. The chest wall laceration was sutured and an intercostal drain inserted on the left side. He was subsequently discharged after removal of the intercostal drain. He presented 3 weeks later with exertional dyspnoea, fever, rigours, and loss of weight. On examination his blood pressure was 102/58 mmHg, heart rate was 115 beats/min, respiratory rate of 30 breaths/min, and temperature of 36.8°C. There was a harsh continuous murmur in the second left intercostal space associated with a palpable thrill. All other systems were clinically unremarkable.

A 12-lead electrocardiogram showed sinus tachycardia. Blood tests revealed raised infective markers with a white cell count of 20×10^9 cells/ μ L (Normal 3.92–10.4 $\times 10^9$ cells/ μ L) and an elevated C-reactive protein of 118 mg/L (Normal <10 mg/L). He was also anaemic with a haemoglobin of 8.9 g/dL (Normal 13.4–17.5 g/dL). All blood cultures were sterile. The chest X-ray showed a small pleural effusion on the left. The transthoracic echocardiogram showed good left ventricular function, with an ejection fraction of 58%. A small pericardial effusion (<1 cm) was noted anterior to the right ventricle. The aortic valve and pulmonary valves were severely damaged with

suspicion of superimposed vegetations secondary to IE (Figure 2). There was severe aortic regurgitation primarily due to destruction of right coronary cusp. Additionally, there was moderate eccentric pulmonary regurgitation. There was a fistula between the aorta and main pulmonary artery, just below the commissure between the right

and left coronary sinus of the aortic valve (Figures 2 and 3). On 3D transoesophageal echocardiography, the defect measured 1.4×0.6 cm in diameter with area of 0.9 cm^2 (Figures 4–6). There was moderate, functional, mitral regurgitation, and moderate tricuspid regurgitation. The pulmonary artery systolic pressure was 40 mmHg

and preserved right ventricular systolic function was noted. The patient was subsequently referred for surgical repair. Surgical debridement of all necrotic and infected material was performed. Closure of the A-P artery fistula was performed with a bovine pericardial patch. The aortic valve was replaced with a 25-mm CardiaMed bileaflet mechanical valve, and the pulmonary valve was replaced with a 27-mm Mitroflow bioprosthetic valve. The cardiopulmonary bypass time was 196 min. The presence of multiple vegetations was confirmed intraoperatively (Figure 7). No organism was identified on cultures of the resected valves. He was given 2 weeks of antibiotics prior to surgery and 4 weeks after surgery. He received ceftriaxone 2 g daily intravenously for a total of 6 weeks, gentamycin 240 mg daily intravenously for the first 2 weeks and vancomycin 1 g 12 hourly intravenously (drug levels for the latter two drugs were monitored). At follow-up, 2 weeks after discharge by the cardiothoracic surgeons, he was asymptomatic and had no murmurs clinically. On echocardiography, he had a trivial aortic valve paravalvular leak, normal pulmonary valve, and an intact pericardial patch repair.

Discussion

Aorta-pulmonary artery fistula following a stab wound to the chest with superimposed IE is a rare presentation. There are several points of interest in this case that need to be highlighted. Firstly, this patient was stabbed with a screwdriver, an unusual weapon. Unfortunately, the screwdriver was removed prior to the patient's arrival, so the angle of entry could not be ascertained on clinical examination. Furthermore, there was a delay in the diagnosis of the fistula due to two possible reasons. Firstly, the patient may have been initially asymptomatic of cardiac symptoms and the continuous murmur missed during the first hospital admission. Alternatively, during the index presentation, there was no fistula, and the patient presented later due to superimposed IE, secondary

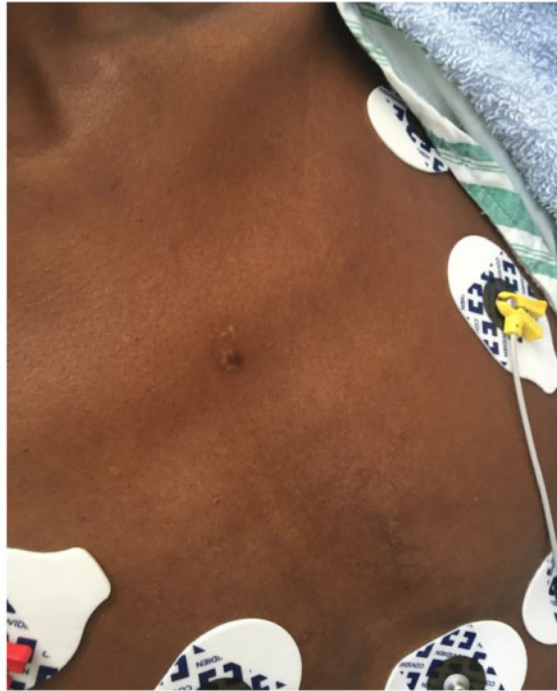

Figure 1 Photograph showing the healing stab wound in the left second intercostal space parasternal.

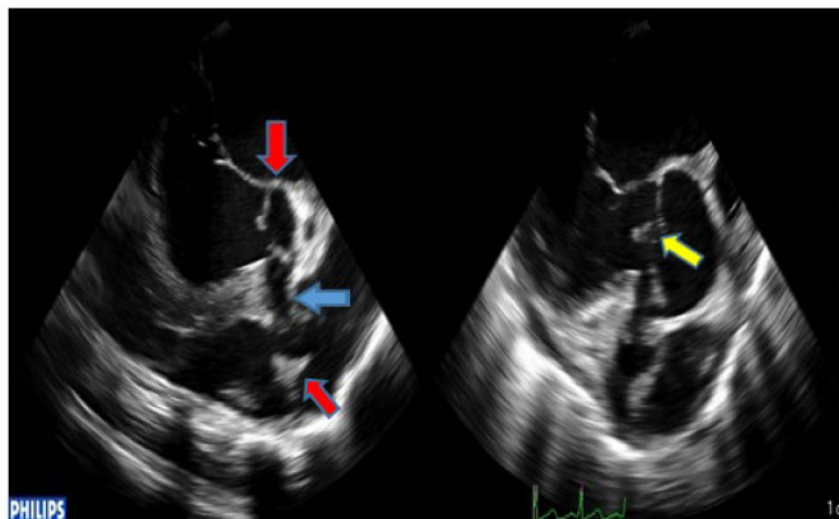


Figure 2 Long-axis transoesophageal views showing destruction of aortic and pulmonary valve leaflets (red arrows) and fistula (blue arrow) with superimposed vegetations (yellow arrow).

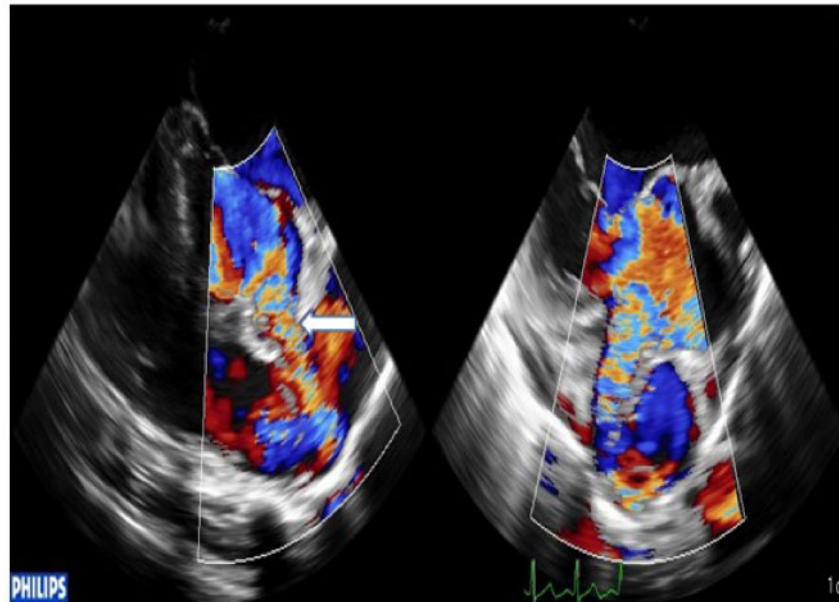


Figure 3 Long-axis two-dimensional colour Doppler views showing fistula (white arrow) between the aorta and main pulmonary artery with left to right shunt.

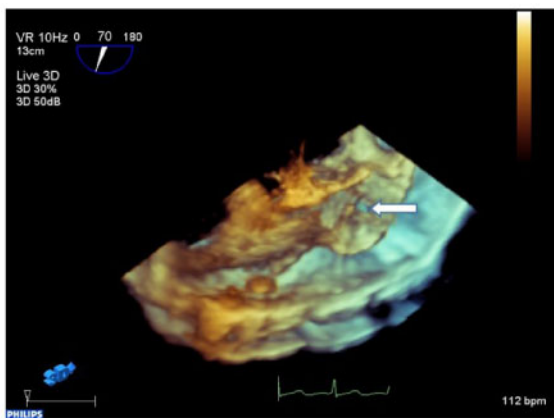


Figure 4 Three-dimensional views showing aorta-pulmonary artery fistula.

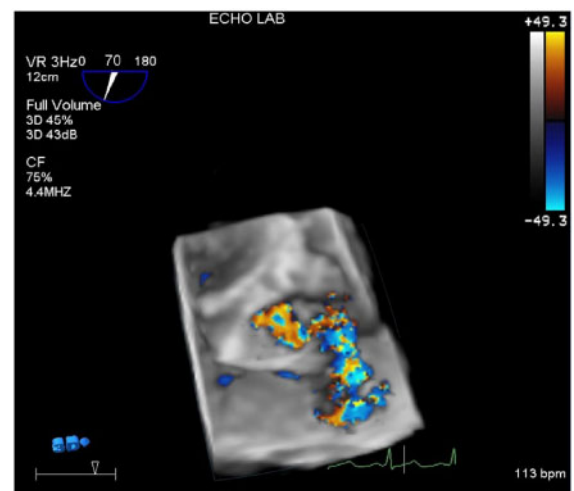


Figure 5 Three-dimensional views showing aorta-pulmonary fistula with colour.

to infection due to the penetrating wound, eventually resulting in tissue necrosis and fistula formation. Thus, a high index of suspicion must be maintained, and a careful search for intracardiac shunts must be made on echocardiography, prior to discharge. Furthermore, the initial cardiac echocardiogram was performed in the emergency department by a junior doctor and not by an expert in echocardiography. We suspect the cardiac lesion may have been missed at the index admission. Thus, we recommend that all cases where there is suspicion of cardiac trauma an expert

echocardiographer must be consulted. Furthermore, a CT scan of the chest should have been performed which may possibly have identified the pericardial effusion and the fistula. A multidisciplinary team approach these patients has been shown to improve patient outcomes.⁶ Additionally, such patients must be followed-up closely after discharge as these lesions may only manifest at a later stage due to poor healing or fibrosis.³

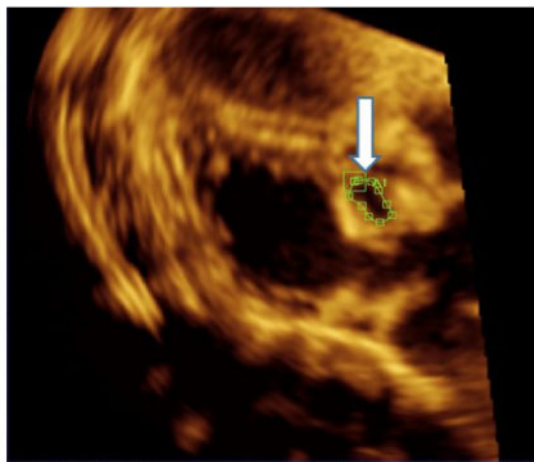


Figure 6 Three-dimensional views showing the aorta-pulmonary artery fistula (arrow), and its measurement using multiplane reconstruction.

It is known that healthy endothelium cannot be easily colonized by bacteria.⁷ Bacteria require endothelial disruption to adhere, multiply and cause infection in the form of IE. The mechanism of endothelial disruption may be related to direct trauma, amongst others, from invasive procedures or penetrating trauma as represented in this case. There was a likely injury to the endothelium of the semilunar valves and concomitant introduction of bacteria by the contaminated screwdriver. The endothelial disruption resulted in exposure of the tissue matrix, leading to platelet adherence, deposition of fibrin, formation of microthrombi and promotion of bacterial adhesion and proliferation. This resulted in the formation of vegetations and enlargement of the fistula. The fistula, in turn, resulted in further damage to the endothelium due to a high-velocity jet caused by the left to right shunting of blood from the aorta to the pulmonary artery, causing further bacterial seeding.

Physical examination alone is not sufficient for detection of the direction and extent of cardiac injury from penetrating trauma.⁸ It is neither sensitive nor specific for recognizing significant pathology. Usually, the shape and size of the weapon and the angle of entry of the instrument provides clues to the potential injuries. The size of the external injury may grossly underestimate the extent of internal injury. Penetrating trauma to the so-called 'box' region should raise a red flag, as there is a high risk of injury to the heart and surrounding mediastinal structures.⁸ The box is superiorly defined by the clavicles and sternal notch, laterally by vertical lines through the nipples, and inferiorly by the costal margins.

The incidence and the natural history of penetrating cardiac injury are not well studied. Some authors have reported secondary cardiac injuries at follow-up, such as fistulas and ventricular septal defects. Based on the aforementioned observations it is suggested that these patients should undergo a follow-up transthoracic echocardiogram, as haemodynamically insignificant or small cardiac lesions may be missed at the initial encounter.^{3,9} A baseline CT scan of the chest should also be performed to exclude a

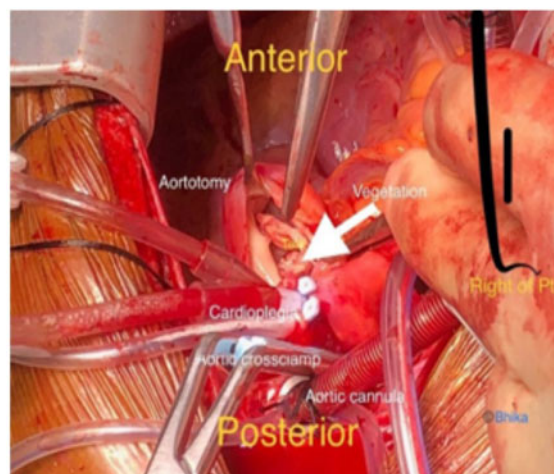


Figure 7 An intraoperative photograph showing a vegetation within the aorto-pulmonary fistula.

haemopericardium and a haemopneumothorax, fistula and intra-cardiac septal defects.

Concurrent involvement of the aortic and pulmonary valve resulting in haemodynamically significant lesions is unique. The aforementioned combination of lesions secondary to a penetrating chest wound has not been reported in the recent literature.

Furthermore, in this case, 3D echocardiography allowed a comprehensive assessment of the morphology of the A-P artery fistula, aortic and pulmonary valve, as well as the superimposed vegetations. Three-dimensional transoesophageal echocardiography allowed acquisition of volumetric data, from which the multiplane reconstruction of the orifice of the fistula allowed us to measure the diameter and the area of the asymmetrical orifice.^{10–12} This information proved useful prior to surgical repair. Additionally, 3D echocardiography allowed enface view visualization of the defect. Three-dimensional imaging has certain inherent limitations which must be taken into account when calculating orifice area in general.¹¹ The main limitations of 3D echocardiography include: (i) its low temporal and spatial resolution which may cause errors in area measurement of the orifice and can miss small vegetations; (ii) reliance on adequate two-dimensional image quality limits its use in patients with poor echo windows; and (iii) presence of artefacts such as due to blooming, can result in underestimation of the orifice area.¹²

Conclusion

We have described a rare case of an A-P artery fistula with concurrent aortic and pulmonary valve regurgitation due to a stab wound to the chest complicated by IE. In patients with stab wounds to the chest, careful physical examination, a chest X-ray, a thorough echocardiogram and a CT scan of the chest should be performed. Furthermore, in addition to two-dimensional echocardiography, 3D echocardiography is useful in providing a comprehensive morphological assessment prior to surgery.

Lead author biography



As a general cardiologist with interest in cardiovascular imaging, Ruchika Meel has a passionate interest in research with to date one book publication, two book chapters and 15 research articles, and 30 congress presentations. Her Master of Medicine research dissertation awarded cum laude was entitled 'Time to fibrinolytics for acute myocardial infarction and reasons for delays at Steve Biko Academic Hospital, Pretoria'. She completed her PhD thesis in 2016, which was an investigation of myocardial

mechanics in chronic rheumatic mitral regurgitation. Currently, she is a Post-Doctoral Carnegie Fellow at the University of the Witwatersrand. Her current research project is entitled 'HIV-associated ascending aortic aneurysms: clinical features and natural history'.

Supplementary material

Supplementary material is available at *European Heart Journal - Case Reports* online.

Acknowledgements

The authors would like to thank Sharmel Bhika for providing us with the intraoperative picture.

Slide sets: A fully edited slide set detailing this case and suitable for local presentation is available online as [Supplementary data](#).

Consent: The author/s confirm that written consent for submission and publication of this case report including image(s) and associated text has been obtained from the patient in line with COPE guidance.

Conflict of interest: none declared.

References

1. Cakir C, Duygu H, Kilicaslan B, Ertas F, Ozen N, Nazli C, Ergene O. Postoperative diagnosis of aorto-right ventricular outflow tract fistula caused by stab wound: a case report. *J Am Soc Echocardiogr* 2007;**20**:1415.e5.
2. Kaya A, Dekkers P, Loforte A, Jaarsma W, Morshuis WJ. Traumatic aorto-right ventricular fistula with aortic insufficiency. *Ann Thorac Surg* 2005;**80**:2362–2364.
3. Theron JP, Du Theron H, Long M, Marx JD. Late presentation of aorto-right ventricular fistula and associated aortic regurgitation following penetrating chest trauma: case report. *Cardiovasc J Afr* 2009;**20**:357–359.
4. Samuels LE, Kaufman MS, Rodriguez-Vega J, Morris RJ, Brockman SK. Diagnosis and management of traumatic aorto-right ventricular fistulas. *Ann Thorac Surg* 1998;**65**:288–292.
5. Dieng PA, Diop MS, Ciss AG, Ba PS, Diatta S, Gaye M, Fall ML, Ndiaye A, Ndiaye M. Penetrating heart injury due to screwdriver assault. *Case Rep Cardiol* 2015; **2015**:1.
6. Onan B, Demirhan R, Öz K, Onan IS. Cardiac and great vessel injuries after chest trauma: our 10-year experience. *Ulus Travma Acil Cerrahi Derg* 2011;**17**: 423–429.
7. Habib G, Lancellotti P, Antunes MJ, Bongiorni MG, Casalta JP, Del Zotti F, Dulgheru R, El Khoury G, Erba PA, lung B, Miro JM. 2015 ESC guidelines for the management of infective endocarditis: the task force for the management of infective endocarditis of the European Society of Cardiology (ESC) endorsed by: European Association for Cardio-Thoracic Surgery (EACTS), the European Association of Nuclear Medicine (EANM). *Eur Heart J* 2015;**36**: 3075–3128.
8. Nagy KK, Lohmann C, Kim DO, Barrett J. Role of echocardiography in the diagnosis of occult penetrating cardiac injury. *J Trauma* 1995;**38**:859–862.
9. Tang AL, Inaba K, Branco BC, Oliver M, Bukur M, Salim A, Rhee P, Herrold J, Demetriades D. Post discharge complications after penetrating cardiac injury: a survivable injury with a high post discharge complication rate. *Arch Surg* 2011; **146**:1061–1066.
10. Nakai H, Takeuchi M, Yoshitani H, Kaku K, Haruki N, Otsuji Y. Pitfalls of anatomical aortic valve area measurements using two-dimensional transoesophageal echocardiography and the potential of three-dimensional transoesophageal echocardiography. *Eur J Echocardiogr* 2010;**11**:369–376.
11. Bruun NE, Habib G, Thuny F, Sogaard P. Cardiac imaging in infectious endocarditis. *Eur Heart J* 2014;**35**:624–632.
12. Faletra FF, Ramamurthi A, Dequarti MC, Leo LA, Moccetti T, Pandian N. Artifacts in three-dimensional transoesophageal echocardiography. *J Am Soc Echocardiogr* 2014;**27**:453–462.