

# Role of chemotherapy and thrombolysis in treatment of choriocarcinoma accompanied with pulmonary embolism

## A case report with literature review

Mei Yang, MD, Li Peng, MD, PhD\*

### Abstract

**Rationale:** Choriocarcinoma accompanied with pulmonary embolism (PE) is rare and difficult to diagnose and treat. There are about 25 cases reported in literature, which presented variable clinical characteristics and prognosis.

**Patient concerns:** We reported a case of choriocarcinoma presenting PE as the first manifestation in a 26-year-old Chinese female.

**Diagnoses:** Four months before her admission to our hospital, she presented to a local hospital with respiratory manifestations, and was first diagnosed as bronchitis and treated with antibiotics without improvement, and subsequently suspected of having pulmonary tuberculosis and receive anti-tuberculosis therapy, with no response. Upon admission to our hospital, spiral computed tomography-pulmonary angiography revealed complete occlusion of right pulmonary artery, leading to PE. She received thrombolysis and anticoagulant therapy, without improvement. Further interrogation of the patient revealed a history of irregular vaginal bleeding and multiple pregnancies and abortions. Following the laboratory report of a significantly elevated level of serum beta-human chorionic gonadotropin ( $\beta$ -HCG) combined with other clinical and laboratory findings, a diagnosis of choriocarcinoma accompanied with PE was established based on the criteria formulated by the International Federation of Gynecology and Obstetrics and guideline of European Society for Medical Oncology.

**Interventions:** With 1 cycle of chemotherapy with etoposide-methotrexateactinomycin D-cyclophosphamide-vincristine (EMA-CO), her dyspnea and other symptoms improved, with a significant decrease in the serum  $\beta$ -HCG level and pulmonary artery pressure.

**Outcomes:** Unfortunately, she showed bone marrow inhibition, could not continue further chemotherapy, and finally died after discharging. We reviewed 25 similar cases in the literature, and found that all 17 cases receiving chemotherapy showed complete recovery while 6 of 8 cases without chemotherapy died during hospitalization.

**Lessons:** This case report illustrates the challenges in diagnosis of choriocarcinoma presenting with respiratory manifestations, and highlights the importance of early diagnosis and timely appropriate chemotherapy in management of this disease.

**Abbreviations:** DOACs = direct oral anticoagulants, ECMO = extracorporeal membrane oxygenation, HCG = human chorionic gonadotropin, PE = pulmonary embolism.

**Keywords:** chemotherapy, choriocarcinoma, pulmonary embolism

Editor: Levent Dalar.

Both authors declared no competing interests. The requirement of informed consent was waived by the Institutional Review Board due to the retrospective nature of this study. Informed consent was obtained from the patient before she died.

The authors report no conflicts of interest.

Supplemental Digital Content is available for this article.

Department of Respiratory and Critical Care Medicine, the First Affiliated Hospital of Chongqing Medical University, Chongqing, China.

\* Correspondence: Li Peng, Department of Respiratory and Critical Care Medicine, the First Affiliated Hospital of Chongqing Medical University, No.1, Youyi Road, Yuzhong District, Chongqing 400016, China (e-mail: pl1228@163.com).

Copyright © 2017 the Author(s). Published by Wolters Kluwer Health, Inc. This is an open access article distributed under the terms of the Creative Commons Attribution-Non Commercial-No Derivatives License 4.0 (CCBY-NC-ND), where it is permissible to download and share the work provided it is properly cited. The work cannot be changed in any way or used commercially without permission from the journal.

Medicine (2017) 96:36(e7866)

Received: 22 March 2017 / Received in final form: 5 July 2017 / Accepted: 20 July 2017

<http://dx.doi.org/10.1097/MD.0000000000007866>

## 1. Introduction

Choriocarcinoma is a highly malignant epithelial neoplasm, which is characterized by rapid growth with a strong potential for hematogenous metastasis. The primary source of this neoplasm is difficult to be identified when hematogenous metastasis occurs in the early stage.<sup>[1]</sup> Choriocarcinoma can spread to various organs and cause aggressive complications. One of the most aggressive complications is pulmonary embolism (PE). The diagnosis of PE caused by metastatic choriocarcinoma is challenging and often delayed or even missed due to nonspecific, insidious presentation.<sup>[2,3]</sup> Although the morbidity of this condition is low, it carries a significant mortality if not treated appropriately.<sup>[4]</sup> Currently, the standard treatment for this condition involves chemotherapy, thrombolytic therapy, and thrombectomy; their efficacies remain to be improved. Here, we report a case of choriocarcinoma presenting PE as the first manifestation in a young woman who showed temporary improvement following chemotherapy but died of progressive disease. We reviewed 25 similar cases reported between January 1959 and December 2016 in PubMed and China National Knowledge Infrastructure (CNKI) database, and summarized their clinical features and treatment outcomes.

## 2. Case report

A 26-year-old Chinese female was admitted to our hospital with complaints of cough, expectoration, and night sweats for 4 months. Four months before admission, she had been diagnosed with bronchitis in a local hospital and treated with antibiotic agents without improvement. The cough continued while she began to experience shortness of breath during routine activities. Four days before admission, her chest radiography revealed patchy infiltrating shadows in both lungs, especially in both lower lobes. Due to these findings as well as her residence in the tuberculosis endemic region, she was suspected of having pulmonary tuberculosis, and thus prescribed anti-tuberculosis drugs. Following this treatment for 3 days, some adverse effects appeared, including nausea, vomiting, anorexia, and aggravated breath shortness, and therefore, she was admitted to our hospital on August 9, 2016.

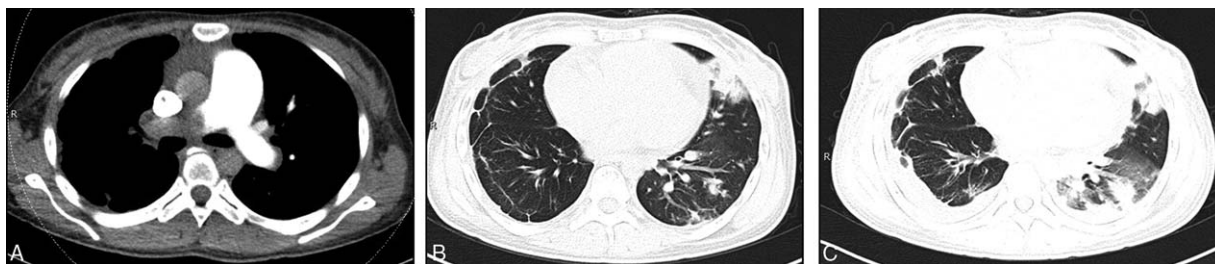Physical examination revealed body weight of 51.5 kg, pulse rate of 100 beats/min, respiratory rate of 25/min, and blood pressure of 88/60 mm Hg. Although without cyanosis, her breath became harsh symmetrically and respiratory murmurs were weak in both lower lungs. Blood test showed a white blood cell count of 1073/dL, hemoglobin 114 g/L, and platelets 39,900/dL. Mild liver dysfunction was suggested by elevated levels of glutamic-pyruvic transaminase (54 U/L), glutamic-oxaloacetic transaminase (80 U/L), and total bilirubin (40.1  $\mu\text{mol/L}$ ), and the reduced level of serum albumin (30 g/L). Coagulation function tests revealed a prothrombin time of 17.5 seconds, and an activated partial thromboplastin time of 37.1 seconds, with a significant increase of D-dimer to 5.38 mg/L. Serum brain natriuretic peptide (BNP) increased to 8440 ng/L. The levels of serum cancer biomarkers, including cytokeratin 19 fragment antigen 21-1, carcinoembryonic antigen, neuron specific enolase, squamous cell carcinoma antigen, and pro-gastrin-releasing peptide, were all in normal range. Serum tuberculosis antibody was negative, and acid-fast bacilli staining of sputum smears collected in 3 different time points were all negative. Echocardiography displayed right atrial and ventricular enlargement, pulmonary hypertension (up to 81.6 mm Hg), and severe tricuspid regurgitation. Ejection fraction was normal and heart wall beat normally.

On the first day of hospitalization, the patient received nasal catheter oxygen inhalation at 3 L/min to treat her tachypnea. The arterial blood gas levels were all abnormal, including pH = 7.462,  $\text{PCO}_2 = 20.3$  mm Hg,  $\text{PO}_2 = 66$  mm Hg,  $\text{BE} = -9$  mmol/L, and  $\text{HCO}_3^- = 14.5$  mmol/L. On the next day (August 10, 2016), spiral computed tomography (CT) pulmonary angiography (CTPA) revealed complete occlusion of right pulmonary artery,

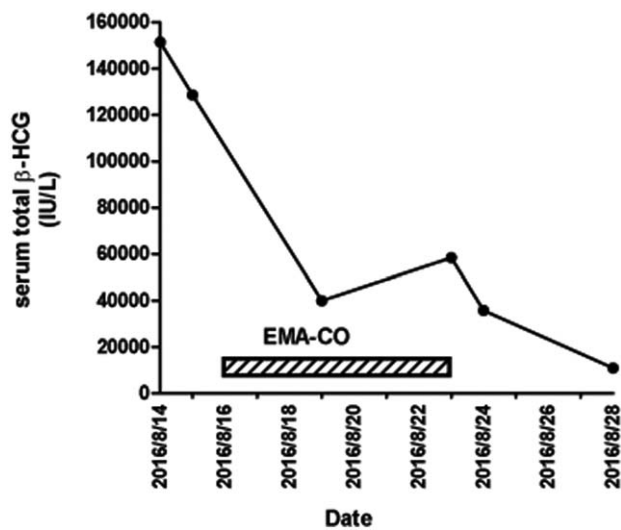
leading to PE. Considering her low body weight, a half dose (50 mg) of recombinant tissue plasminogen activator (ACTIVASE rt-PA) was administered intravenously for thrombolysis,<sup>[5]</sup> complemented with anticoagulant therapy by subcutaneous injection of low molecular weight heparin (LMWH, enoxaparin, Lovenox) at 40 mg every 12 hours, followed by oral warfarin of 2.5 mg once daily.

To seek the cause of PE, we interrogated the patient again. She denied smoking or the use of oral contraceptives, but reported a history of 4 pregnancies with 2 abortions. The latest pregnancy occurred 3 years ago, and long-term use of condoms contraception. In addition, she reported a history of irregular vaginal bleeding for 1 month. We conducted additional tests in local hospital, including the thrombophilia index, which was normal; ultrasound examination of our hospital on August 10, which showed no evidence of venous thromboembolism that might lead to PE; and ultrasound and enhanced CT of abdomen and pelvis, which excluded intrauterine pregnancy and extrauterine pregnancy. Nevertheless, serum beta-human chorionic gonadotropin ( $\beta\text{-HCG}$ ) was significantly elevated (128,575.77 IU/L) while progesterone decreased (0.93 ng/mL). Five days after thrombolytic therapy, a follow-up CTPA and echocardiography did not find clear improvement in PE, implying a poor response to thrombolysis. In addition, chest CT showed deterioration of pulmonary lesions in the lower left lobe, including an increase in the number and size of lesions (Fig. 1).

On the basis of a multidisciplinary consultation meeting, gestational trophoblastic neoplasm was highly suspected as the cause of PE in this patient. We further excluded the possibility of mole abortion and invasive hydatid disease by reviewing her medical history and performing abdominal and pelvic-enhanced CT examinations. A diagnosis of choriocarcinoma accompanied with PE was established based on a combination of clinical and laboratory findings following the criteria formulated by the International Federation of Gynecology and Obstetrics (FIGO),<sup>[6]</sup> and the guideline of European Society for Medical Oncology.<sup>[7,8]</sup> Subsequently, the patient was given the high-risk EMA-CO (etoposide-methotrexate-actinomycin D-cyclophosphamide-vincristine) chemotherapy regimen. On the second day of chemotherapy, her dyspnea aggravated and required noninvasive ventilation. Two days after the end of chemotherapy, her dyspnea improved and the ventilation was discontinued. Serum  $\beta\text{-HCG}$  decreased to 10,946.67 IU/L (Fig. 2) and pulmonary artery systolic blood pressure decreased to 64.7 mm Hg with echocardiography (from 81.6 mm Hg on admission). Unfortunately, bone marrow inhibition (degree II) was noted and her Karnofsky Performance Status (KPS) score



**Figure 1.** Chest CT images of a patient with choriocarcinoma accompanied with pulmonary embolism. (A) CTPA revealed complete occlusion of right pulmonary artery on admission (August 10, 2016). (B) Chest CT on August 10, 2016, showed pulmonary nodules in the lower lobe of the left lung. (C) CT scan on August 15, 2016, showed deterioration of pulmonary lesions in lower left lobe, including an increase in the number and size of pulmonary lesions. CT = computed tomography, CTPA = computed tomography pulmonary angiography.



**Figure 2.** Dynamic changes of serum β-HCG during course of choriocarcinoma with pulmonary embolism disease. The hatched bar indicates the period of chemotherapy with EMA-CO.

decreased to only 50.<sup>[9]</sup> She was not given an additional course of chemotherapy and discharged. Ten days after discharging, she died at home.

### 3. Discussion

We searched the PubMed and CNKI database for articles published from January 1, 1959, to December 31, 2016, using the terms “choriocarcinoma” and “pulmonary embolism.” The search resulted in 17 articles in English,<sup>[2,3,10–24]</sup> 3 articles in Chinese,<sup>[25–27]</sup> and 1 article in Japanese,<sup>[28]</sup> in which a total of 25 cases were reported (supplement Table, <http://links.lww.com/MD/B836>). The characteristics of choriocarcinoma accompanied with PE in these cases are summarized in Table 1. The mean age of these cases was 31 years (ranged 22–51 years). The most common manifestations were dyspnea (20/25 or 80%) and chest pain (15/25 or 60%). Other manifestations included cough, hemoptysis, and fever, which occurred in 24% to 44% cases. About half (48%) of these cases had a history of spontaneous abortion. The mortality was about 32% (8/25), and the average time for diagnosis after the onset of symptoms was 5 months.

**Table 1**  
**Characteristics of 25 cases of choriocarcinoma accompanied with pulmonary embolism in the literature.**

Characteristics	No. of patients* (n=25)
Dyspnea	20 (80%)
Chest pain	15 (60%)
Cough or expectoration	11 (44%)
Hemoptysis	9 (36%)
Fever	6 (24%)
Spontaneous abortion	12 (48%)
Induced abortion	5 (20%)
Serum/urine HCG ≥10,000 IU/L	17 (68%)
Outcome of death	8 (32%)
Time from onset to diagnosis, mo	5.67 ± 4.96
Age, y	31.24 ± 7.82

HCG=human chorionic gonadotropin.  
\* Values are shown as means ± SD or no. (%).

**Table 2**  
**Comparison of characteristics between patients with complete recovery and those with progressive development.**

	CR group* (n=17)	PD group* (n=8)
Time of diagnosis, mo	5.82 ± 5.33	5.34 ± 4.38
Age, y	31.18 ± 7.81	31.38 ± 8.37
Chemotherapy	17 (100%)	2 (25%)
Thrombolytic therapy or embolectomy	7 (41%)	3 (38%)
anticoagulant therapy	13 (76%)	3 (38%)

CR=complete recovery in outcome, PD=progressive development in outcome.  
\* Values are shown as means ± SD or no. (%).

The prognosis and treatment outcomes varied among previous reports. Complete recovery was reported for 17 patients, while 8 patients died during hospitalization. We evaluated some factors that might influence the outcomes (Table 2). Strikingly, all 17 patients (100%) with complete recovery received chemotherapy, while only 2 of 8 patients (25%) who died during hospitalization received chemotherapy. These observations support the potential therapeutic benefit of chemotherapy in the treatment of choriocarcinoma with PE.

The case we reported here illustrates the challenges in diagnosing choriocarcinoma when it first presents with respiratory symptoms. The challenges can come from 3 sides, including the patient, the doctor, and the disease itself. The patient may think that irregular periods are common for women and not worthy of reporting, and she may also be reluctant to report her history of pregnancy and abortion. The doctor may pay little attention to the history of menstruation and pregnancy, and/or has low awareness of the association of choriocarcinoma with respiratory symptoms. The disease itself is uncommon but complicated by its nonspecific, insidious presentation. As found in our literature review of 25 cases (Table 1), the average time for diagnosis of choriocarcinoma after the onset of symptoms was 5 months (ranging from 5 days to 18 months).

Our case report highlights the importance of a detailed review of the menstrual and pregnant history and a close follow-up of the HCG level in diagnosis and management of choriocarcinoma with lung metastasis. For any woman of childbearing age who present dyspnea, PE, or pulmonary arterial hypertension, the possibility of choriocarcinoma should be considered and the history of menstruation, pregnancy, and abortion should be reviewed in detail. It is essential to measure HCG before commencing chemotherapy, especially biopsy of lesions is highly risky in this very vascular disease.<sup>[8]</sup> HCG testing plays an important role not only in the diagnosis of choriocarcinoma but also in the evaluation of its prognosis of treatment outcomes. In our case, the HCG level dropped sharply following chemotherapy (Fig. 2). Furthermore, the HCG level has been included as a parameter to classify gestational trophoblastic neoplasias by FIGO and guide the selection of chemotherapy regimens for these cancers.<sup>[6,7]</sup> Some scientists reported that circulating tumor DNA could be detected through simple blood samples and determined the source of HCG-related tumors, which could help doctors diagnose malignant trophoblastic disease early and determine FIGO classifications to guide the selection of chemotherapy.<sup>[6,29]</sup>

Our case report also highlights the important role of chemotherapy in the treatment of choriocarcinoma. Like all gestational trophoblastic neoplasias, choriocarcinoma cells have short doubling times and are highly sensitive to chemotherapy, which implies that early chemotherapy is essential to reduce manifestations, prevent progression, and achieve the best possible

outcome.<sup>[22]</sup> The guideline of European Society for Medical Oncology suggested that gestational trophoblastic neoplasias is treated on clinical, rather than pathological.<sup>[8]</sup> In our case, choriocarcinoma was not diagnosed in its early stage, which delayed the chemotherapy for more than 4 months. After admission to our hospital, 1 course of EMA-CO chemotherapy resulted in substantial improvement in symptoms and a significant decrease in the HCG level and pulmonary artery pressure, though the patient showed bone marrow inhibition, could not continue further chemotherapy, and finally died after discharging. The benefit of chemotherapy in treatment of choriocarcinoma is strongly supported by our review of 25 cases in the literature in which all 17 cases receiving chemotherapy showed complete recovery while 6 of 8 cases without chemotherapy died during hospitalization.

If the patients of choriocarcinoma with PE are in an unstable hemodynamic situation, appropriate chance of chemotherapy became difficult. Chung et al<sup>[14]</sup> reported a case, with the supporting of extracorporeal membrane oxygenation, accepted chemotherapy successfully and got a good outcome. In the 10th edition guideline of American College of Chest Physician, LMWH treatment remains the first preferred medication for cancer patients with deep vein thrombosis or PE, and direct oral anticoagulants (DOACs) or warfarin is recommended for patients not suitable for LMWH treatment.<sup>[30]</sup> The emergence of DOACs in recent years has brought new hope to cancer patients with thromboembolism, which have the advantages of more convenient administration, no need to monitor coagulation function, and less drug interactions.<sup>[31]</sup> It is worthwhile to explore appropriate anticoagulation for such patients with choriocarcinoma and PE.

#### 4. Conclusion

We presented an unusual case of choriocarcinoma accompanied with PE. This case report, together with the literature review of 25 similar cases, illustrates the challenges in diagnosis of choriocarcinoma presenting with respiratory symptoms, and highlights the importance of early diagnosis and timely appropriate chemotherapy in this disease. Physicians should have a high awareness of the association of choriocarcinoma with respiratory symptoms in women at the reproductive age.

#### References

- [1] Lewis JL Jr. Diagnosis and management of gestational trophoblastic disease. *Cancer* 1993;71(4 Suppl):1639–47.
- [2] Ma L, Zhu Y, Sun H, et al. A lesson from a rare cause of pulmonary embolism. *Respir Care* 2013;58:e149–152.
- [3] Seckl MJ, Rustin GJ, Newlands ES, et al. Pulmonary embolism, pulmonary hypertension, and choriocarcinoma. *Lancet* 1991;338:1313–5.
- [4] Ngan HY, Seckl MJ, Berkowitz RS, et al. Update on the diagnosis and management of gestational trophoblastic disease. *Int J Gynaecol Obstet* 2015;131(Suppl 2):S123–126.
- [5] Wang C, Zhai Z, Yang Y, et al. Efficacy and safety of low dose recombinant tissue-type plasminogen activator for the treatment of acute pulmonary thromboembolism: a randomized, multicenter, controlled trial. *Chest* 2010;137:254–62.
- [6] Committee FO. FIGO staging for gestational trophoblastic neoplasia 2000. FIGO Oncology Committee. *Int J Gynaecol Obstet* 2002;77:285–7.
- [7] Seckl MJ, Gillmore R, Foskett M, et al. Routine terminations of pregnancy: should we screen for gestational trophoblastic neoplasia? *Lancet* 2004;364:705–7.
- [8] Seckl MJ, Sebire NJ, Fisher RA, et al. Gestational trophoblastic disease: ESMO Clinical Practice Guidelines for diagnosis, treatment and follow-up. *Ann Oncol* 2013;24(Suppl 6):vi39–50.
- [9] Yates JW, Chalmer B, McKegney FP. Evaluation of patients with advanced cancer using the Karnofsky performance status. *Cancer* 1980;45:2220–4.
- [10] Bagshawe KD, Brooks WD. Subacute pulmonary hypertension due to chorionepithelioma. *Lancet* 1959;1:653–8.
- [11] Brusselle G, Van Nooten G, Delrue L, et al. Cor pulmonale and respiratory failure in a young woman. *Respiration* 2005;72:549–51.
- [12] Chai L, Ong KC, Ng SB. A case of pulmonary tumour embolism mimicking miliary tuberculosis. *Respirology* 2000;5:297–9.
- [13] Chen DC, Hsu HH, Yu CP, et al. Improvement in uterine choriocarcinoma complicated by life-threatening pulmonary infarction. *Acta Obstet Gynecol Scand* 2006;85:370–3.
- [14] Chung JH, Yeo HJ, Cho HM, et al. Treatment of pulmonary tumor embolism from choriocarcinoma: extracorporeal membrane oxygenation as a bridge through chemotherapy. *Cancer Res Treat* 2017;49:279–82.
- [15] De Hendrickse JP, Willis AJ, Evans KT. Acute dyspnoea with trophoblastic tumours. *J Obstet Gynaecol Br Commonw* 1965;72:376–83.
- [16] El Fekih L, Hassene H, Fenniche S, et al. Pulmonary metastases revealing choriocarcinoma. *Tunis Med* 2010;88:49–51.
- [17] Gangadharan VP, Chitrathara K, Sivaramakrishnan R, et al. Pulmonary hypertension: a rare presentation of choriocarcinoma. *Acta Oncol* 1993;32:461–2.
- [18] Graham JP, Rotman HH, Weg JG. Tumor emboli presenting as pulmonary hypertension. A diagnostic dilemma. *Chest* 1976;69:229–30.
- [19] Hebart H, Erley C, Kaskas B, et al. Positron emission tomography helps to diagnose tumor emboli and residual disease in choriocarcinoma. *Ann Oncol* 1996;7:416–8.
- [20] Khakural P, Shrestha KR, Sapkota R, et al. An unusual case of pulmonary embolism. *J Surg Case Rep* 2015;2015: pii: rjv006.
- [21] Ong C, Low SY, Thirugnanam A, et al. Metastatic trophoblastic disease masquerading as pulmonary embolism. *Thorax* 2008;63:1030.
- [22] Savage P, Roddie M, Seckl MJ. A 28-year-old woman with a pulmonary embolus. *Lancet* 1998;352:30.
- [23] Watanabe S, Shimokawa S, Sakasegawa K, et al. Choriocarcinoma in the pulmonary artery treated with emergency pulmonary embolectomy. *Chest* 2002;121:654–6.
- [24] Yutani C, Imakita M, Ishibashi-Ueda H, et al. Pulmonary hypertension due to tumor emboli: a report of three autopsy cases with morphological correlations to radiological findings. *Acta Pathol Jpn* 1993;43:135–41.
- [25] Chen YW. A Case Report of Pulmonary Embolism. Wuhan University; 2005, Chinese. <http://t.cn/R9rJNF7>.
- [26] Wang Y. Pregnancy accompanied with choriocarcinoma, splenic rupture, and tumor pulmonary embolism. *Clin Misdiagn Misther* 2007;12:49–50. Chinese.
- [27] Huang Y, Liang XM, Wang HY. A case of pulmonary embolism caused by choriocarcinoma. *Chin J Clin Oncol* 2014;41:280 Chinese.
- [28] Tajiri S, Ozawa H, Komatsu M, et al. [A case of choriocarcinoma of suspected lung origin manifesting pulmonary embolism]. *Nihon Kokyuki Gakkai Zasshi* 2008;46:1029–33.
- [29] Bolze PA, Slim R. Circulating tumor DNA: a potential novel diagnostic approach in gestational trophoblastic neoplasia. *EBioMedicine* 2016;4:11–2.
- [30] Kearon C, Akl EA, Ornelas J, et al. Antithrombotic therapy for VTE disease: CHEST Guideline and Expert Panel Report. *Chest* 2016;149:315–52.
- [31] Franchini M, Bonfanti C, Lippi G. Cancer-associated thrombosis: investigating the role of new oral anticoagulants. *Thromb Res* 2015;135:777–81.