

Diagnosis and management options in malignant pleural effusions

Ramakant Dixit, KC Agarwal, Archana Gokhroo¹, Chetan B Patil, Manoj Meena, Narender S Shah², Piyush Arora

Departments of Respiratory Medicine, ¹Internal Medicine and ²Radiation Oncology, J.L.N. Medical College, Ajmer, Rajasthan, India

ABSTRACT

Malignant pleural effusion (MPE) denotes an advanced malignant disease process. Most of the MPE are metastatic involvement of the pleura from primary malignancy at lung, breast, and other body sites apart from lymphomas. The diagnosis of MPE has been traditionally made on cytological examination of pleural fluid and/or histological examination of pleural biopsy tissue that still remains the initial approach in these cases. There has been tremendous advancement in the diagnosis of MPE now a day with techniques i.e. characteristic Ultrasound and computed tomography features, image guided biopsies, fluorodeoxyglucose-positron emission tomography imaging, thoracoscopy with direct biopsy under vision, tumor marker studies and immunocytochemical analysis etc., that have made possible an early diagnosis of MPE. The management of MPE still remains a challenge to pulmonologist and oncologist. Despite having various modalities with better tolerance such as pleurodesis and indwelling pleural catheters etc., for long-term control, all the management approaches remain palliative to improve the quality of life and reduce symptoms. While choosing an appropriate management intervention, one should consider the clinical status of the patient, life expectancy, overall cost, availability and comparative institutional outcomes, etc.

KEY WORDS: Malignancy, pleural effusion, pleurodesis, thoracoscopy

Address for correspondence: Dr. Ramakant Dixit, Department of Respiratory Medicine, J.L.N. Medical College, Ajmer, Rajasthan, India.
E-mail: dr.ramakantdixit@gmail.com

INTRODUCTION

Malignancy is the most common manifestation of the pleural involvement by advanced malignant disease occurring in approximately half of all patients with metastatic carcinomas. About two-third of malignant pleural effusions (MPE) are secondary to lung cancers, breast cancers and lymphomas. Next to these sites is ovarian carcinoma followed by other malignancies. In about 6% of these patients, the primary site is not identified.^[1]

Involvement of pleura in the malignant tumor can occur directly or indirectly. The direct involvement of pleura results from the several mechanism that includes pleural

metastasis with increased permeability, pleural metastasis with obstruction of pleural lymphatics, mediastinal lymph node involvement, thoracic duct interruption, bronchial obstruction, pericardial involvement, etc., Indirect involvement of pleura in malignancy may also results secondary to hypoproteinaemia, postobstructive pneumonitis, pulmonary embolism, postradiotherapy, etc., in these cases.^[2]

CLINICAL ASSESSMENT

The initial clinical assessment essentially includes an in-depth clinical history to identify the possible underlying cause for pleural effusion. Symptoms and signs may

Access this article online	
Quick Response Code: 	Website: www.lungindia.com
	DOI: 10.4103/0970-2113.201305

This is an open access article distributed under the terms of the Creative Commons Attribution-NonCommercial-ShareAlike 3.0 License, which allows others to remix, tweak, and build upon the work non-commercially, as long as the author is credited and the new creations are licensed under the identical terms.

For reprints contact: reprints@medknow.com

How to cite this article: Dixit R, Agarwal KC, Gokhroo A, Patil CB, Meena M, Shah NS, *et al.* Diagnosis and management options in malignant pleural effusions. Lung India 2017;34:160-6.

be specific to the respiratory system or nonspecific one. Dyspnea is a major respiratory symptom in such patients and is usually progressive. This is seen in up to 50% of the patients of MPE and due to several factors that includes loss of functional lung tissue secondary to atelectasis, mediastinal shift and most importantly reduced compliance of chest wall.^[3] Chest pain is another important symptom in these patients although it is nonspecific and can occur in inflammatory processes such as infections and other conditions like pulmonary infarction. About 60% of patients having mesothelioma experience constant dull or occasionally localized pleuritic chest pain compared with patients having MPE due to adenocarcinoma.^[4] Hemoptysis usually point towards associated endobronchial lesion. A cough is another nonspecific symptom. History is also useful in getting information about asbestos exposure to suggest mesothelioma and other conditions like drug-induced pleural effusion.

Constitutional symptoms such as fever, decreased appetite, weight loss, night sweats, restriction of daily activities, although nonspecific one, are most often seen. A previous history of malignancy at other body sites even in the remote past should be seriously asked in such patients.

Physical examination should be thorough in these patients. The findings of superior vena cava obstruction, soft tissue swellings or lymph nodes are important to suspect malignancy and reach the final diagnosis. In all women, a careful breast and pelvic examination should always be attempted as these may be the sites for primary malignancy. Respiratory system examination findings usually suggest pleural effusion in such cases depending on the amount of pleural effusion. One should not forget to leave the possibility bilateral pleural effusions that can occur in this situation.

IMAGING STUDIES

Chest radiograph

It is almost always abnormal in patients with MPE. A standard chest radiograph can detect as little as 50 ml of pleural fluid on lateral view. A massive or recurrent effusion with shift of mediastinum to contra lateral side usually point toward underlying malignant etiology [Figure 1a]. Chest radiograph may also show some additional features such as lobulated pleural thickening, plaques, atelectasis, consolidation, mass lesion, mediastinal widening, reticulonodular shadows or lymphangitic patterns, etc.^[5]

Chest ultrasonography

It has 100% sensitivity to diagnose pleural effusion. Even small or loculated effusion can be best detected on ultrasonography. Effusions with loculations and fibrous septa may sometimes give pseudo mass like appearance on chest radiography that may be resolved by chest ultrasound. Chest ultrasound also detects tumor in relation to parietal pleura and chest wall. It is an important tool not only for screening but also in diagnosing MPE by

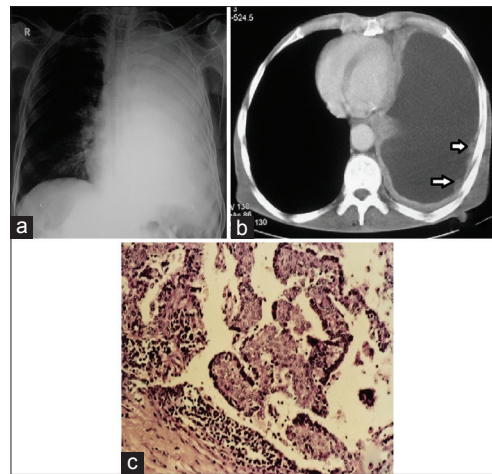


Figure 1: (a) Chest radiograph showing massive pleural effusion with ipsilateral mediastinal shift; (b) computed tomography scan showing mediastinal pleural thickening with focal nodular areas (see arrows); (c) computed tomography guided pleural biopsy of the same patient showing histological features consistent with epithelioid variety of malignant mesothelioma

doing guided aspiration, fine needle aspiration cytology, biopsy etc.^[6]

Certain ultrasonographic features such as pleural nodularity, pleural thickening more than 10 mm, diaphragmatic thickening more than 7 mm are diagnostic of malignancy with 73% sensitivity and 100% specificity.^[7] An echogenic swirling pattern characterized by numerous free floating echogenic particles swirling in the pleural cavity during respiratory movements or heart beat is another sign that points toward MPE.^[8] Pleural metastases may appear as circular, nodular or broad based with frond-like extensions in the pleural cavity.^[9]

Computed tomography

Computed tomography (CT) of the chest is an important investigation in patients of MPE. It is superior to conventional chest radiograph and ultrasound in detecting pleural thickening and focal masses. Not only pleural space but also the lung parenchyma and mediastinum can be assessed in such cases. The CT features highly suggestive of malignancy are nodular pleural thickening, pleural irregularity, mediastinal pleural thickening, circumferential pleural thickening, and pleural thickness more than 10 mm^[10] [Figure 1b]. The reported sensitivity is 36–51% with specificity of 88–100%. However, in a large series of 370 patients the sensitivity was 68%, but the specificity was 78% with a negative predictive value of 65% only stressing the role of invasive pleural biopsies even in patients having negative CT report for malignancy.^[11]

Magnetic resonance imaging

Magnetic resonance imaging (MRI) has a limited role in pleural effusion due to poor spatial resolution and motion artifacts. However T1-weighted images after intravenous gadolinium contrast may occasionally help in detecting

pleural enhancement.^[12] It is effective in detecting tumor invasion into chest wall and diaphragm. MRI with triple-echo sequence has high sensitivity for small effusions and can identify features of fluid to differentiate exudates from transudative effusions.^[13]

Fluorodeoxyglucose-positron emission tomography imaging

Chest imaging with positron emission tomography (PET) with fluorine 18-labeled fluorodeoxyglucose (FDG) has shown sensitivity of 93–100%, specificity of 67–89% in MPE with negative predictive value of 94–100%. However, false positive results can occur in uremic effusions, parapneumonic effusions, and following pleurodesis.^[14] A meta-analysis of 14 studies covering 407 patients with MPE suggest that, although of some value, FDG-PET imaging does not seem to change the probability of pleural malignancy sufficiently enough to be recommended in the routine workup of effusions of undetermined etiology.^[15]

PLEURAL THORACOCENTESIS

The diagnosis of MPE requires demonstration of malignant cells in pleural fluid for that cytological examination of pleural fluid is required. Thoracocentesis is a must investigation in all exudative pleural effusion cases with strong suspicion of malignancy.

Pleural effusion with hemorrhagic or serohemorrhagic appearance is likely to be malignant. Pleural effusion in malignancy is exudate on biochemical analysis by light's criteria. However in rare instances, a transudative pleural effusion may also show malignant cells on cytological examination.^[16] A low pleural fluid pH <7.3 and low sugar <60 mg/dl although common phenomenon in parapneumonic effusion or empyema, may also be seen in MPE and suggest extensive pleural involvement and rapid tumor cells metabolism. A low sugar and low pH malignant effusion have diagnostic, therapeutic, and prognostic implications. The diagnostic yield of pleural fluid cytology is usually high in such cases, and the outcome of therapeutic interventions and survival is also poor in such patients due to extensive pleural involvement.^[17]

PLEURAL FLUID CYTOLOGY

Pleural fluid cytology is a simplest and definitive method to diagnose MPE. However, the diagnostic yield of pleural fluid cytology ranges from 40% to 87%.^[2] The diagnostic yield of pleural fluid cytology depends on several factors such as extent of disease, nature of primary malignancy, number of specimens taken, transportation time, experience of cytopathologist, use of fixative solutions, use of cell blocks in addition to smear, and the histological type of malignancy (adenocarcinoma is commonly diagnosed compared to squamous cell carcinoma) etc.^[18] The distinction between atypical mesothelial cells and metastatic carcinoma may be difficult at times. When

adenocarcinoma is diagnosed on cytology, it is difficult to identify the primary site of the tumor. Three factors are important while considering the primary site of metastatic malignancies that include-The type of cells present in the effusion; location of effusion in relation to age and sex; and presence and nature of tumor at the distant site.^[19]

TUMOUR MARKERS IN PLEURAL FLUID

Several tumor markers such as carcinoembryonic antigen (CEA), carbohydrate antigen-125 (CA), CA-19-9, cytokeratin fragment-21-1, stage-specific embryonic antigen-1, nonspecific enolase etc., has been tested in patients of MPE.^[20] Routine use of tumor markers in the diagnosis of MPE is presently not recommended as some overlap may occur with benign effusions, and further pathological examination is warranted. In patients of effusions of undetermined cause and negative cytology, an increased pleural fluid mesothelin or fibulin-3 level strongly favors mesothelioma.^[21]

IMMUNOHISTOCHEMICAL TESTS

Use of monoclonal antibody may help to differentiate malignant from benign effusion. Immunocytochemistry also helps in differentiating epithelioid mesothelioma from adenocarcinoma and also to establish the primary site of MPE in patients with an occult primary or multiple primaries. This is an essential investigation for the diagnosis of mesothelioma now days. Metastatic adenocarcinoma reacts positively to CEA, MOC 3.1, B72.3, Ber-EP4, BG-8 and thyroid transcription factor-1 (TTF-1). Malignant mesothelial cells and benign mesothelial cells stains positive to calretinin, keratin 5/6, podoplanin, and WT-1. TTF-1 has high specificity for lung cancer [Figure 2].^[22]

Different molecular tests such as fluorescent *in situ* hybridization and gene expression may complement cytology in diagnosing MPE but requires specialized equipment and personnel, therefore limiting its routine use in clinical practice.^[23]

Biochemical/biological markers in malignant pleural fluid or serum cannot replace routine cytopathologic examination in the diagnosis of disease and predicting patient outcome without a firm diagnosis.

PLEURAL BIOPSY

Another method to diagnose MPE is to demonstrate malignant cells in the pleural tissue that can be done by pleural biopsy. The diagnostic yield of needle biopsy of the pleura in patients with MPE ranges from 39% to 75%.^[2] The diagnostic yield of pleural biopsy is relatively lower compared to pleural fluid cytology. A combination of pleural fluid cytology and needle biopsy of the pleura seems to improve the diagnostic yield compared to single

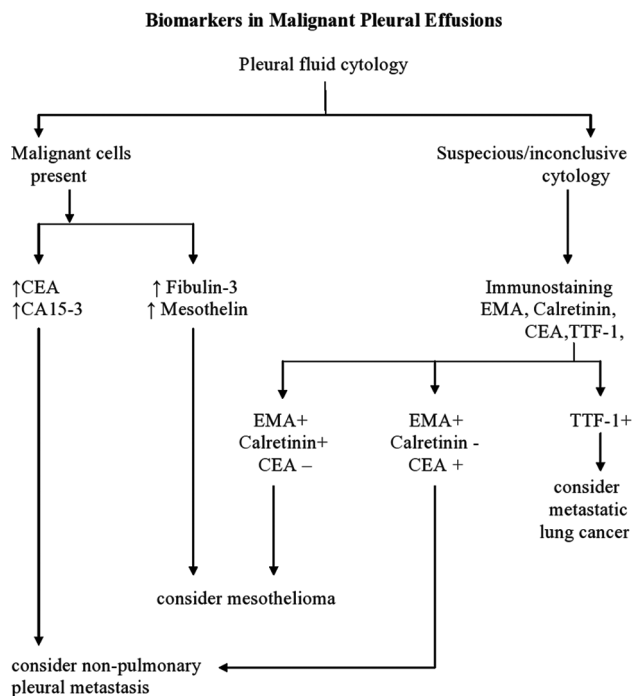


Figure 2: The biomarkers in various types of malignant pleural effusion

technique alone. Low diagnostic yield of pleural biopsy may be due to factors such as early stage disease with small pleural extension, location of tumor in those areas of pleura which are not approachable by needle (including diaphragmatic, visceral, and mediastinal pleura), number of blind biopsy specimens (at least 5 biopsy specimens are needed for accurate diagnosis), site of pleural biopsy (higher diagnostic yield when lowest costal pleura is selected) and inexperience of performing physician.^[24]

Image-guided pleural biopsy under ultrasound or CT guidance also improves diagnostic yield in cytologically negative pleural effusions compared to blind biopsy by Abram's or Cope's needle^[25] [Figure 1c].

THORACOSCOPY/PLEUROSCOPY

Thoracoscopy is considered to be gold standard in the diagnosis of MPE when previous investigation workup has turned negative. This is a simple and safe technique with diagnostic yield ranging from 93% to 97%. Procedure can be performed under local anesthesia by semi rigid or rigid thoracoscope and under general anesthesia for video-assisted thoracic surgery (VATS) with single lung ventilation to sample the pleural lesions under direct vision. Endoscopic features highly suggestive of malignancies are multiple nodule, polypoidal masses, pleural ulcerations, candle wax droplet lesions etc., [Figure 3]. Use of autofluorescence during thoracoscopy may be useful when early pleural malignancy are studied and has potential in diagnostic and staging of malignant mesothelioma. Thoracoscopy has an important role in diagnosis and staging of lung cancer causing MPE. In

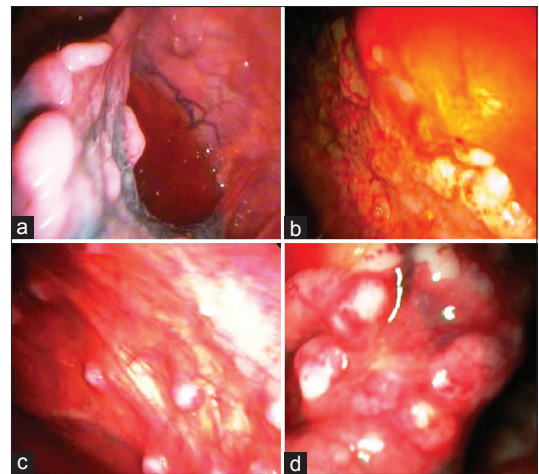


Figure 3: Thoracoscopic appearance in (a) metastatic lung cancer as multiple nodules over both visceral and parietal pleural surface; (b) malignant mesothelioma as diffuse goose like pleural thickening with irregular pleural surfaces; (c) metastatic ovarian cancer as multiple small discrete nodules; (d) metastatic sarcoma as multiple large polypoidal nodules

recent tumor–node–metastasis staging of lung cancer, pleural metastasis/effusion is defined as Stage M1a (from T4) representing/corresponding change from Stage III b to Stage IV. It is rare to find resectable lung cancer in presence of exudative pleural effusion despite having negative cytology. Therefore, thoracoscopy can establish operative eligibility by determining if the pleural effusion is paramalignant or due to metastasis.^[26]

Thoracoscopy is also favored over thoracotomy in patients of malignant mesothelioma. As the pleural specimens are equally comparable, staging can be performed in a minimally invasive manner and fluorescence detection using 5-aminolevulinic acid can be applied to improve staging.^[26]

Complications of thoracoscopy are usually mild and include hemorrhage, hypotension, cardiac arrhythmia, prolonged air leak, subcutaneous emphysema, postoperative fever, empyema, wound infection, and seeding of chest wall, especially in malignant mesothelioma. Mortality in conventional thoracoscopy using rigid instrument ranges from 0.09% to 0.24% that is comparable with conventional bronchoscopic transbronchial lung biopsy.^[26]

BRONCHOSCOPY

Bronchoscopy is indicated in patients where endobronchial/endotracheal lesion are suspected and those cases having hemoptysis. This is also preferred in those patients having atelectasis and pulmonary infiltrates on chest X-ray and/or CT scan. Bronchoscopy is helpful in assessing the extent of disease in the tracheobronchial tree for management and prognosis of lung cancer associated effusions. Figure 4 illustrates the initial diagnostic approach in suspected cases of MPE.^[27]

MANAGEMENT OPTIONS IN MALIGNANT PLEURAL EFFUSIONS

MPE still remains a therapeutic challenge to pulmonologist and oncologist. The primary goal of treating MPE is palliative to improve quality of life and reduce symptoms. The various therapeutic options for patients with recurrent MPE are summarized in following [Table 1].

Therapeutic options in malignant pleural effusion

The initial step after diagnosis in these patients should be search of primary site of malignancy. Certain primary malignancies i.e., small cell lung cancer, breast carcinoma,

ovarian carcinoma, some nonsmall cell lung cancers and lymphoma etc., respond positively to systemic chemotherapy. In these cases definitive intervention beyond this approach may not be necessary for MPE. Many of these cases respond to simple drainage for symptomatic relief pending response to the systemic chemotherapy. However, if there is recurrence of effusion after systemic therapy definitive management should be considered. If the patient is having chylothorax, radiotherapy should be given to mediastinum.^[2,28]

Those patients where primary malignancy is not responsive to chemotherapy or fails to respond to chemotherapy, definitive management approach should be considered for recurrent symptomatic MPE. It is also important to note that only those patients who are dyspneic and whose dyspnea improves after therapeutic thoracentesis should be considered for pleural fluid removal. If the patient is asymptomatic and effusion is small no treatment is recommended and simple observation is required.^[2]

Those patients where dyspnea do not improve after therapeutic thoracentesis, alternative causes of dyspnea should be ruled out such as microtumor emboli, lymphangitis carcinomatosa, pulmonary thromboembolism, effect of chemo or radiotherapy, cardiac failure, pericardial effusion, restrictive cardiomyopathy due to tumor infiltration, constrictive pericarditis, airway obstruction by tumor, bilateral vocal cord paralysis, concurrent infection, cancer-related cachexia, myopathy, deconditioning, chest wall invasion by tumor, etc.^[29] Many of these patients requires supportive and symptomatic treatment that includes oxygen and/or opiates.

All symptomatic patients of MPE having dyspnea relieved by therapeutic thoracentesis and when effusion is recurrent, moderate to massive even after systemic chemotherapy to primary malignancy should be subjected to definitive management approach that includes thoracostomy drainage followed by pleurodesis or indwelling pleural catheter. Repeated thoracentesis is another option in those patients where fluid re accumulate rapidly, expected survival is 1–3 months and interventional procedures cannot be tolerated.^[30]

Chest tube drainage is primarily used in MPE for symptomatic relief and chemical pleurodesis. Smaller chest tubes (10–14 French size) equally works well as larger chest tubes and are recommended by British Thoracic Society guidelines.^[31] After tube thoracostomy if the lung expands, pleurodesis is the procedure of choice. However if the underlying remains collapsed after tube thoracostomy, pleurodesis should not be attempted. These patients require either indwelling pleural catheter or pleuro-peritoneal shunts.

PLEURODESIS

Pleurodesis is one of the most commonly used management approaches. This is considered in patients

Algorithm for Diagnosis in Suspected Malignant Pleural Effusion (MPE)

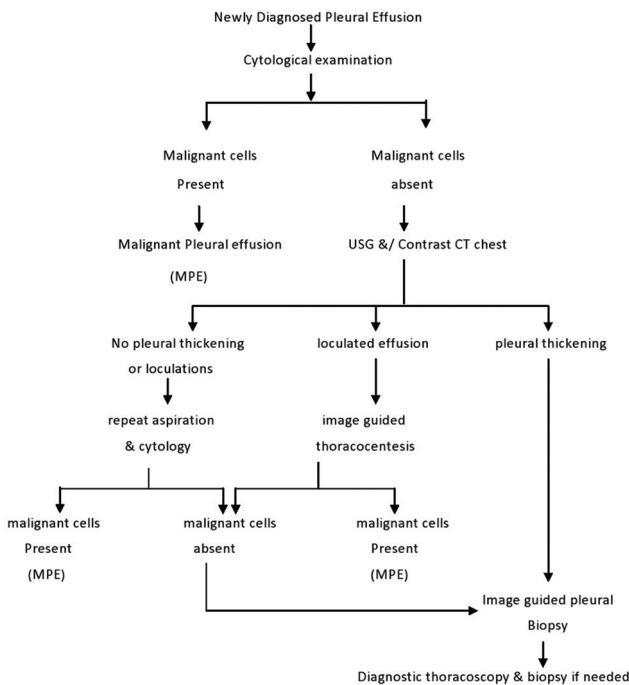


Figure 4: The diagnostic steps in suspected malignant pleural effusion

Table 1: Management options in MPE

- Simple observation
- Systemic chemotherapy for underlying malignancy
- Repeated thoracentesis
- Chest tube drainage alone (tube thoracostomy)
- Pleurodesis
 - Physical
 - Chemical
 - Biological
 - Mechanical
- Pleural catheters
- Surgical method
 - Pleuroperitoneal shunt
 - Pleurectomy
- Other measures
 - Intrapleural chemotherapy
 - Radiotherapy for chylothorax
 - Intrapleural fibrinolytic agents for multiloculated effusions
- Supportive and symptomatic (oxygen, opiates, etc.)

MPE = Malignant pleural effusions

with MPE who are not suitable candidates for pleural catheter or systemic chemotherapy and also where systemic chemotherapy or mediastinal radiotherapy has failed. Only symptomatic patients having massive and recurrent collection with mediastinal shift to opposite side responds best to pleurodesis. Successful pleurodesis requires apposition of the visceral and parietal pleura. Patients with underlying trapped lung or endobronchial obstruction are unlikely to respond.^[32] Various methods such as physical, chemical, and biological agents have been used for pleurodesis. The commonly used agents are tetracycline or its derivative, quinacrine, iodopovidine, bleomycin, mitoxantrone, cisplatin, doxorubicin, etoposide, fluoro uracil, mitomycin, interferons (IFN) and methyl prednisolone, *Corynebacterium parvum*, etc., apart from talc with varying success rates. The talc is most commonly used agent with highest efficacy and least cost that can be given as slurry through drainage tube or via insufflation method by thoracoscopy.^[2]

Controversies exist as to whether talc slurry is as efficacious as aerosolized talc via thoracoscopy. Although the two techniques are equally effective, thoracoscopic insufflations of talc has been found marginally superior to talc slurry in a recent phase III prospective study on 482 patients of lung cancer.^[33] The risk of acute respiratory distress syndrome using talc is directly related to the dose, particle size or other factors related to its instillation. Larger particle size (more than 15 microns) has reduced the risk of this complication now days.^[34]

Thoracoscopic pleurodesis can be achieved either through VATS or medical thoracoscopy. The pleurodesis can be achieved by intrapleural sclerosants or pleural abrasion using dry-gauze pea nut. Pleurodesis using medical thoracoscopy under local anesthesia and moderate sedation has been shown to achieve success rate up to 97% with low morbidity.^[35]

In a prospective multicenter trial, the second therapeutic intervention in malignant effusion trial 2 recently compared patients undergoing talc pleurodesis using 12 Fr small bore catheter tube with indwelling tunneled pleural catheters. The success rate of 89% was seen by pleurodesis in 54 patients that received talc slurry via chest drains.^[36]

INDWELLING TUNNELED PLEURAL CATHETER

Tunneled pleural catheter system (Pleur X) is a 15.5 Fr catheter that may be placed in outpatient setting under local anesthesia. Drainage is performed daily or alternate day by the patient, family members or visiting healthcare professionals. Spontaneous pleurodesis have been reported in 21–58% patients; however, symptomatic improvement occurs in 81–100% patients.^[37] Complications are generally low (5–27%) and includes bleeding, pneumothorax,

cellulitis, empyema, catheter obstruction with subsequent tension pleural effusion and tumor spread along the catheter tract, etc.^[38] This method is becoming increasingly popular in view of reduced hospitalizations, recovery time and overall cost.^[39]

If above procedures fails, pleuro-peritoneal shunt, or pleurectomy can be considered. However, these procedures are costly, associated with high morbidity, operative mortality and should be reserved in patients with significant anticipated life expectancy.^[40]

Management of malignant pleural mesothelioma is multimodality treatment programs that combine maximal surgical cytoreduction with novel forms of radiation therapy and more effective chemotherapy combination to offer survival benefits. Lung sparing surgery may allow improvements in pulmonary functions after surgery based multimodality therapy compared to extrapleural pneumonectomy. Experimental treatment such as immunotherapy and gene therapy (suicide gene therapy and cytokine gene therapy) may be future modality of treatment in addition to current standard therapy.^[41]

Role of intrapleural chemotherapy for management of MPE is controversial. This has been applied in hope to reduce the tumor cells in pleural space. Its efficacy is doubtful if the tumor is disseminated. Therapeutic efficacy of *Staphylococcus aureus* superantigen has also been evaluated in MPE from nonsmall cell lung cancer in small case series to control the effusion and improve survival.^[42] Other intrapleural agents investigated include Rituximab, IFN-gamma, interleukin-2 etc.^[2]

In multiloculated pleural effusions intrapleural fibrinolytic agents i.e. streptokinase has also been used successfully to relieve dyspnea in these terminally ill-patients without any complications.^[43]

PROGNOSIS

Life expectancy is usually short in patients of MPE. The rationale approach to treatment is usually palliative involving drainage of pleural effusion and prevention of recurrence. Median survival in these patients ranges from 3 to 12 months depending on the primary site, stage and histological type of underlying malignancy (17.4 months in mesothelioma, 13.2 months in breast cancers, 7 months in lymphoma and 2.6 months in lung cancers).^[44]

Poor prognosis factors in these patients also includes the Karnofsky performance scale <30, pH of pleural fluid <7.2, pleural fluid glucose <60 mg/dl, pleural fluid lactate dehydrogenase more than twice the upper limit of normal for serum, pleural adhesions seen on thoracoscopy, higher vascular endothelial growth factor levels in pleural effusions due to lung cancers.^[45] All these situations reflects greater tumor burden in the pleural space.

CONCLUSION

MPE is a common manifestation in patients having advanced lung cancer and other malignancies. There has been a considerable improvement in the diagnosis of MPE through newer cytologic and imaging techniques with improved methods of pleural biopsy. Despite various well tolerated techniques to control MPE by pleurodesis or long-term catheter drainage, all management approaches remain palliative. While selecting an appropriate intervention, clinician should consider patients general condition, cost, expected survival, local expertise, and comparative institutional outcome from the available techniques.

Financial support and sponsorship

Nil.

Conflicts of interest

There are no conflicts of interest.

REFERENCES

- Anderson CB, Philpott GW, Ferguson TB. The treatment of malignant pleural effusions. *Cancer* 1974;33:916-22.
- Light RW. *Pleural Diseases*. 6th ed. Philadelphia: Lippincott Williams and Wilkins; 2013.
- Estenne M, Yernault JC, De Troyer A. Mechanism of relief of dyspnea after thoracentesis in patients with large pleural effusions. *Am J Med* 1983;74:813-9.
- Lee YC, Light RW, Musk AW. Management of malignant pleural mesothelioma: A critical review. *Curr Opin Pulm Med* 2000;6:267-74.
- Qureshi NR, Gleeson FV. Imaging of pleural disease. *Clin Chest Med* 2006;27:193-213.
- Tsai TH, Yang PC. Ultrasound in the diagnosis and management of pleural disease. *Curr Opin Pulm Med* 2003;9:282-90.
- Qureshi NR, Rahman NM, Gleeson FV. Thoracic ultrasound in the diagnosis of malignant pleural effusion. *Thorax* 2009;64:139-43.
- Chian CF, Su WL, Soh LH, Yan HC, Perng WC, Wu CP. Echogenic swirling pattern as a predictor of malignant pleural effusions in patients with malignancies. *Chest* 2004;126:129-34.
- Mayo PH, Doelken P. Pleural ultrasonography. *Clin Chest Med* 2006;27:215-27.
- Traill ZC, Davies RJ, Gleeson FV. Thoracic computed tomography in patients with suspected malignant pleural effusions. *Clin Radiol* 2001;56:193-6.
- Hallifax RJ, Haris M, Corcoran JP, Leyakathalikhhan S, Brown E, Srikantharaja D, et al. Role of CT in assessing pleural malignancy prior to thoracoscopy. *Thorax* 2015;70:192-3.
- Evans AL, Gleeson FV. Radiology in pleural disease: State of the art. *Respirology* 2004;9:300-12.
- Davis SD, Henschke CI, Yankelevitz DF, Cahill PT, Yi Y. MR imaging of pleural effusions. *J Comput Assist Tomogr* 1990;14:192-8.
- Duysinx B, Nguyen D, Louis R, Cataldo D, Belhocine T, Bartsch P, et al. Evaluation of pleural disease with 18-fluorodeoxyglucose positron emission tomography imaging. *Chest* 2004;125:489-93.
- Porcel JM, Hernández P, Martínez-Alonso M, Bielsa S, Salud A. Accuracy of fluorodeoxyglucose-PET imaging for differentiating benign from malignant pleural effusions: A meta-analysis. *Chest* 2015;147:502-12.
- Assi Z, Caruso JL, Herndon J, Patz EF Jr. Cytologically proved malignant pleural effusions: Distribution of transudates and exudates. *Chest* 1998;113:1302-4.
- Rodríguez-Panadero F, López Mejías J. Low glucose and pH levels in malignant pleural effusions. Diagnostic significance and prognostic value in respect to pleurodesis. *Am Rev Respir Dis* 1989;139:663-7.
- Järvi OH, Kunnas RJ, Laitio MT, Tyrkkö JE. The accuracy and significance of cytologic cancer diagnosis of pleural effusions. (A followup study of 338 patients). *Acta Cytol* 1972;16:152-8.
- Bedrossian CW. Diagnostic problems in serous effusions. *Diagn Cytopathol* 1998;19:131-7.
- Porcel JM, Vives M, Esquerda A, Salud A, Pérez B, Rodríguez-Panadero F. Use of a panel of tumor markers (carcinoembryonic antigen, cancer antigen 125, carbohydrate antigen 15-3, and cytokeratin 19 fragments) in pleural fluid for the differential diagnosis of benign and malignant effusions. *Chest* 2004;126:1757-63.
- Porcel JM. Pleural fluid biomarkers: Beyond the light criteria. *Clin Chest Med* 2013;34:27-37.
- Ordóñez NG. What are the current best immunohistochemical markers for the diagnosis of epithelioid mesothelioma? A review and update. *Hum Pathol* 2007;38:1-16.
- Sriram KB, Relan V, Clarke BE, Duhig EE, Yang IA, Bowman RV, et al. Diagnostic molecular biomarkers for malignant pleural effusions. *Future Oncol* 2011;7:737-52.
- Canto A, Rivas J, Saumench J, Morera R, Moya J. Points to consider when choosing a biopsy method in cases of pleurisy of unknown origin. *Chest* 1983;84:176-9.
- Maskell NA, Gleeson FV, Davies RJ. Standard pleural biopsy versus CT-guided cutting-needle biopsy for diagnosis of malignant disease in pleural effusions: A randomised controlled trial. *Lancet* 2003;361:1326-30.
- Lee P, Colt HG. Pleuroscopy in 2013. *Clin Chest Med* 2013;34:81-91.
- Vergnon JM, Froudarakis M. Bronchoscopy. In: Grassi C, editor. *Pulmonary Diseases*. London: McGraw-Hill International; 1999. p. 39-43.
- Bruneau R, Rubin P. The management of pleural effusions and chylothorax in lymphoma. *Radiology* 1965;85:1085-92.
- Heffner JE, Klein JS. Recent advances in the diagnosis and management of malignant pleural effusions. *Mayo Clin Proc* 2008;83:235-50.
- Antony VB, Loddenkemper R, Astoul P, Boutin C, Goldstraw P, Hott J, et al. Management of malignant pleural effusions. *Eur Respir J* 2001;18:402-19.
- Roberts ME, Neville E, Berrisford RG, Antunes G, Ali NJ; BTS Pleural Disease Guideline Group. Management of a malignant pleural effusion: British Thoracic Society Pleural Disease Guideline 2010. *Thorax* 2010;65 Suppl 2:i32-40.
- American Thoracic Society. Management of malignant pleural effusions. *Am J Respir Crit Care Med* 2000;162:1987-2001.
- Chen H, Brahmer J. Management of malignant pleural effusion. *Curr Oncol Rep* 2008;10:287-93.
- Janssen JP, Collier G, Astoul P, Tassi GF, Noppen M, Rodriguez-Panadero F, et al. Safety of pleurodesis with talc poudrage in malignant pleural effusion: A prospective cohort study. *Lancet* 2007;369:1535-9.
- Marrazzo A, Noto A, Casà L, Taormina P, Lo Gerfo D, David M, et al. Video-thoroscopic surgical pleurodesis in the management of malignant pleural effusion: The importance of an early intervention. *J Pain Symptom Manage* 2005;30:75-9.
- Davies HE, Mishra EK, Kahan BC, Wrightson JM, Stanton AE, Guhan A, et al. Effect of an indwelling pleural catheter vs chest tube and talc pleurodesis for relieving dyspnea in patients with malignant pleural effusion: The TIME2 randomized controlled trial. *JAMA* 2012;307:2383-9.
- Spector M, Pollak JS. Management of malignant pleural effusions. *Semin Respir Crit Care Med* 2008;29:405-13.
- Tremblay A, Michaud G. Single-center experience with 250 tunneled pleural catheter insertions for malignant pleural effusion. *Chest* 2006;129:362-8.
- Rial MB, Lamela IP, Fernández VL, Arca JA, Delgado MN, Pombo CV, et al. Management of malignant pleural effusion by an indwelling pleural catheter: A cost-efficiency analysis. *Ann Thorac Med* 2015;10:181-4.
- Belani CP, Pajean TS, Bennett CL. Treating malignant pleural effusions cost consciously. *Chest* 1998;113 1 Suppl: 78S-85S.
- Haas AR, Sterman DH. Malignant pleural mesothelioma: Update on treatment options with a focus on novel therapies. *Clin Chest Med* 2013;34:99-111.
- Ren S, Terman DS, Bohach G, Silvers A, Hansen C, Colt H, et al. Intrapleural staphylococcal superantigen induces resolution of malignant pleural effusions and a survival benefit in non-small cell lung cancer. *Chest* 2004;126:1529-39.
- Dixit R, Dixit K, Bansal R. Intrapleural streptokinase in multiloculated malignant pleural effusion. *Indian J Chest Dis Allied Sci* 2004;46:59-62.
- Bielsa S, Salud A, Martínez M, Esquerda A, Martín A, Rodríguez-Panadero F, et al. Prognostic significance of pleural fluid data in patients with malignant effusion. *Eur J Intern Med* 2008;19:334-9.
- Hsu IL, Su WC, Yan JJ, Chang JM, Lai WW. Angiogenic biomarkers in non-small cell lung cancer with malignant pleural effusion: Correlations with patient survival and pleural effusion control. *Lung Cancer* 2009;65:371-6.