

Ultrasound-guided peripheral nerve interventions for common pain disorders

Krishna Prasad B P, Binu Joy, Vijayakumar A Raghavendra, Ajith Toms, Danny George, Brijesh Ray¹

Department of Radiology, Rajagiri Hospital, Aluva, ¹Department of Imaging and Interventional Radiology, Aster Medcity Hospital, Cheranelloor, Ernakulam, Kerala, India

Correspondence: Dr. Krishna Prasad B P, Department of Radiology, Rajagiri Hospital, Aluva, Ernakulam - 683 112, Kerala, India.
E-mail: krishnaprasadir@gmail.com

Abstract

There are a number of common pain disorders that can be managed effectively by injections around or ablation of peripheral nerves. Ultrasound is a universally available imaging tool, is safe, cost-effective, and is excellent in imaging many peripheral nerves and guiding needles to the site of the nerves. This article aims to present an overview of indications and techniques of such procedures that can be effectively performed by a radiologist.

Key words: Ganglion block; nerve block; perineural injection

Introduction

Peripheral nerve injections have been used for a number of common pain causing conditions. Imaging guidance using fluoroscopy, computed tomography (CT), or ultrasound ensures correct site injection; ultrasound among them has a lot of advantages including absence of radiation, real-time cross-sectional visualization of needle placement and injection, cost-effectiveness, universal availability, and portability.^[1-3] Ultrasound (using a high-frequency linear transducer) is an excellent modality for visualizing almost all peripheral nerves.^[1,3]

Nerves in cross-section show a “honeycomb” or “salt in pepper” appearance due to hypoechoic nerve fascicles separated by hyperechoic septae made of interfascicular perineurium. Nerves are less echogenic than tendons which have more compact arrangement of fibers, and are more echogenic than muscles.^[1,2] Whenever there is difficulty in identifying a nerve from adjacent muscles or tendons in

cross-section, gentle probe tilt ensuring exactly perpendicular orientation of the ultrasound beam will enhance the difference in echogenicity between these structures. The classic cross-sectional appearance of the nerves might not be apparent when they are very small or deep, in which case, they are identified by their location and relation to adjacent more apparent structures. Differentiation of smaller nerves from blood vessels is made using color Doppler.

Using ultrasound to guide peripheral nerve injections increases the success rate, and reduces drug dosage, toxicity and complications.^[3,4] Thorough understanding of anatomy and sonoanatomy of peripheral nerves and adjacent structures and proper imaging technique to demonstrate the nerve and adequate skill in ultrasound-guided injection are important for successful perineural injection without complications.

All perineural injections are performed with the aim of short to medium-term pain relief; long-term pain relief

This is an open access journal, and articles are distributed under the terms of the Creative Commons Attribution-NonCommercial-ShareAlike 4.0 License, which allows others to remix, tweak, and build upon the work non-commercially, as long as appropriate credit is given and the new creations are licensed under the identical terms.

For reprints contact: reprints@medknow.com

Cite this article as: Krishna Prasad BP, Joy B, Raghavendra VA, Toms A, George D, Ray B. Ultrasound-guided peripheral nerve interventions for common pain disorders. Indian J Radiol Imaging 2018;28:85-92.

Access this article online

Quick Response Code:



Website:
www.ijri.org

DOI:
10.4103/ijri.IJRI_108_17

depends on treatment of any underlying condition.^[2] However, long-term pain relief fortunately is seen in some patients, which can be explained by either the resolution of any inflammation or improved mobility and effective physiotherapy following injections. Sometimes, a course of repeated injections confer long-term pain relief, as seen in intercostal nerve block, and sometimes in greater occipital and ilioinguinal/iliohypogastric nerve blocks. A combination of local anaesthetic and steroid is used for injection for all therapeutic perineural injections. Local anaesthetic in isolation is used for either injection for diagnostic purposes or for acute pain relief in postoperative or post-traumatic situations. Steroids have anti-inflammatory and pain-modulating effects but might take some time for its action, during which analgesia is provided by anaesthetics.^[2] The usual combination is 4 mL of 0.5% bupivacaine and 1 mL (40 mg) of triamcinolone acetate. Methyl prednisolone and betamethasone are alternatives to triamcinolone, and the choice depends on operator preference and experience. 2% Lignocaine solution is used in carpal tunnel syndrome instead of bupivacaine to avoid unnecessary long-term anesthesia in median nerve distribution.

Chemical neurolysis, which is frequently performed in celiac plexus, trigeminal ganglion, and lumbar sympathetic chain, is not widely performed on peripheral nerves. Radiofrequency ablation, electrocoagulation, and cryoablation of peripheral nerves have been reported in multiple studies to cause successful pain relief, however, it should be performed after demonstrating a good response after perineural injection. Though these procedures cause longer duration of pain relief compared to perineural injections, they are expensive, do not confer permanent pain relief in many patients due to axonal regeneration necessitating multiple sessions of treatment, and there is a risk of neuroma formation.^[5-7] Perineural botulinum toxin type A injection, which is quite commonly used for neuropathic pain, has been tried for occipital neuralgia and carpal tunnel syndrome in small studies which has shown favorable pain relief, but multicenter trials and long-term follow-up data are lacking.^[8,9]

Median nerve injection for carpal tunnel syndrome

Median nerve compression in the carpal tunnel is the most common entrapment neuropathy worldwide.^[10,11] Cause is unknown in half the cases, and in the other half it is associated with repetitive occupational trauma, pregnancy, obesity, and hypothyroidism. In certain patients, space-occupying lesions (including synovial hypertrophy in tenosynovitis and arthritis) in the carpal tunnel cause median nerve compression.^[12,13] Flexor tendon subsynovial fibrosis and its associated vascular proliferation are considered to be the cause of idiopathic carpal tunnel syndrome.^[14] Sensory component is affected initially resulting in burning and tingling sensation in hand in median nerve distribution; motor symptoms follow later. Nerve conduction studies

are used for diagnosis.^[11,14] Ultrasonography shows swelling of the nerve at the carpal tunnel inlet, which has been shown to correlate with findings of nerve conduction studies.^[15] However, ultrasound is not routinely used for diagnosis. Ultrasound also helps in detecting anatomic variants (like bifid nerves and brachiomedian artery) and space-occupying lesions within the carpal tunnel.^[16,17] Ultrasound-guided injection is more effective than surface marking-guided injections.^[18,19] Splints are used initially for treatment, but its utility is questionable.^[20] Steroid injection in the carpal tunnel, performed when splints fail, causes clinical and electrophysiological improvement lasting as long as 10 weeks; and surgical release is used for persistently symptomatic cases.^[21,22] In our experience of treating more than 350 patients, we have seen pain relief lasting between 6 and 12 weeks, and in some patients for as long as 9 months.

Ultrasonographic nerve localization and injection technique

With the patient in supine position, the hand to be imaged is kept to the side of the patient, with forearm extended and supinated, wrist resting on a support, and fingers partially extended. Linear high-frequency transducer is kept in the ventral part of the distal-most forearm where median nerve is easily identified by its cross-sectional appearance [Figure 1A]. The nerve can be traced into the carpal tunnel in the proximal part of the palm underneath the flexor retinaculum, which is seen as a transverse hyperechoic band [Figure 1B]. Using in-plane technique,

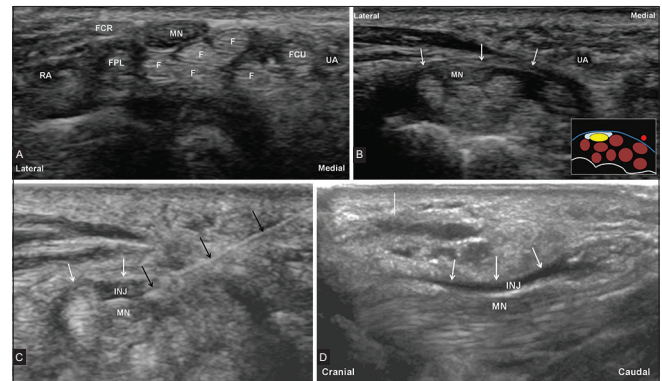


Figure 1 (A-D): (A) Ultrasound transverse image with probe placed on the ventral aspect of the distal-most forearm showing the median nerve (MN). Flexor digitorum tendons (F), flexor carpi radialis tendon (FCR), flexor carpi ulnaris tendon (FCU), flexor pollicis longus tendon (FPL), radial (RA), and ulnar (UA) arteries are also shown. (B) Ultrasound transverse image with probe placed on the ventral aspect of the proximal palm over the carpal bones showing the median nerve (MN) within the carpal tunnel bound by the flexor retinaculum ventrally (white arrows). UA is also shown. Inset: Schematic representation of anatomy – median nerve (yellow oval), flexor tendons (brown discs), ulnar artery (red disc), flexor retinaculum (blue curve) and target site of injection (white area) are shown. (C) Transverse ultrasound image of the carpal tunnel showing needle (black arrows) inserted with its tip placed between the MN and the flexor retinaculum (white arrows); and the injectate (INJ) distributed between the two structures. (D) Longitudinal view of median nerve in the carpal tunnel after injection showing longitudinal spread of INJ between the MN and the flexor retinaculum (white arrows)

either ulnar or radial site skin puncture can be used to position the tip of a 22G 1.5-inch long needle in between the flexor retinaculum and the median nerve taking care not to poke the nerve or injure the ulnar vessel (in case of ulnar side skin puncture) [Figure 1C]. A mixture of 1 ml 2% lignocaine and 40 mg triamcinolone or methyl prednisolone is injected at this site. It is not necessary to distribute the dose superficial and deep to the nerve since injection at the above-mentioned site is sufficient for circumferential distribution of the injectate.^[23] Median nerve is imaged in sagittal plane after the injection to ensure longitudinal spread of injectate [Figure 1D]. The patient is informed not to lift any heavy weights with the injected hand for 3 days and is warned of numbness in the median nerve distribution in palm for 2–4 h.

Suprascapular nerve injection for shoulder pain

Chronic shoulder pain is a considerable cause of significant disability, especially in the elderly, and has multiple causes, some of which are degenerative joint disease, adhesive capsulitis, rheumatoid arthritis, rotator cuff injury, calcific tendinitis, and hemiplegic shoulder pain.^[24] Suprascapular nerve is a mixed nerve, supplies motor branches to the supraspinatus and infraspinatus muscles, and sensory supply to the acromioclavicular and shoulder joints. The site of injection is where it courses through the suprascapular notch below the suprascapular ligament.^[24,25] Suprascapular injection has shown to be effective in reducing shoulder pain and improving functional status for as long as 3 months, and ultrasound is the preferred mode of guidance.^[26,27] Physical therapy is better tolerated after the procedure, and appropriate and regular physiotherapy can result in prolonged improvement in functional status and long-term reduction in pain; such an effect has especially been found in our experience in patients with adhesive capsulitis. In spite of the fact that there are other nerves that supply the shoulder capsule, suprascapular block-induced pain relief is profound.^[3,25] A few studies of nerve ablation for pain have shown promising results.^[28,29]

Ultrasonographic nerve localization and injection technique

With the patient in sitting position, the whole shoulder on the side to be injected is exposed. Linear ultrasound probe is placed horizontally parallel to and above the spinous process of scapula in the suprascapular fossa, and the probe is slid laterally till the suprascapular notch comes into view. The suprascapular nerve can be seen in the notch beneath the transverse scapular ligament near the suprascapular artery [Figure 2A]. Using a lateral approach and in-plane technique, a combination of 4 ml of 0.5% bupivacaine and 40 mg of triamcinolone is injected into the suprascapular notch around the nerve [Figure 2B].

Greater occipital nerve block for headaches

Greater occipital neuralgia is a condition causing occipital pain due to known or unknown causes of greater occipital

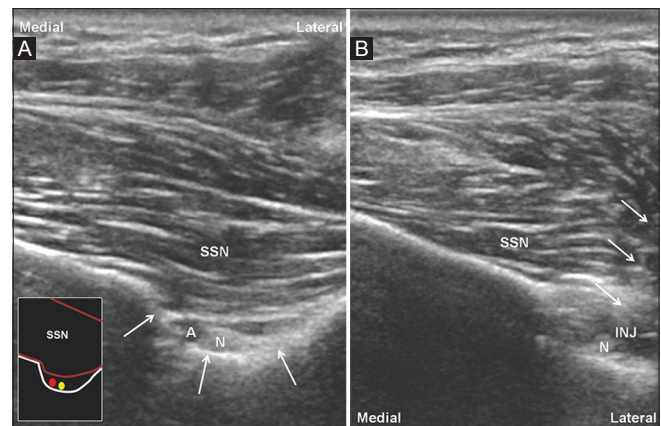


Figure 2 (A and B): (A) Ultrasound image with a linear transducer placed in the suprascapular fossa parallel to the spinous process of scapula showing the suprascapular notch (white arrows), suprascapular nerve (N) and the artery (A) deep to the supraspinatus muscle (SSN). Inset: Schematic representation of anatomy – suprascapular notch (white line), nerve (yellow disc) and artery (red disc) are shown underlying SSN. (B) Ultrasound image showing the position of the needle (white arrows) with its tip in the suprascapular notch, and the injectate (INJ) around the suprascapular nerve (N)

nerve irritation. Greater occipital neuralgia, cluster headache, and cervicogenic headaches respond well to greater occipital nerve block.^[30,31] Other kinds of headache where greater occipital nerve block causes effective pain relief include chronic migraine, postdural puncture headache, posttraumatic occipital neuralgia, and hypnic headache.^[32,33] Pain relief lasts from 3 weeks to 3 months.^[34] In our experience, the maximum duration of pain relief has been 8 months after single injection in a patient with greater occipital neuralgia. Functional connections between occipital nerve and trigeminal nerve sensory distribution due to close proximity of the spinal nucleus of trigeminal nerve to the sensory ganglion of occipital nerve explains why occipital nerve block relieves some of the anteriorly distributed headaches like cluster headache.^[32,35] Ultrasound guidance increases the success rate and precision of block, and the preferred site of injection is in the upper nape of the neck where the nerve courses close to the inferior oblique muscle.^[36–38]

Ultrasonographic nerve localization and injection technique

The patient is positioned in prone position with a pillow beneath the chest to partially flex the neck. Linear ultrasound probe is placed obliquely in the upper nape of the neck in paramedian position at C2 level with the lateral end of the probe cranial to the medial end. The lamina of axis vertebra and the inferior oblique muscle which extends from spinous process of axis to the transverse process of atlas are identified. Greater occipital nerve can be seen as a small round structure in between the inferior oblique muscle and the overlying semispinalis capitis muscle, and can be seen in both transverse and longitudinal plane [Figure 3A and B]. Vertebral artery can be seen on cranial tilt of the probe. Either a lateral or medial skin puncture

with in-plane technique is used to inject a solution of 4 ml of 0.5% bupivacaine and 40 mg of triamcinolone in the plane between the two muscles around the greater occipital nerve [Figure 3C].

Ilioinguinal/iliohypogastric and genitofemoral nerve injection

Chronic postoperative inguinal pain is a common condition characterized by moderate to severe pain persisting 3 months after inguinoscrotal surgeries, especially following hernia repairs.^[39] Ilioinguinal/iliohypogastric nerve block in isolation or along with genitofemoral nerve block are shown to be effective in control of chronic postoperative inguinal, upper medial thigh, scrotal (in males), or labia majora (in females) pain.^[3,40,41] Idiopathic persistent orchialgia has been shown to respond to ablation of the genitofemoral nerve.^[42] Duration of pain relief usually lasts longer than 3 months; one study has showed pain relief as long as 50 months.^[40] Conventional blind method of injecting in the intramuscular planes of the anterior abdominal wall to achieve block is difficult and requires higher volumes of anaesthetic; ultrasound increases precision of injection and decreases anaesthetic volumes.^[4,43,44]

Ultrasonographic ilioinguinal/iliohypogastric nerve localization and injection technique

The ilioinguinal/iliohypogastric nerves are visualized by placing a linear transducer in an oblique plane over a line joining the anterior superior iliac spine and umbilicus, with the lateral end of the transducer over the anterior superior iliac spine. The three muscle planes of the anterior abdominal wall (external oblique, internal oblique, and the transverse abdominis from superficial to deep) are identified. Ilioinguinal and iliohypogastric nerves can be easily visualized at this level in either of the two intermuscular planes between these three muscles [Figure 4A]. A small branch of the deep circumflex iliac artery often accompanies

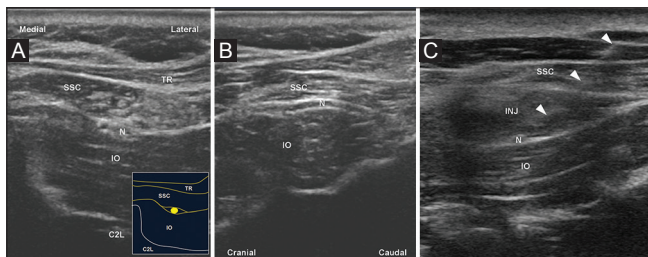


Figure 3 (A-C): (A) Ultrasound image with a linear transducer placed obliquely over the C2 lamina (C2L) showing the greater occipital nerve (N) between the internal oblique (IO) and semispinalis capitis (SSC) muscles. Trapezius muscle (TR) is seen superficial to these muscles. Inset: Schematic diagram showing anatomy, muscles are indicated by same annotations as in the sonographic image, and the greater occipital nerve is shown by the yellow disc. (B) Ultrasound image with the transducer placed along the long axis of the greater occipital nerve showing longitudinal course of the nerve caudocranially between the internal oblique (IO) and semispinalis capitis (SSC) muscles. (C) Ultrasound image showing needle (white arrowheads) placed with its tip in between the internal oblique (IO) and semispinalis capitis (SSC) muscles and injectate (INJ) around the greater occipital nerve (N)

the nerves and aids in identification of these nerves.^[45] Using in-plane technique, either a medial or a lateral approach is chosen to inject a solution of 4 cc 0.5% bupivacaine and 40 mg triamcinolone around the nerves [Figure 4B].

Ultrasonographic genitofemoral nerve localization and injection technique

Genitofemoral nerve is a content of the inguinal canal and accompanies the vas deferens and testicular vessels. The contents of the inguinal canal are identified in cross-section by placing a linear transducer in sagittal plane over the femoral vessels at the level of the origin of inferior epigastric artery from the external iliac artery (junction of external iliac and common femoral vessels). Color Doppler is utilized to identify the testicular vessels; the genitofemoral nerve can be seen as a small hyperechoic structure close to these structures [Figure 4C]. Using in-plane technique, a solution of 4 cc 0.5% bupivacaine and 40 mg triamcinolone is injected around the nerve if it can be identified or around the contents of the inguinal canal if the nerve is not identified [Figure 4D].

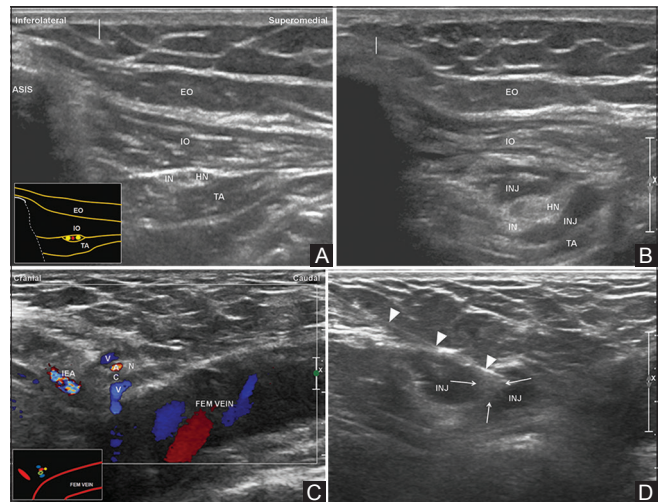


Figure 4 (A-D): (A) Ultrasound image showing the anterior superior iliac spine (ASIS) in the lateral end, the three muscle layers of the anterior abdominal wall – external oblique (EO), internal oblique (IO) and the transverse abdominis (TA) and the ilioinguinal (IN) and iliohypogastric (HN) nerves in the intermuscular plane between the internal oblique (IO) and transverse abdominis (TA) muscles. Inset: Schematic diagram showing anatomy, muscles shown with same annotations as the sonographic image, ilioinguinal and iliohypogastric nerves are shown as yellow discs and the accompanying artery shown as a red disc. (B) Ultrasound image after ilioinguinal/iliohypogastric nerve block showing the injectate (INJ) distributed around the ilioinguinal (IN) and iliohypogastric (HN) nerves. (C) Ultrasound image with Doppler with a linear transducer placed longitudinally over the femoral vein (FEM VEIN) at the site of the inferior epigastric artery (IEA) showing the contents of the inguinal canal – testicular artery (A), testicular veins (V), vas deferens (C) and the genitofemoral nerve (N). Inset: Schematic diagram of the anatomy showing the femoral vein (FEM VEIN), inferior epigastric artery (red oval), and the contents of the spermatic cord – testicular artery (red disc), testicular veins (blue discs), vas deferens (green circle) and the genitofemoral nerve (yellow disc). (D) Ultrasound image showing needle (white arrowheads) placed within the inguinal canal and injectate (INJ) spread around the contents of the inguinal canal (white arrows)

Lateral cutaneous nerve of thigh injection for meralgia paresthetica

Meralgia paresthetica is a pain or paresthesia causing condition in the lateral aspect of the thigh due to entrapment neuropathy of the lateral cutaneous nerve of thigh.^[46,47] Recently, wearing low-cut tight trousers has emerged as a risk factor for developing this condition.^[48] The diagnosis is clinical and is based on classical distribution of symptoms and typical exacerbating factors.^[49] The usual site of compression is at the lateral aspect of the inguinal region just medial to the anterior superior iliac spine.^[50] Ultrasound-guided injection has been shown to cause long-lasting relief of symptoms, and ultrasound increases success of injection due to variability of the nerve course.^[50,51] Studies have shown complete pain relief till 2–4 months of follow-up,^[50,52] and in our experience, we have seen pain relief lasting till 1 year of follow-up.

Ultrasonographic nerve localization and injection technique

With the patient in supine position, a linear ultrasound probe is placed on the inguinal crease with the lateral end of the probe over the anterior superior iliac spine and slowly slid inferiorly. The lateral cutaneous nerve of thigh is seen due to its characteristic cross-sectional echotexture within 2 cm below the anterior superior iliac spine superficial to the sartorius muscle; or lateral to the sartorius muscle further downward [Figure 5A]. For confirmation, the nerve can be traced caudally to demonstrate its lateral-ward course and branching. Using in-plane technique, a solution of 4 ml of

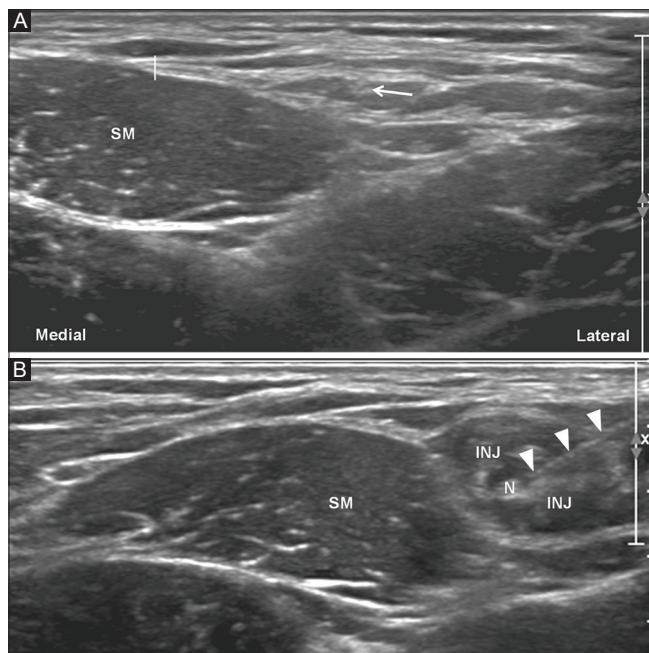


Figure 5 (A and B): (A) Ultrasound transverse image with the probe kept approximately 4–5 cm below the anterior superior iliac spine in the lateral part of the upper thigh showing the sartorius muscle (SM) and the lateral cutaneous nerve of thigh (white arrow) lateral to the muscle. (B) Ultrasound image showing a needle (white arrowheads) placed with its tip close to the lateral cutaneous nerve of thigh (N) and injectate (INJ) spread around the nerve. Sartorius muscle is shown (SM)

0.5 bupivacaine and 1 ml of 40 mg methyl prednisolone acetate is injected around the nerve [Figure 5B].

Stellate ganglion block

Stellate ganglion is the fused lower cervical and upper thoracic sympathetic ganglion present in about 80% of population.^[53] Blockage of stellate ganglion is performed for a variety of sympathetically mediated pain conditions such as complex regional pain syndrome, herpes zoster associated cervicofacial pain, ischemic neuropathies, and ischemic vascular diseases of upper limb, and phantom limb, among others.^[53,54] There is risk of development of different complications such as hoarseness (due to recurrent laryngeal nerve block), Horner's syndrome, vascular injury causing hematomas, brachial plexus blockage, phrenic nerve block or injury, esophageal injury, and seizures due to intravascular injection (especially vertebral artery).^[55,56] Various methods including blind, fluoroscopy-guided, and ultrasound-guided techniques have been described; ultrasound guidance is considered safest and more effective due to accurate localization of injection and demonstration of various anatomic variations (e.g. thickness of longus colli muscle, variability in phrenic nerve course, variability in the course of vertebral artery and esophagus, presence of an asymptomatic Zenker's diverticulum, etc.).^[57,58] The effect of injection (using bupivacaine) lasts anywhere between 1 week and more than 2 months.

Ultrasonographic localization and injection technique

The patient is placed in supine position with head turned to the opposite site. Linear ultrasound transducer is placed over the lower part of the neck in transverse orientation to visualize the C6 and C7 transverse process. C7 transverse process is identified by the absence of a prominent anterior tubercle, which is found in transverse process of C6 [Figure 6A and B]. The longus colli, anterior scalene muscles, internal carotid, and vertebral arteries are identified. The sympathetic ganglion lies deep to the prevertebral fascia and superficial to the longus colli muscle [Figure 6B].^[54,57,59] A 1.5-inch 22G needle is inserted from lateral approach through the scalenus anterior muscle, tip is placed over the longus colli muscle, and solution of 4 ml 0.5% bupivacaine and 40 mg of triamcinolone is injected just superficial to the longus colli muscles [Figure 6C]. Care is taken not to injure the phrenic nerve or brachial plexus. Patient is clinically evaluated for Horner's syndrome to confirm stellate ganglion block.

Saphenous nerve block for chronic knee pain

Chronic knee pain is an exceedingly common condition and affects a staggering 25% of people over 55 years of age.^[60] Degenerative joint disease is the most common cause accounting for 70% of chronic knee pain in the elderly. Saphenous nerve is a pure sensory branch of the femoral nerve, and carries cutaneous sensation from the medial aspect of knee, leg, and the foot. Saphenous nerve has

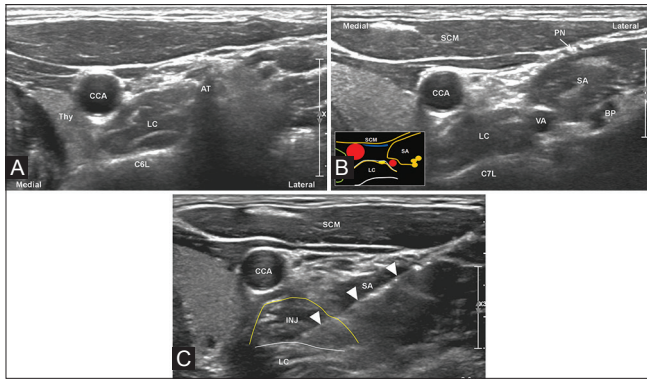


Figure 6 (A-C): (A) Transverse ultrasound image of the lower neck at the level of C6 showing the C6 lamina (C6L) bearing a prominent anterior tubercle (AT). Common carotid artery (CCA), thyroid gland (Thy) and longus colli muscle (LC) are shown. (B) Transverse ultrasound image of the lower neck at the level of C7 showing the C7 lamina (C7L), longus colli muscle (LC) over the lamina, common carotid artery (CCA), vertebral artery (VA), sternocleidomastoid muscle (SCM), scalenus anterior muscle (SA), phrenic nerve (PN) along the anterior surface of scalenus anterior muscle and brachial plexus (BP) posterolateral to the scalenus anterior muscle. Inset: Schematic diagram showing the position of the stellate ganglion (yellow oval) deep to the prevertebral fascia (blue line) lying on the longus colli muscle (LC); also shown are muscles with similar annotation as the sonographic image, brachial plexus as orange discs, carotid and vertebral arteries as red discs, compressed jugular vein as a blue structure, and thyroid outlined by the green line. (C) Ultrasound image during stellate ganglion block showing a needle (white arrowheads) placed with its tip just superficial to the longus colli (LC) muscle, and injectate (INJ) expanding the space between the anterior border of the longus colli muscle (marked by a white line) and the prevertebral fascia (marked by a yellow line). Common carotid artery (CCA), scalenus anterior (SA) muscle and sternocleidomastoid muscle (SCM) are shown

been shown to supply the anteromedial aspect of the knee joint, and ultrasound-guided saphenous nerve block in the adductor canal has been shown to cause significant relief in chronic knee pain, lasting from less than a month to as much as more than 4 years.^[61,62] Adductor canal block is more effective than saphenous block performed near the knee joint because subsartorial canal injectate also blocks the medial branch of the anterior femoral cutaneous nerve.^[62] With pain relief, adequate physiotherapy and limb-strengthening exercises can be carried out, which is probably the cause for better functional status and prolonged decrease in pain.

Ultrasonographic nerve localization and injection technique

With the patient in supine position with leg kept externally rotated, a linear transducer is placed in the medial mid-thigh and the femoral vessels are identified in the adductor canal (deep to the sartorius muscle) [Figure 7A]. The saphenous nerve can be seen as a small hyperechoic structure anteromedial to the femoral artery either within the adductor canal or in between the sartorius muscle and the vastus medialis muscle [Figure 7A]. Using in-plane technique, a solution of 4 ml 0.5% bupivacaine and 40 mg triamcinolone or methyl prednisolone acetate is injected around the nerve within the adductor canal [Figure 7B].

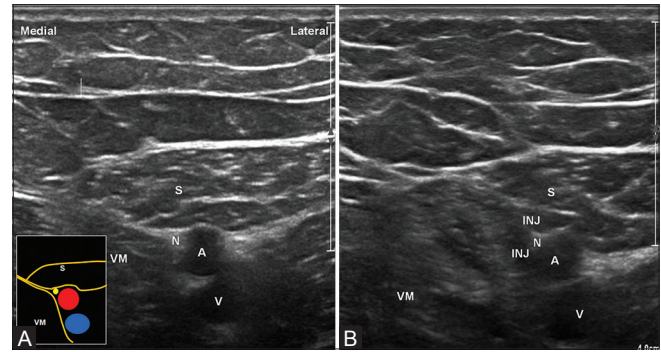


Figure 7 (A and B): (A) Transverse ultrasound image showing femoral artery (A) and femoral vein (V) in the adductor canal deep to the sartorius muscle (S), and saphenous nerve (N) anteromedial and close to the femoral artery. Vastus medialis muscle (VM) is also shown. Inset: Schematic diagram showing anatomical relation of the saphenous nerve (yellow disc) to the femoral artery and vein (red and blue discs), all these structures lying the subsartorial canal underneath the sartorius muscle (S). (B) Ultrasound image after saphenous nerve block showing injectate (INJ) around the saphenous nerve (N). Femoral artery (A) and vein (V), sartorius (S) and vastus medialis (VM) muscles are shown

Intercostal nerve block for postherpetic neuralgia

Intercostal nerve blocks are commonly performed by anesthesiologists for procedural analgesia during chest wall surgeries. Postherpetic neuralgia is the most common nonoperative anesthetic indication for intercostals nerve block. Post herpetic neuralgia affects as much as one-fifth of adults over 50 years affected with herpes zoster.^[63,64] It commonly affects the thoracic dermatomes, and pain and allodnia resistant to medical treatment respond well to intercostal nerve block.^[65] The analgesia is, however, short-lived, lasting from 1–3 days and has to be repeated 3–10 times to see a prolonged response, and the patient should be counselled regarding this before starting the course of nerve blocks. The number of repetitions depend on the clinical response, and should be repeated once after attaining adequate clinical response.^[64] Performing the block without imaging guidance is effective but there is possibility of pneumothorax.^[64,66] Ultrasound shows the layers of intercostals muscles and pleura and the approximate site of the intercostals nerve clearly; thereby, a pneumothorax could be prevented.

Ultrasonographic nerve site localization and injection technique

The area of pain is mapped and the corresponding dermatomes and associated intercostal nerves responsible for pain are determined. The patient is placed in prone position on a couch with the upper limbs hanging on either side of the couch; this rotates the scapula externally and displaces it laterally. A linear transducer is placed in a parasagittal oblique position perpendicular to the ribs approximately 6 cm from the midline. Ribs and intercostals spaces can be seen [Figure 8]. At this level in the intercostals space, there is only a single muscle plane – the external intercostal muscle, deep to which lies the pleura, which appears hyperechoic and slides with respiration. The intercostal nerve lies deep to the muscle layer at the inferior

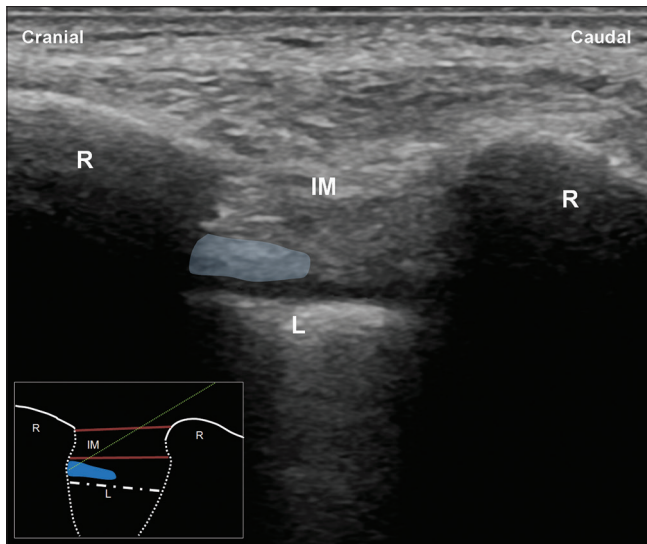


Figure 8: Ultrasound image of an intercostal space with probe kept at right angles to the ribs showing ribs (R) with their post acoustic shadowing, intercostal muscle (IM), and pleural hyperechogenicity (L) with comet tail artifacts. The area marked by the translucent blue oval deep to the intercostal muscles and superficial to the pleural line indicates plane of the intercostal neurovascular bundle and the target site for injection. Inset: Schematic diagram showing ribs (R), intercostal muscle (IM) and pleural line (white dot and dash line); also shown is the ideal needle pathway (green dotted line) and the target site for injection (blue region)

border of the rib. Using in-plane technique, a 22G needle is placed through the muscle, and as soon as the needle tip crosses the muscle, 2–4 ml of 0.5% bupivacaine and 40 mg triamcinolone or methyl prednisolone acetate is injected; care is taken not to puncture the pleura.

Conclusion

Various painful clinical conditions can be treated with perineural injections of combinations of anesthetic agents and steroids around pain causing or pain transmitting nerves. Ultrasound is best suited for most of these peripheral nerve-related pain interventions, underpinned by its superior spatial resolution, and ability to show the course of inserted needles and distribution of injectate in real time; conferring high-procedure success and least complication rates.

Financial support and sponsorship
Nil.

Conflicts of interest

There are no conflicts of interest.

References

- Lawande AD, Warriar SS, Joshi MS. Role of ultrasound in evaluation of peripheral nerves. *Indian J Radiol Imaging* 2014;24:254-8.
- Daftary AR, Karnik AS. Perspectives in ultrasound-guided musculoskeletal interventions. *Indian J Radiol Imaging* 2015;25:246-60.
- Soneji N, Peng PW. Ultrasound-guided pain interventions – a review of techniques for peripheral nerves. *Korean J Pain* 2013;26:111-24.
- Khedkar SM, Bhalerao PM, Yemul-Golhar SR, Kelkar KV. Ultrasound-guided ilioinguinal and iliohypogastric nerve block, a comparison with the conventional technique: An observational study. *Saudi J Anaesth* 2015;9:293-7.
- Trescot AM. Cryoanalgesia in interventional pain management. *Pain Physician* 2003;6:345-60.
- Kim CH, Hu W, Gao J, Dragan K, Whealton T, Julian C. Cryoablation for the treatment of occipital neuralgia. *Pain Physician* 2015;18:E363-8.
- Friedman T, Richman D, Adler R. Sonographically guided cryoneurolysis preliminary experience and clinical outcomes. <http://draliafriedman.com/wp-content/themes/johndoe-theme/cryo1.pdf>. [Last accessed on 2017 Aug 06].
- Mittal S, Safarpour D, Jabbari B. Botulinum toxin treatment of neuropathic pain. *Semin Neurol* 2016;36:73-83.
- Fabregat G, De Andrés J, Villanueva-Pérez VL, Asensio-Samper JM. Subcutaneous and perineural botulinum toxin Type A for neuropathic pain. *Clin J Pain* 2013;29:1006-12.
- Padua L, Coraci D, Erra C, Pazzaglia C, Loreti C, Paolasso I, *et al.* Carpal tunnel syndrome: Clinical features, diagnosis, and management. *Lancet Neurol* 2016;15:1273-84.
- Aroori S, Spence RA. Carpal tunnel syndrome. *Ulster Med J* 2008;77:6-17.
- Chen CH, Wu T, Sun JS, Lin WH, Chen CY. Unusual causes of carpal tunnel syndrome: Space occupying lesions. *J Hand Surg Eur Vol* 2012;37:14-9.
- Kang HJ, Jung SH, Yoon HK, Hahn SB, Kim SJ. Carpal tunnel syndrome caused by space occupying lesions. *Yonsei Med J* 2009;50:257-61.
- Bland JD. Carpal tunnel syndrome. *Curr Opin Neurol* 2005;18:581-5.
- Pulikkottil BJ, Schub M, Kadow TR, Wang W, Fowler JR. Correlating median nerve cross-sectional area with nerve conduction studies. *J Hand Surg Am* 2016;41:958-62.
- Walker FO, Cartwright MS, Blocker JN, Arcury TA, Suk JJ, Mora DC, *et al.* Prevalence of bifid median nerves and persistent median arteries and their association with carpal tunnel syndrome in a sample of Latino poultry processors and other manual workers. *Muscle Nerve* 2013;48:539-44.
- Kachlik D, Konarik M, Riedlova J, Baca V. Brachiomedian artery (arteria brachioamericana) revisited: A comprehensive review. *Bosn J Basic Med Sci* 2016;16:91-101.
- Evers S, Bryan AJ, Sanders TL, Selles RW, Gelfman R, Amadio PC. The Effectiveness of ultrasound-guided compared to blind steroid injections in the treatment of carpal tunnel syndrome. *Arthritis Care Res (Hoboken)* 2017;69:1060-5.
- Menge TJ, Rinker EB, Fan KH, Block JJ, Lee DH. Carpal tunnel injections: A novel approach based on wrist width. *J Hand Microsurg* 2016;8:21-6.
- Page MJ, Massy-Westropp N, O'Connor D, Pitt V. Splinting for carpal tunnel syndrome. *Cochrane Database Syst Rev* 2012;7:CD010003.
- Gurcay AG, Karaahmet OZ, Gurcan O, Kazanci A, Karsli PB, Umay EK, *et al.* Comparison of short-term clinical and electrophysiological outcomes of local steroid injection and surgical decompression in the treatment of carpal tunnel syndrome. *Turk Neurosurg* 2017;27:447-52.
- Khosrawi S, Emadi M, Mahmoodian AE. Effectiveness of splinting and splinting plus local steroid injection in severe carpal tunnel syndrome: A randomized control clinical trial. *Adv Biomed Res* 2016;5:16.
- Nwawka OK, Miller TT, Jawetz ST, Saboeiro GR. Ultrasound-guided perineural injection for nerve blockade: Does a single-sided injection produce circumferential nerve coverage? *J Clin Ultrasound* 2016;44:465-9.

24. Fernandes MR, Barbosa MA, Sousa AL, Ramos GC. Suprascapular nerve block: Important procedure in clinical practice. *Rev Bras Anesthesiol* 2012;62:96-104.
25. Harmon D, Hearty C. Ultrasound-guided suprascapular nerve block technique. *Pain Physician* 2007;10:743-6.
26. Messina C, Banfi G, Orlandi D, Lacelli F, Serafini G, Mauri G, *et al.* Ultrasound-guided interventional procedures around the shoulder. *Br J Radiol* 2016;89:20150372.
27. Ozkan K, Ozcekcic AN, Sarar S, Cift H, Ozkan FU, Unay K. Suprascapular nerve block for the treatment of frozen shoulder. *Saudi J Anaesth* 2012;6:52-5.
28. Simopoulos TT, Nagda J, Aner MM. Percutaneous radiofrequency lesioning of the suprascapular nerve for the management of chronic shoulder pain: A case series. *J Pain Res* 2012;5:91-7.
29. Kane TP, Rogers P, Hazelgrove J, Wimsey S, Harper GD. Pulsed radiofrequency applied to the suprascapular nerve in painful cuff tear arthropathy. *J Shoulder Elbow Surg* 17:436-40.
30. Ward JB. Greater occipital nerve block. *Semin Neurol* 2003;23:59-62.
31. Choi I, Jeon SR. Neuralgias of the head: Occipital neuralgia. *J Korean Med Sci* 2016;31:479-88.
32. Cuadrado ML, Aledo-Serrano Á, Navarro P, Gonzalez-Suarez I, Orviz A, Fernandez-Perez C, *et al.* Short-term effects of greater occipital nerve blocks in chronic migraine: A double-blind, randomised, placebo-controlled clinical trial. *Cephalalgia* 2017;9:864-72.
33. Akyol F, Binici O, Kuyruklyildiz U, Karabakan G. Ultrasound-guided bilateral greater occipital nerve block for the treatment of post-dural puncture headache. *Pakistan J Med Sci* 31:111-5.
34. Koçer A. Greater occipital nerve blocks in the treatment of refractory chronic migraine: An observational report of nine cases. *World J Clin cases* 2016;4:323-7.
35. Piovesan EJ, Kowacs PA, Tatsui CE, Lange MC, Ribas LC, Werneck LC. Referred pain after painful stimulation of the greater occipital nerve in humans: Evidence of convergence of cervical afferences on trigeminal nuclei. *Cephalalgia* 2001;21:107-9.
36. Greher M, Moriggl B, Curatolo M, Kirchmair L, Eichenberger U. Sonographic visualization and ultrasound-guided blockade of the greater occipital nerve: A comparison of two selective techniques confirmed by anatomical dissection. *Br J Anaesth* 2010;104:637-42.
37. Palamar D, Uluduz D, Saip S, Erden G, Unalan H, Akarimak U. Ultrasound-guided greater occipital nerve block: An efficient technique in chronic refractory migraine without aura? *Pain Physician* 2015;18:153-62.
38. Zipfel J, Kastler A, Tatu L, Behr J, Kechidi R, Kastler B. Ultrasound-guided intermediate site greater occipital nerve infiltration: A technical feasibility study. *Pain Physician* 2016;19:E1027-34.
39. Hakeem A, Shanmugam V. Inguinodynia following Lichtenstein tension-free hernia repair: A review. *World J Gastroenterol* 2011;17:1791-6.
40. Khan JS, Rai A, Sundara Rajan R, Jackson TD, Bhatia A. A scoping review of perineural steroids for the treatment of chronic postoperative inguinal pain. *Hernia* 2016;20:367-76.
41. Acar F, Ozdemir M, Bayrakli F, Cirak B, Coskun E, Burchiel K. Management of medically intractable genitofemoral and ilioinguinal neuralgia. *Turk Neurosurg* 2013;23:753-7.
42. Terkawi AS, Romdhane K. Ultrasound-guided pulsed radiofrequency ablation of the genital branch of the genitofemoral nerve for treatment of intractable orchialgia. *Saudi J Anaesth* 2014;8:294-8.
43. Demirci A, Efe EM, Türker G, Gurbet A, Kaya FN, Anil A, *et al.* Iliohypogastric/ilioinguinal nerve block in inguinal hernia repair for postoperative pain management: Comparison of the anatomical landmark and ultrasound guided techniques. *Rev Bras Anesthesiol* 64:350-6.
44. Shanthanna H. Successful treatment of genitofemoral neuralgia using ultrasound guided injection: A case report and short review of literature. *Case Rep Anesthesiol* 2014;2014:371703.
45. Gofeld M, Christakis M. Sonographically guided ilioinguinal nerve block. *J Ultrasound Med* 2006;25:1571-5.
46. Patijn J, Mekhail N, Hayek S, Lataster A, van Kleef M, Van Zundert J. Meralgia Paresthetica. *Pain Pract* 2011;11:302-8.
47. Son BC, Kim DR, Kim IS, Hong JT, Sung JH, Lee SW. Neurolysis for meralgia paresthetica. *J Korean Neurosurg Soc* 2012;51:363-6.
48. Moucharafieh R, Wehbe J, Maalouf G. Meralgia paresthetica: A result of tight new trendy low cut trousers ('taille basse'). *Int J Surg* 2008;6:164-8.
49. Grossman MG, Ducey SA, Nadler SS, Levy AS. Meralgia paresthetica: Diagnosis and treatment. *J Am Acad Orthop Surg* 9:336-44.
50. Tagliafico A, Serafini G, Lacelli F, Perrone N, Valsania V, Martinoli C. Ultrasound-guided treatment of meralgia paresthetica (lateral femoral cutaneous neuropathy): Technical description and results of treatment in 20 consecutive patients. *J Ultrasound Med* 2011;30:1341-6.
51. Hurdle MF, Weingarten TN, Crisostomo RA, Psimos C, Smith J. Ultrasound-guided blockade of the lateral femoral cutaneous nerve: Technical description and review of 10 cases. *Arch Phys Med Rehabil* 2007;88:1362-4.
52. Kim JE, Lee SG, Kim EJ, Min BW, Ban JS, Lee JH. Ultrasound-guided lateral femoral cutaneous nerve block in meralgia paresthetica. *Korean J Pain* 2011;24:115-8.
53. Elias M, Elias M. Association of pain management anesthesiologists @ Cervical sympathetic and stellate ganglion blocks. *Pain Physician* 2000;3:294-304.
54. Kulkarni R. Ultrasound-guided Stellate Ganglion Block. *Journal on Recent Advances in Pain* 2016;2:22-4.
55. Serna-Gutiérrez J. Ultrasound-guided stellate ganglion block. *Colomb J Anesthesiol* 2015;43:278-82.
56. Ojeda A, Sala-Blanch X, Moreno LA, Busquets C. Ultrasound-guided stellate ganglion block: What about the phrenic nerve? *Reg Anesth Pain Med* 2013;38:170.
57. Narouze S. Ultrasound-guided stellate ganglion block: Safety and efficacy. *Curr Pain Headache Rep* 2014;18:424.
58. Ghai A, Kaushik T, Kundu ZS, Wadhwa S, Wadhwa R. Evaluation of new approach to ultrasound guided stellate ganglion block. *Saudi J Anaesth* 2016;10:161-7.
59. Gofeld M, Bhatia A, Abbas S, Ganapathy S, Johnson M. Development and validation of a new technique for ultrasound-guided stellate ganglion block. *Reg Anesth Pain Med* 34:475-9.
60. Mallen CD, Peat G, Porcheret M. Chronic knee pain. *BMJ* 2007;335:303.
61. Burckett-St Laurant D, Peng P, Girón Arango L, Niazi AU, Agur A, Perlas A, *et al.* The nerves of the adductor canal and the innervation of the knee: An anatomic study. *Reg Anesth Pain Med* 41:321-7.
62. Harshe R. Prolonged knee pain relief by saphenous block (new technique). *Indian J Pain* 2013;27:36.
63. Johnson RW, McElhaney J. Postherpetic neuralgia in the elderly. *Int J Clin Pract* 2009;63:1386-91.
64. Malec-Milewska M, Sękowska A, Kołęda I, Horosz B, Guć M, Jastrzębski J. Sympathetic nerve blocks for the management of postherpetic neuralgia – 19 years of pain clinic experience. *Anesthesiol Intensive Ther* 2014;46:255-61.
65. Chau SW, Soo LY, Lu DV, Chen TI, Cheng KI, Chu KS. Clinical experience of pain treatment for postherpetic neuralgia in elderly patients. *Acta Anaesthesiol Taiwan* 2007;45:95-101.
66. Moore DC, Bridenbaugh LD. Pneumothorax. Its incidence following intercostal nerve block. *JAMA* 1962;182:24-32.