

Shellfish allergy–induced overlap chronic graft-versus-host disease



Hayley Anne Braun, MD, MPH,^a and Justin Cheeley, MD^{a,b}
Atlanta, Georgia

Key words: allergy; graft-versus-host disease; shellfish; stem cell transplant.

INTRODUCTION

Graft-versus-host disease (GVHD) is a complication of allogeneic hematopoietic stem cell transplantation (SCT) and is categorized into acute and chronic forms. The pathophysiology of acute graft-versus-host disease (aGVHD) is believed to include tissue damage, antigen-presenting cell activation, antigen-presenting cell presentation to donor T cells, and donor T cells–triggered inflammatory response from innate and adaptive immune cells.¹ Chronic graft-versus-host disease (cGVHD) is less well understood but believed to include similar T cell activation, immune dysregulation, and inability to maintain tolerance.² In some instances, both acute and chronic components may coexist, now termed overlap chronic graft-versus-host disease (ocGVHD).²

Allergy-induced GVHD has been reported but is not well understood. Exposure of hematopoietic SCT recipients to donor allergenic drugs has been reported to precede the development of GVHD and may incite tissue damage and T cell activation.³ One study of donor allergenic drug exposure 60 days after transplantation found 2 cases of diagnosed and 1 case of suspected aGVHD.³ In another study, dog-dander hypersensitivity was reported in an unrelated hematopoietic transplant recipient 20 months after transplantation, even with repeated exposure to dogs in the preceding months.⁴ Interestingly, the donor was allergic to nuts as well as dander from cats and dogs, whereas the recipient displayed symptoms of hypersensitivity only to dog dander. In this report, we describe a case of shellfish allergy–induced ocGVHD.

Abbreviations used:

aGVHD:	acute graft-versus-host disease
BSA:	body surface area
cGVHD:	chronic graft-versus-host disease
GVHD:	graft-versus-host disease
ocGVHD:	overlap chronic graft-versus-host disease
SCT:	stem cell transplantation

CASE REPORT

A man in his 50s with a history of JAK2⁺ essential thrombosis and subsequent myelofibrosis presented with a complaint of throat pain 5 months after 10/10–matched related donor peripheral blood SCT. The patient's SCT was conditioned with busulfan/flucytosine and followed by tacrolimus for GVHD prophylaxis. Post-100-day transplant chimerism studies showed increasing donor T cell chimerism and full myeloid engraftment. No signs or symptoms of GVHD were present 130 days after transplantation.

Seven days prior to presentation, facial and oral edema developed in the patient hours after shellfish consumption. The patient had no history of shellfish allergy, whereas the donor had a known shellfish hypersensitivity. A pruritic exanthem on the chest, back, legs, and palms rapidly manifested thereafter, followed by conjunctival injection and lip peeling. Diphenhydramine and methylprednisolone from an outside facility provided little relief. Oral tacrolimus had been tapered by 0.5 mg daily 3 weeks ago; otherwise, no medication changes had been made. A review of systems was significant for anorexia, mild

From the Department of Dermatology^a and Department of General Medicine and Geriatrics, Emory University School of Medicine, Atlanta.^b

Funding sources: None.

IRB approval status: Not applicable.

Correspondence to: Justin Cheeley, MD, Department of Dermatology, Emory University School of Medicine, 1525 Clifton Road NE, Ste 100, Atlanta, GA 30323. E-mail: justin.cheeley@emory.edu.

JAAD Case Reports 2021;17:100-2.
2352-5126

© 2021 by the American Academy of Dermatology, Inc. Published by Elsevier, Inc. This is an open access article under the CC BY-NC-ND license (<http://creativecommons.org/licenses/by-nc-nd/4.0/>).

<https://doi.org/10.1016/j.jidcr.2021.08.036>

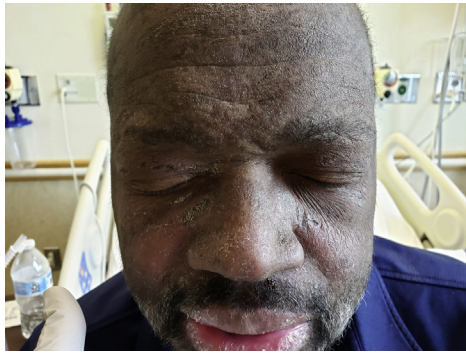

Fig 1. Overlap chronic graft-versus-host disease. Facial edema with dusky, reticulate patches and exfoliative scale.

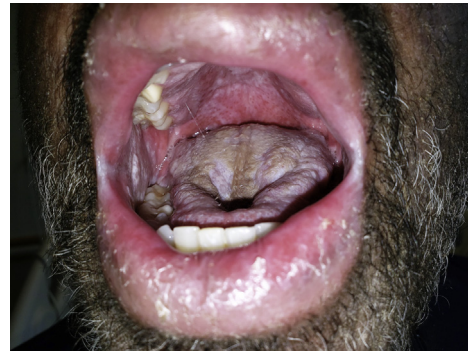

Fig 2. Overlap chronic graft-versus-host disease. Edema and crusted erosions of the vermilion lip with white patches on the palate and buccal mucosa.

dysphagia, rhinorrhea, and intermittent cough and negative for nausea, vomiting, diarrhea, and dysuria.

Examination showed facial edema, erythema, gray-brown patches, eyelid erythema, bilateral conjunctival injection, and crusted erosions on the vermilion lips (Fig 1). Scattered oral erosions, lacy white patches along the palate and buccal mucosa, and petechiae of the posterior aspect of the oropharynx were noted (Fig 2). A diffuse, superficial scale was present on the face, ears, chest, back, abdomen, arms, and legs. Dusky oval and reticular macules with a predilection for skin folds covered the chest, trunk, upper portion of the abdomen, and the proximal portion of arms with underlying erythema. Scattered dusky, hyperpigmented perifollicular macules extended along the distal portions of arms and legs bilaterally. Dyshidrosiform papules with underlying erythema were noted on bilateral mid palms. Total body surface area (BSA) involvement approximated 20%.

Laboratory workup was notable for elevated levels of peripheral eosinophils (32%), elevated liver function tests (aspartate aminotransferase: 99 IU/L [normal range, 13-39 IU/L]; alanine aminotransferase: 142 IU/L [normal range, 7-52 IU/L]), a low serum tacrolimus level (<2 ng/mL; normal range, 8-18 ng/mL), and negative findings of viral respiratory polymerase chain reaction (including SARS-CoV-2). Findings of blood cultures, urinalysis, and chest x-ray were negative or normal. A punch biopsy of the skin obtained from the left flank showed vacuolar interface dermatitis (Fig 3). A diagnosis of ocGVHD was made based on clinicopathologic features. The tacrolimus dosage was increased; prednisone was initiated at 1 mg/kg; and topical corticosteroid ointments as well as oral rinses, calcineurin inhibitor ointments, topical analgesics, and artificial tears were administered for symptom management.

Five months later, the dermatology department was reconsulted for management of the worsening clinical disease. Bone marrow transplant team assessment of current cGVHD included known eye, skin, and mouth involvement and suspected liver involvement. The current GVHD regimen included sirolimus 2 mg (switched from tacrolimus, given the kidney injury), ruxolitinib 5 mg (reduced, given cytopenias and infection), and rituximab. On examination, the patient had approximately 80% BSA involvement of poikilodermatous scaly plaques (Fig 4). Oral involvement included lip edema with pseudomembranes and crusted erosions present over the lips, gingival mucosa, and tongue. Genital involvement included penile edema with heme-crusted erosions of the glans and shaft.

DISCUSSION

Classic cutaneous aGVHD commonly presents with discrete erythematous or dusky macules and papules, which may coalesce and progress to erythroderma with toxic epidermal necrolysis-like bullae and erosions.⁵ Other symptoms include nausea, vomiting, anorexia, profuse diarrhea, ileus, or cholestatic disease. aGVHD is staged by BSA of rash, bilirubin level, and volume of diarrhea, whereas cGVHD requires at least 1 diagnostic manifestation in the skin, mouth, gastrointestinal tract, lung, fascia, or genitalia or “distinctive” manifestation confirmed by testing (ie, biopsy suggestive of GVHD).^{6,7} Peripheral eosinophilia has been reported in cGVHD.²

Although alternative processes such as drug reaction with eosinophilia and systemic symptoms may have overlapping features of ocGVHD, drug reaction with eosinophilia and systemic symptoms is less clinically compelling. The lack of preceding new medication or iodinated contrast makes drug reaction with eosinophilia and systemic symptoms unlikely. The onset of symptoms shortly following

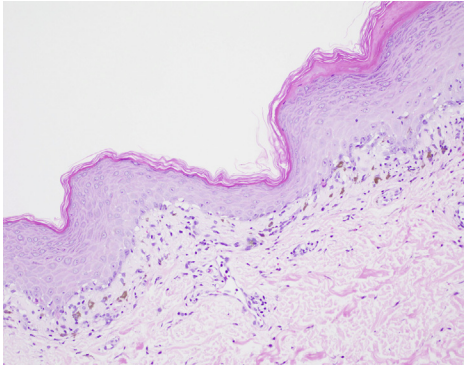


Fig 3. Overlap chronic graft-versus-host disease. Vacuolar interface alteration with pigment incontinence. (Hematoxylin-eosin stain; original magnification: $\times 120$.)

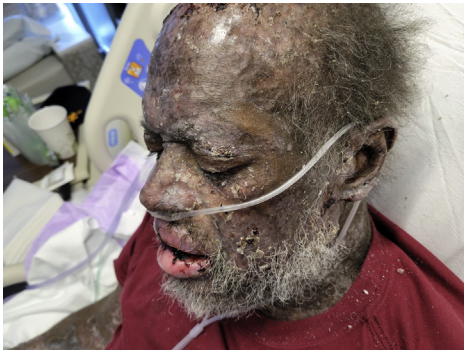

Fig 4. Overlap chronic graft-versus-host disease. Poikilodermatous, scaly, and eroded patches and plaques on the face with heme-crusted stomatitis 5 months after the initial presentation.

shellfish consumption, full donor myeloid engraftment, and tapered tacrolimus dosage support GVHD. Progressive oral and genital disease and extensive BSA involvement of poikilodermatous plaques support the diagnosis of ocGVHD.

In our patient, erythema, dusky hyperpigmentation secondary to interface alteration, elevated liver function tests, and anorexia were suggestive of aGVHD. An initial papulosquamous eruption followed by genital erosions (both distinctive cGVHD findings), subsequent poikilodermatous

changes (diagnostic cGVHD finding), and peripheral eosinophilia support a cGVHD component. The uncommon trigger of shellfish allergy could contribute to the overlapping presentation if the acute component arose later than expected because T cell activation was not triggered by human leukocyte antigen discrepancies between donor and recipient but, rather, by food hypersensitivity. Further study into the pathomechanisms behind donor-derived food-, medication-, or environmental hypersensitivity-induced GVHD is needed. Clinicians may recommend empirical avoidance of known donor allergens in SCT recipients.

Conflicts of interest

None disclosed.

REFERENCES

- Ghimire S, Weber D, Mavin E, Wang XN, Dickinson AM, Holler E. Pathophysiology of GvHD and other HSCT-related major complications. *Front Immunol*. 2017;8:79. <https://doi.org/10.3389/fimmu.2017.00079>
- Cromvik J, Johnsson M, Vaht K, Johansson JE, Wennerås C. Eosinophils in the blood of hematopoietic stem cell transplanted patients are activated and have different molecular marker profiles in acute and chronic graft-versus-host disease. *Immun Inflamm Dis*. 2014;2(2):99-113. <https://doi.org/10.1002/iid3.25>
- Gordon J, Damstetter E, Nardone B, Mehta J, West DP, Cotliar J. Drug allergy in haematopoietic stem cell transplantation. *Allergol Immunopathol (Madr)*. 2014;42(4):375-377. <https://doi.org/10.1016/j.aller.2013.01.006>
- Storek J, Vliagoftis H, Grizel A, et al. Allergy transfer with hematopoietic cell transplantation from an unrelated donor. *Bone Marrow Transplant*. 2011;46(4):605-606. <https://doi.org/10.1038/bmt.2010.150>
- Martires KJ, Cowen EW. Graft-versus-host disease. In: Kang S, Amagai M, Bruckner AL, et al., eds. *Fitzpatrick's Dermatology*. 9th ed. McGraw-Hill Education; 2019.
- Lee SJ. Classification systems for chronic graft-versus-host disease. *Blood*. 2017;129(1):30-37. <https://doi.org/10.1182/blood-2016-07-686642>
- Jagasia MH, Greinix HT, Arora M, et al. National Institutes of Health consensus development project on criteria for clinical trials in chronic graft-versus-host disease: I. The 2014 Diagnosis and Staging Working Group report. *Biol Blood Marrow Transplant*. 2015;21(3):389-401.e1. <https://doi.org/10.1016/j.bbmt.2014.12.001>