

## Cesarean section scar dehiscence during pregnancy: Case reports

Ibrahim A. Abdelazim<sup>1,2</sup>, Svetlana Shikanova<sup>3</sup>, Sakiyeva Kanshaiym<sup>3</sup>, Bakyt Karimova<sup>3</sup>, Mukhit Sarsembayev<sup>3</sup>, Tatyana Starchenko<sup>3</sup>

<sup>1</sup>Department of Obstetrics and Gynecology, Ahmadi Hospital, Kuwait Oil Company, Ahmadi, Kuwait, <sup>2</sup>Department of Obstetrics and Gynecology, Ain Shams University, Cairo, Egypt, <sup>3</sup>Department of Obstetrics and Gynecology №1, Marat Ospanov, West Kazakhstan State Medical University, Aktobe, Kazakhstan

### ABSTRACT

**Background:** The incidence of cesarean section increased worldwide with subsequent increase in the risk of cesarean section scar dehiscence (CSSD). The clinical significance and the management of the CSSD are still unclear. **Case Reports:** Here, we report two cases of CSSD. A 35-year-old woman, gravida 2, previous CS, due to preterm premature rupture of membranes (PPROM) and breech presentation at 30 weeks, was admitted for elective CS at 38<sup>+3d</sup> weeks' gestation. During the second elective CS, it was seen that the site of the previous CS scar was very thin along its whole length and the anterior uterine wall was completely deficient, leaving visible bulging fetal membranes and moving baby underneath. A 32-year-old woman, previous three CSs, was admitted as unbooked case without any antenatal records at 29<sup>+4d</sup> weeks' gestation, triplet pregnancy with preterm labor. She received betamethasone and magnesium sulfate (MgSO<sub>4</sub>) for fetal lung and fetal brain protection, respectively, followed by emergency CS. During the CS, the previous CS scars were dehiscent over more than half of its length and the anterior uterine wall was missing leaving visible fetal membranes. The uterine incision of the studied women was repaired in two layers using vicryl 0 interrupted simple stitches for the first layer, followed by interrupted mattress stitches for the second layer. The studied women had uneventful postoperative recovery and were discharged from the hospital after counseling regarding intraoperative findings, uterine incisions repair, and future pregnancies. **Conclusion:** It is useful to assess the lower uterine segment of women with previous CS using the available ultrasound facilities. If the CSSD is diagnosed before the elective CS, the surgeon should prepare himself with the safest uterine incision with least possible complications and the best way of repair of the defective or dehiscent uterine wall.

**Keywords:** Cesarean, dehiscence, pregnancy, reports, scar

### Introduction

The incidence of cesarean sections (CSs) has increased worldwide. For example, the incidence of CSs in the United States increased from 5.0% in 1970 to 32.9% in 2009.<sup>[1]</sup> One of the most important complications of cesarean deliveries is cesarean section scar dehiscence (CSSD), in which the scar tissue of the previous CS is disrupted and separated.<sup>[2]</sup>

The reported incidence of the CSSD ranges from 0.2% to 4.3%.<sup>[1,2]</sup> Previous CSSD is a well-known risk factor for uterine rupture during trial of labor (TOL) in subsequent pregnancy.<sup>[2]</sup> However, the clinical significance of CSSD in cases of repeated CS remains unclear. In addition, an appropriate screening method for such cases and the best surgical approach for repairing CSSD during delivery does not exist or has not been established.<sup>[1,2]</sup>

Obstetricians often encounter CSSD during elective CSs. However, the extension of the CSSD to involve half or whole of the previous CS scar is rare, and it will be seen what will be

**Address for correspondence:** Prof. Ibrahim A. Abdelazim, Department of Obstetrics and Gynecology, Ain Shams University, Cairo, Egypt, and Department of Obstetrics and Gynecology, Ahmadi Hospital, Kuwait Oil Company, Ahmadi, Kuwait.  
E-mail: dr.ibrahimanwar@gmail.com

This is an open access journal, and articles are distributed under the terms of the Creative Commons Attribution-NonCommercial-ShareAlike 4.0 License, which allows others to remix, tweak, and build upon the work non-commercially, as long as appropriate credit is given and the new creations are licensed under the identical terms.

For reprints contact: reprints@medknow.com

**How to cite this article:** Abdelazim IA, Shikanova S, Kanshaiym S, Karimova B, Sarsembayev M, Starchenko T. Cesarean section scar dehiscence during pregnancy: Case reports. J Family Med Prim Care 2018;7:1561-5.

#### Access this article online

##### Quick Response Code:



Website:  
www.jfmipc.com

DOI:  
10.4103/jfmipc.jfmipc\_361\_18

the best surgical approach for repairing the deficient anterior uterine wall in cases of CSSD. This report represents two cases of CSSD seen during cesarean delivery to highlight the possible causes of CSSD and how the CSSD can be diagnosed and managed properly.

## Case Reports

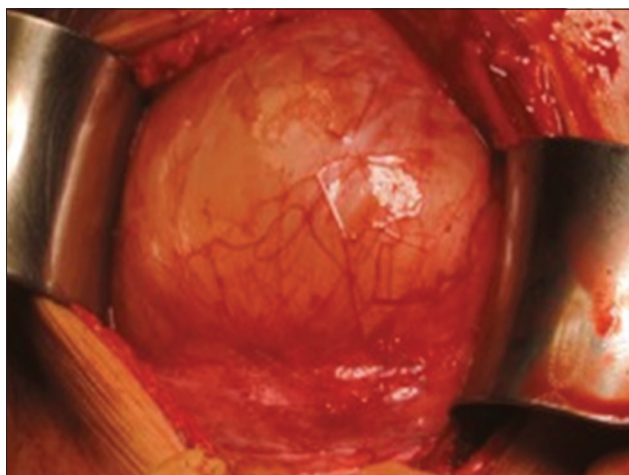
### Case 1

A 35-year-old woman, gravida 2, previous cesarean delivery, due to preterm premature rupture of membranes (PPROM), drained liquor at 30 weeks' gestation and breech presentation. She was admitted for elective CS at 38<sup>+3d</sup> weeks' gestation because of recurrent breech presentation after uneventful regular antenatal care.

Her second pregnancy was achieved spontaneously within the first 6 months from the first CS. Her reports during the antenatal follow up showed appropriate fetal growth matching to the gestational age calculated from the first day of the last menstrual.

During the second elective CS, the site of the previous CS scar was seen to be very thin along its whole length and the anterior uterine wall was completely deficient, leaving visible bulging fetal membranes and moving baby underneath [Figure 1]. We decided to deliver the baby through vertical uterine incision for the patient's safety and to avoid lateral extensions and injuries of the uterine vessels and the bladder if transverse uterine incision is used to deliver the baby.<sup>[2]</sup>

A healthy living baby boy was delivered, weighing 3.220 kg with Apgar scores 8 and 9 at first and fifth minutes after delivery, respectively. The uterine incision was repaired in two layers using vicryl 0 interrupted simple stitches for the first layer, followed by interrupted mattress stitches for the second layer. The interrupted sutures allowed repair and approximation of



**Figure 1:** During the elective cesarean section of the studied case 1, the previous cesarean section scar was very thin along its whole length and the anterior uterine wall was completely deficient, leaving a visible bulging fetal membranes and moving baby underneath

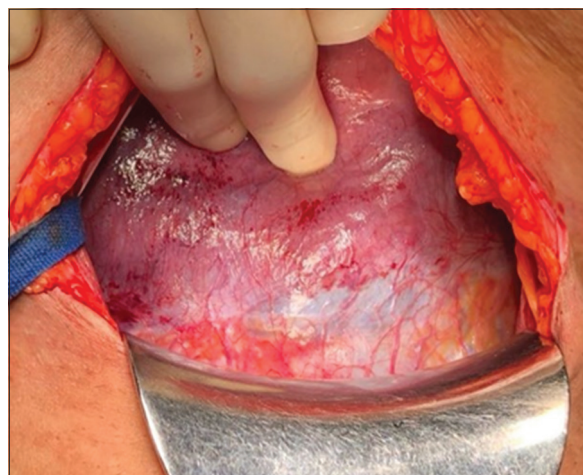
the two edges of the uterine incision without any tension or traction on the edges of the incision, compared with continuous stitches which may precipitate further tear of the already deficient anterior uterine wall. The closure of the uterine incision was followed by the closure of the anterior abdominal wall in layers. The studied woman had uneventful postoperative recovery and was discharged from the hospital in good general condition after counseling regarding her intraoperative findings, vertical uterine incision, and future pregnancies.

### Case 2

A 32-year-old woman, gravida 4, previous three CSs, was admitted as unbooked case without any antenatal records in our hospital, at 29<sup>+4d</sup> weeks' gestation, triplet pregnancy after ovulation induction by clomiphene citrate (Clomid) with preterm labor pain (PTL).<sup>[3]</sup> The PTL was diagnosed by regular uterine contractions lasting at least 30 s and occurring at least four times per 30 min with significant cervical changes on digital examination (cervical dilatation <3 cm, cervical effacement ≤50%).<sup>[4]</sup>

She received betamethasone and magnesium sulfate (MgSO<sub>4</sub>) for fetal lung and fetal brain protection, respectively, according to the hospital protocol,<sup>[5-7]</sup> followed by emergency CS after counseling, cross matching, basic preoperative investigations, and neonatology consultation. During the CS, the previous CSs' scars were dehiscent over more than half of its length and the anterior uterine wall was missing leaving visible fetal membranes [Figure 2].

The bladder flap was dissected downward away from the lower uterine segment as much as possible to avoid urinary bladder injury if the uterine incisions extended downward. The dissection of the urinary bladder flap was followed by inserting one transverse untied vicryl stitch over the anterior wall of the lower uterine segment below the dehiscent previous scars [for identification of the lower flap of our uterine incision



**Figure 2:** During the cesarean section of the studied case 2, the previous cesarean sections scars were dehiscent over more than half of its length and the anterior uterine wall was missing leaving visible fetal membranes

(*I. Abdelazim's stitch*)). A transverse uterine incision was done through the dehiscence uterine scars, followed by delivery of three girls admitted to the neonatal intensive care unit: 1.235 kg Apgar scores 6 and 7 at first and fifth minutes after birth, respectively; 1.150 kg Apgar scores 7 and 8 at first and fifth minutes after birth, respectively; and 1.045 kg Apgar scores 5 and 6 at first and fifth minutes after birth, respectively.

After the delivery of three girls, the upper and the lower uterine flaps of our transverse uterine incision were identified by the previous described untied vicryl stitch (*I. Abdelazim's stitch*). After identification of the two uterine flaps (upper and lower) of our transverse uterine incision, the untied vicryl stitches (*I. Abdelazim's stitch*) inserted below the dehiscence previous scars were removed and repair of our transverse incision was started. The uterine incision was repaired as described before in two layers using vicryl 0 interrupted simple stitches for the first layer and interrupted mattress stitches for the second layer, followed by closure of the anterior abdominal wall in layers. The studied woman had uneventful postoperative recovery and was discharged from the hospital after counseling regarding her intraoperative findings, uterine incision, and future pregnancies.

## Discussion

Cesarean delivery complications include wound hematoma, infection, and CSSD as early complications, and morbid adherent placenta and intra-abdominal adhesions with subsequent infertility as long-term complications.<sup>[8-10]</sup>

There are numerous definitions of myometrial thinning; however, there is no consistent definition of this condition with respect to uterine incision.<sup>[11-13]</sup> Myometrial thinning is observed in 0.2%–4.3% of postcesarean pregnancies<sup>[1]</sup> and is thought to occur because of CSSD.

However, no clear consensus has been reached regarding the precise underlying mechanism of this condition after CS delivery.<sup>[2]</sup> The major complication of CSSD is uterine rupture, which is reported in approximately 0.3% during TOL in women with previous CS scar.<sup>[14,15]</sup>

Recent studies reported the efficacy of ultrasound in predicting lower uterine segment tears before TOL in women with previous CS scar.<sup>[16,17]</sup> A recent meta-analysis supports the use of antenatal lower uterine segment measurements to predict and avoid uterine ruptures during TOL in women with previous CS scar.<sup>[16]</sup> Although screening for CSSD during TOL has been reported previously, the efficacy of this technique remains unknown for patients with planned elective repeat CSs.<sup>[2]</sup>

In addition, there is no consensus about the diagnostic criteria of the CSSD during the sonographic assessment of lower uterine segment, and little is known about the ideal uterine incisions and time of delivery in CSSD cases when diagnosed.<sup>[2]</sup>

This report represents two cases of CSSD seen during cesarean delivery to highlight the possible causes of CSSD and how the CSSD can be diagnosed and managed properly. The CSSD was seen in the first presented case during elective CS 38<sup>+3d</sup> weeks, and her reports showed uneventful antenatal care. During the elective CS, the previous CS scar was seen to be very thin along its whole length and the anterior uterine wall was completely deficient, leaving visible bulging fetal membranes and moving baby underneath [Figure 1]. Vertical uterine incision was used to deliver the baby to avoid lateral extensions and injuries of the uterine vessels and the bladder if transverse uterine incision is used.<sup>[2]</sup>

Retrograde analysis showed two main causes found behind the complete CSSD of the studied woman. First, the previous CS at 30 weeks' gestation and second, the short interpregnancy interval (6 months).

The second studied case was admitted at 29<sup>+4d</sup> weeks' gestation after previous three CSs, triplet pregnancy with PTL, for emergency CS after receiving betamethasone and MgSO<sub>4</sub> for fetal lung and brain protection, respectively. During the CS, the previous CSs' scars were dehiscence over more than half of its length and the anterior uterine wall was missing leaving visible fetal membranes [Figure 2].

The bladder flap was dissected downward away from the lower uterine segment as much as possible to avoid urinary bladder injury if the uterine incisions extended downward. The dissection of the urinary bladder flap was followed by inserting one transverse untied vicryl stitch over the anterior wall of the lower uterine segment below the dehiscence previous scars [for identification of the lower flap of our uterine incision (*I. Abdelazim's stitch*)].

A transverse uterine incision was done through the dehiscence uterine scars, followed by delivery of three girls. After delivery of three girls, the upper and the lower uterine flaps of our transverse uterine incision were identified by the previous described untied vicryl stitch (*I. Abdelazim's stitch*). After identification of the two uterine flaps (upper and lower) of our transverse uterine incision, the untied vicryl stitches (*I. Abdelazim's stitch*) inserted below the dehiscence previous scars were removed and repair of our transverse incision was started.

The uterine incision was repaired as described before in two layers using vicryl 0 interrupted simple stitches for the first layer and interrupted mattress stitches for the second layer, followed by closure of the anterior abdominal wall in layers. Retrograde analysis of the second studied case showed that triplet pregnancy and uterine overdistension were the main reasons behind CSSD and PTL.

Sawada *et al.* reported major complications with extension of the uterine incision to the bladder and cervix during intraoperative management of CSSD.<sup>[2]</sup> In women with CSSD, although the

fetus can be delivered carefully, the transverse uterine incision of the lower uterine segment may extend downward to the uterine cervix or the bladder and/or transversely to the uterine vessels with subsequent bleeding. Therefore, it is important for clinicians to make the uterine incision in an upward vertical direction away from extensively thinned, deficient lower uterine segment.

In addition, Landon and Lynch concluded that the use of a vertical uterine incision may be considered a protective measure in CSSD to prevent the lateral extension and/or damage to the uterine parametrium in CSSD cases managed by transverse uterine incisions. However, the risk of increased bleeding associated with longitudinal uterine incision and its potential effects on subsequent pregnancies must also be considered.<sup>[18]</sup>

Although the two studied cases have no symptoms of CSSD and most of the CSSD is found during CS, it is not harmful to assess the lower uterine segment of women with previous CS using the available ultrasound facilities. If the CSSD is diagnosed before the elective CS, the surgeon should prepare himself with the safest uterine incision with least possible complications and the best way of repair of the defective or dehiscence uterine wall.<sup>[2]</sup>

Further studies with long-term follow-up are needed to investigate the causes of CSSD, benefits of ultrasound screening of women with previous cesarean scars in detection of CSSD, safest uterine incision, and the best way for repair of the defective or dehiscence lower uterine wall.

## Conclusion

It is useful to assess the lower uterine segment of women with previous CS using the available ultrasound facilities. If the CSSD is diagnosed before the elective CS, the surgeon should prepare himself with the safest uterine incision with least possible complications and the best way of repair of the defective or dehiscence uterine wall. In women with CSSD, the transverse uterine incision of the lower uterine segment may extend downward to the uterine cervix or the bladder and/or transversely to the uterine vessels, and therefore, the vertical uterine incision may be considered a protective measure in CSSD cases.

## Acknowledgment

The authors are grateful to the studied women for their agreement and consent to participate in this presentation (signed consent taken from the studied women).

## Financial support and sponsorship

The case reports are funded by the authors themselves.

## Conflicts of interest

There are no conflicts of interest.

## References

1. Baron J, Weintraub AY, Eshkoli T, Hershkovitz R, Sheiner E. The consequences of previous uterine scar dehiscence and cesarean delivery on subsequent births. *Int J Gynaecol Obstet* 2014;126:120-2.
2. Sawada M, Matsuzaki S, Nakae R, Iwamiya T, Kakiga-no A, Kumasawa K, Ueda Y, *et al.* Treatment and repair of uterine scar dehiscence during cesarean section. *Clin Case Rep* 2017;5:145-9.
3. Abdelazim IA, Makhoulouf HH. Sequential clomiphene citrate/hMG versus hMG for ovulation induction in clomiphene citrate-resistant women. *Arch Gynaecol Obstetr* 2013;287:591-7.
4. Abu-Faza M, Abdelazim I, Svetlana S, Nusair B, Farag R, Nair S. Diagnostic accuracy of PremaQuick versus Actim Partus in prediction of preterm labor in symptomatic women within 14 days. *Open J Obstetr Gynecol* 2018;8:741-55.
5. Farghali M, Abdelazim I, Abdelrazek K. Delayed second twin delivery: benefits and risks. *J Matern-Fetal Neo Med* 2017; Doi: 10.1080/14767058.2017.1413547.
6. Abu-Faza M, Abdelazim IA. Antenatal magnesium sulphate (MgSO<sub>4</sub>) for fetal neuro-protection prior to preterm labor: Mini-review. *ARC J Gynecol Obstetr* 2017;2:11-4.
7. Abdelazim IA, Munaifi SA. Delayed delivery of the two remaining fetuses of triplet pregnancy: Case report. *Gynecol Obstet Reprod Med* 2018;24. Doi: <http://dx.doi.org/10.21613/GORM.2017.756>.
8. Marshall NE, Fu R, Guise JM. Impact of multiple cesarean deliveries on maternal morbidity: A systematic review. *Am J Obstet Gynecol* 2011;205:262.e1-8.
9. Gurol-Urganci I, Bou-Antoun S, Lim CP, Cromwell DA, Mahmood TA, Templeton A, *et al.* Impact of Caesarean section on subsequent fertility: A systematic review and meta-analysis. *Hum Reprod* 2013;28:1943-52.
10. Silver RM. Abnormal placentation: Placenta previa, vasa previa, and placenta accreta. *Obstet Gynecol* 2015;126:654-68.
11. Roberge S, Boutin A, Chaillet N, Moore L, Jastrow N, Demers S, *et al.* Systematic review of cesarean scar assessment in the nonpregnant state: Imaging techniques and uterine scar defect. *Am J Perinatol* 2012;29:465-71.
12. Lin N, Li X, Song T, Wang J, Meng K, Yang J, *et al.* The effect of collagen-binding vascular endothelial growth factor on the remodeling of scarred rat uterus following full-thickness injury. *Biomaterials* 2012;33:1801-7.
13. Vkhareva Osser O, Valentin L. Risk factors for incomplete healing of the uterine incision after caesarean section. *BJOG* 2010;117:1119-26.
14. Dow M, Wax JR, Pinette MG, Blackstone J, Cartin A. Third-trimester uterine rupture without previous cesarean: A case series and review of the literature. *Am J Perinatol* 2009;26:739-44.
15. Guise JM, Denman MA, Emeis C, Marshall N, Walker M, Fu R, *et al.* Vaginal birth after cesarean: New insights on maternal and neonatal outcomes. *Obstet Gynecol* 2010;115:1267-78.
16. Kok N, Wiersma IC, Opmeer BC, de Graaf IM, Mol BW, Pajkrt E. Sonographic measurement of lower uterine segment thickness to predict uterine rupture during a trial of labor in women with previous Cesarean section: A meta-analysis. *Ultrasound Obstet Gynecol* 2013;42:132-9.

17. Cheung VY, Constantinescu OC, Ahluwalia BS. Sonographic evaluation of the lower uterine segment in patients with previous cesarean delivery. *J Ultrasound Med* 2004;23:1441-7.
18. Landon MB, Lynch CD. Optimal timing and mode of delivery after cesarean with previous classical incision or myomectomy: A review of the data. *Semin Perinatol* 2011;35:257-61.