

**Case Report**

## A rare case of multifocal lymphadenopathy in a young male

Anshum Aneja<sup>1,\*</sup>, Uma Maheswari K<sup>1</sup>, Gayathri Devi H.J<sup>1</sup> and Shamim Sheikh<sup>2</sup>

<sup>1</sup>Department of Respiratory Medicine, M.S. Ramaiah Medical College, Bangalore, Karnataka, India and

<sup>2</sup>Department of Pathology, M.S. Ramaiah Medical College, Bangalore, Karnataka, India

\*Correspondence address. Department of Respiratory Medicine, M.S. Ramaiah Medical College, MSRIT Post, Bangalore, Karnataka 560044, India. Tel: +91-8800706010; Fax: +91-080-23606213; E-mail: dranshumaneja@yahoo.com

Received 31 July 2014; revised 8 October 2014; accepted 19 October 2014

Lymphadenopathy can be caused by localized and systemic diseases. While viral and bacterial infections commonly cause lymphadenitis in young adults, tuberculosis (TB) is a common cause for lymphadenopathy in endemic areas. Besides, lymphadenopathy may be a presenting manifestation of malignancy, systemic disorders and some rare diseases. Thus, relevant evaluation and exclusion of commoner causes is important to clinch the diagnosis. Histopathological examination is mandatory in such patients. We hereby report the case of a young adult male who presented with low-grade fever and abdominal pain with cervical and mesenteric lymphadenopathy in a TB endemic region, but was proved to have atypical presentation of Kikuchi–Fujimoto disease, which is a rare but benign cause of lymphadenopathy.

### INTRODUCTION

Multifocal lymphadenopathy can be caused by various localized and systemic diseases. The aetiology of lymphadenitis can be broadly divided into infectious, inflammatory and malignant causes and depends on epidemiology, age of the patient and patient's immune status. Some causes of generalized lymphadenopathy include tuberculosis (TB), lymphoma, HIV–AIDS, toxoplasmosis, secondary syphilis, Kikuchi–Fujimoto disease (KFD), Lymphogranuloma venereum and Kawasaki disease. In endemic areas, 20–40% of tubercular lymphadenitis involves cervical lymph nodes, whereas ~39% may involve other lymph node sites [1]. In children and young adults, both acute and chronic infectious agents like Epstein–Barr virus and *Mycobacterium tuberculosis* are common [2].

In countries with high TB prevalence, empirical anti-tubercular therapy (ATT) is often routinely instituted based on clinical history and findings. In these cases, other causes may be overlooked until there is a non-response to ATT. WHO recommends lymph node excision biopsy in cases where fine needle aspiration cytology (FNAC) and stain for acid fast bacilli (AFB) are inconclusive [3]. While this aids confirmation of TB, a negative histopathology would indicate the need for further investigations to rule out other causes.

We hereby report a case of KFD in a young Asian male presenting with abdominal pain, polyarthralgia, cervical and mesenteric lymphadenopathy.

### CASE REPORT

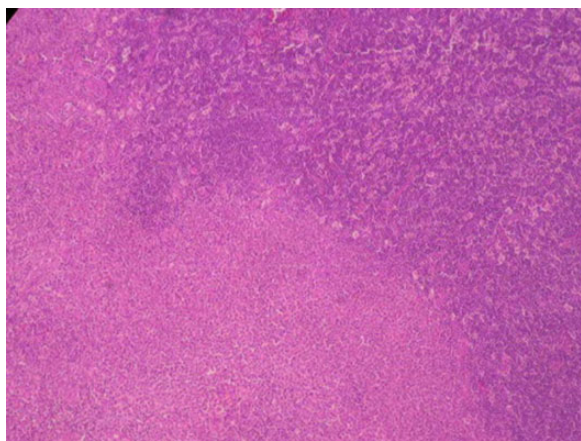
A 19-year-old male student presented to the Department of Respiratory Medicine with a 2-month history of intermittent low-grade fever, polyarthralgia and dull abdominal pain. There was no history of vomiting, diarrhoea or weight loss. A meticulous workup had been performed prior to presentation to our clinic (Table 1) and was within normal limits except for mesenteric lymphadenopathy on abdominal ultrasonography. He had previously been treated with a short course of non-steroidal anti-inflammatory drugs (NSAIDs) and antibiotics. In view of partial relief of symptoms, a presumptive diagnosis of abdominal TB was made and empirical ATT had been instituted by the treating physician.

At presentation to our hospital, the patient had been on ATT for 3 weeks and had developed a new onset painless right-sided neck swelling along with intermittent high-grade fever and joint pains. On examination, vital signs were normal (temperature—36.6°C, pulse rate—80/min, BP—120/

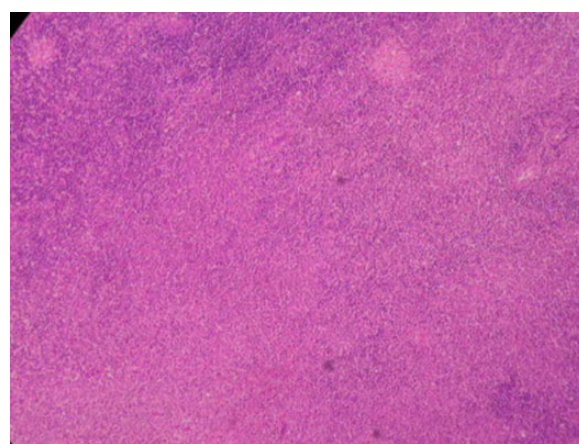
**Table 1.** Laboratory investigations

Investigations	Prior to admission	Post admission	Follow-up
Total leucocyte count	4200 cells/cumm	3700 cells/cumm	6200 cells/cumm
Mantoux test	Negative	—	—
ESR	58 mm/h	35 mm/h	20 mm/h
C-reactive protein	85 mg/l	—	—
Uric acid	Normal	7.2 mg/dl	7.1 mg/dl
Liver enzymes			
SGOT	Normal	65.8 IU/l	42 IU/l
SGPT		13.7 IU/l	65 IU/l
Smear for malarial parasite	Negative	—	—
Dengue serology	Negative	—	—
Blood, urine culture	Sterile	—	—
ASO, rheumatoid factor	Negative	—	—
Widal test	Negative	—	—
Hbs Ag, HCV, HIV serology	Negative	—	—
ANA, anti-dsDNA	—	Negative	—

ANA: antinuclear antibody; ASO: anti-streptolysin o; ESR: erythrocyte sedimentation rate; SGOT: serum glutamic oxaloacetic transaminase; SGPT: serum glutamic pyruvic transaminase.



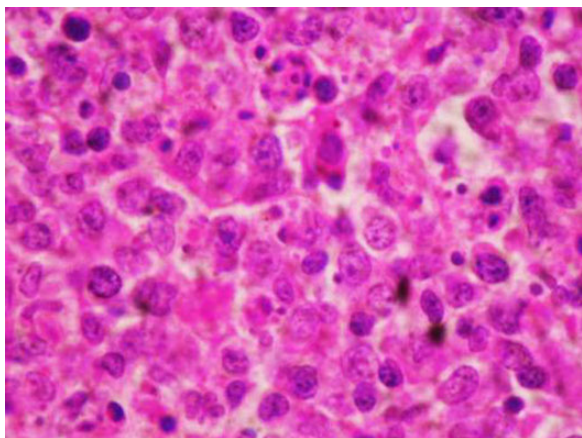
**Figure 1:** Lymph node biopsy section showing patchy areas of necrosis, histiocytes with abundant cytoplasm, peripheral crescentic nuclei, patchy mononuclear and mixed lymphoid cell proliferation, paracortical hyperplasia, cellular debris and nuclear dust (karyorrhexis) (H&E  $\times 10$ ).



**Figure 2:** Lymph node biopsy section showing paracortical necrosis with collection of histiocytes and karyorrhexis (H&E  $\times 10$ ).

76 mmHg and respiratory rate—15/min). There was no pallor, icterus, cyanosis or jugular venous distension. Neck examination revealed non-tender, matted, firm lymph nodes 1  $\times$  2 cm size in the right lower deep cervical region without rise in local temperature. There were no palpable lymph nodes elsewhere. Lung and cardiac examination were normal. On abdominal examination, there was no organomegaly, free fluid or tenderness. Laboratory investigations were performed (detailed in Table 1). A chest radiogram was normal. A repeat abdomino-pelvic ultrasonography confirmed the presence of multiple variable sized, non-matted mesenteric lymph nodes predominantly in the right lumbar region, the largest

measuring 20  $\times$  11 mm. There was no free fluid or organomegaly. FNAC of right lower cervical lymph node showed non-specific lymphoid hyperplasia; stain for AFB was negative. As new lymph nodes had appeared and patient continued to be symptomatic on ATT, an excision biopsy of the same lymph node site was performed to rule out non-tubercular causes of lymphadenopathy. Histopathological examination of the specimen revealed follicles with reactive germinal centres, paracortical hyperplasia, patchy necrosis and crescentic histiocytes, suggestive of KFD. There was no evidence of granulomas or atypical cells. Stain for AFB was negative. TB PCR was also negative; culture for AFB was not performed in view of negative stain and PCR results (Figs 1–3). Bone marrow



**Figure 3:** Lymph node biopsy section showing prominence of karyorrhectic debris with histiocytes (H&E  $\times 40$ ).

aspiration and biopsy were performed to rule out lymphoma. No evidence of lymphomatous involvement on the aspirate was noted. Karyotyping in the bone marrow aspirate was also normal. Patient also underwent enteroscopy and colonoscopy with mucosal biopsies to rule out mycobacterial and *Yersinia pseudotuberculosis* infection. Histopathology showed non-specific duodenitis, ileitis and colitis with no evidence of tubercular granulomas. Since KFD is known to be associated with systemic lupus erythematosus (SLE), antinuclear antibody (ANA) and anti-ds-DNA were sent and were negative. As there was no evidence of TB, ATT was stopped and the patient was managed symptomatically with NSAIDs. He improved clinically with complete regression of the cervical and abdominal lymphadenopathy within a month of treatment. Steroids were not added in view of complete response on follow-up.

## DISCUSSION

KFD is also known as histiocytic necrotizing lymphadenitis. It is a rare, benign and self-limiting cause for localized lymphadenopathy. Though KFD has a worldwide distribution, but Asians have a higher prevalence of occurrence of the disease [4]. On review of literature, sporadic case reports and series have been published, but the exact incidence and pathogenesis of the disease is still unknown [5–7].

Pathogenic hypotheses proposed for KFD include apoptosis, autoimmune responses and infections due to Epstein–Barr virus, Cytomegalovirus and Herpes virus. KFD has also been reported as a forme fruste of SLE. Several authors have reported a diagnosis of KFD before, during and after SLE diagnosis.

This disease occurs predominantly in young female patients. The clinical presentation includes low-grade fever, night sweats and cervical lymphadenopathy, which is similar to that of TB. In two case series by Kikuchi [8] and Fujimoto *et al.* [9], KFD has been misdiagnosed as lymph node TB and wrongly treated before histopathological confirmation in ~50 and 58% of patients, respectively. It is thus considered as an uncommon differential of lymphadenopathy, because its

course and treatment differ dramatically from other causes of lymphadenopathy such as lymphoma, TB and SLE. In a case series by Dorfman and Berry [10], ~40% of patients with KFD have been wrongly diagnosed or treated as Hodgkin's lymphoma. In SLE patients, arthritis and polyarthralgia may also be present. However, these manifestations have been sporadically reported even in patients without SLE [11, 12].

Involvement of other lymph node sites is less frequent. Of these, involvement of intra-abdominal lymph nodes by KFD is extremely uncommon. Only about 17 cases of intra-abdominal lymphadenopathy have been reported thus far in the literature [13].

Management of this disease is usually supportive and includes NSAIDs to alleviate symptoms. The use of systemic corticosteroids has been recommended in severe cases of generalized and extranodal KFD with multisystem involvement or in the presence of positive ANA titres. Immunosuppressive agents have also been used in life-threatening disease.

The disease is usually self-limiting and has a favourable prognosis in most patients with resolution within 6 months of onset. However, protracted symptoms and recurrences have also been reported. As SLE may occur even after complete resolution of symptoms, a strong index of suspicion is important during follow-up visits.

Our patient was a young Asian male who presented with constitutional symptoms, mesenteric and cervical lymphadenopathy in a TB endemic area. He had been initiated on anti-tubercular treatment based on the presence of mesenteric lymphadenopathy. The subsequent appearance of cervical lymphadenopathy and the intervention of excision biopsy following an inconclusive FNAC was the cornerstone to diagnosis in this patient.

## CONFLICT OF INTEREST STATEMENT

None declared.

## REFERENCES

1. Gupta PR. Difficulties in managing lymph node tuberculosis. *Lung India* 2004;**21**:50–3.
2. Sharma SK, Mohan A. Extrapulmonary tuberculosis. *Indian J Med Res* 2004;**120**:316–53.
3. World Health Organization. Improving the diagnosis and treatment of smear-negative pulmonary and extrapulmonary tuberculosis among adults and adolescents. Recommendations for HIV-prevalent and resource-constrained settings 2007. [http://whqlibdoc.who.int/hq/2007/WHO\\_HTM\\_TB\\_2007.379\\_eng.pdf](http://whqlibdoc.who.int/hq/2007/WHO_HTM_TB_2007.379_eng.pdf) (9 November 2014, date last accessed).
4. Bosch X, Guilabert A, Miquel R, Campo E. Enigmatic Kikuchi-Fujimoto disease: a comprehensive review. *Am J Clin Pathol* 2004;**122**:141–52.
5. Pileri S, Kikuchi M, Helbron D. Histiocytic necrotizing lymphadenitis without granulocytic infiltration. *Virchows Arch A Pathol Anat Histol* 1982;**395**:257–71.
6. Tsang WYW, Chan JKC, Ng CS. Kikuchi's lymphadenitis: a morphologic analysis of 75 cases with special reference to unusual features. *Am J Surg Pathol* 1994;**18**:219–31.
7. Dalton J, Shaw R, Democratis J. Kikuchi-Fujimoto disease. *Lancet* 2014;**383**:1098.

8. Kikuchi M. Lymphadenitis showing focal reticulum cell hyperplasia with nuclear debris and phagocytes. A clinico-pathological study. *Nippon Ketsueki Gakkai Zasshi* 1972;**35**:379–80 (in Japanese).
9. Fujimoto Y, Kojima Y, Yamaguchi K. Cervical subacute necrotizing lymphadenitis. *Naika* 1972;**30**:920–7 (in Japanese).
10. Dorfman RF, Berry GJ. Kikuchi's histiocytic necrotizing lymphadenitis: an analysis of 108 cases with emphasis on differential diagnosis. *Semin Diagn Pathol* 1988;**5**:329–45.
11. Douglas M, Bradbury R, Kannagara S, Mitchell D. Arthritis as an unusual manifestation of Kikuchi-Fujimoto disease. *Rheumatology* 2003;**42**:1010–12.
12. Graham LE. Kikuchi-Fujimoto disease and peripheral arthritis: a first! *Ann Rheum Dis* 2002;**61**:475.
13. Vijayaraghavan R, Chandrashekar R, Saraswathi A, Belagavi CS. Kikuchi-Fujimoto's disease involving mesenteric nodes: a report and review of literature. *BMJ Case Rep* 2011; **2011**.