

# High-resolution Sonographic Measurements of Lower Extremity Bursae in Chinese Healthy Young Men

Yong-Yan Gao<sup>1</sup>, Chi-Qiu Wu<sup>2</sup>, Wei-Xing Liu<sup>1</sup>, Lei Zhang<sup>2</sup>, Chun-Ling Li<sup>1</sup>

<sup>1</sup>Department of Ultrasound, The General Hospital of Chinese People's Armed Police Forces, Beijing 100039, China

<sup>2</sup>Department of Ultrasound, The General Hospital of Zhejiang Corps of Chinese People's Armed Police Forces, Hangzhou, Zhejiang 310054, China

## Abstract

**Background:** Lower extremity bursae are very vulnerable to injury during strenuous physical exercises. Understanding the imaging characteristics of normal bursae is essential for early diagnosis of morphological abnormalities. Therefore, we evaluated the normal range of lower extremity bursae in healthy young men using high-resolution ultrasound (HR-US) imaging.

**Methods:** Bursae in the lower extremities were examined by HR-US in 290 Chinese healthy young men with a median age of 18 years (range, 18–23 years). The bilateral suprapatellar bursa (SPB), deep infrapatellar bursa (DIPB), popliteal bursa (PB), and retrocalcaneal bursa (RCB) were imaged and measured for analysis.

**Results:** The HR-US identification rates of the SPB, DIPB, PB, and RCB were 89.0% (517/580), 55.0% (319/580), 29.4% (171/580), and 49.5% (287/580), respectively. With the assumption that the bursae were normal in 95% of the study participants, the length and width values at the maximal cross-section of the SPB, DIPB, PB, and RCB were  $\leq 18.00$  and 6.09 mm, 8.10 and 2.11 mm, 7.67 and 3.93 mm, and 7.82 and 2.04 mm, respectively.

**Conclusions:** Using HR-US imaging, we were able to analyze lower extremity bursae with high detection rates in healthy young men. The normal ranges of lower extremity bursa dimensions in healthy young men measured by HR-US in this study could be used as reference values for evaluation of bursa abnormalities in the lower extremity.

**Key words:** Bursa; Lower Extremity; Ultrasonography

## INTRODUCTION

Bursae are closed connective tissue capsules that have a thin wall, contain synovial fluid, and are located around joints where tendons contact bone surfaces and some bursae communicate with the articular cavity.<sup>[1,2]</sup> The main function of a bursa is to reduce the friction and oppression between the soft tissue and bones.<sup>[1,2]</sup> Lower extremity bursae are highly susceptible to injury during strenuous physical exercises, such as those involved in sports and military training.<sup>[3]</sup> Histopathological changes in bursae usually begin to occur at early stages of joint damage, even before the presentation of any symptoms. Therefore, understanding the imaging characteristics of normal bursae is essential for early diagnosis of morphological abnormalities.

X-ray imaging is the traditional radiological method used to diagnosis joint trauma, but it cannot display bursae. Magnetic resonance imaging (MRI) can clearly demonstrate the anatomic structures and pathological changes of muscles and soft tissues of joints, including the bursae, and is a beneficial

imaging modality for diagnosing pathological changes in soft tissues. However, most medical services of sports facilities or training sites usually lack an MRI scanner, and in addition, MRI has certain disadvantages including pose limitations, complex operation, and high cost, which hinder its application. Clinical diagnosis of bursa abnormalities usually relies on physical examination and without any imaging modality for diagnostic supporting.<sup>[4,5]</sup> Many studies have suggested that high-resolution ultrasound (HR-US) is better than clinical examination and MRI for the diagnosis of articular cavity effusion.<sup>[4,5]</sup> A study by Ulasli *et al.*<sup>[4]</sup> showed a

**Address for correspondence:** Dr. Chun-Ling Li,  
Department of Ultrasound, The General Hospital of Chinese People's  
Armed Police Forces, Beijing 100039, China  
E-Mail: lichunling315@hotmail.com

This is an open access article distributed under the terms of the Creative Commons Attribution-NonCommercial-ShareAlike 3.0 License, which allows others to remix, tweak, and build upon the work non-commercially, as long as the author is credited and the new creations are licensed under the identical terms.

**For reprints contact:** reprints@medknow.com

© 2016 Chinese Medical Journal | Produced by Wolters Kluwer - Medknow

**Received:** 05-08-2015 **Edited by:** Ning-Ning Wang  
**How to cite this article:** Gao YY, Wu CQ, Liu WX, Zhang L, Li CL. High-resolution Sonographic Measurements of Lower Extremity Bursae in Chinese Healthy Young Men. Chin Med J 2016;129:309-12.

### Access this article online

#### Quick Response Code:



**Website:**  
www.cmj.org

**DOI:**  
10.4103/0366-6999.174487

low consistency between US and clinical examination results for diagnosing knee joint effusion, especially in cases with low amounts of liquid. Because HR-US images can clearly display the structures and blood flow of tissues around joints and HR-US is an inexpensive, noninvasive method that is simple to perform, this technique has been gradually accepted by clinical physicians and has become the first choice imaging modality for examining soft tissue trauma.<sup>[5-7]</sup>

Some previous studies<sup>[1,8]</sup> reported the sizes of bursae in lower extremities. However, the subjects in these studies covered a large age span (20–80 years) and were both male and females. Limiting the age and gender of study subjects can avoid some confounding factors. Because the majority of patients who incur injuries to bursae are athletes and soldiers who are around 20 years old, we investigated the normal ranges of lower extremity bursa dimensions in Chinese healthy young men recruited from a military team, and the measured values may be used as reference values for early diagnosis of bursa abnormalities using US in patients with injuries resulting from strenuous physical activity.

## METHODS

### Subjects

A total of 290 Chinese healthy young men who had been recruited into the military but had yet not to conduct military training were enrolled in this study from January to March 2013. The participants had a median age of 18 years (range, 18–23 years), a mean height of  $174.02 \pm 3.55$  cm, and a mean weight of  $63.81 \pm 9.87$  kg.

Their physical examinations, laboratory examinations (including blood routine examination, erythrocyte sedimentation, and urine tests), electrocardiogram, chest X-ray, and abdominal US results all showed the absence of disease to ensure that the subjects were not affected by any orthopedic, rheumatic, cardio, or pulmonary diseases. The exclusive criteria were as follows: (1) symptoms of pain or palpable positive signs at the locations to be imaged and (2) a history of rheumatism, joint injury, or joint surgery. Each subject signed an informed consent form. Our study was approved by the Institutional Review Board of our institution.

### Ultrasound examination

US examinations of the lower extremity were performed using an iU22 ultrasound system (Philips Healthcare, Bothell, WA, USA) with a L5-12 probe or LOGIQ E9 US system (GE Healthcare, WI, USA) with a ML6-15 probe. The examined lower extremity bursae included the bilateral suprapatellar bursa (SPB), deep infrapatellar bursa (DIPB), popliteal bursa (PB), and retrocalcaneal bursa (RCB). All US scans were conducted by two physicians (Chi-Qiu Wu and Lei Zhang) with more than 5 years of musculoskeletal US experience each.

US examinations of the SPB and DIPB were performed with the subjects sitting with both knees flexed at  $30^\circ$ .<sup>[9]</sup> The probe was placed at the knees longitudinally above the patella, and the SPB could be detected between the quadriceps

tendon and femur with two fat pads surrounding it. While the probe was placed longitudinally below the patella, the DIPB could be found between the patellar tendon and tibia. The PB and RCB were scanned in a prone position with the legs keeping straight. The PB could be observed between the semimembranosus muscle and the medial head of the gastrocnemius muscle when the probe was placed horizontally below the popliteal fossa. The RCB could be detected longitudinally in the rear between the Achilles tendon and the posterior–superior corner of the calcaneus.

### Measurement of bursa dimensions

For each identified bursa, measurements were taken with US calipers in two dimensions of length and width in the maximal cross-section of the bursa. Each dimension was measured 3 times, and average values were calculated.

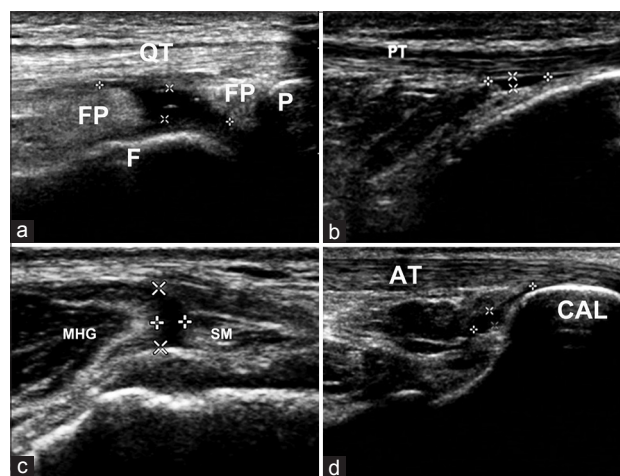
### Statistical analysis

All the statistical analyses were performed with SPSS 18.0 software (SPSS Inc., Chicago, IL, USA). The identification rates of the lower extremity bursae by HR-US were determined. The length and width measurements for each bursa type are presented as percentiles.

## RESULTS

### Identification rates of lower extremity bursae

HR-US examination was performed on 580 lower extremities of 290 healthy young men. The bursae appeared as elongated sac-shaped or irregular-shaped areas with an echogenicity. Overall, 89.0% (517/580) of SPB, 55.0% (319/580) of DIPB, 29.4% (171/580) of PB, and 49.5% (287/580) of RCB were identified by HR-US. The dimensions (length and width) at the maximal cross-section of these visualized bursae were measured as illustrated in Figure 1.



**Figure 1:** Sonographic images of lower extremity bursae. (a) Sagittal image of a SPB; (b) sagittal image of a DIPB; (c) cross-sectional image of a PB; and (d) sagittal image of a RCB. SPB: Suprapatellar bursa; DIPB: Deep infrapatellar bursa; PB: Popliteal bursa; RCB: Retrocalcaneal bursa; QT: Tendon of quadriceps femoris; FP: Fat pad; F: Femur; P: Patella; PT: Patella tendon; MHG: Medial head of the gastrocnemius muscle; SM: Semimembranosus muscle; AT: Achilles tendon; CAL: Calcaneus.

## Sonographic measurements of lower extremity bursa dimensions

Size percentiles for the SPB, DIPB, PB, and RCB dimensions measured with HR-US imaging are provided in Table 1. The length and width of the SPB tended to be normally distributed, whereas those of the DIPB, PB, and RCB tended to exhibit a skewed distribution [Figure 2]. Assuming that the bursa dimensions were within normal ranges in 95% of all subjects, the threshold values for normal bursa size (length and width) at the maximal cross-section were  $\leq$  the values of 18.00 and 6.09 mm for the SPB, 8.10 and 2.11 mm for the DIPB, 7.67 and 3.93 mm for the PB, and 7.82 and 2.04 mm for the RCB, respectively.

## DISCUSSION

Healthy bursa contains a small amount of synovial fluid, and the normal size range for a bursa is the basis for diagnosing pathologic effusion.<sup>[1,10]</sup> High-frequency US can be used to precisely determine the location of bursae, according to the anatomical relations of surrounding tissues.<sup>[1]</sup> However, because the amount of synovial fluid in some bursae is too little to be visualized using US, the identification rate for bursae is  $<100\%$ .<sup>[10]</sup> Schmidt *et al.*<sup>[1]</sup> studied healthy people (both men and women) aged from 20 to 60 years and reported identification rates of 77% for the SPB, 16% for the PB, and 24% for the RCB. In the present study, the identification rates

were 89.0% for the SPB, 55.0% for the DIPB, 29.4% for the PB, and 49.5% for the RCB, and all of these rates are higher than those reported in the literature. Possible explanations for the higher identification rates of lower extremity bursae in our study were as follows: First, the subjects in this study were young men approximately 20 years of age who had no symptoms of physical injury. Thus, their bursae in the lower extremities were more likely to be visible. Second, it may be due to higher resolution imaging in current study with the use of sophisticated US system. The measurements of normal bursae in most previous studies were provided as mean and standard deviation values.<sup>[1,8]</sup> However, we found that the measured bursa dimensions, which can represent the volume of synovial fluid within the bursae when a subject is in a supine or prone position, followed a skewed distribution for the DIPB, PB, and RCB, and thus, using the range values of the length and width to describe the size of a normal bursa was more appropriate. Therefore, we used the percentile method to describe the normal range of lower extremity bursa dimensions.

The SPB is the largest bursa of the knee joint and is located between the quadriceps tendon and femur. It has been reported that effusion of the SPB can be easily observed with knee flexion at 30°.<sup>[9]</sup> In 2004, Schmidt *et al.*<sup>[1]</sup> reported that the lateral longitudinal diameter of the SPB displayed on US was  $22.8 \pm 23.0$  mm, which was much greater than the measured values in our present study. For one decade, the resolution of US system had been greatly improved. The 95<sup>th</sup> percentile values for the length and width of the SPB measured in our study in healthy young men was 18.00 mm and 6.09 mm, respectively, which suggested that the SPB dimensions in 95% of the study subjects were  $\leq 18.00$  mm  $\times$  6.09 mm. Thus, these data could be used as reference values for normal SPB in healthy young men.

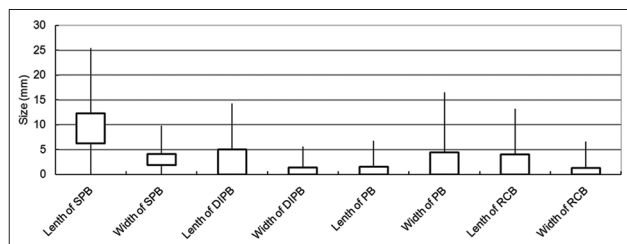
The DIPB is located between the patellar tendon and the tibial tubercle, with a fat pad above it. The detection rate of the DIPB on MRI was reported to be 19–41% in asymptomatic knees,<sup>[11,12]</sup> compared to the rate of 55% in the present study. The reason for the higher detection rate in our study may be the usage of the high frequency US which make it easier to observe anechoic areas of liquid. Previous studies reported craniocaudal and anteroposterior diameters of 6 mm and 2.7–3 mm, respectively, for the DIPB on MRI.<sup>[11,13]</sup> In contrast, in our study, the 95<sup>th</sup> percentile values for the length and width of the DIPB were 8.10 mm and 2.11 mm, respectively. Viegas *et al.*<sup>[14]</sup> reported that the mean craniocaudal, mediolateral, and anteroposterior diameters of the DIPB in cadavers were 20.9–30.1 mm, 25.6–32.8 mm, and 3.4–8.6 mm, respectively. Their results were larger than our results and those measured on MRI, and the reason may be that their measurements were performed after injection of contrast medium and with the bursae fully extended.

The PB is located between the semimembranosus muscle and the medial head of the gastrocnemius muscle and communicates with the joint cavity. Injury or inflammation of knee joints, such as knee osteoarthritis, meniscal lesions, and rheumatoid arthritis, can increase the amount of synovial

**Table 1: Sonographic measurements of bursa in 580 lower extremities of 290 healthy young men (mm)**

Bursa	Percentile (mm)			
	25	50	75	95
SPB				
Length	6.24	9.11	12.30	18.00
Width	1.90	2.90	4.10	6.09
DIPB				
Length	0.00	2.14	4.98	8.10
Width	0.00	0.70	1.38	2.11
PB				
Length	0.00	0.00	4.40	7.67
Width	0.00	0.00	1.50	3.93
RCB				
Length	0.00	0.00	4.05	7.82
Width	0.00	0.00	1.30	2.04

SPB: Bilateral suprapatellar bursa; DIPB: Deep infrapatellar bursa; PB: Popliteal bursa; RCB: Retrocalcaneal bursa.



**Figure 2:** Length and width distributions for lower extremity bursae ( $n = 580$ ). SPB: Bilateral suprapatellar bursa; DIPB: Deep infrapatellar bursa; PB: Popliteal bursa; RCB: Retrocalcaneal bursa.



bursa fluid and form a popliteal cyst.<sup>[15,16]</sup> Rupp *et al.*<sup>[16]</sup> found that 70% of popliteal cysts were associated with injury of the medial meniscus and 85% were related to the degeneration and damage of articular cartilage. Schmidt *et al.*<sup>[1]</sup> reported a display rate of 16% for the PB with US, in comparison to a detection rate of 29.4% in our study. The 95<sup>th</sup> percentile values for the length and width of the PB in our study were 7.67 mm and 3.93 mm, respectively, and thus, values equal to or less than these 95<sup>th</sup> percentile values could be set as a reference of the normal range.

The RCB is located between the Achilles tendon and the posterior–superior corner of the calcaneus. Nazarian *et al.*<sup>[8]</sup> reported a sonographic display rate of 50% among 60 bursae in 30 healthy volunteers, and this rate was consistent with the rate of 49.5% in our study. The mean width of the RCB in the study by Nazarian *et al.* was 1.4 mm, with a range of 0.6–2.5 mm, but they did not report the distribution characteristics of the measured values. In addition, their study subjects ranged in age from 22–84 years and included both gender. The 95<sup>th</sup> percentile values for the length and width of the RCB in healthy young men in the present study were 7.82 mm and 2.04 mm, respectively, suggesting that the normal maximal range for the RCB dimensions is  $\leq 7.82 \text{ mm} \times 2.04 \text{ mm}$ .

There were some limitations in our study. First, as the purpose of this research was to provide US references for early diagnosis of bursa abnormalities resulting from physical injury incurred during sporting exercises or military training, the subjects were limited to healthy young men approximately 20 years of age, and other age groups and women were not involved. Thus, additional research is needed for these populations. Second, we did not collect data regarding the subjects' areas of residence or exercise habits, and such factors could affect the presence and size of lower extremity bursae and further affect our results. We plan to include these relevant factors and perform corresponding statistical analyses in future studies of patients with abnormal lower extremity bursae.

In conclusion, real-time US imaging is an important modality for evaluating the bursae of the lower extremities and offers the advantages of providing HR images of most bursae, being simple to perform, not involving radiation, and using only portable equipment. In the present study, HR-US imaging allowed measurement of bursae of the lower extremities with much higher detection rates than reported in previous studies. The normal ranges for the dimensions of lower extremity bursae in healthy young men as measured by US in this study can be used as reference values for the evaluation of bursa abnormalities in the lower extremities.

### Financial support and sponsorship

This work was supported by grants from the Chinese People's Armed Police Force (No. WJHQ2012-15 and No. WZ20130115).

### Conflicts of interest

There are no conflicts of interest.

### REFERENCES

- Schmidt WA, Schmidt H, Schicke B, Gromnica-Ihle E. Standard reference values for musculoskeletal ultrasonography. *Ann Rheum Dis* 2004;63:988-94. doi: 10.1136/ard.2003.015081.
- Mahgoub HA, Bailey M, Kaiser P. An overview of infectious bursal disease. *Arch Virol* 2012;157:2047-57. doi: 10.1007/s00705-012-1377-9.
- Castagna A, Garofalo R, Cesari E, Markopoulos N, Borroni M, Conti M. Posterior superior internal impingement: An evidence-based review [corrected]. *Br J Sports Med* 2010;44:382-8. doi: 10.1136/bjism.2009.059261.
- Ulasli AM, Yaman F, Dikici Ö, Karaman A, Kaçar E, Demirdal ÜS. Accuracy in detecting knee effusion with clinical examination and the effect of effusion, the patient's body mass index, and the clinician's experience. *Clin Rheumatol* 2014;33:1139-43. doi: 10.1007/s10067-013-2356-6.
- Siddiqui IA, Sabah SA, Satchithananda K, Lim AK, Cro S, Henckel J, *et al.* A comparison of the diagnostic accuracy of MARS MRI and ultrasound of the painful metal-on-metal hip arthroplasty. *Acta Orthop* 2014;85:375-82. doi: 10.3109/17453674.2014.908345.
- Birn J, Prunte R, Avram R, Eylar W, Mahan M, van Holsbeeck M. Sonographic evaluation of hip joint effusion in osteoarthritis with correlation to radiographic findings. *J Clin Ultrasound* 2014;42:205-11. doi: 10.1002/jcu.22112.
- Nazarian LN, Jacobson JA, Benson CB, Bancroft LW, Bedi A, McShane JM, *et al.* Imaging algorithms for evaluating suspected rotator cuff disease: Society of Radiologists in Ultrasound consensus conference statement. *Radiology* 2013;267:589-95. doi: 0.1148/radiol.13121947.
- Nazarian LN, Rawool NM, Martin CE, Schweitzer ME. Synovial fluid in the hindfoot and ankle: Detection of amount and distribution with US. *Radiology* 1995;197:275-8. doi: 10.1148/radiology.197.1.7568837.
- Mandl P, Brossard M, Aegerter P, Backhaus M, Bruyn GA, Chary-Valckenaere I, *et al.* Ultrasound evaluation of fluid in knee recesses at varying degrees of flexion. *Arthritis Care Res (Hoboken)* 2012;64:773-9. doi: 10.1002/acr.21598.
- Morrison JL, Kaplan PA. Water on the knee: Cysts, bursae, and recesses. *Magn Reson Imaging Clin N Am* 2000;8:349-70.
- Tschirch FT, Schmid MR, Pfirrmann CW, Romero J, Hodler J, Zanetti M. Prevalence and size of meniscal cysts, ganglionic cysts, synovial cysts of the popliteal space, fluid-filled bursae, and other fluid collections in asymptomatic knees on MR imaging. *AJR Am J Roentgenol* 2003;180:1431-6. doi: 10.2214/ajr.180.5.1801431.
- Vahlensieck M, Linneborn G, Schild HH, Schmidt HM. Magnetic resonance imaging (MRI) of the bursa around the knee joint. *Rofo* 2001;173:195-9. doi: 10.1055/s-2001-11599.
- Aydingoz U, Oguz B, Aydingoz O, Comert RB, Akgun I. The deep infrapatellar bursa: Prevalence and morphology on routine magnetic resonance imaging of the knee. *J Comput Assist Tomogr* 2004;28:557-61. doi: 10.1097/00004728-200407000-00020.
- Viegas FC, Aguiar RO, Gasparetto E, Marchiori E, Trudell DJ, Haghghi P, *et al.* Deep and superficial infrapatellar bursae: Cadaveric investigation of regional anatomy using magnetic resonance after ultrasound-guided bursography. *Skeletal Radiol* 2007;36:41-6. doi: 10.1007/s00256-006-0142-0.
- Labropoulos N, Shifrin DA, Paxinos O. New insights into the development of popliteal cysts. *Br J Surg* 2004;91:1313-8. doi: 10.1002/bjs.4635.
- Rupp S, Seil R, Jochum P, Kohn D. Popliteal cysts in adults. Prevalence, associated intraarticular lesions, and results after arthroscopic treatment. *Am J Sports Med* 2002;30:112-5. doi: 10.1097/00013644-200209000-00026