

# Comparison of Midface Advancement by External and Internal Craniofacial Distraction Osteogenesis

S. M. Balaji, Preetha Balaji

Department of Oral and Maxillofacial Surgery, Balaji Dental and Craniofacial Hospital, Chennai, Tamil Nadu, India

## Abstract

**Background:** Distraction osteogenesis (DO) is employed to address the midface abnormalities using either an external DO (EDO) or an internal DO (IDO) device. There are few studies that have reported EDO and IDO outcomes through cephalometric evaluation. The aim of this retrospective, record-based study is to compare the change in position of the midface resulting from distraction of noncomplicated cases of Le Fort III osteotomies with EDO as well as IDO and compare the groups using standard right facing lateral cephalometry. We hypothesized that there would be no difference between EDO and IDO in terms of displacement (of point of reference) as well as complications. **Materials and Methods:** Retrospective analyses of cases fulfilling inclusion and exclusion criteria were retrieved from archives. Using two sets of right-side cephalometry, preoperative and after consolidation (at the end of the treatment), the changes in Point A and Orbitale (O) as described by Lima *et al.* were used for the study. Movement in X-axis and Y-axis was noted down and subjected to statistical analysis. Descriptive statistics, the coefficient of variability (expressed as percentage), and the interquartile range (maximum and minimum values) were presented.  $P \leq 0.05$  was taken as statistically significant. **Results:** Significant midface advancement was achieved with the procedure. There were five cases of EDO and eight cases of IDO. The age at which patients were operated ranged from 9 to 18 years (mean: 13 years). The mean follow-up time was for  $14 \pm 8$  months. There were eight females (3 – EDO and 5 – IDO) and five males in total. There was no complication in the entire study group. The difference in total bone length gain along the horizontal axis was as follows: 12.19 and 12.84 along the Point A for EDO and IDO and 3.89 and 4.65 along the Point O for EDO and IDO, respectively. The difference was not statistically significant ( $P = 0.833$  and  $0.622$ , respectively). The total movement along the vector at Point A in EDO and IDO was 13.08 and 12.56, respectively, the difference of which was not statistically significant ( $P = 1$ ); while along the vector at Point O in EDO and IDO, the total movement was 10.98 and 11.48, respectively, the difference of which was not again statistically significant ( $P = 0.833$ ). **Discussion:** The significance of the difference in EDO and IDO is discussed using the biomechanical principles and the results deliberated based on the existing literature. **Conclusion:** The positioning of the devices plays a significant role in deciding the outcome. Both the distractors have their distinct advantages and their applications have to be customized.

**Keywords:** Craniofacial syndromes, craniofacial synostosis, external distraction osteogenesis, internal distraction osteogenesis

## INTRODUCTION

Midfacial deficiency is a part of many craniofacial anomalies. There are scores of syndromes with midface hypoplasia that often concomitantly presents with synostosis, ophthalmic abnormalities, malocclusion, facial asymmetry, and sleep apnea. Although most commonly a part of syndromes such as Crouzon, Apert, Pfeiffer, Saethre–Chotzen, and Carpenter syndromes, they can occur sporadically.<sup>[1-3]</sup> In either cases, the underlying developmental pathology is observed to be stunted maxillary growth that often stems from hypoplasia. The success of the treatment of the condition lies in establishment of early diagnosis and instituting early treatment. The earlier the midfacial growth is surgically corrected monitored for coordinated growth, more stable the results. The timing of these

kinds of surgery is crucial and when the growth potential could be harnessed.<sup>[4]</sup>

Distraction osteogenesis (DO) is a method that encourages the body to form its own bones and associated tissues such as blood vessels and nerves. It has been demonstrated to be a very novel and useful technique for the correction of skeletal anomalies. It was evolved for long and straight bones, mainly of limbs. The concept and treatment was pioneered by Codivilla and Ilizarov

**Address for correspondence:** Dr. S. M. Balaji,  
Balaji Dental and Craniofacial Hospital, 30, KB Dasan Road, Teynampet,  
Chennai - 600 018, Tamil Nadu, India.  
E-mail: [smbalaji@gmail.com](mailto:smbalaji@gmail.com)

### Access this article online

Quick Response Code:



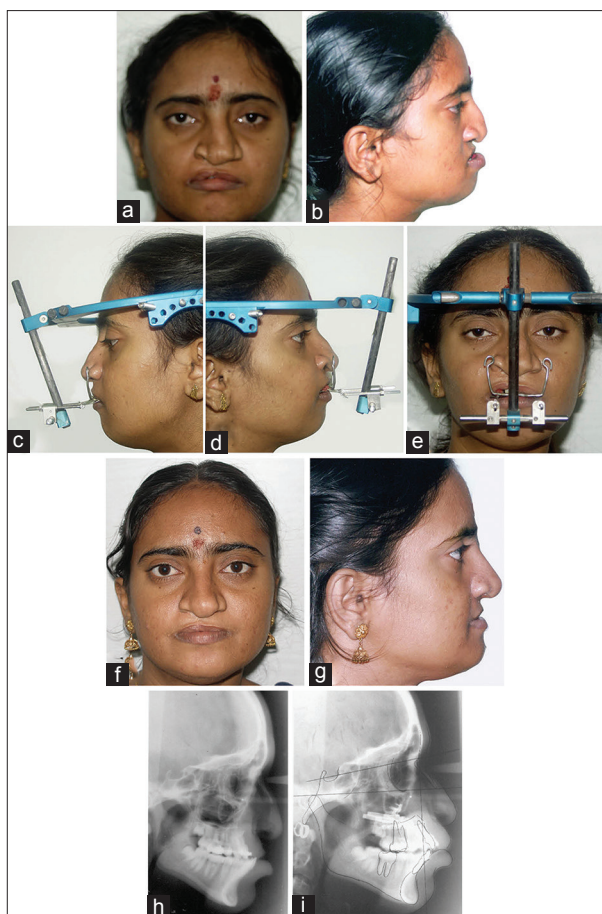
Website:  
[www.amsjournal.com](http://www.amsjournal.com)

DOI:  
10.4103/ams.ams\_234\_18

This is an open access journal, and articles are distributed under the terms of the Creative Commons Attribution-NonCommercial-ShareAlike 4.0 License, which allows others to remix, tweak, and build upon the work non-commercially, as long as appropriate credit is given and the new creations are licensed under the identical terms.

**For reprints contact:** [reprints@medknow.com](mailto:reprints@medknow.com)

**How to cite this article:** Balaji SM, Balaji P. Comparison of midface advancement by external and internal craniofacial distraction osteogenesis. *Ann Maxillofac Surg* 2018;8:200-5.

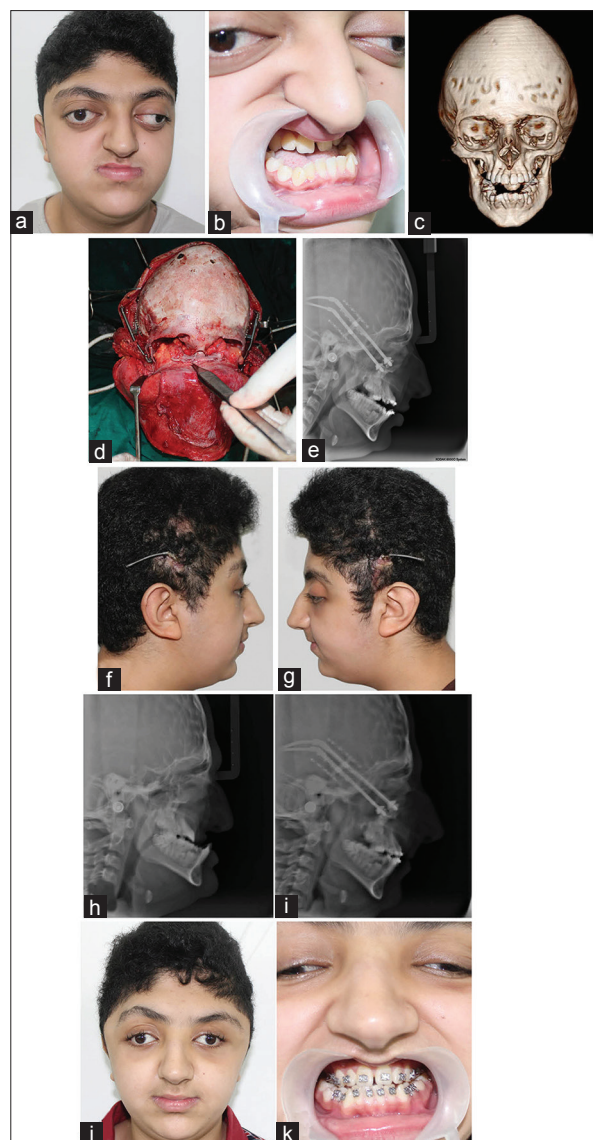


**Figure 1:** External distraction: (a) preoperative frontal view, (b) preoperative right lateral view, (c) Left view after fixation of halo-type rigid external distraction system (RED II), (d) right lateral view after external distractor fixation, (e) frontal lateral view after external distractor fixation, (f) posttreatment frontal view, (g) posttreatment right lateral view, (h) preoperative right lateral cephalogram, and (i) posttreatment right lateral cephalogram

for long bones.<sup>[5,6]</sup> Later, it was McCarthy *et al.* adapted the concept to the mandibular lengthening. Following this, DO was used for craniofacial reconstructions.<sup>[7]</sup>

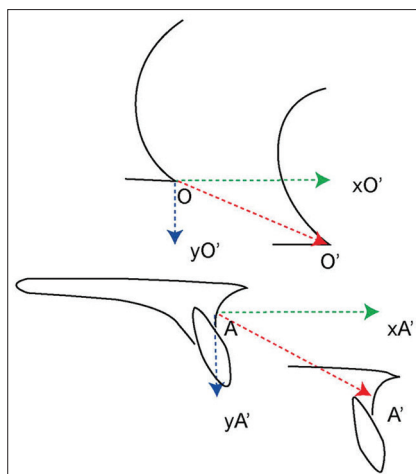
With deeper understanding as well as technical advancements, DO is now used for correcting anatomically complex bones including those of the cranium.<sup>[1,8]</sup> As compared to standard plate fixation after a traditional advancement Le Fort III osteotomy, DO has distinct advantage of allowing both further advancement and improved long-term stability. Furthermore, the less amount of plates, need of grafts, donor-site morbidity, and nondisturbance of midfacial growth are some added advantages.<sup>[1,8]</sup> The DO comes in two forms – the external DO (EDO) and internal DO (IDO) variants, depending on the place where the distractor is positioned. If it is internally placed (inside the oral cavity), then it is internal. Each system has its own advantages and disadvantages.<sup>[1,8]</sup>

EDO is reported to facilitate and utilize multiple fixations, directions, and orientations which ensured enhanced control of



**Figure 2:** Internal distraction: (a) preoperative frontal view, (b) a view of the preoperative crossbite, (c) preoperative three-dimensional computed tomography scan of the skull, (d) intraoperative view during Kawamoto internal distractor fixation, (e) postoperative lateral cephalogram during distraction treatment. (f) lateral view showing exposed part of internal distractor device on the right side, (g) lateral view showing exposed part of internal distractor device on the left side, (h) preoperative lateral cephalogram, (i) lateral cephalogram after completion of distraction treatment. (j) posttreatment frontal view of patient's face, and (k) a view of the posttreatment bite with ongoing orthodontic treatment

vectors of forces. Resultantly, the surgeon has multidirectional control of the midface position during the activation stage. On the other hand, the EDO utilizes an external apparatus, which is often placed for weeks or months together causing immense challenge in terms of quality of life during the entire procedure. The IDO has a distinct advantage of being innocuous, having less intrusion on the quality of life during the treatment. Furthermore, being small and unidirectional, the control over the vector is limited and might require a series of IDO placements for bringing in complex bone regenerations.



**Figure 3:** Shift of the Orbitale "O" and Point "A;" X indicates movement along X-axis and Y indicates movement in Y-axis. O' and A' are the new position of Orbitale and Point A at the immediate postoperative and after completion of distraction osteogenesis

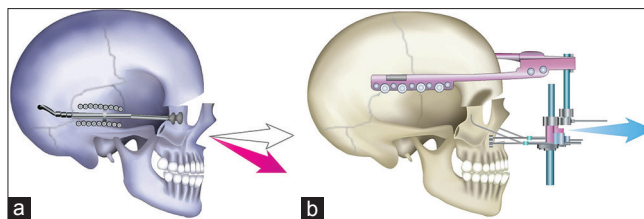
This often results in increased number of procedures or revision procedures.<sup>[1,3,8,9]</sup>

The mechanism of movement of the midface during post-DO after Le Fort III osteotomy has been studied. However, there are only very few studies that compare the effect of anatomical displacement characteristics of the EDO and IDO after Le Fort III osteotomies.<sup>[8-11]</sup> The aim of this retrospective, record-based study is to compare the change in position of the midface resulting from distraction of noncomplicated cases of Le Fort III osteotomies with EDO as well as IDO and compare the groups using standard right facing lateral cephalometry. We hypothesized that there would be no difference between EDO and IDO in terms of displacement (of point of reference) as well as complications.

## MATERIALS AND METHODS

This retrospective, record-based, descriptive study was done using data gathered from files and assessments of radiological examinations (lateral cephalometrics) done pre, immediate, and late postoperatively of patients who had symptomatic craniosynostosis with midface hypoplasia (involving maxilla, malar, and orbital bones) who needed DO procedure with Le Fort III type osteotomy using either an EDO or IDO device at the authors' institute between 2008 and 2015. Patients with incomplete records, complex craniofacial deficiencies and other systemic disorders that could affect bone metabolism were excluded from the study. Procedures that warranted complex, multistaged DO procedures, or needed grafts were also excluded from this study. All the patients were operated by the author. The cases included Apert, Crouzon syndromes and patients having midfacial deficiencies.

Only patients with significant, yet simple, facial alterations with midface skeletal hypoplasia, Angle Class III malocclusion, and



**Figure 4:** Schematic movement of midface in external distractor and internal distractor

lower orbital rim abnormalities were included in this study. Patients have been treated with either EDO or IDO as per the case requirement and individual preferences.

## Surgical procedures

In EDO group, halo-type rigid external distraction system (RED II, KLS Martin, Muhlheim, Germany) was used. After standard preparation under general anesthesia, a conventional standard Le Fort III osteotomy was performed.<sup>[12]</sup> It was ensured that the instrument was aligned parallel to the Frankfort horizontal (FH) plane as much as possible, and four fixation pins were engaged bilaterally along the temporal region. The EDO's horizontal cross-bar assembly was placed approximately at the level of the upper lip. The fixation arms were engaged and secured through the skin along the lateral piriform rim on each side. A 24-gauge wire was used to connect the fixation posts to the cross-bar assembly, as instructed by manufacturer, twisted just until there was sufficient tension. Additional wires were passed as necessary with an awl from the cross-bar assembly transorally through the buccal vestibule to the zygomaticofrontal osteotomy and attached to the lateral orbital rim by looping through a small drill hole and twisted until needed tension was achieved. The EDO was further secured in this position with four fixation pins bilaterally in the temporal region. Care should be taken during the positioning and placement of vertical component of the cross-bar assembly as that would alter the distraction vector and also influence the soft-tissue forces [Figure 1a-i].

In IDO group, a standard Le Fort III was performed through the coronal approach (to avoid scar).<sup>[12]</sup> Bilaterally, the temporalis muscle was partially elevated to facilitate internal distractor placement (Kawamoto Midface Distractor, KLS Martin), posterior part positioned as much as parallel to the standard FH plane. The anterior part of the device footplate was positioned as per the patient orbital morphology, secured just nearer to the bony part of the lateral orbital rim, just 1 cm below the zygomaticofrontal osteotomy. Owing to difference in the midfacial morphology, the anterior footplate may not be in parallel to FH plane. The plates were further secured with two 6-mm screws on both sides. The posterior plates were secured to the temporal bones with six 6-mm screws bilaterally [Figure 2a-k].

In both the EDO and IDO, the incisions were closed after checking the devices as per standard procedure.<sup>[12]</sup> Appropriate standard of care and pharmacotherapeutics instituted to control pain and swelling and to prevent infection. A 5-day latency period for EDO and IDO was allowed after which the device was activated at the

recommended rate of 1 mm/day until the occlusion and desired frontal profile were achieved. Overcorrection to accommodate relapse during consolidation phase was performed. The EDO/IDO devices remained in place up to 12 weeks (about 3 months time) weeks to ensure completion of consolidation.

In all, at least two sets of right-side cephalometry, using the same machine (Somatom Emotion, 6 slices, Model 1065880, Siemens. Shanghai, China), were obtained, first one preoperative and after consolidation (at the end of the treatment). The same operator performed all cephalometric tracings. Standard, manual tracings were performed. The anatomical landmarks of the anterior portion of the cranial base were traced in each of the cephalograms, and using total structural cephalometric superposition method, they were superimposed into single tracing. The anatomic landmarks used were anterior border of the sella turcica, the optic canal, the superior aspect of the sphenoid bone body, the sphenothmoidal suture, and the horizontal portion of the inner cortex of the frontal bone, which were used as superposition parameters. The method used by Lima *et al.* was used for the study.<sup>[8]</sup> A vertical reference line (true vertical line) was then marked to the tracing for reference. Using this, Point A (most posterior point of the concavity of the anterior surface of the maxillary alveolar process) and Point O (orbit point-intersection point between the border of the orbit floor and the lateral orbit border) were identified. After consolidation, the same points were marked as A' and O'. The horizontal and vertical extensions were marked as  $A_x$ ,  $O_x$ ,  $A_x'$ ,  $O_x'$  and  $A_y$ ,  $O_y$ ,  $A_y'$ ,  $O_y'$ , respectively. The difference between the total bone length gain along the horizontal (X-axis:  $A_x' - A_x$ ;  $O_x' - O_x$ ) and vertical axis (Y-axis:  $A_y' - A_y$ ;  $O_y' - O_y$ ) and resulting bone gain length along the movement vector was then calculated for the Points A and O ( $A' - A$ ;  $O' - O$ ) [Figure 3].

All data were entered and analyzed using the Statistical Package for the Social Service (version 16; IBM, IL, USA). Descriptive statistics of the mean  $\pm$  standard deviation, the coefficient of variability (expressed as percentage), and the interquartile range (maximum and minimum values) were presented. Depending on the normality as determined by the Shapiro–Wilk test, normal distribution was assessed to find an association among variables. Spearman's correlation was applied when the distribution was not normal.  $P \leq 0.05$  was taken to be statistically significant.

## RESULTS

In all, 13 cases fulfilled the criteria and were considered for the study. There were five cases of EDO and eight cases of IDO. The age at which patients were operated ranged from 9 to 18 years (mean: 13 years). The mean follow-up time was for  $14 \pm 8$  months. There were eight females (3 – EDO and 5 – IDO) and five males in total. There was no complication in the entire study group. The entire EDO group had expressed at least some concern with the device during the course of treatment such as difficulty in sleeping and socializing that has been marked in the case records. On the contrary, there was no such complaint

in the IDO group. In all, a maximum total lengthening of the bone achieved was  $18.2 \text{ mm} \pm 2.8 \text{ mm}$  in the study population, with no significant difference between the EDO and IDO.

The difference in total bone length gain along the horizontal axis was as follows: 12.19 and 12.84 along the Point A ( $A_x' - A_x$ ) for EDO and IDO and 3.89 and 4.65 along the Point O ( $O_x' - O_x$ ) for EDO and IDO, respectively. The difference was not statistically significant ( $P = 0.833$  and  $P = 0.622$ , respectively). The difference in total bone length gain along the vertical axis was as follows: 4.65 and 3.89 along the Point A ( $A_y' - A_y$ ) for EDO and IDO and 3.4 and 3.0 along the Point O ( $O_y' - O_y$ ) for EDO and IDO, respectively. The difference was not statistically significant ( $P = 0.171$  and  $P = 0.724$ , respectively). The total movement along the vector at Point A in EDO and IDO was 13.08 and 12.56, respectively, the difference of which was not statistically significant ( $P = 1$ ); while along the vector at Point O in EDO and IDO, the total movement was 10.98 and 11.48, respectively, the difference of which was not again statistically significant ( $P = 0.833$ ) [Table 1].

The correlation tests revealed that the movement along the X-axis and Y-axis or the vector movements were not statistically significant. While the trend was similar in Y-axis and vector movement, X-axis was much less for IDO as compared to EDO [Table 2].

## DISCUSSION

Several studies have shown that the treatment for midfacial hypoplasia in syndromic craniosynostosis patients produces limited results.<sup>[8]</sup> Conventional Le Fort III osteotomy (CLFO) with advancement alone does not warrant long-term results, owing to the soft-tissue resistance. In addition, the CLFO would necessitate the bone grafts to fill in the space, if created. Treatment with CLFO may need advancement up to 24 mm which is often higher than the upper limit of the advancement provided by CLFO without the risk of soft-tissue discrepancies or potential long-term failures. When DO was supplemented with CLFO, as in the present study, the results were stable and better, as new soft-vascularized soft-tissues were formed along with bone. This resulted in long-term stable results.<sup>[13-17]</sup> A systematic review has reported that CLFO with DO often has the best amount of bone formation.<sup>[18]</sup> In addition, the use of CLFO and DO would help to initiate or concurrently employ orthodontic treatments if situation demands.

Previous works published by Fearon, Shetye *et al.*, Holmes *et al.*, Iannetti *et al.*, Denny *et al.*, Gosain *et al.*, and Tunçbilek *et al.* have shown that CLFO by EDO or IDO has produced necessary advancement at the end of the treatment.<sup>[19-24]</sup> In the present study too, the bone length gained was in the range of  $18.2 \pm 2.8$  and comparable to those reported in literature. The inconsistencies in reporting, implications of random sampling, and large variation in the distribution are pointed out earlier by Lima *et al.* extensively.<sup>[8]</sup>

In the present study, the vertical displacement (i.e., along Y-axis) was lower than horizontal component (X-axis). Complex hypoplasia exists heterogeneously in three dimensions; clinically,

**Table 1: Difference between the Points A and O in X-axis and Y-axis changes in preoperative and immediate postoperative (after consolidation) values in the study group**

	External distractors (n=5)					Internal distractors (n=8)					P
	Mean±SD	Maximum	Minimum	IQR	CV%	Mean±SD	Maximum	Minimum	IQR	CV%	
A <sub>x</sub> -A <sub>x</sub> '	12.19±4.45	18.00	7.80	8.65	36.53	12.84±5.7	21	4.5	10.5	44.35	0.833
A <sub>y</sub> -A <sub>y</sub> '	3.89±3.52	6.35	-2.3	4.78	90.36	4.65±5.06	8.6	-4.5	8	108.86	0.171
A-A'	13.08±3.64	18.7	9.0	6.25	27.82	12.56±2.43	15.6	8.7	4.35	19.38	1
O <sub>x</sub> -O <sub>x</sub> '	9.4±3.7	13.2	4.3	6.95	39.38	8.93±4.08	15.6	3.8	7.3	45.69	0.622
O <sub>y</sub> -O <sub>y</sub> '	3.4±4.6	7.8	-4.2	12	135.19	3.0±5.3	7.9	-3.3	10	175.21	0.724
O-O'	10.98±2.69	14.5	7.8	5.1	24.50	11.48±3.37	16.9	7.6	5.95	29.36	0.833

IQR=Interquartile range; CV=Coefficient of variability; SD=Standard deviation

**Table 2: Correlation within the corresponding variables**

Correlation	External distractors		Internal distractors	
	Spearman Rho	P	Spearman Rho	P
A <sub>x</sub> -O <sub>x</sub>	-0.526	0.36	-0.700	0.19
A <sub>y</sub> -O <sub>y</sub>	-0.33	0.59	-0.300	0.62
A-O	0.21	0.74	0.19	0.75

most of the abnormalities are perceived and attributed to horizontal abnormalities.<sup>[8]</sup> This forces the surgeons to address the horizontal component more than the vertical component and becomes the goal of the surgery. Such observation has been made by several authors including Lima *et al.*, Cedars, and Shetye *et al.*<sup>[8-11,13]</sup> The present results are in agreement with their observations. Sagittal plane advancement is widely studied in the literature. Shetye *et al.*, 2009, reported that often for an ideal CLFO, the center of resistance would be at the 55% of the distance from the occlusal plane to nasion and parallel to the maxillary occlusal plane.<sup>[1,10]</sup> A force applied along this area would result in translation, whereas any other force above or below would result in rotation (clockwise or anticlockwise, respectively). This may collapse the final result and later the stability as well as esthetics.<sup>[1,10]</sup>

Stable bone length gain was achieved with DO as they are technically adapted to gradually lengthen soft tissues, thereby overcoming their resistance.<sup>[8]</sup> The newly formed orthotopic bone has been described to be superior to bone grafts. Stability has been analyzed in published studies using clinical parameters. Only few studies have used reliable and measurable indicators such as cephalometry values.<sup>[8]</sup> Although with inherent nature of certain bias, including reproduction bias, these studies often provide insights on how the movements are affected. In this study, we proceeded to assess the change of Point A (in maxilla) and Orbitale. The aim was to identify the difference in these points in the EDO and IDO.

In this present study, the relationship of vectors, direction of rotation, and center of resistance was not studied in detail, as it was a retrospective study. However, the extent and spectrum of clinical presentation were only accounted and correlated. The parameters studied were accepted norms for similar studies and have been used to study the CLFO previously by Lima *et al.* and that of Robertson *et al.*<sup>[1,8]</sup>

As shown in the results and table, the normal vector of force, irrespective to the center of resistance of the midface, when applied, IDO would lead to more inferior displacement of the Le Fort III segment and thus less pure horizontal advancement, while the EDO would lead to less inferior displacement of segment with more horizontal advancement. This is consistent with the previous findings of by Lima *et al.* and that of Robertson *et al.*<sup>[1,8]</sup> However, EDO is reported to allow more flexibility and customization of vectors during distraction. This is achieved by altering the points of fixation, modifying cross-bar assembly on the frame, and differential activation. This can be passively harnessed even during consolidation phase.

It has been reported by Robertson, 2018, that the standard positioning of EDO often delivers a horizontal force closer to the center of resistance of the midface which would result in more horizontal advancement, while standard IDO would deliver the horizontal force above the center of resistance creating clockwise rotation leading to inferior displacement and reducing the horizontal advancement [Figure 4].<sup>[8]</sup> In the present study, it has been observed that for the cases included, the inferior displacement and vertical height gained were more for IDO, while there was no greater difference in terms of horizontal shift of the Points O and A. As the Robertson *et al.* studies were based on elderly formalin-fixed cadavers and nonconsideration of the functional component as well as nonregeneration of soft-tissue components during DO, comparison of the results is not equal and cogent. Theoretically, IDO could produce changes in horizontal as well as vertical dimension, while EDO causes only in horizontal direction. The results of the present studies show that the difference in dimensions (X-axis, Y-axis, and total movement) is not statistically significant.

In the present study, as there is no statistical significance between the IDO and EDO in terms of shift of the A'-A and O'-O, the total length gain is not statistically significant. As the X- and Y-coordinates also do not show any significance, it can be conveniently concluded that for this sample, when there are no complexities in CLFO cases, EDO and IDO nearly produce identical results. The hardships of having the rigid frames for EDO drastically compromising social and physical hardships can be negated by the use of IDO. Based on the presented results, it can be safely inferred that for the present group of straightforward midfacial hypoplasia in symptomatic

craniosynostosis cases, with little or no complexities, the IDO is better than EDO as there is no statistically significant advantage in the X-axis and Y-axis movements.

As there were no previous studies in this direction to support or refute the findings, more studies are needed to establish the findings of the results of the present study. However, comparison with previous pertinent literature identifies that the complexity of the case, accuracy in determination of center of resistance, and the placement of vector – above or below or along the plane of resistance – can effectively harness the principles of vectors effectively.<sup>[1,8]</sup> The present study also highlights the need for more studies in this direction, using large case numbers with variety of cases involving many centers as well as time points. Future studies also need to study the postsurgery growth patterns in such cases. The retrospective nature of study design prevented inclusion of factors in the present study.

To summarize, in terms of the horizontal, vertical vectors and total displacement of Points O and A, for simple midfacial hypoplasia cases, no much advantage is achieved by the use of EDO. If complex vectors are needed to correct the midfacial deficiency, EDO offers better accuracy, prediction of vectors, and numerous possibilities, while IDO offers only limited choices. Given the hardships associated with EDO, for simple midfacial hypoplasia cases that lack only horizontal measurement discrepancies, IDO offers a distinct advantage for ease of handling and better quality of life.

## CONCLUSION

The study shows that DO after CLFO with EDO or IDO has no observable difference in terms of gain in bone length. However, proper identification of desired postoperative position of Points A and O will help the surgeon to choose the best device and plan the treatment effectively. The positioning of the devices plays a significant role and it is this crucial step that the surgeon's prior experience and knowledge has a definite role to play. The consolidation phase is long (about 3 months) for both devices. EDO devices, as compared to IDO, poses multiple challenges during this period. In younger patients, especially of school going age, IDO would be much easier than EDO. In terms of quality of life, IDO is advantageous than EDO.

## Declaration of patient consent

The authors certify that they have obtained all appropriate patient consent forms. In the form the patient(s) has/have given his/her/their consent for his/her/their images and other clinical information to be reported in the journal. The patients understand that their names and initials will not be published and due efforts will be made to conceal their identity, but anonymity cannot be guaranteed.

## Financial support and sponsorship

Nil.

## Conflicts of interest

There are no conflicts of interest.

## REFERENCES

- Robertson KJ, Mendez BM, Bruce WJ, McDonnell BD, Chiodo MV, Patel PA, *et al*. Le fort III distraction with internal vs. external distractors: A cephalometric analysis. *Cleft Palate Craniofac J* 2018;55:721-7.
- Tahiri Y, Taylor J. An update on midface advancement using le fort II and III distraction osteogenesis. *Semin Plast Surg* 2014;28:184-92.
- Shetye PR, Davidson EH, Sorkin M, Grayson BH, McCarthy JG. Evaluation of three surgical techniques for advancement of the midface in growing children with syndromic craniosynostosis. *Plast Reconstr Surg* 2010;126:982-94.
- Fearon JA. Halo distraction of the le fort III in syndromic craniosynostosis: A long-term assessment. *Plast Reconstr Surg* 2005;115:1524-36.
- Codivilla A. On the means of lengthening, in the lower limbs, the muscles and tissues, which are shortened through deformity. *Am J Orthop Surg* 1904;2:353-69.
- Ilizarov GA: Tension-stress effect on the genesis and growth of tissues: II. The influence of the rate and frequency of distraction. *Clin Orthop* 1989;239:249-80.
- McCarthy JG, Schreiber J, Karp N, Thorne CH, Grayson BH. Lengthening the human mandible by gradual distraction. *Plast Reconstr Surg* 1992;89:1-8.
- Lima DS, Alonso N, Câmara PR, Goldenberg DC. Evaluation of cephalometric points in midface bone lengthening with the use of a rigid external device in syndromic craniosynostosis patients. *Braz J Otorhinolaryngol* 2009;75:395-406.
- Shetye PR, Grayson BH, McCarthy JG. Le fort III distraction: Controlling position and path of the osteotomized midface segment on a rigid platform. *J Craniofac Surg* 2010;21:1118-21.
- Shetye PR, Giannoutsos E, Grayson BH, McCarthy JG. Le fort III distraction: Part I. Controlling position and vectors of the midface segment. *Plast Reconstr Surg* 2009;124:871-8.
- Shetye PR, Boutros S, Grayson BH, McCarthy JG. Midterm follow-up of midface distraction for syndromic craniosynostosis: A clinical and cephalometric study. *Plast Reconstr Surg* 2007;120:1621-32.
- Balaji SM. *Clinical Cranio Maxillofacial Surgery*. 1<sup>st</sup> ed. Elsevier: New Delhi, India; 2017. p. 196-8.
- Cedars MG, Linck DL 2<sup>nd</sup>, Chin M, Toth BA. Advancement of the midface using distraction techniques. *Plast Reconstr Surg* 1999;103:429-41.
- McCarthy JG, Glasberg SB, Cutting CB, Epstein FJ, Grayson BH, Ruff G, *et al*. Twenty-year experience with early surgery for craniosynostosis: II. The craniofacial synostosis syndromes and pansynostosis – Results and unsolved problems. *Plast Reconstr Surg* 1995;96:284-95.
- Toth BA, Kim JW, Chin M, Cedars M. Distraction osteogenesis and its application to the midface and bony orbit in craniosynostosis syndromes. *J Craniofac Surg* 1998;9:100-13.
- Chin M, Toth BA. Le fort III advancement with gradual distraction using internal devices. *Plast Reconstr Surg* 1997;100:819-30.
- Fearon JA, Patel N. Treatment of the syndromic midface with rigid external distraction Le sFort III: A long-term assessment at skeletal maturity. *Plast Reconstr Surg* 2014;133:973.
- Saltaji H, Altalibi M, Major MP, Al-Nuaimi MH, Tabbaa S, Major PW, *et al*. Le Fort III distraction osteogenesis versus conventional Le Fort III osteotomy in correction of syndromic midfacial hypoplasia: A systematic review. *J Oral Maxillofac Surg* 2014;72:959-972.
- Fearon JA. The le fort III osteotomy: To distract or not to distract? *Plast Reconstr Surg* 2001;107:1091-103.
- Iannetti G, Fadda T, Agrillo A, Poladas G, Iannetti G, Filiaci F, *et al*. LeFort III advancement with and without osteogenesis distraction. *J Craniofac Surg* 2006;17:536-43.
- Holmes AD, Wright GW, Meara JG, Heggie AA, Probert TC. Le fort III internal distraction in syndromic craniosynostosis. *J Craniofac Surg* 2002;11:262-72.
- Denny AD, Kalantarian B, Hanson PR. Rotation advancement of the midface by distraction osteogenesis. *Plast Reconstr Surg* 2003;111:1789-99.
- Gosain AK, Santoro TD, Havlik RJ, Cohen SR, Holmes RE. Midface distraction following le fort III and monobloc osteotomies: Problems and solutions. *Plast Reconstr Surg* 2002;109:1797-808.
- Tunçbilek G, Mavili ME, Vargel I, Enacar A, Erk Y. Midface distraction using spring scale attached to rigid external device. *Plast Reconstr Surg* 2004;113:1410-6.