

Case Report

Idiopathic multiple retinal pigment epithelial detachments – A case report



Vivek Pravin Dave*; Rajeev R. Pappuru

Abstract

Retinal pigment epithelial detachment, often asymptomatic is a common retinal finding. Multiple serous retinal pigment epithelial detachment especially in a female is very uncommon. We describe a case of multiple retinal pigment epithelial detachments throughout the fundus in a 51-year old female otherwise asymptomatic. Indocyanine green angiography and fundus auto fluorescence showed abnormalities with a normal systemic work-up. This is the first report of an asymptomatic patient correlating angiogram with auto fluorescence in multiple serous retinal pigment epithelial detachments.

Keywords: Retinal pigment epithelial detachments, Asymptomatic, ICG, FFA, AF

© 2015 The Authors. Production and hosting by Elsevier B.V. on behalf of Saudi Ophthalmological Society, King Saud University. This is an open access article under the CC BY-NC-ND license (<http://creativecommons.org/licenses/by-nc-nd/4.0/>).
<http://dx.doi.org/10.1016/j.sjopt.2015.05.006>

Introduction

Single or multiple retinal pigment epithelial detachments (RPED) are seen in various conditions such as central serous chorioretinopathy (CSCR), age related macular degeneration, polypoidal choroidal vasculopathy, Vogt–Koyanagi–Harada disease, systemic hypercortisolism, renal disorders, malignant hypertension and in acute leukemias.^{1–4} Though often associated with an underlying disorder, multiple RPEDs can sometimes be associated with a normal ocular and systemic status.^{5–7} We describe a case of multiple serous RPEDs in a female otherwise asymptomatic. To the best of our knowledge this is the first report of multiple RPED documented indocyanine green angiogram and corresponding fundus autofluorescence.

Case report

A 51-year old female presented to us with complaints of mild itching in both eyes since the last 2 weeks. Best corrected visual acuity in the right eye was 20/20. The left eye

was phthisical due to ocular trauma in childhood and had no perception of light. On examination, the intraocular pressure was 14 mmHg in the right eye with a normal anterior segment examination. Fundus examination revealed multiple orangish well circumscribed elevations at the level of the retinal pigment epithelium extending from the macula till almost the ora serrata, consistent with RPEDs. Indocyanine green angiography done showed mildly hyperfluorescent lesions with a hypofluorescent halo largely similar in the early and late phases. Fundus autofluorescence showed multiple circumscribed hyper autofluorescent lesions corresponding to the pigment epithelial detachments. Near-infrared reflectance imaging showed isoreflexive lesions corresponding to the RPEDs surrounded by a hypo reflective halo as shown in the previous literature.⁸ The left eye was phthisical with no perception of light with a history of trauma to the eye in childhood. Ultrasound B scan revealed closed funnel retinal detachment in the left eye. Detailed ocular and systemic history was taken to rule out any ocular or systemic illness. A complete blood count, erythrocyte sedimentation rate, angiotensin converting enzyme, anti nuclear antibodies,

Received 28 July 2014; received in revised form 15 April 2015; accepted 11 May 2015; available online 19 May 2015.

Smt. Kanuri Santhamma Center for Vitreo Retinal Diseases, LV Prasad Eye Institute, Hyderabad, India

* Corresponding author. Tel.: +91 7680859900.
e-mail address: vivekoperates@yahoo.co.in (V.P. Dave).



Peer review under responsibility of Saudi Ophthalmological Society, King Saud University



Production and hosting by Elsevier

Access this article online:
www.saudiophthaljournal.com
www.sciencedirect.com

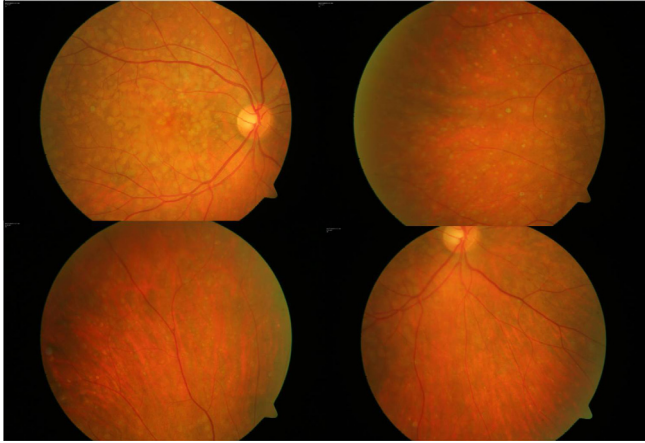


Figure 1. Fundus photograph showing multiple retinal pigment epithelial detachments on the posterior pole and the peripheral fundus.

Mantoux test, chest X-ray and serum lipid levels were done which were all within normal limits. The ocular findings remained the same at the last follow up 6 months later (see Figs. 1–5).

Discussion

Isolated serous RPEs are often found in healthy asymptomatic individuals.^{9,10} Idiopathic multiple serous RPEs though are uncommon, Gass et al.⁵ reported similar cases with normal visual acuity (20/20). Fundus fluorescein angiography and OCT showed no evidence of CNVM. Goncu et al.⁶ reported two cases with multiple RPEs who otherwise had a normal systemic and ocular examination except that one of the cases had a hemorrhagic RPE at the fovea in the left eye. Yi et al.¹¹ reported a case of multiple RPE in a young woman with multiple RPEs and associated sub retinal hemorrhage with one RPE. Both FFA and ICG were done which showed no evidence of CNVM. Klein et al.¹² had reviewed data of serous RPEs in young patients without associated fundus pathology. The study found no incidence of CNVM or secondary complications in those cases. Roberts and Haine¹³ showed a correlation of multiple RPE with psychological stress similar to CSCR.

It may be postulated that idiopathic multiple serous retinal detachment may be a variant of CSCR. On fundus fluorescein angiography, RPEs show a pooling phenomenon wherein there is an increase in the intensity of the fluorescence in the successive frames without an increase in size. OCT shows

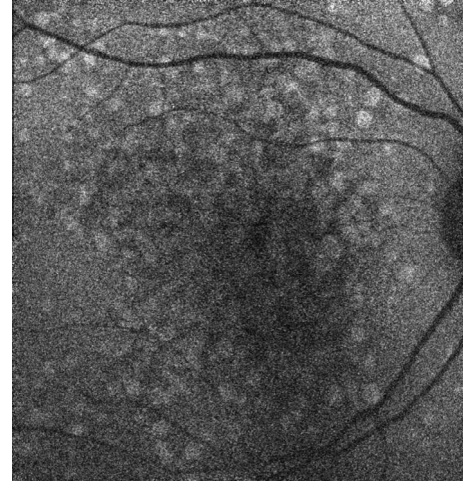


Figure 3. Fundus autofluorescence image showing multiple circumscribed hyper autofluorescent lesions corresponding to the pigment epithelial detachments.

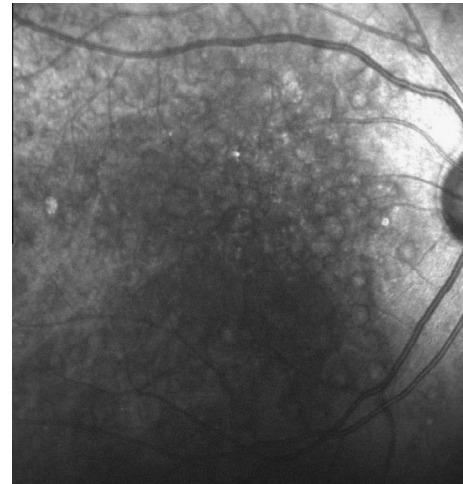


Figure 4. Near infra red reflectance image of the multiple pigment epithelial detachments showing isorefective lesions corresponding to the RPEs surrounded by a hypo reflective halo.

a dome shaped elevation of the RPE layer lining a hyporeflective space. ICG angiography shows both hypofluorescent and hyperfluorescent lesions corresponding to the RPEs. This is consistent with the ICG findings of serous RPE as described

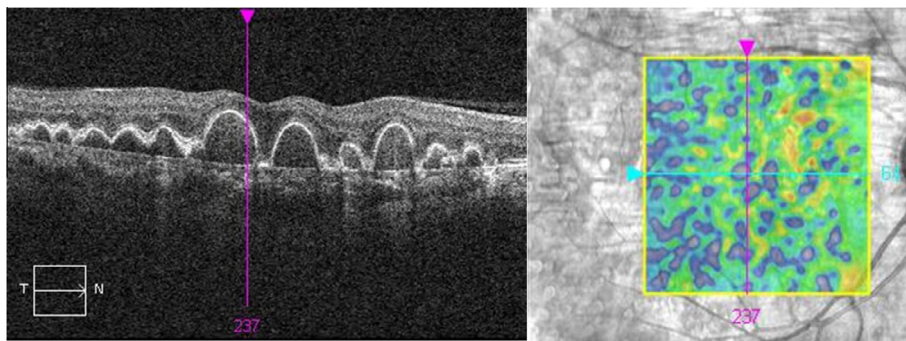


Figure 2. OCT showing multiple pigment epithelial detachments as dome shaped elevations of the RPE with few intervening drusens seen as hyper reflective elevations.

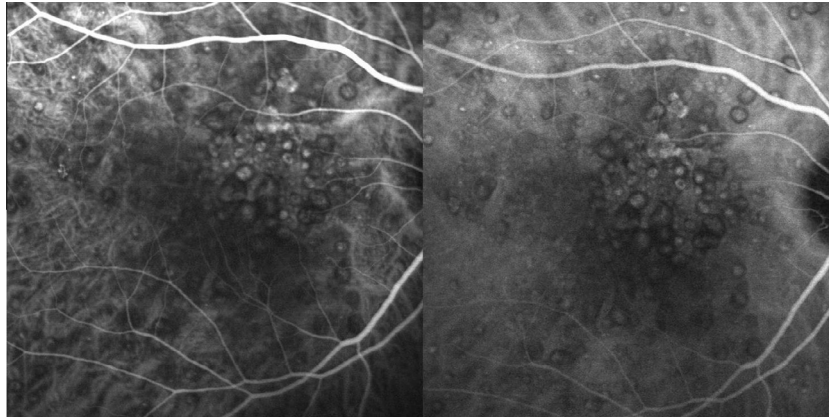


Figure 5. Fundus indocyanine green angiography of the multiple pigment epithelial detachments showing typically both hypofluorescent and hyperfluorescent lesions.

previously.^{14,15} Unlike RPED associated with age related macular degeneration, RPED associated with CSCR develops CNVM uncommonly. The exact cause of multiple RPED as well as the natural history is not known. These patients should undergo fundus fluorescein angiography as well as indocyanine green angiography to rule out the presence of an occult CNVM. As the pathology of serous RPED is known to be due to lipid deposition in the Bruch membrane, it may be useful to estimate the serum lipid levels in a case of multiple RPED.¹⁶ Currently no treatment is known to be of any particular significance for multiple serous RPED. If there is no associated CNVM and the visual acuity is preserved the patients may be followed up without any intervention.

The findings in our case were consistent with that in the literature. The patient was observed without any intervention. At the last follow up 6 months later, the visual acuity was noted to be 6/6, N6 to the best of our knowledge, this is the first case of idiopathic multiple RPED with autofluorescence documentation correlated with fundus fluorescein and indocyanine green angiography in an otherwise asymptomatic patient.

References

- Gass JDM. Pathogenesis of disciform detachment of the neuroepithelium. II. Idiopathic central serous choroidopathy. *Am J Ophthalmol* 1967;**63**:587–615.
- Yannuzzi LA, Freund B, Goldbaum M, et al. Polypoidal choroidal vasculopathy masquerading as central serous choroidopathy. *Ophthalmology* 2000;**107**:767–77.
- Wolfensberger TJ, Tufail A. Systemic disorders associated with detachment of the neurosensory retina and retinal pigment epithelium. *Curr Opin Ophthalmol* 2000;**11**:455–61.
- Tang RA, Vila-Coro AA, Wall S, et al. Acute leukemia presenting as a retinal pigment epithelial detachment. *Arch Ophthalmol* 1998;**106**:21–2.
- Gass JDM, Bressler SB, Akduman L, et al. Bilateral idiopathic multifocal PED in otherwise healthy middle-aged adults. *Retina* 2005;**25**:304–10.
- Goncu T, Ozdek S. Idiopathic multiple tiny serous retinal epithelial detachments: report of 2 cases and review of literature. *Optometry* 2011;**82**:556–62.
- Sawa M, Gomi F, Harino S, et al. Three dimensional optical coherence tomographic findings of idiopathic multiple serous retinal pigment epithelial detachment. *Arch Ophthalmol* 2005;**123**:122–3.
- Theelen T, Berendschot TJM, Hoyng CB, et al. Near-infrared reflectance imaging of neovascular age-related macular degeneration. *Graefes Arch Exp Ophthalmol* 2009;**247**:1625–33.
- Zayit-Soudry S, Moroz I, Loewenstein A. Retinal pigment epithelial detachment. *Surv Ophthalmol* 2007;**52**:227–43.
- Lewis ML. Idiopathic serous detachment of the retinal pigment epithelium. *Arch Ophthalmol* 1978;**96**:620–4.
- Yi C, Pan X, Russell S, et al. Diagnostic and therapeutic challenges. *Retina* 2006;**26**:688–92.
- Klein ML, Obertynski H, Patz A, et al. Follow-up study of detachment of the retinal pigment epithelium. *Br J Ophthalmol* 1980;**64**:412–6.
- Roberts DK, Haine CL. Idiopathic multiple serous detachments of the retinal pigment epithelium: a report of two cases. *J Am Optom Assoc* 1991;**62**:464–71.
- Baumal CR, Reichel E, Duker JS, et al. Indocyanine green hyperfluorescence associated with serous retinal pigment epithelial detachment in age-related macular degeneration. *Ophthalmology* 1997;**104**:761–9.
- Parodi M, Saviano S, Bondel E, et al. Hyperfluorescence associated with serous retinal pigment epithelial detachment on indocyanine green angiography. *Acta Ophthalmol Scand* 2000;**78**:443–7.
- Pauleikhoff D, Harper CA, Marshall J, Bird AC. Aging changes in Bruch's membrane: a histochemical and morphologic study. *Ophthalmology* 1990;**97**:171–8.