

## CASE REPORT

# Anti-programmed cell death-1 (PD-1) monoclonal antibodies involve reversible cranial dura matter

Hiroshi Kataoka<sup>\*,†</sup>, Daisuke Shimada, Hitoki Nanaura and Kazuma Sugie

Department of Neurology, Nara Medical University, Kashihara, Nara, Japan

\*Correspondence address. Department of Neurology, Nara Medical University 840 Shijo-cho, Kashihara, Nara 634-8522, Japan. Tel: +81-744-29-8860; Fax: +81-744-24-6065; E-mail: hk55@naramed-u.ac.jp

## Abstract

This case is the first document to describe a patient receiving anti-programmed cell death 1 (PD-1) antibodies which showed cranial dura matter involvement. According to the increasing use of anti-PD-1 monoclonal antibodies, adverse effects can occur in several organs since its ligand PD-L1 and PD-L2 are expressed in a wide variety of tissues. The estimated rate of neurological complications is 1–4.2% of patients, and neuromuscular disorders are the most common. Adverse effects on the central nervous system including encephalitis are less frequent. Here, a patient receiving anti-PD-1 antibodies showed cranial dura matter involvement, and the dura enhancement on MRI was resolved by withdrawal of the treatment with anti-PD-1 antibodies only.

## INTRODUCTION

The use of immune checkpoint inhibitors (ICPIs), including anti-programmed cell death-1 (PD-1) monoclonal antibodies, has been increasing for treating solid-organ tumors. Anti-PD-1 antibodies bind with its ligands, PD-L1 and PD-L2, and these antibodies maintain self-tolerance during chronic antigen stimulation by normally suppressing T-cell activation [1]. In the tumor microenvironment, tumors inhibit antitumor T-cell-mediated reactions by expressing the PD-L1 ligand, and the blockade of anti-PD-1 antibodies can initiate an antitumor immune response [2]. Although the balanced promotion and inhibition of T-cell activation is maintained to prevent the development of autoimmune diseases, anti-PD-1 antibodies can cause autoimmune adverse effects by producing unbalanced T-cell responses [3–5]. With the increasing use of ICPIs, adverse effects can occur in several organs where PD-L1 and PD-L2 are expressed. The estimated rate of neurological complications is 1–4.2%, and neuromuscular disorders are the most common. Adverse effects on the central nervous system (CNS), including encephalitis, are less frequent [3–6]. Most encephalitis associated with ICPIs show focal encephalitis. The magnetic resonance

imaging (MRI) pattern of nonfocal encephalitis is meningeal enhancement or multiple brain parenchyma hyperintensities [7]. Here, a patient receiving anti-PD-1 antibodies exhibited cranial dura matter involvement, and dura enhancement on MRI was resolved by treatment withdrawal with anti-PD-1 antibodies only.

## CASE REPORT

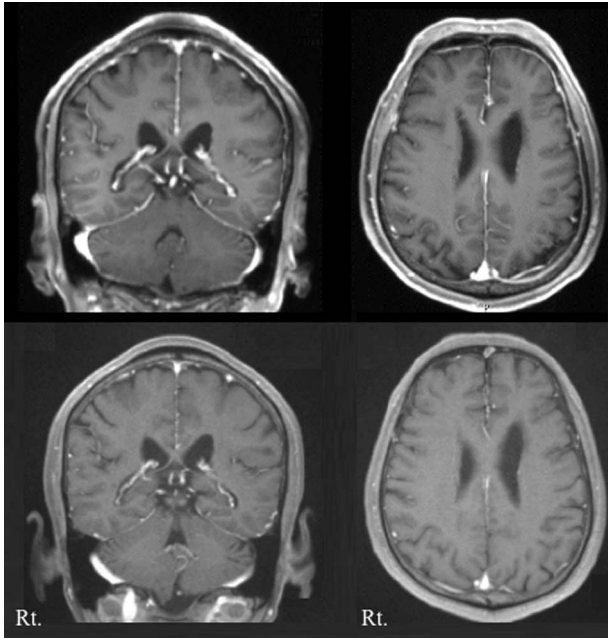
This is a case of a 69-year-old man with metastatic lung adenocarcinoma treated with seven courses of pembrolizumab (200 mg) combined with pemetrexed (820 mg/kg) and carboplatin (6.6 mg/kg) administered every month. An enhanced brain magnetic resonance imaging (MRI) was performed every year for the early detection of metastatic brain tumors. After seven courses of these chemotherapies and pembrolizumab, the brain MRI revealed thickness and enhancement of the dura matter (Fig. 1) without the abnormal intensity of the brain parenchyma. An asymptomatic internal carotid posterior communicating (IC-PC) artery aneurysm was evident, leading to a visit to our department. No history of neurological manifestations,

<sup>†</sup>Hiroshi Kataoka, <http://orcid.org/0000-0002-4157-5447>

Received: April 23, 2021; Revised: June 28, 2021; Accepted: July 17, 2021

© The Author(s) 2021. Published by Oxford University Press. All rights reserved. For Permissions, please email: [journals.permissions@oup.com](mailto:journals.permissions@oup.com)

This is an Open Access article distributed under the terms of the Creative Commons Attribution Non-Commercial License (<http://creativecommons.org/licenses/by-nc/4.0/>), which permits non-commercial re-use, distribution, and reproduction in any medium, provided the original work is properly cited. For commercial re-use, please contact [journals.permissions@oup.com](mailto:journals.permissions@oup.com)



**Figure 1:** Upper panel: Brain enhanced MRI showed enhancements of the dura mater after seven cycles of anti-PD-1 monoclonal antibodies. Lower panel: The enhancement of dura mater was resolved on repeated enhanced MRI 4 months after discontinuing pembrolizumab.

including headache, and no neurological deficit were reported. He had no meningismus. Serum laboratory examinations were within the normal range. Serum autoantibodies, including antinuclear antibody, anti-neutrophil cytoplasmic antibody, anti-DNA antibody, and anti-cardiolipin antibody, were negative. Additionally, the levels of serum IgG, IgM or IgG-4 were not increased. The levels of serum aspergillus antigen,  $\beta$ -D glucan and angiotensin-converting enzyme were within the normal range. Routine cerebrospinal fluid (CSF) findings revealed no white blood cells, protein (37 mg/dl) and glucose (64 mg/dl) with no increase in titers of herpes simplex virus, cryptococcus antigen or adenosine deaminase. The IgG index was 0.45. The bacterial and tuberculosis culture and cytology results of the CSF were negative. Four months after discontinuing pembrolizumab, a repeat MRI revealed that the enhancement of dura mater was resolved (Fig. 1). Five months after the first MRI, IC-PC aneurysm was operated on and simultaneously a dural biopsy was performed. Histological findings revealed no malignant or inflammatory cells. The clinical course was free of neurological complaints or features. Additional cancer treatment was not performed because tumor shrinkage was maintained with no further development on a repeat follow-up whole-body computed tomography. A written informed consent was obtained from the patient for these routine clinical examinations, treatments and publication of the case report.

## DISCUSSION

The patient showed dura mater involvement on MRI, and this was completely resolved after treatment withdrawal with anti-PD-1 antibodies only. Previously, one patient with meningoencephalitis revealed diffuse dural enhancement on MRI, and the patient recovered completely after steroid treatment;

however, the detailed clinical information, including imaging, was not mentioned [5]. The exact mechanism underpinning neurological adverse events has been largely unknown. It has been postulated that ICPI disrupts immune tolerance resulting in an exaggerated immune response manifesting neurological adverse effects [8]. Cross-reactivity between the nervous system antigens and antigens expressing the tumor is a hypothesis [5]. PD-L2 is expressed in brain endothelial cells [9], but whether the ligand exists in the dura mater is uncertain. A mouse model expressing a neo-self-antigen in both Purkinje neurons and implanted breast tumor cells evoked antigen-specific T-cell migration into the cerebellum after treatment with an anti-CTLA4 monoclonal antibody [10]. Most patients presenting with neurological adverse effects had no involvement of other organs [5], supporting the cross-reactivity of specific nervous system antigens with tumor antigens.

This case was asymptomatic, and complications due to ICPIs resolved with ICPI discontinuation were incidentally found. The patient did not need additional immunosuppressant treatment. The diagnosis of encephalitis associated with ICPIs can be challenging because MRI is not highly sensitive, with an estimated sensitivity of 55% [7]. These patients have advanced malignancies with limited treatment options. It is important to note that treatment discontinuation risks and benefits need to be carefully discussed, and decisions for treatment need to be made on a case-to-case basis, depending on the severity of neurological symptoms.

ICPI discontinuation only has a potential during recovery from a mild CNS disorder. Hence, as a recommendation, additional immunosuppressant treatment with efficiency for reducing the severity of neurological complications due to ICPIs should be considered when severe clinical deficits are evident or worsen [3–5].

## ACKNOWLEDGMENTS

Thanks to Dr Shigeto Kizu, Department of Respiratory Medicine for his management of lung adenocarcinoma. Thanks to Dr Syuichi Yamada, Dr Kenta Nakase, Department of Neurosurgery for their operation of cranial aneurysm and dural biopsy.

## CONFLICT OF INTEREST

The authors report no competing interest related to our paper.

## FUNDING

There was no funding related to our paper.

## ETHICAL APPROVAL, CONSENT AND GUARANTOR STATEMENTS

No investigations or interventions were performed outside routine clinical care for this patient. As this is a case report, without experimental intervention into routine care, no formal research ethics approval was required; Written, fully informed consent was given from this patient. This case study reports routine clinical care provided for a patient only.

## AUTHOR RESPONSIBILITIES AND CONTRIBUTIONS

H. Kataoka was responsible for the overall study design and wrote the manuscript.

D. Shimada, H Nanaura, and H Kataoka contributed to acquisition of data.

H. Nanaura and H. Kataoka contributed to analysis and interpretation of data.

H. Kataoka and S. Kazuma contributed to drafting and critical revision of part of the submitted materials.

## REFERENCES

1. Sharpe AH, Pauken KE. The diverse functions of the PD1 inhibitory pathway. *Nat Rev Immunol* 2018;**18**:153–67.
2. Pardoll DM. The blockade of immune checkpoints in cancer immunotherapy. *Nat Rev Cancer* 2012;**12**:252–64.
3. Kao JC, Liao B, Markovic SN, Klein CJ, Naddaf E, Staff NP, et al. Neurological complications associated with anti-programmed death 1 (PD-1) antibodies. *JAMA Neurol* 2017;**74**:1216–22.
4. Kao JC, Brickshawana A, Liewluck T. Neuromuscular complications of programmed cell death-1 (PD-1) inhibitors. *Curr Neurol Neurosci Rep* 2018;**18**:63.
5. Fellner A, Makranz C, Lotem M, Bokstein F, Taliansky A, Rosenberg S, et al. Neurologic complications of immune checkpoint inhibitors. *J Neurooncol* 2018;**137**:601–9.
6. Sechi E, Markovic SN, McKeon A, Dubey D, Liewluck T, Lennon VA, et al. Neurologic autoimmunity and immune checkpoint inhibitors: autoantibody profiles and outcomes. *Neurology*. 2020;**95**:e2442–52.
7. Velasco R, Villagrán M, Jové M, Simó M, Vilariño N, Alemany M, et al. Encephalitis induced by immune checkpoint inhibitors: a systematic review. *JAMA Neurol*. 2021;**78**: 864–73.
8. Hottinger AF. Neurologic complications of immune checkpoint inhibitors. *Curr Opin Neurol* 2016;**29**:806–12.
9. Pittet CL, Newcombe J, Prat A, Arbour N. Human brain endothelial cells endeavor to immunoregulate CD8 T cells via PD-1 ligand expression in multiple sclerosis. *J Neuroinflammation* 2011;**8**:155.
10. Yshii LM, Gebauer CM, Pignolet B, Mauré E, Quériault C, Pierau M, et al. CTLA4 blockade elicits paraneoplastic neurological disease in a mouse model. *Brain* 2016;**139**: 2923–34.