



Review Article

Patulous Eustachian tube (PET), a practical overview

Manohar Bance^{a,b,*}, James R. Tysome^{a,b}, Matthew E. Smith^a

^a Cambridge Ear Institute, Cambridge University Hospitals Trust, Cambridge UK

^b University of Cambridge, Cambridge, UK

Received 6 May 2019; accepted 22 August 2019

Available online 11 October 2019

KEYWORDS

Patulous Eustachian tube;
Autophony;
Cartilage
tympanoplasty;
Eustachian tube function testing;
Sonotubometry

Abstract Symptoms of patulous Eustachian tube (ET), particularly autophony, can overlap with other conditions, and can arise from a variety of causes. We review the pathophysiology of “speech hyper-resonance syndromes”, and possible mechanisms, including resonances in the tympanic membrane, Eustachian tube and nasopharynx. Treatment can be directed at the eardrum or the ET depending on site of pathology. We review typical presentations, examination findings, and useful clinical tests to distinguish PET from other disorders, and our philosophy of management.

Copyright © 2019 Chinese Medical Association. Production and hosting by Elsevier B.V. on behalf of KeAi Communications Co., Ltd. This is an open access article under the CC BY-NC-ND license (<http://creativecommons.org/licenses/by-nc-nd/4.0/>).

The Eustachian tube (ET) is normally closed at rest, in order to protect the middle ear from nasopharyngeal secretions, opening only briefly during swallowing and Valsalva. Fig. 1 is a dynamic CT image of the ET during rest, showing the closed valve area, a feature not easily visible from the nasopharyngeal (NP) side. If this protective closure of the

ET is deficient, patients may experience patulous Eustachian tube (PET) dysfunction.

The closed ET also protects the middle ear from unwanted acoustic energy from self-vocalization and breathing, which would otherwise make it difficult to attend to environmental sounds during speaking or respiration. When there is a true air-filled continuous communication through the ET, extending between the NP and the middle ear, then large pressure changes such as those occurring with breathing are able to move the eardrum. However, many of the symptoms associated with PET, such as autophony (hearing one’s own voice resonating loudly in the ear) could quite easily happen without this continuous air-filled connection; for instance if there is a thin membrane in the ET lumen, then large pressure changes cannot be transmitted, but small rapidly changing signals such as

* Corresponding author. ENT Department, CUH-Addenbrookes, Hills Road, Cambridge, CB2 0QQ, UK.

E-mail address: Mlb59@cam.ac.uk (M. Bance).

Peer review under responsibility of Chinese Medical Association.



Production and Hosting by Elsevier on behalf of KeAi




Fig. 1 Air contrast dynamic CT scan of the Eustachian tube at rest, showing the bony ET full of air, and very little air in the lumen on the NP side. The arrow marks the bony canal, and the cartilaginous canal is collapsed.

sounds can vibrate the membrane and cause it to transmit signals to the air column beyond, similar to a capacitor transmitting AC but not DC electrical signals. Hence, the autophony type symptoms of PET can occur even without a truly open ET, but do require that there is reduced acoustic impedance from the NP to the middle ear when compared to normal ears.

Autophony is not synonymous with PET

Autophony is often thought to be pathognomic of a truly PET, but the symptom is nonspecific and can be caused by many other disorders. Conversely, the authors have seen patients with clear movements of the tympanic membrane (TM) on respiration found incidentally, with no subjective symptoms.

Autophony can be produced by occluding the external ear canal (EAC), which causes enhancement of the low speech frequencies by creating a resonant cavity, with both the sealed column of air in the EAC and the eardrum as part of this system.¹ The enhanced low frequency sound perception of own voice often mimics what PET patients say they hear on vocalization. Other disorders such as superior canal dehiscence also enhance low frequency perception, causing autophony very similar to that seen with PET.² These examples suggest that autophony in PET is primarily due to sensitivity to low frequency speech sounds. Occasionally, foreign bodies on the eardrum such as hairs or wax can have a speech triggered resonant behaviour and cause a buzzing with certain self-vocalizations. In fact, anything that creates a resonant cavity can result in a sensation of enhanced perception of self-vocalization, which can be termed speech hyper-resonance disorder (SHRED), and there are many candidates for this resonant cavity or structure (Fig. 2).

SHRED is especially relevant to consider when diagnosing PET, because many patients with symptoms of autophony may have a hypermobile “floppy” eardrum, but no movements of the TM with respiration. Yet, this kind of flaccid, very compliant, TM should be easily moved by air pressure

changes if there was a truly patent air-filled connection between the NP and the middle ear. These patients may, in fact, have created a resonant cavity between the TM elasticity and mass, and the compliance of the air in the middle ear and mastoid. This resonant cavity may only be excited by acoustic energy input from a ET with reduced acoustic impedance from the NP to middle ear, with subjects with a normal ET remaining non-symptomatic. This mechanism can be tested by changing the resonance of the system by mass/stiffness loading of the TM, either by applying cream (Fig. 3), “Blu tack” or steri-strips to the TM,³ which can instantly relieve symptoms. If the trial is successful, these patients may benefit from cartilage tympanoplasty.⁴

ET closure failure, or the “popper-sniffer” patient

The middle ear cannot usually be evacuated by negative pressures in the NP, such as those caused by sniffing. Magnuson in 1978 and subsequently many others have described habitual sniffing in relation to the mechanism of formation of retraction pockets, serous otitis media, perforations and cholesteatoma.^{5–8} In Magnuson’s description, he hypothesized that subjects sniffed to alleviate the autophony from a subclinical patulous ET, i.e. a truly patent ET that was closed by sniffing. However, since many of these patients have “floppy” TMs from previous perforations, or repeated sniffing, if this was the case then as noted above, the TM should move with forced respiration prior to sniffing. In the authors experience, whilst this is sometimes true, it is not so in the majority of these cases. It is more likely that the sniffing causes the TM to retract, changing its frequency response, and reducing the perceived autophony. Patients who are habitual sniffers often have a history of childhood otitis media and hence poorly pneumatized mastoids.⁵ This combination of small mastoid volume and “floppy TM” may result in a resonant cavity that accentuates certain speech frequencies. As mentioned above, this can be tested by mass loading the TM, which alleviates the symptoms in these patients. Many of these patients sniff, drawing in the TM to reduce autophony, but then experience some hearing loss, which they then try to alleviate by performing a Valsalva to force out the TM again. This forms a “popping-sniffing” habit. Fig. 4 shows a typical TM in such a patient after Valsalva.

Symptoms and signs

While ET dysfunction is often divided into obstructive or PET as broad categories, as Smith et al⁹ have shown, symptoms rarely map well to the underlying state of the ET. The easy PET diagnoses are those with classic autophony with movement of the TM on respiration. However, most patients present with a variety of symptoms which overlap with other disorders, have only some features of PET, and may not have movement of the TM with respiration. These patients provide a significant diagnostic challenge, with Fig. 5 demonstrating how what we see in clinic can back-project to many possible underlying diagnoses. Classically

Possible Mechanisms for Speech Hyper-Resonance

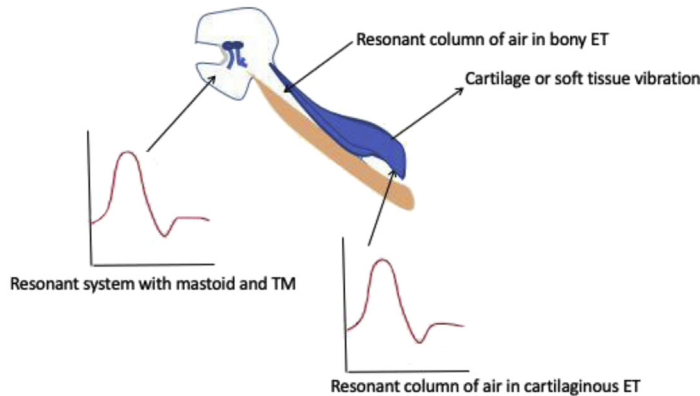


Fig. 2 Possible sites of resonance to speech sounds within the middle ear/mastoid/ET complex.

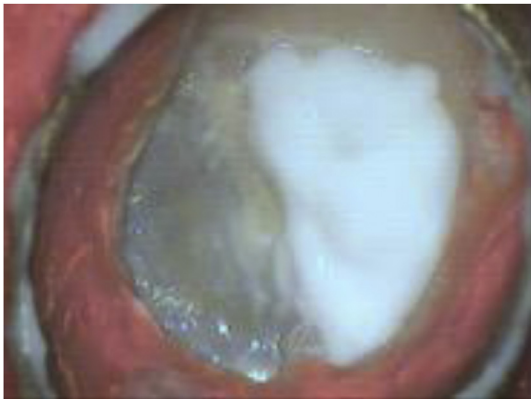

Fig. 3 Cream loading of the TM to test if autophony is relieved.

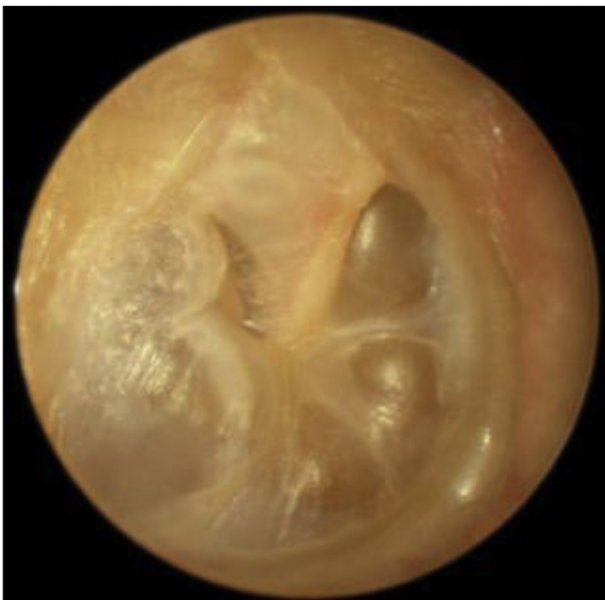

Fig. 4 Typical "floppy" TM after Valsalva in a "popper-sniffer" patient.

PET is more likely to occur after weight loss, radiation therapy, pregnancy, allergies, or gastroesophageal reflux,¹⁰ but in our experience, in most patients it is idiopathic.

Common PET symptoms are autophony, aural fullness, and hearing one's own breathing (aerophony).¹⁰ The autophony is often described as similar to talking into a barrel, i.e. an "echoey" quality. Other symptoms such as tinnitus (both pulsatile and non-pulsatile) and vertigo have been described but are difficult to explain from PET mechanisms.¹⁰ Of these, hearing one's own respiration is the most specific for PET. Symptoms can be brought on by vigorous exercise, and may be better in the morning from overnight venous congestion around the NP orifice, with a worsening during the day. A few patients may spontaneously notice that autophony gets better with lying down, although most have not identified this at presentation. It should be noted that relief in symptoms when supine is also true of superior canal dehiscence, which has many overlap features. PET symptoms are commonly intermittent and fluctuate.

The clinical examination is limited by the intermittency of the condition, and nothing may be found at the time. One option to unmask signs and symptoms is to have the patient exercise, such as by climbing stairs, but this method is not reliable and it may take vigorous exercise to induce symptoms. Autophony symptom modification by lying down can be tested by having the patient say "1,1,1,1" repeatedly while lying and sitting. Symptoms can sometimes be made better by pressing on the neck, which partly closes the ET. If the patient is not symptomatic during the consultation, occluding the external ear canal (occlusion effect) and asking the patient if this reproduces their autophony symptoms while they talk can be a good comparator.

On examination of the ear, it is important that this is performed with the patient sitting up, as TM movements synchronous with breathing may stop when the patient is recumbent. Movement of the TM is best tested by having the patient take deep breaths in and out with the contralateral nostril occluded, while the TM is examined under a microscope. This maximizes the pressure peaks and troughs in the NP. The TM movements can be quite subtle.

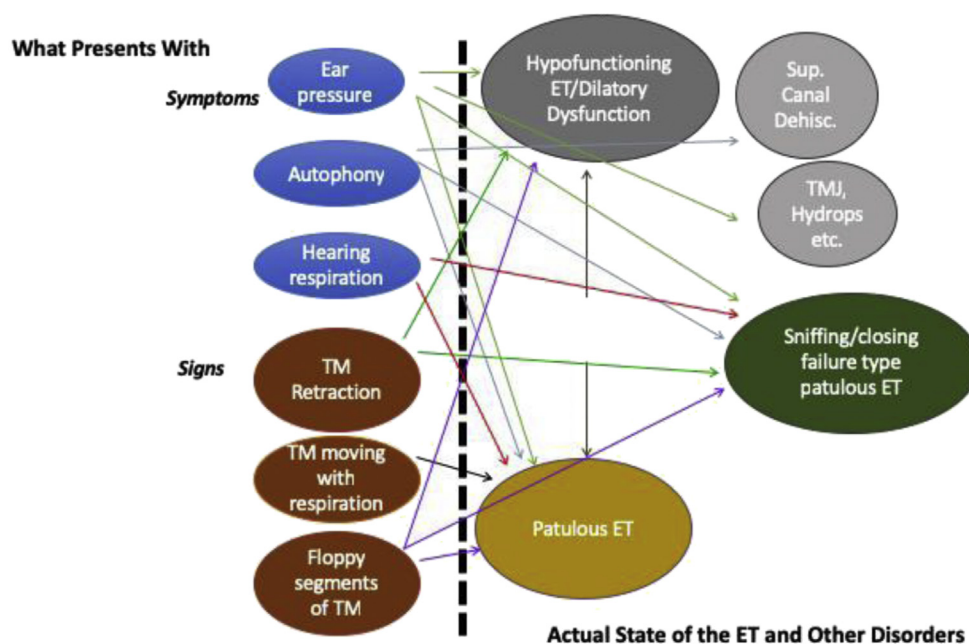


Fig. 5 Mapping presenting symptoms and signs to underlying state of the ET (TMJ = Temporomandibular joint).

If the patient is suspected of having autophony due to the resonant cavity model described earlier, then cream can be applied to the TM to see if this is relieved.

Finally, endoscopic examination of the ET may show if there is wasting of Ostman's fat pad, and Poe's group have described that the normal S-shaped opening of the ET in the NP can be lost in patients with PET,¹¹ although this requires some experience to appreciate. It is also worth palpating the palate to look for submucous cleft palate.

Testing

Perhaps the most important test for diagnosis of the truly patulous ET is long time-base tympanometry. This measures the acoustic immittance of the TM while the patient breathes forcefully (though one nostril). In this test condition (often tested using the "reflex-decay" settings in commercial tympanometers), the acoustic immittance is measured to a probe tone (usually 226 Hz). The inward and outward excursions of the TM with respiration cause a cyclical change in the immittance. Fig. 6 shows an example of a positive test. In this testing it is important for the patient not to breathe too loudly, as the microphone in the ear canal will pick this up as a signal, generating noise artefact.

We have shown that a 668 Hz probe tone is more sensitive and has fewer false positive results than a 226 Hz probe tone when using this method of diagnosis.¹²

Other tests that have been reported include nasal audiometry, in which a sound is presented in the nose, and the audibility in the ear is measured. This has been reported to show good results in the Japanese literature,^{13,14} but in our own experiments in a Caucasian population, we have found it of limited use.¹⁵

Sonotubometry is a promising modality also, but at present its use in PET is poorly understood and it has been

REFLEX DECAY

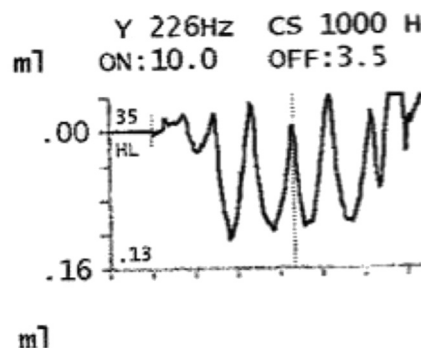


Fig. 6 Typical long time-base tympanometry pattern in PET.

primarily used for dilatatory failure (obstructive) ET dysfunction. There are many new developments in this area, some that we have described,^{16,17} that make this likely to be perhaps the most useful future investigation modality.

Currently, imaging has only a limited role to play in the diagnosis of PET. Although Stenver's plane is very good at showing the bony ET, it does not show the more important soft tissue components, and few centres have the capacity to use dynamic imaging of the ET, which is in its infancy, but promises also to revolutionize ET diagnostics if it becomes perfected.

Treatment options

Treatment options for PET are diverse, and difficult to comprehensively review in this article. They can be minimally invasive, medical, and surgical. Good systematic

reviews are available of this topic by Luu et al¹⁸ 2015 and (surgical only) Hussein et al¹⁹ 2015. Minimally invasive options include increasing fluid intake, nasal distilled water, putting one's head between one's legs (or if possible lying with legs raised against a wall), which can sometimes give relief for minutes to hours.

Pharmacologic options (see Luu et al¹⁸ 2015) are nasal applications of estrogens, dilute hydrochloric acid, potassium iodide, boric acid and salicylic acid powders and benzyl alcohols. Success rates of 60%–100% are described, but in general the quality of the published data is very poor for these interventions.

Surgical treatments can be directed at the middle ear side or the NP side. Perhaps the most commonly used middle ear intervention is the insertion of a ventilation tube (grommet). It should be noted, in passing, that relief of aural fullness with a grommet does not mean that the underlying diagnosis is obstructive dysfunction of the ET, as ventilation tubes have been reported to relieve symptoms of PET in 50%–100% of patients.¹⁸ In our experience the success rate is closer to 50%, and a subset of patients actually report a worsening of symptoms. Of the middle ear interventions, an interesting group of patients have been reported by us who have had autophony and other symptoms of PET relieved by mass loading of the TM³; in our original series using Blu-tack®, relief lasted for days up to 4 months, whereas Steri-strips® (which we currently use) can last even longer.

Of patients whose symptoms can be relieved by TM mass loading, we have reported results of cartilage tympanoplasty in controlling their symptoms, with success in about 75% of these carefully selected patients.⁴ Others have subsequently reported very high success rates in all-comers with PET with cartilage tympanoplasty,²⁰ which has not been our experience with patients without some “floppy” segments to the TM.

There have been long-standing reports of obstruction of the bony ET orifice with catheters or with bone wax plugging the lumen,²¹ usually with small numbers. More recently much larger case series using a transtympanically-inserted silicone plug, custom-designed to close the ET, have been published by Kikuchi et al,²² who reported very good results. However, this plug is difficult to obtain outside of Japan.

Of NP manipulations (see Luu et al¹⁸ and Hussein et al¹⁹ for overview), interventions range from injection of fillers into the lateral wall of the ET (such as hyaluronic acid and hydroxyapatite), to manipulations to the C-shaped cartilage abutting the torus.

However, the most extensive reports have come from Ward et al¹⁰ using cartilage bulking agents inserted into the lateral wall of the ET to close off the ET lumen. Other strategies have included shims inserted into the ET lumen from the NP side. Recently Ward et al¹⁰ reported on 12 month outcomes of a large series of patients ($n = 276$) treated with various surgical procedures on the ET. Of note, about 50% had recurrence of symptoms after 12 months, with obliteration of the ET being the most reliable longer-term solution (100% at 12 months, but with most requiring ventilation tubes), and fillers and injectables the least reliable. Shims and ET reconstruction procedures were in-between in outcome results.

Conclusions

PET can be difficult to diagnose, to investigate and to treat. It is especially difficult to achieve good long-term results with any of the various treatment options available.

The symptoms of PET do not require a patent air-filled lumen connection between the NP and the middle ear. Some of these symptoms, in particular autophony, may arise from the presence of a resonant cavity created through the mechanical properties of the TM, ET soft tissues, and air-filled cavities in the NP-ET-middle ear system.

Declaration of Competing Interest

The author declare no conflict of interest relevant to this paper.

References

1. Edgerton BJ, Klodd DA. Occlusion effect in bone conduction pure tone and speech audiometry. *J Am Audiol Soc.* 1977;2(4): 151–158.
2. Yuen HW, Eikelboom RH, Atlas MD. Auditory manifestations of superior semicircular canal dehiscence. *Otol Neurotol.* 2009; 30:280–285.
3. Bartlett C, Pennings R, Ho A, Kirkpatrick D, van Wijhe R, Bance M. Simple mass loading of the tympanic membrane to alleviate symptoms of patulous eustachian tube. *J Otolaryngol Head Neck Surg.* 2010;39:259–268.
4. Brace MD, Horwich P, Kirkpatrick D, Bance M. Tympanic membrane manipulation to treat symptoms of patulous eustachian tube. *Otol Neurotol.* 2014;35:1201–1206.
5. Magnuson B. Tubal closing failure in retraction type cholesteatoma and adhesive middle ear lesions. *Acta Otolaryngol.* 1978;86:408–417.
6. Takizawa Y, Mizuta K, Hamada N, et al. Relationship between tympanic membrane retraction and habitual sniffing in patients with cholesteatoma. *Acta Otolaryngol.* 2013;133: 1030–1034.
7. Ikeda R, Oshima T, Oshima H, et al. Management of patulous eustachian tube with habitual sniffing. *Otol Neurotol.* 2011;32: 790–793.
8. Hauser R, Munker G. Sniff-induced negative pressure—a cause for the development of middle ear diseases? *HNO.* 1989;37: 242–247.
9. Smith ME, Takwoingi Y, Deeks J, et al. Eustachian tube dysfunction: a diagnostic accuracy study and proposed diagnostic pathway. *PLoS One.* 2018;13:e0206946.
10. Ward BK, Chao WC, Abiola G, et al. Twelve-month outcomes of Eustachian tube procedures for management of patulous Eustachian tube dysfunction. *The Laryngoscope.* 2019;129: 222–228.
11. Grimmer JF, Poe DS. Update on eustachian tube dysfunction and the patulous eustachian tube. *Curr Opin Otolaryngol Head Neck Surg.* 2005;13:277–282.
12. Pyne JM, Lawen TI, Floyd DD, Bance M. The 678 Hz acoustic immittance probe tone: a more definitive indicator of PET than the traditional 226 Hz method. *J Otolaryngol Head Neck Surg.* 2018;47:43.
13. Kano S, Kawase T, Baba Y, Sato T, Kobayashi T. Possible new assessment of patulous Eustachian tube function: audiometry for tones presented in the nasal cavity. *Acta Otolaryngol.* 2004;124:431–435.

14. Hori Y, Kawase T, Hasegawa J, et al. Audiometry with nasally presented masking noise: novel diagnostic method for patulous eustachian tube. *Otol Neurotol*. 2006;27:596–599.
15. Paradis J, Bance M. Assessment of nasal-noise masking audiometry as a diagnostic test for patulous Eustachian tube. *Otol Neurotol*. 2015;36:e36–e41.
16. Amoako-Tuffour Y, Garland P, Bance M. Interpretation of sonotubometric data based on phase-shift detection. *J Otolaryngol Head Neck Surg*. 2016;45:37.
17. Amoako-Tuffour Y, Jufas N, Quach J, et al. Acoustic transmission characteristics of a Eustachian tube volitionally opened in two living subjects. *Otol Neurotol*. 2016;37:1055–1058.
18. Luu K, Remillard A, Fandino M, Saxby A, Westerberg BD. Treatment effectiveness for symptoms of patulous Eustachian tube: a systematic review. *Otol Neurotol*. 2015;36:1593–1600.
19. Hussein AA, Adams AS, Turner JH. Surgical management of Patulous Eustachian tube: a systematic review. *The Laryngoscope*. 2015;125:2193–2198.
20. Si Y, Chen Y, Li P, et al. Eardrum thickening approach for the treatment of patulous Eustachian tube. *Eur Arch Otorhinolaryngol*. 2016;273:3673–3678.
21. Bluestone CD, Cantekin EI. Management of the patulous Eustachian tube. "How I do it"—otology and neurotology. A specific issue and its solution. *The Laryngoscope*. 1981;91:149–152.
22. Kikuchi T, Ikeda R, Oshima H, et al. Effectiveness of Kobayashi plug for 252 ears with chronic patulous Eustachian tube. *Acta Otolaryngol*. 2017;137:253–258.

Edited by Xin Jin