

Palisaded neutrophilic and granulomatous dermatitis as a novel cause of hypercalcemia

A case report

Michihito Kono, MD, PhD^{a,*}, Tomoka Hasegawa, DDS, PhD^b, So Nagai, MD, PhD^c, Toshio Odani, MD, PhD^a, Kazumasa Akikawa, MD^a, Yukiko Nomura, MD, PhD^d, Hidetsugu Sato, MD^d, Keisuke Kikuchi, MD^e, Norio Amizuka, DDS, PhD^b, Hideaki Kikuchi, MD^a

Abstract

Rationale: Palisaded neutrophilic and granulomatous dermatitis (PNGD) is a benign, inflammatory dermatosis with distinct histopathological features often observed in patients with systemic diseases. There were no reports of PNGD without underlying systemic diseases as an underlying cause of hypercalcemia. Herein, we report a case of a 62-year-old man with hypercalcemia due to PNGD, but with no underlying systemic diseases, including tuberculosis, sarcoidosis, or vasculitis.

Patient concerns: Laboratory tests showed an elevated C-reactive protein level, an elevated corrected calcium level, a normal 25-hydroxyvitamin D level, and an elevated 1,25-dihydroxyvitamin D level. There were no other abnormalities to explain the hypercalcemia. Positron emission tomography–computed tomography showed abnormal uptake in his skin. Histopathological examination of the skin showed palisaded granulomatous infiltrate in the dermis. Neutrophils, degenerated collagen, and fibrin were present in the centers of the palisades without prominent mucin. There were no eosinophils, central necrosis, or necrotizing vasculitides. These features were consistent with PNGD.

Diagnoses: A diagnosis of PNGD with hypercalcemia was established.

Interventions: Oral prednisolone was administered to the patient.

Outcomes: After treatment, his symptoms resolved, and his calcium, 1,25-dihydroxyvitamin D and CRP levels returned to normal. Skin specimens before and after treatment were assessed using immunohistochemistry for 1 α -hydroxylase. Granuloma and epidermal cells were 1 α -hydroxylase-positive before treatment. After treatment, the granuloma diminished in size and the 1 α -hydroxylase-positive areas of the epidermal cells decreased.

Lessons: This case was particularly unique because increased 1 α -hydroxylase expression in the granuloma and epidermal cells seemed to result in hypercalcemia due to excessive transformation of 25-hydroxyvitamin D to 1,25-dihydroxyvitamin D. Physicians should consider PNGD as an underlying cause of hypercalcemia.

Abbreviations: BSA = bovine serum albumin, CRP = C-reactive protein, PBS = phosphate-buffered saline, PET-CT = positron emission tomography-computed tomography scan, PNGD = palisaded neutrophilic and granulomatous dermatitis, PTH = parathyroid hormone.

Keywords: 1 α -hydroxylase, hypercalcemia, palisaded neutrophilic and granulomatous dermatitis

Editor: Sergio Gonzalez Bombardiere.

Disclosure: Written informed consent was obtained from the patient for publication including photographs of this case report. This study was conducted in accordance with the Helsinki Declaration and we got consent from Hokkaido P.W.F.A.C., Obihiro-Kosei General Hospital.

The authors have no funding and conflicts of interest to disclose.

^a Third Department of Internal Medicine, Hokkaido P.W.F.A.C., Obihiro-Kosei General Hospital, Obihiro, ^b Department of Developmental Biology of Hard Tissue, Graduate School of Dental Medicine, Hokkaido University, Sapporo, ^c Department of Diabetes and Endocrinology, Sapporo Medical Center, NTT EC, Sapporo, ^d Division of Dermatology, ^e Division of Pathology, Hokkaido P.W.F.A.C., Obihiro-Kosei General Hospital, Obihiro, Japan.

* Correspondence: Michihito Kono, Third Department of Internal Medicine, Hokkaido P.W.F.A.C., Obihiro-Kosei General Hospital, Obihiro, Japan (e-mail: m-kono@med.hokudai.ac.jp).

Copyright © 2017 the Author(s). Published by Wolters Kluwer Health, Inc. This is an open access article distributed under the Creative Commons Attribution-No Derivatives License 4.0, which allows for redistribution, commercial and non-commercial, as long as it is passed along unchanged and in whole, with credit to the author.

Medicine (2017) 96:21(e6968)

Received: 30 June 2016 / Received in final form: 25 April 2017 / Accepted: 3 May 2017

<http://dx.doi.org/10.1097/MD.0000000000000698>

1. Introduction

Palisaded neutrophilic granulomatous dermatitis (PNGD) is a rare neutrophilic dermatosis that characteristically presents in patients with underlying connective tissue diseases,^[1,2] vasculitis,^[3,4] or malignancy.^[3,5] However, previous cases with no underlying systemic diseases have been reported.^[5,6] Herein, we describe the case of a man with hypercalcemia possibly secondary to PNGD, but with no underlying systemic diseases, including tuberculosis, sarcoidosis, or vasculitis. PNGD should be considered as a cause of hypercalcemia even in the absence of associated chronic diseases.

2. Case presentation

A 62-year-old Asian office-worker complained of dark red papules and nodules, scattered mainly on the trunk, of 3-year duration. The erythema gradually fused into a dark red erythema-related situation forming geographical areas over his entire body, including extremities (Fig. 1A and B). The patient had been receiving topical steroid therapy at a local dermatology clinic for 3 years and there was adhesion of monitoring. The patient had no other symptoms during this period apart from the skin rash. He

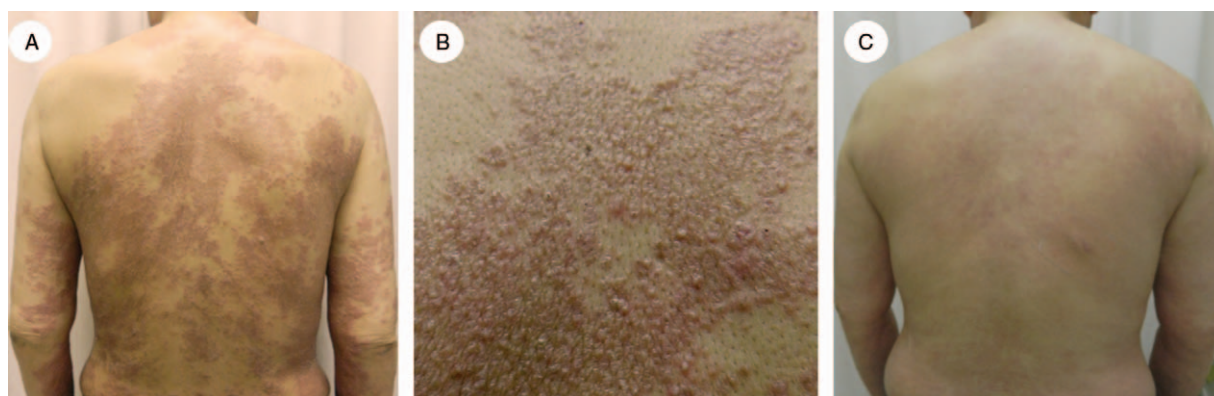

Figure 1. Photograph showing the patient's skin rash. (A) Before treatment, dark red papules and nodules fused into erythema-related situation, taking a geographic form on the trunk and 4 extremities, and particularly on the back. (B) Close-up photography of the skin rash on the back before treatment. (C) After 6 months of treatment, the exanthema changed to postinflammatory pigmentation, with significant improvement up to almost cure.

was admitted to our department in November 2014 secondary to fever, fatigue, nausea, and anorexia. The patient had no other relevant past or family history, including autoimmune diseases or liver diseases, and denied history of surgery, trauma, or drug allergies. The patient was not receiving any medications or dietary supplements. Physical examination was significant for the skin rash only, with no lymphadenopathy. Laboratory tests showed an elevated C-reactive protein (CRP) level of 23.3 mg/dL, an elevated corrected calcium level (correction based on the serum albumin level) of 12.8 mEq/L, a normal 25-hydroxyvitamin D level (29 ng/mL; normal range: 7–41 ng/mL), and an elevated 1,25-dihydroxyvitamin D level (124 pg/mL; normal range: 20–40 pg/mL). Parathyroid hormone (PTH) and PTH-related protein levels were low. There were no abnormalities in the urinalysis. There were no other abnormalities that could explain the patient's hypercalcemia (Table 1).

Positron emission tomography-computed tomography scan (PET-CT) showed abnormal uptake in his skin, hilar lymph nodes, and bone marrow (Fig. 2). PET-CT did not show hilar lymphadenopathy. Bone marrow biopsy and endobronchial ultrasound-guided transbronchial needle aspiration of the hilar lymph nodes showed no abnormalities, including possibility of sarcoidosis or tuberculosis, and histopathological examinations of the skin (of the left upper arm, the left femur, the right chest, and the lower abdomen) showed palisaded granulomatous infiltrate all through the dermis. Neutrophils, partial collagen degeneration, and fibrin were present in the centers of the palisades without prominent mucin. Histiocytes had circular or semicircular nuclei which did not have increased chromatin, irregular contours, or mitotic figures. Histiocytes showed both diffuse infiltration and palisaded granulomas. There were no eosinophils, central necrosis, or necrotizing vasculitides. These features were consistent with PNGD (Fig. 3A).

Blood, sputum, and urine culture tests, including culture for tuberculosis, and interferon-gamma release assay, yielded negative results, and serum levels of angiotensin-converting enzyme were normal. Although laboratory tests showed positive antinuclear antibody (speckled pattern), the patient had no specific antibodies, including anti-Ro (anti-Sjögren's-syndrome-related antigen A) antibody, anti-U1 ribonucleoprotein antibody, or anti-Sm antibody. The patients did not have any symptoms of connective tissue diseases or organ involvement. No underlying systemic diseases, including tuberculosis, sarcoidosis, systemic lupus erythematosus, or vasculitis, were identified. A diagnosis of

Table 1

Laboratory data.

Parameter	Value	Normal value
White blood cell count, per mm ³	9200	3600–9000
Differential count, %		
Neutrophils	91	40–70
Lymphocytes	4	22–44
Monocytes	5	4–11
Eosinophils	0	0–8
Basophils	0	0–3
Atypical lymphocytes	0	0
Hematocrit, %	32.2	37.4–48.6
Hemoglobin, g/dL	10.5	12.6–16.5
Platelet count, per mm ³	398,000	138,000–309,000
Sodium, mmol/L	134	135–146
Potassium, mmol/L	4.0	3.4–4.8
Chloride, mmol/L	95	98–108
Urea nitrogen, mg/dL	16.6	7–24
Creatinine, mg/dL	1.14	0–1.0
Calcium, mg/dL	11.5	8.7–10.3
Phosphorus, mg/dL	3.4	2.7–4.4
Magnesium, mg/dL	1.7	1.7–2.4
Albmin, g/dL	2.4	4.0–5.2
Aspaarate aminotransferase, U/L	26	0–30
Alanine aminotransferase, U/L	31	0–30
Alkaline phosphatase, U/L	354	104–338
γ-Glutamyltransferase, U/L	113	0–50
Angiotensin-converting enzyme, U/L	7.2	8.3–21.4
Parathyroid hormone, pg/mL	2	10–65
Parathyroid hormone-related protein, pmol/L	<1	0–1.1
25-Hydroxyvitamin D, ng/mL	29	7–41
1,25-dihydroxyvitamin D, pg/mL	124	20–40
Prostate-specific antigen, ng/mL	0.23	0–4.0
Immunoglobulins, mg/dL		
IgA	370	110–410
IgG	2493	870–1700
IgM	104	35–220
C-reactive protein, mg/dL	23.3	0–0.3
Total 50% complement	63.8	31.5–48.8
Hemolytic unit, U/mL		
Antinuclear antibody	Positive at 1:320 dilution speckled pattern	
Anti-Ro (SSA) antibody	5.0	0–9.9
Anti-DNA antibody	4.7	0–6.0
Anti-U1 RNP antibody	5.0	0–14.9
Anti-Sm antibody	0.7	0–6.9
Hepatitis B surface antigen	Negative	Negative
Anti-hepatitis C virus antibody	Negative	Negative
Anti-human immunodeficiency virus antibody	Negative	Negative

DNA = deoxyribonucleic acid, RNP = ribonucleoprotein, SSA = anti-Sjögren's-syndrome-related antigen A.

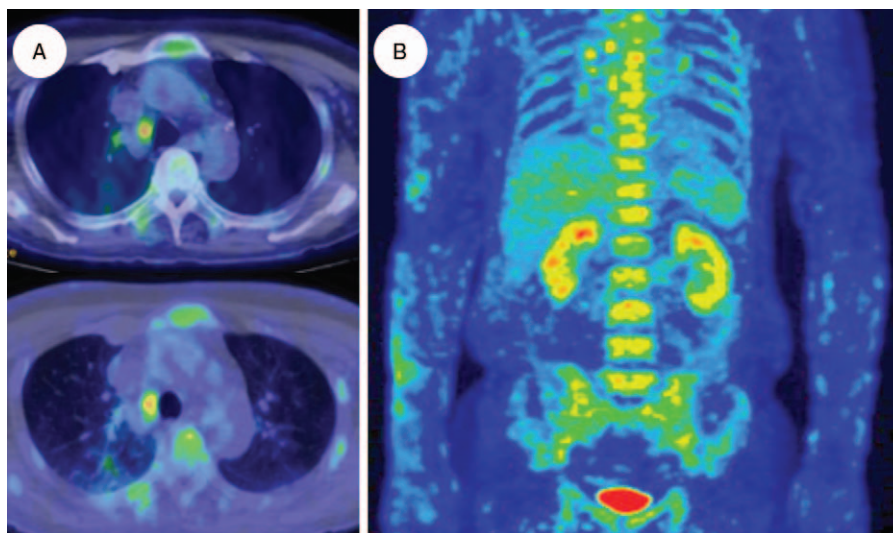


Figure 2. Positron emission tomography-computed tomography scan of the patient. (A) Abnormal uptake in hilar lymph nodes and bone marrow. (B) Abnormal uptake in skin.

PNGD with hypercalcemia was established, and oral prednisolone (30 mg/day) was administered to the patient. Symptoms resolved after 3 days of medical treatment, with normalization of calcium (correction based on serum albumin level; 9.8 mEq/L), 1,25-dihydroxyvitamin D and CRP levels after 1 month. After 6 months of treatment, prednisolone was tapered to 14 mg/day, and the exanthema changed to postinflammatory pigmentation with significant improvement of the condition, up to almost cure (Fig. 1C). The patient's adherence to treatment and tolerability was very good. No adverse effects were reported.

3. Materials and methods

3.1. Immunohistochemistry of skin tissue

Skin biopsies were taken from the left upper arm before and after treatment and the tissue was fixed in 10% formalin. After inhibition of endogenous peroxidase activity with 0.3% hydrogen peroxidase in methanol for 30 minutes, dewaxed paraffin sections were pretreated with 1% bovine serum albumin (BSA);

Serologicals Proteins Inc. Kankakee, IL) in phosphate-buffered saline (PBS) (1% BSA-PBS) for 30 minutes. Sections were then incubated for 2 hours at room temperature with sheep anti-25 (OH) vitamin D3-1 α -hydroxylase (BioLogo, Kronshagen, Germany) diluted at 1:800 with 1% BSA-PBS. This was followed by incubation with horseradish peroxidase-conjugated donkey anti-sheep IgG (Bethyl Laboratories, Inc., Montgomery, TX) diluted at 1:100 with 1% BSA-PBS. For visualization of all immunoreactions, immune complexes were visualized using 3,3'-diaminobenzidine tetrahydrochloride (Dojindo Laboratories, Kumamoto, Japan).

4. Results

Skin specimens before and after treatment were assessed using immunohistochemistry for 1 α -hydroxylase. Granuloma and epidermal cells were 1 α -hydroxylase-positive before treatment (Fig. 3C, upper panel). After treatment, the granuloma diminished in size and 1 α -hydroxylase-positive areas of the epidermal cells decreased (Fig. 3B; C, lower panel).

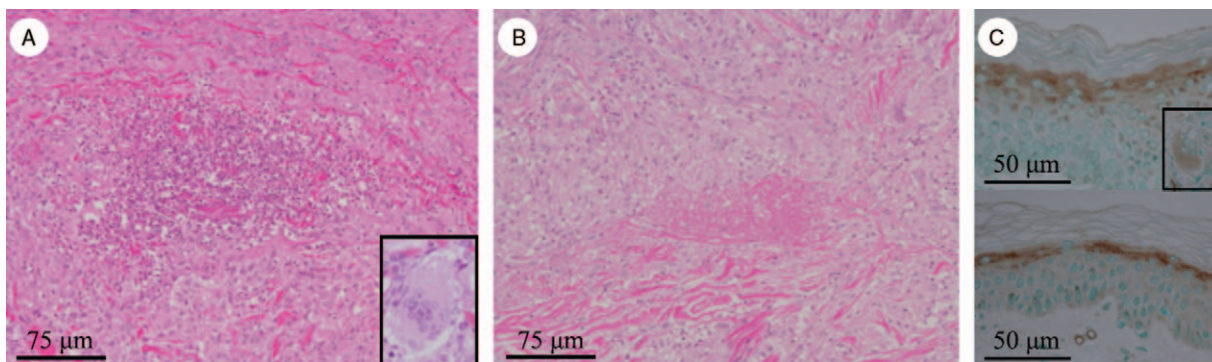


Figure 3. Light photo-microgram of the skin biopsy specimen. (A, B) Hematoxylin-eosin staining, (C) immunohistochemistry for 1 α -hydroxylase before (upper panel) and after treatment (lower panel). Granuloma and epidermal cells were 1 α -hydroxylase-positive before treatment. After treatment, the granuloma diminished in size and 1 α -hydroxylase-positive areas of the epidermal cells decreased.

5. Discussion

Hypercalcemia is a relatively common metabolic derangement, most commonly caused by hyperparathyroidism and malignancy. Causes of hypercalcemia can be divided into PTH-dependent and PTH-independent causes.^[7] Granulomatous diseases can cause PTH-independent hypercalcemia.^[7,8] In these diseases, the extra renal production of 1,25-dihydroxyvitamin D by macrophages can lead to increased bone resorption and intestinal calcium absorption.^[9,10] 1 α -hydroxylase is the enzyme which converts 25-hydroxyvitamin D to 1,25-dihydroxyvitamin D, the biologically active form of the molecule.^[11,12]

The patient's symptoms, fatigue, nausea, and anorexia, could have been attributed to hypercalcemia. We considered PTH-independent hypercalcemia because PTH levels were low. The patient was not receiving any medications or dietary supplements that could have caused the hypercalcemia. Although the patient underwent electrocardiogram, abdominal ultrasonography, chest-abdomen-pelvic contrast-enhance CT, PET-CT, magnetic resonance cholangiopancreatography, upper gastrointestinal endoscopy, colonoscopy, skin and bone marrow biopsies, and endobronchial ultrasound-guided transbronchial needle aspiration of the hilar lymph node, he had no evidence of other granulomatous diseases, cancers or hematologic diseases, including tuberculosis, sarcoidosis, lymphoproliferative diseases and multiple myeloma. The patient consulted an ophthalmologist and there are no ophthalmologic abnormalities. In addition, he had no symptoms or evidence of connective tissue diseases, including arthritis, Raynaud's phenomenon, scleroderma, myalgia, muscle weakness, xerostomia, xerophthalmia, or photosensitivity. The histopathological examinations of the skin had no findings of interface dermatitis, cutaneous lupus, sarcoidosis, or leprosy. Thus, a diagnosis of PNGD with hypercalcemia was established.

PNGD is a benign, inflammatory dermatosis with distinct histopathological features often observed in patients with systemic diseases such as connective tissue diseases and lymphoproliferative diseases.^[5] However, no underlying systemic diseases, including other granulomatous diseases that cause hypercalcemia, such as sarcoidosis,^[7,8] were identified in this patient. PNGD shows some histopathological stages, which may suggest the development of the disease.^[5,13] Early-stage lesions show leukocytoclastic vasculitis with diffuse pandermal neutrophilic infiltrates and altered collagen.^[5,13] In fully developed-stage lesions, palisaded granulomas surround leukocytoclastic debris, fibrin, and degenerated collagen, and resolving lesions show palisaded granulomas with dermal fibrosis.^[5,13] Histopathological features of the skin in the patient were consistent with these findings.

This patient had a normal 25-hydroxyvitamin D level and an elevated 1,25-dihydroxyvitamin D level. Before treatment, granuloma and epidermal cells of the skin were 1 α -hydroxylase-positive, and after treatment the granuloma diminished in size, 1 α -hydroxylase-positive areas of the epidermal cells decreased, and levels of calcium and 1,25-dihydroxyvitamin D returned to normal. From these data, we showed that increased

1 α -hydroxylase expression in the granuloma and epidermal cells could result in hypercalcemia due to excessive transformation of 25-hydroxyvitamin D to 1,25-dihydroxyvitamin D. This study has some limitations. The patient was performed endobronchial ultrasound-guided transbronchial needle aspiration of the lung hilar lymph nodes, however could not be performed lung hilar biopsy. Thus, we cannot perfectly rule out whether lung hilar lymph nodes also contribute to hypercalcemia. We cannot perfectly rule out whether this patient will have other systemic diseases including sarcoidosis or connective tissue diseases in future. Although PNGD is a rare disease, we could not collect the cases of PNGD with hypercalcemia or undertake a literature review. We could not show a direct causal relation between PNGD and hypercalcemia.

6. Conclusions

We reported the case of hypercalcemia possibly secondary to PNGD. This case was particularly unique because excess 1 α -hydroxylase expression in the granuloma and epidermal cells in PNGD seemed to cause hypercalcemia. Accordingly, physicians should consider PNGD as an underlying cause of hypercalcemia even in the absence of associated chronic diseases.

References

- [1] Sanguenza OP, Caudell MD, Mengesha YM, et al. Palisaded neutrophilic granulomatous dermatitis in rheumatoid arthritis. *J Am Acad Dermatol* 2002;47:251–7.
- [2] Germanas JP, Mehrabi D, Carder KR. Palisaded neutrophilic granulomatous dermatitis in a 12-year-old girl with systemic lupus erythematosus. *J Am Acad Dermatol* 2006;55:S60–62.
- [3] Calonje JE, Greaves MW. Cutaneous extravascular necrotizing granuloma (Churg-Strauss) as a paraneoplastic manifestation of non-Hodgkin's B-cell lymphoma. *J R Soc Med* 1993;86:549–50.
- [4] Hunt RD, Hartman RD, Molho-Pessach V, et al. Palisaded neutrophilic and granulomatous dermatitis in an adolescent girl with perinuclear antineutrophil cytoplasmic antibody-positive pauci-immune glomerulonephritis and arthritis. *J Am Acad Dermatol* 2012;67:e164–6.
- [5] Mahmoodi M, Ahmad A, Bansal C, et al. Palisaded neutrophilic and granulomatous dermatitis in association with sarcoidosis. *J Cutan Pathol* 2011;38:365–8.
- [6] Singh M, Comfere N. Images in clinical medicine Palisaded neutrophilic and granulomatous dermatitis. *N Engl J Med* 2012;366:e33.
- [7] Powe NR, Peterson PG, Mark EJ. Case records of the Massachusetts general hospital. Case 27-2015. A 78-year-old man with hypercalcemia and renal failure. *N Engl J Med* 2015;373:864–73.
- [8] Hamzeh N. Sarcoidosis. *Med Clin North Am* 2011;95:1223–34.
- [9] Bell NH, Stern PH, Pantzer E, et al. Evidence that increased circulating 1 alpha, 25-dihydroxyvitamin D is the probable cause for abnormal calcium metabolism in sarcoidosis. *J Clin Invest* 1979;64:218–25.
- [10] Karakelides H, Geller JL, Schroeter AL, et al. Vitamin D-mediated hypercalcemia in slack skin disease: evidence for involvement of extrarenal 25-hydroxyvitamin D 1alpha-hydroxylase. *J Bone Miner Res* 2006;21:1496–9.
- [11] Brunette MG, Chan M, Ferriere C, et al. Site of 1,25(OH)₂ vitamin D₃ synthesis in the kidney. *Nature* 1978;276:287–9.
- [12] Akiba T, Endou H, Koseki C, et al. Localization of 25-hydroxyvitamin D₃-1 alpha-hydroxylase activity in the mammalian kidney. *Biochem Biophys Res Commun* 1980;94:313–8.
- [13] Chu P, Connolly MK, LeBoit PE. The histopathologic spectrum of palisaded neutrophilic and granulomatous dermatitis in patients with collagen vascular disease. *Arch Dermatol* 1994;130:1278–83.