

This is an Open Access article licensed under the terms of the Creative Commons Attribution-NonCommercial-NoDerivs 3.0 License ([www.karger.com/OA-license](http://www.karger.com/OA-license)), applicable to the online version of the article only. Distribution for non-commercial purposes only.

# 'Pseudo Wine Glass' Radiological Appearance of Intracranial Haemorrhage as a Result of Chemotherapy- Induced Thrombocytopenia and Red Cell Sedimentation

O. Oladipo<sup>a</sup> R. Kennedy<sup>a</sup> A. Shiels<sup>b</sup> S. McAleer<sup>a</sup>

Departments of <sup>a</sup>Medical Oncology and <sup>b</sup>Radiology, Belfast City Hospital, Belfast, UK

## Key Words

Chemotherapy · Haemorrhage, intracranial · Thrombocytopenia · Allosensitisation · Peripheral stem cell transplantation · Wine-glass, red cell sedimentation

## Abstract

The radiological features of intracranial haemorrhage are well described in the literature, but atypical appearances can sometimes develop. We report a case of chemotherapy-induced thrombocytopenia resulting in fatal intracranial haemorrhage in a man undergoing autologous peripheral stem cell transplantation. The CT showed an unusual appearance, with separation of blood products and fluid within the haemorrhage leading to a wine-glass-shaped outline in the image. This case draws attention to this uncommon radiological finding and emphasises the risks of allosensitisation following chemotherapy and peripheral stem cell transplantation.

## Case Report

A 39-year-old male received high-dose chemotherapy (intravenous etoposide, carboplatin and ifosfamide) for recurrent testicular teratoma, and subsequently underwent autologous peripheral stem cell transplantation. One week after the procedure, the patient had developed renal tubular failure believed to be secondary to the high-dose carboplatin, with therapy-resistant hypertension (190/120 mm Hg) and a serum creatinine of 697 mmol/l. Therefore emergency haemodialysis was performed. In addition, there had been an immune response to donor platelets resulting in thrombocytopenia with platelet counts of 3,000/ $\mu$ l. This led to a search for HLA-matched platelets to attempt to maintain the count above 10,000/ $\mu$ l. However, identical or closely HLA-matched blood products for this patient were not obtainable.

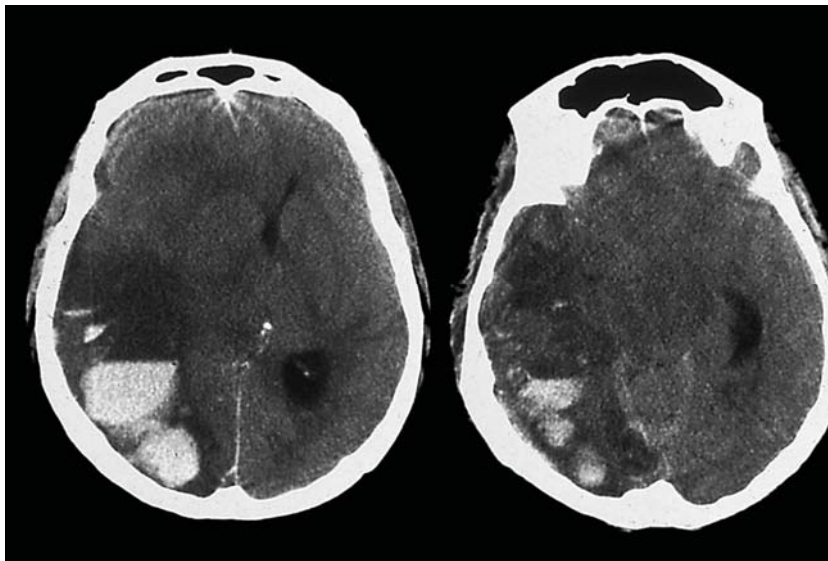
One week later, shortly after a session of haemodialysis, he developed a severe headache and progressive drowsiness. An urgent CT scan of the brain ([fig. 1](#)) demonstrated an intracerebral bleed in the right hemisphere, subarachnoid haemorrhage around the basal cisterns and compression of the right ventricle with midline shift. The intracerebral bleed was layered in appearance due to red cell sedimentation as the platelet count of 3,000/ $\mu$ l at the time of the event was inadequate for clot formation and retraction, and the subarachnoid bleed surrounding the midbrain created an unusual ‘wine glass’ appearance. This catastrophic haemorrhage was probably due to thrombocytopenia, exacerbated by hypertension and the heparin used during haemodialysis. The patient was ventilated, but died before surgical intervention was possible.

## Discussion

There are few large-scale reports into thrombocytopenia following chemotherapy for solid tumours, leading to variability in clinical practice [1]. In general, guidelines are extrapolated from available data in haematological malignancies [2] and the threshold of 20,000 platelets/ $\mu$ l before administration of prophylactic platelet transfusions is widely used [2]. Recent studies in solid tumours suggest that this threshold may be acceptable, as the incidence of chemotherapy-induced thrombocytopenia remains low and at-risk patients are readily identifiable [3]. Moreover, the efficacy of such transfusions is reportedly limited [3], as seen in our patient. For patients who are refractory to platelet transfusions, HLA alloimmunisation is the commonest cause, and HLA-matched platelets have been shown to improve platelet increments when transfused, compared with unmatched platelets [4]. Unfortunately, no appropriate match was available for this case. Even when significant thrombocytopenia occurs, the incidence of severe events such as intracranial haemorrhage is low [3, 5], and major bleeding is associated with, among other factors, a platelet count of less than 10,000/ $\mu$ l [6]. The risks of intracranial haemorrhage are, however, not insignificant, particularly in the presence of other risk factors, and the outcome is often devastating, and mortality rates very high [7].

The radiological appearance of intracranial haemorrhages differs, depending on the timing of the imaging after the event, due to differences in composition of the blood breakdown products [8]. The earliest phase (up to 12 h after the haemorrhage) is referred to as the ‘hyperacute stage’ and the CT appearance is usually hyperdense. During this stage, the bleed is usually comprised of a liquid collection of intracellular oxygenated haemoglobin, and in the presence of adequate platelet function, this will gradually clot over the following hours, and retract, expelling serum and creating vasogenic oedema in the surrounding brain tissue [9]. CT imaging of our patient was performed 6 h after the devastating haemorrhage (i.e. in the hyperacute stage), and we noted an unusual layering effect, with the formation of a fluid-blood level within the haemorrhage and unclotted blood settling within the dependent portion of the ventricular or subarachnoid space. Additionally, there was significant background low attenuation observed in the right hemisphere, and this may have represented haemorrhage within the infarct, possibly related to the uncontrolled hypertension. Whilst it has been reported that thrombocytopenia alone may not alter the distinctive CT appearances of intracranial haemorrhage [10, 11], there were other mitigating factors in this case; not least the use of heparin during the preceding haemodialysis session. This may have contributed further to the impaired blood clotting and resulted in the atypical radiological appearance. Thus a pattern comparable to a wine glass outline was created, and to our knowledge, this has not been previously described in such a context.

This case highlights the risks associated with allosensitisation following chemotherapy and peripheral stem cell transplantation. The profound effects of the impaired clotting in the setting of acute renal failure requiring haemodialysis, and the subsequent intracranial haemorrhage, emphasises the difficulties with managing complex co-existing medical complications of chemotherapy. Thus we report this rare radiological finding as a consequence of these complications.



**Fig. 1.** An axial unenhanced CT image from a 39-year-old male with severe intracranial haemorrhage. The CT demonstrates a gross intracerebral haematoma in the parieto-occipital region of the right cerebral hemisphere. The layering effect seen in the haematoma suggests impaired clotting, with multiple levels noted. There is also evidence of intraventricular haemorrhage in the left lateral ventricle and subarachnoid haemorrhage around the basal cisterns. A gross midline shift with mass effect of the right cerebral hemisphere can be seen.

## References

- 1 Kaushansky K: The thrombocytopenia of cancer. Prospects for effective cytokine therapy. *Hematol Oncol Clin North Am* 1996;10:431–455.
- 2 Pisciotto PT, Benson K, Hume H, Glassman AB, Oberman H, Popovsky M, et al: Prophylactic versus therapeutic platelet transfusion practices in hematology and/or oncology patients. *Transfusion* 1995;35:498–502.
- 3 Norfolk DR, Ancliffe PJ, Contreras M, Hunt BJ, Machin SJ, Murphy WG, et al: Consensus Conference on Platelet Transfusion, Royal College of Physicians of Edinburgh, 27–28 November, 1997. Synopsis of background papers. *Br J Haematol* 1998;101:609–617.
- 4 Elting LS, Rubenstein EB, Martin CG, Kurtin D, Rodriguez S, Laiho E, et al: Incidence, cost, and outcomes of bleeding and chemotherapy dose modification among solid tumor patients with chemotherapy-induced thrombocytopenia. *J Clin Oncol* 2001;19:1137–1146.
- 5 Heal JM, Blumberg N, Masel D: An evaluation of crossmatching, HLA, and ABO matching for platelet transfusions to refractory patients. *Blood* 1987;70:23–30.

- 6 Goldberg GL, Gibbon DG, Smith HO, DeVictoria C, Runowicz CD, Burns ER: Clinical impact of chemotherapy-induced thrombocytopenia in patients with gynecologic cancer. *J Clin Oncol* 1994;12:2317–2320.
- 7 Heckman KD, Weiner GJ, Davis CS, Strauss RG, Jones MP, Burns CP: Randomized study of prophylactic platelet transfusion threshold during induction therapy for adult acute leukemia: 10,000/microL versus 20,000/microL. *J Clin Oncol* 1997;15:1143–1149.
- 8 Hill MD, Silver FL, Austin PC, Tu JV: Rate of stroke recurrence in patients with primary intracerebral hemorrhage. *Stroke* 2000;31:123–127.
- 9 Osborn AG: Intracranial Hemorrhage. *Diagnostic Neuroradiology*. St. Louis, Mosby, 1994, pp 154–198.
- 10 Kidwell CS, Wintermark M: Imaging of intracranial haemorrhage. *Lancet Neurol* 2008;7:256–267.
- 11 Pierce JN, Taber KH, Hayman LA: Acute intracranial hemorrhage secondary to thrombocytopenia: CT appearances unaffected by absence of clot retraction. *AJNR Am J Neuroradiol* 1994;15:213–215.