

Isolated Non-chylous Pleural Effusion in Two Neonates

Isolated pleural effusion, so called primary pleural effusion denotes a pleural effusion without documented etiology such as a cardiac, inflammatory, iatrogenic problem or fetal hydrops. Chromosomal anomaly such as Down syndrome may be associated with isolated pleural effusion. The content of the isolated pleural effusion is mostly chylous, and isolated non-chylous pleural effusion in neonate is rare. We experienced 2 cases of isolated non-chylous pleural effusion. They had neither cardiac problem nor other sign of hydrops fetalis. Imaging diagnosis was done by plain chest radiography and subsequent ultrasonogram. One of them was diagnosed to Down syndrome by karyotyping. They were fared well after diagnostic and therapeutic thoracentesis. We describe 2 cases of non-chylous pleural effusion and review a few English-language case reports of this entity.

Key Words : Hydrothorax; Pleural Effusion; Down Syndrome

Ji Young Hwang, Jeong Hyun Yoo,
Jeong Soo Suh, Chung Sik Rhee

Department of Radiology, Ewha Womans University,
Seoul, Korea

Received : 3 June 2002
Accepted : 1 October 2002

Address for correspondence

Jeonghyun Yoo, M.D.
Department of Radiology, Ewha Womans
University, Dongdaemun Hospital, 70 Chongro
6-ga, Chongro-gu, Seoul 110-783, Korea
Tel : +82.2-760-5144, 5231, Fax : +82.2-760-5046
E-mail : YooLee@ewha.ac.kr

INTRODUCTION

Congenital isolated pleural effusion is a rare condition, with an incidence at about 1 in 12,000 to 1 in 15,000 pregnancies (1). The content of the effusion is usually chylous, however, a minority of cases is not chylous (2, 3). The incidence of non-chylous, isolated pleural effusion in neonate and its association of chromosome anomaly have not been exactly unknown. Only one case report has been described about congenital non-chylous pleural effusion with Down syndrome (4). We experienced 2 cases of non-chylous pleural effusion, one of which was associated with Down syndrome.

CASE REPORT

Case 1

A newborn, whose mother had not received antenatal care, was transferred with respiratory distress. The initial Apgar scores were 2 at 1 min and 6 at 5 min. He had no cardiac problem. He was not febrile. Chest radiograph showed haziness of the left hemithorax. The endotracheal tube was pushed rightward, indicating mediastinal shifting (Fig. 1A). Ultrasonogram showed pleural fluid in the left hemithorax with the collapsed left lung (Fig. 1B). A chest tube was inserted for drainage of the pleural fluid which was clear. Analysis of the fluid was shown protein 34 g/L, glucose 88 mg/dL, Cl⁻ 100 mM/L, LDH 953 IU/L, WBC 2,000/ μ L and RBC 1,000/ μ L. Bacteriologic examination demonstrated no microorganism. Subsequent analysis of the pleural fluid following total parenteral nutri-

tion revealed triglyceride (TG) 3 mg/dL, indicative of non-chylous pleural effusion.

His karyotype was 47,XY,+21, so he was diagnosed as Down syndrome. Follow-up chest radiograph showed well expanded both lungs without residual pleural effusion (Fig. 1C).

Case 2

A newborn at 36 weeks of gestational age was delivered by cesarean section without respiratory distress. He had been diagnosed as fetal hydrothorax by fetal ultrasonogram at 32 weeks of gestational age (not shown). The initial chest radiograph showed diffuse increased opacity of the right hemithorax with widening of pleural space (Fig. 2A). Ultrasonogram showed anechoic fluid collection in right hemithorax (Fig 2B). He underwent sono-guided thoracentesis. Analysis of pleural fluid showed protein 32 g/L, glucose 85 mg/dL, Cl⁻ 103 mM/L, LDH 281 IU/L, WBC 2,500/ μ L and RBC 220/ μ L. The level of TG in pleural fluid after milk feeding was 4 mg/dL.

No chromosomal anomaly was detected. He had no cardiac problem. He had neither congenital mass nor infectious disease. Follow-up chest radiograph showed clear resorption of pleural effusion (Fig. 2C). He did well until he was 4 yr old.

DISCUSSION

Neonatal pleural effusion may be congenital, inflammatory, iatrogenic following line placement, or secondary to congenital heart failure (5). The effusion is mostly unilateral and about 60% of cases has been found in the right hemithorax (2).

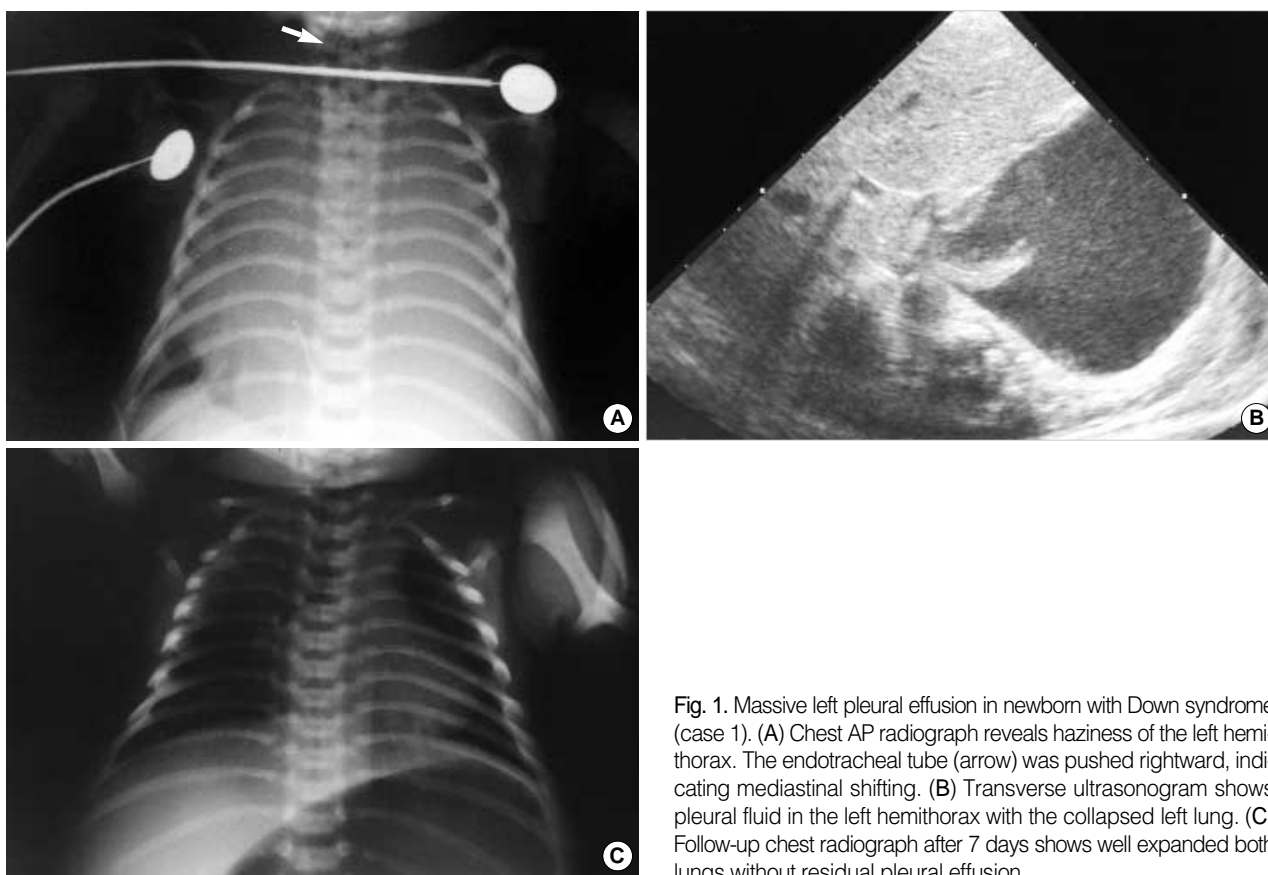


Fig. 1. Massive left pleural effusion in newborn with Down syndrome (case 1). (A) Chest AP radiograph reveals haziness of the left hemithorax. The endotracheal tube (arrow) was pushed rightward, indicating mediastinal shifting. (B) Transverse ultrasonogram shows pleural fluid in the left hemithorax with the collapsed left lung. (C) Follow-up chest radiograph after 7 days shows well expanded both lungs without residual pleural effusion.

Among the neonatal pleural effusions, isolated pleural effusion may be diagnosed when there are no other findings of hydrops fetalis nor any inflammatory, iatrogenic, and cardiac problem (5).

The content of the isolated pleural effusion is mostly chylous, resulting from a malformation or tear in the fetal thoracic duct. Chylous pleural effusion may be initially serous and turns into chylous only after milk feeding (2). Distinguishing features of chylous effusion from serous effusion are milky-white or yellow bloody color, more than 110 mg/dL (>1.24 mMol/L) of TG level and lymphocytosis. However, lymphocytosis can be also discovered in other conditions such as tuberculosis or viral infection. Our two cases proved to non-chylous effusion after milk feeding and total parenteral nutrition containing intralipid with medium-chain TG (6).

In a minority of the cases, the content of the effusion is serous. Some authors reported that non-chylous or serous congenital pleural effusion may be associated with underlying thoracic cause such as primary lymphangiectasia, congenital cystic adenomatoid malformation, bronchopulmonary dysplasia, diaphragmatic hernia, chest wall hamartoma, and pulmonary vein atresia (3, 7). Like our case, isolated non-chylous pleural effusion is rare. Several cases have been reported about congenital or fetal pleural effusion with chromosomal anomaly such as Down syndrome and Turner syndrome (8-11). Most of these

pleural effusion were chylothorax or associated hydrops fetalis (6, 9). Hence, karyotyping is indicated in a fetus or newborn with isolated pleural effusion for the evaluation of associated chromosomal anomaly (8, 11). However, association of Down syndrome with isolated non-chylous pleural effusion has been rarely reported (4). One of our cases was diagnosed as Down syndrome.

Imaging diagnosis was done by plain chest radiograph and ultrasonogram with thoracentesis (5). Chest radiograph usually demonstrates homogeneous haziness in the involved hemithorax. It may be sometimes confusing. Diaphragmatic hernia filled with fluid contents, congenital chest mass, such as congenital cystic adenomatoid malformation or pulmonary sequestration and total atelectasis should be included in differential diagnosis. Chest ultrasonogram readily and noninvasively distinguish pleural effusion from other conditions (5).

The clinical course of the isolated pleural effusion is variable. Congenital pleural effusion causing pulmonary hypoplasia or maternal polyhydramnios by extrinsic compression of the fetal esophagus may be associated with high mortality (1). However, it is reported that some cases showed spontaneous resolution in utero or fared well with residual small amount of pleural effusion (7, 11).

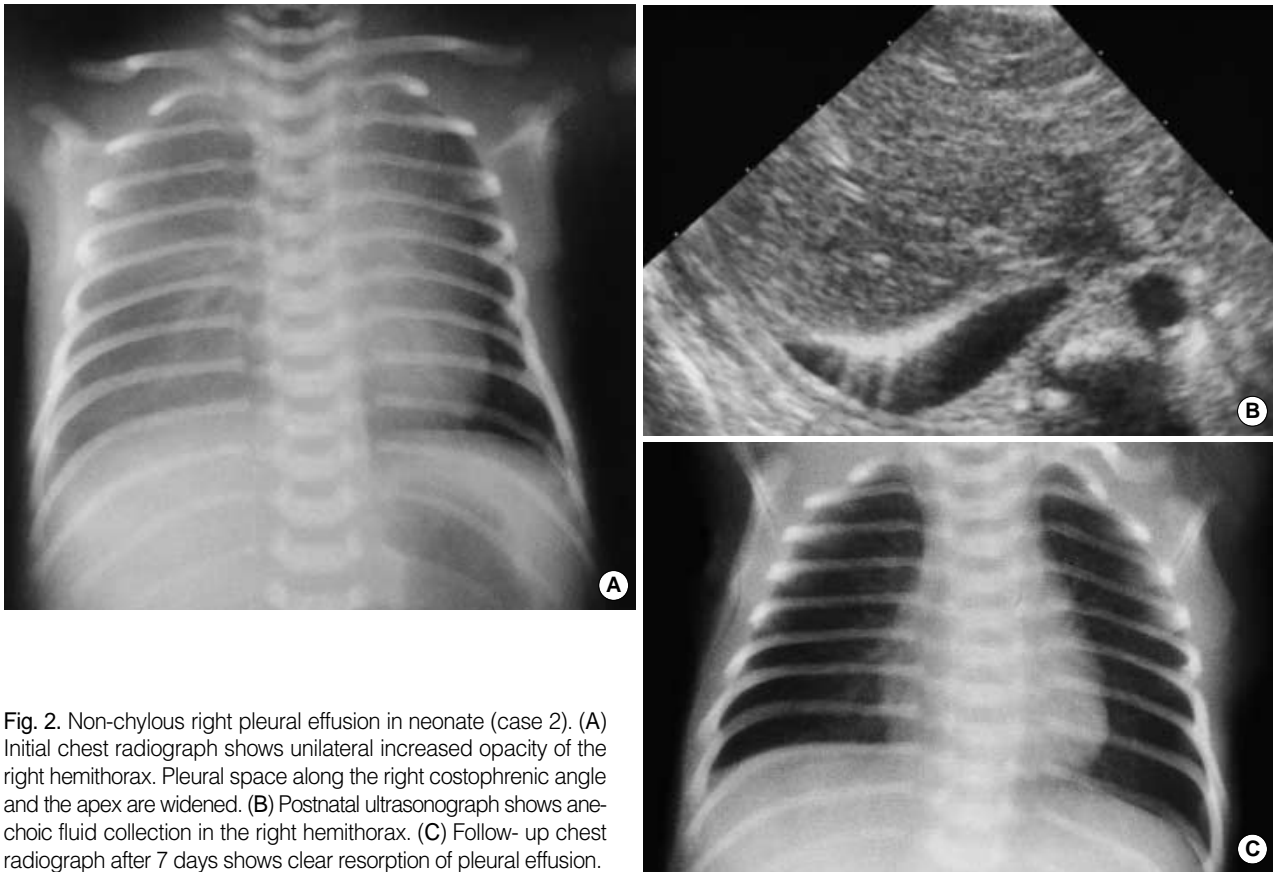


Fig. 2. Non-chylous right pleural effusion in neonate (case 2). (A) Initial chest radiograph shows unilateral increased opacity of the right hemithorax. Pleural space along the right costophrenic angle and the apex are widened. (B) Postnatal ultrasonograph shows anechoic fluid collection in the right hemithorax. (C) Follow-up chest radiograph after 7 days shows clear resorption of pleural effusion.

REFERENCES

1. Longaker MT, Laberge JM, Dansereau J, Langer JC, Crombleholme TM, Callen PW, Golbus MS, Harrison MR. *Primary fetal hydrothorax: natural history and management. J Pediatr Surg* 1989; 24: 573-6.
2. Chernick V, Reed MH. *Pneumothorax and chylothorax in the neonatal period. J Pediatr* 1970; 76: 624-32.
3. Laberge JM, Crombleholme TM, Longaker MT. *The fetus with pleural effusions. In: Harrison MR, Golbus MS, Filly RA, editors, The unborn patient, 2nd edition, Philadelphia, WB Saunders 1990; 314-9.*
4. Modi N, Cooke RW. *Congenital non-chylous pleural effusion with Down's syndrome. J Med Genet* 1987; 24: 567-8.
5. May DA, Barth RA, Yeager S, Nussbaum-Blask A, Bulas DI. *Perinatal and postnatal chest sonography. Radiol Clin North Am* 1993; 31: 499-516.
6. Yamamoto T, Koeda T, Tamura A, Sawada H, Nagata I, Nagata N, Ito T, Mio Y. *Congenital chylothorax in a patient with 21 trisomy syndrome. Acta Paediatr Jpn* 1996; 38: 689-91.
7. Weber AM, Philipson EH. *Fetal pleural effusion: a review and meta-analysis for prognostic indicators. Obstet Gynecol* 1992; 79: 281-6.
8. Achiron R, Weissman A, Lipitz S, Mashiach S, Goldman B. *Fetal pleural effusion: the risk of fetal trisomy. Gynecol Obstet Invest* 1995; 39: 153-6.
9. Ho NK, Leong NK, Lim SB. *Chylothorax in Down's syndrome associated with hydrops fetalis. J Singapore Paediatr Soc* 1989; 31: 90-2.
10. Foote KD, Vickers DW. *Congenital pleural effusion in Down's syndrome. Br J Radiol* 1986; 59: 609-10.
11. Hegay Z, Reece A, Roberts A, Hobbins JC. *Isolated fetal pleural effusion: a prenatal management dilemma. Obstet Gynecol* 1993; 81: 147-52.